



Textbook of  
**HISTOLOGY**  
&  
A PRACTICAL GUIDE

**Second edition**

**JP Gunasegaran**


**Textbook of Histology  
and  
A Practical Guide**

"This page intentionally left blank"

# Textbook of Histology and A Practical Guide

**JP Gunasegaran**

Professor, Department of Anatomy  
Rajah Muthiah Medical College & Hospital  
Annamalai University  
Annamalai Nagar-608 002  
Chidambaram, Tamil Nadu, India



**ELSEVIER**

*A division of*

Reed Elsevier India Private Limited  
Gurgaon (Haryana)

**Textbook of Histology and a Practical Guide, 2/e**  
Gunasegaran

ELSEVIER  
*A division of*  
Reed Elsevier India Private Limited

*Mosby, Saunders, Churchill Livingstone, Butterworth Heinemann and  
Hanley & Belfus are the Health Science imprints of Elsevier.*

© 2010 Elsevier

First Edition 2007  
Second Edition 2010

All rights reserved. No part of this publication may be reproduced or transmitted in any form or by any means, electronic or mechanical including photocopying, recording, or any information storage and retrieval system without the prior written permission from the publisher and the copyright holder.

ISBN: 978-81-312-2490-8

Medical knowledge is constantly changing. As new information becomes available, changes in treatment, procedures, equipment and the use of drugs become necessary. The authors, editors, contributors and the publisher have, as far as it is possible, taken care to ensure that the information given in this text is accurate and up-to-date. However, readers are strongly advised to confirm that the information, especially with regard to drug dose/usage, complies with current legislation and standards of practice. *Please consult full prescribing information before issuing prescriptions for any product mentioned in the publication.*

Published by Elsevier, a division of Reed Elsevier India Private Limited.  
*Registered Office:* Gate No. 3, Building No. A-1, 2 Industrial Area, Kalkaji, New Delhi-110 019.  
*Corporate Office:* 14th Floor, Building No. 10B, DLF Cyber City, Phase II, Gurgaon-122 002, Haryana, India.

Head, Medical Education: Jalees Farhan  
Managing Editor (Development): Binny Mathur  
Copy Editor: Goldy Bhatnagar  
Manager-Production: N.C. Pant

Laser typeset by Chitra Computers, New Delhi.

Printed and bound at Sanat Printers, Kundli, Haryana.

# PREFACE TO THE SECOND EDITION

---

I am extremely thankful to my colleagues and students for their valuable suggestions and also drawing my attention towards minor errors and omissions in the first edition of my book, "Textbook of Histology and a Practical Guide" released in 2007. I am very happy to state that I have tried to incorporate almost all of them as detailed below, without changing the simple, concise and friendly format of the book.

1. Minor errors and omissions have appropriately been amended where ever applicable throughout the book.
2. A brief account on principles of various types of microscopes has been included in the first chapter dealing with histological techniques.
3. Salient features of biological phenomena of the cell is added in the second chapter devoted to epithelial tissue.
4. Characteristics of oral mucosa have been included under Oral Cavity in Chapter 12, detailing digestive system.
5. All photomicrographs have been enlarged for better visualization of labelling inside them besides replacing around 50 old ones with new higher resolution digital pictures. In addition, legends and all illustrations have been aligned side by side for easy and ready comprehension by the students. Similarly the H&E diagrams have also been enlarged.

I sincerely hope to receive the same kind of support for this revised edition, which is being released within a short span of three years.

At this juncture I wish to thank the staff of Reed Elsevier India Pvt. Ltd., especially Dr. Binny Mathur (Managing Editor) for shouldering the responsibility of editing the book for the second time and for taking a keen interest in making the book 'the best'.

**JP GUNASEGARAN**

"This page intentionally left blank"

# PREFACE TO THE FIRST EDITION

This book presents microscopic structure of tissues and organs in a sequential manner using simple and precise language to make it easily understandable, while sustaining the interest of the reader. The charts and tables given in the book are intended to help the reader to revise the topic quickly.

The advantage of the book is its concise nature. Detailed descriptions have been deliberately avoided keeping in mind the heavy workload on the beginners and the fact that they need to know only the basic facts.

The self-assessment exercises incorporating all the important information are provided after the text. The exercises enable the students to test their ability to recapitulate what has been studied. The section on Practicals at the end of each chapter is designed to suit the revised curriculum and time schedule. Each of the 23 Practicals follows a class lecture on the topic. Though all slides in Histology are found in the Practical section, the rare ones like cardio-oesophageal, pyloroduodenal, rectoanal, sclerocorneal junctions are meant for postgraduates and these may, if so desired, be shown as demonstration to undergraduate students.

The unique features of the book are its photomicrographs from slides collected over a period of time and colour diagrams in boxes drawn by the author himself with haematoxylin and eosin colour pencils.

- The photomicrographs and the legends in the form of practical instructions will help the students to identify the tissue/organ and understand the details of the slide given by the institution without much help from the teacher.
- The colour diagrams will guide the students to learn the art of drawing so that they can draw a better labelled diagram of their own in the record notebook. The intention is to make the students develop their own artistic skill rather than copying from the book or from other record notebooks. The salient features for identification of the section are given in boxes by the side of the diagrams to help the students in practical examination.

The vast experience gained by the author in India and abroad in premier institutions like CMC, JIPMER, RMMC and Al-Fateh University of Medical Sciences and the constant encouragement given by his colleagues and well wishers induced him to come out with the book.

It is hoped that the book will meet the requirements of undergraduate students in the fields of medicine, dentistry, veterinary science, mammalian biology and other allied fields.

Though care is taken at every stage to fulfill the requirements of the students based on curriculum prescribed by MCI, it may still be possible to improve the quality of the book. I would very much appreciate and welcome suggestions/comments for improvement from teachers and students, and this may be conveyed to me through e-mail (jpguna@rediffmail.com) or by post.

**JP GUNASEGARAN**



"This page intentionally left blank"

# ACKNOWLEDGEMENTS

With profound joy and happiness, I express my heartfelt thanks and gratitude to all those who helped me to fulfill my dream project ‘Textbook of Histology and a Practical Guide’.

First and foremost I place on record the yeomen contribution made by two senior academics, Professor S Vembar and Professor Samir C Mitra in educating me throughout the period of writing and in shaping this book as it appears today. I am deeply indebted to Professor S Vembar, Adviser to Vice Chancellor, Annamalai University and former Principal, Rajah Muthiah Medical College for sparing his valuable time and meticulously going through the manuscript word by word to improve the quality of presentation. I sincerely thank Professor Samir C Mitra, Professor Emeritus, JIPMER for his valuable guidance and suggestions to maintain the accuracy of the contents throughout the course of writing.

I am grateful to my senior colleague, Professor A Krishnamurthy, for his constant encouragement and for providing some line diagrams. I am also thankful to my other colleagues who shared my teaching burden when I was busy with the ‘project’. My special thanks are due to Dr. M Nirmal, Reader in Oral Pathology, Mr. K Beekar, Mrs A Gnanmpal, Technicians of my department and Mr. Kamal Hassan Kader, Technician, now in UAE, for their support in photomicrography. I express my thanks to Mr. N Sundar for helping me in computer-related work and to Mr. Gnanavel for drawing line diagrams.

I am indebted to my family especially my wife Vanmathi and children Divya, Niranj and Jeff for their patience during the period of writing when I kept busy and would not devote enough time to them. I fondly remember the technical support rendered by my daughter Divya throughout the exercise. I am very happy to dedicate this book to my family.

I thank the University authorities for permitting me to utilize the infrastructure available.

With pleasure I express my deep gratitude to the staff of Elsevier India Pvt. Ltd. and in particular, Mr. Rajiv Banerji (Publishing Manager), Mr. Tanweer Ahmad (Commissioning Editor), and Dr. Binny Mathur (Managing Editor) for their efforts and keen interest in bringing out the book to the best of my satisfaction. I hope this book, which has been a labour of love for me, will be well received by academics and student community.

It is because of His grace that I have been able to accomplish the task of writing the book and may all glory and honour be His!

**JP GUNASEGARAN**

"This page intentionally left blank"

# CONTENTS

<i>Preface to the Second Edition</i>	v
<i>Preface to the First Edition</i>	vii
<i>Acknowledgements</i>	ix
<b>1. HISTOLOGICAL TECHNIQUES AND MICROSCOPY</b>	<b>1</b>
Introduction	1
General Architecture of the Body	1
Units of Measurement Used in Histology	1
Interpretation of a Section	2
Processing of Tissues for Light Microscopy (Paraffin Wax Embedding)	2
Staining Procedure	4
Microscopy	5
Self-assessment Exercise	8
Practical No. 1 Light Microscope and Histological Technique	9
<b>2. EPITHELIAL TISSUE</b>	<b>13</b>
Classification of Epithelial Tissue	13
<b>Surface (or) Lining Epithelium</b>	<b>13</b>
General Features	13
Intercellular Junctions (Junctional Complexes)	14
Surface Modifications of Epithelial Cells	15
Classification of Lining Epithelium	16
Some Biological Phenomena of the Cell	23
Self-assessment Exercise	27
Practical No. 2 Epithelial Tissue	29
I: Simple Epithelium	29
II: Stratified Epithelium	34
<b>3. GLANDS</b>	<b>37</b>
General Features	37
Development	37
Classification of Glands	37
General Architecture of a Compound Gland	42
Exercise	49
Self-assessment Exercise	43
Practical No. 3 Glandular Epithelium: The Salivary Glands	45
<b>4. CONNECTIVE TISSUE</b>	<b>51</b>
General Features	51
Classification of Connective Tissue (Based on Structure and Function)	51
Ordinary Connective Tissue	56
Self-assessment Exercise	65
Practical No. 4 Connective Tissue I: Ordinary	67

<b>5. CARTILAGE</b>	<b>73</b>
General Features	73
Components	74
Types	74
Functions	76
Self-assessment Exercise	77
Practical No. 5 Connective Tissue II: Cartilage	79
<b>6. BONE</b>	<b>83</b>
General Features	83
Types of Bone	83
Bone Membranes	84
Bone Composition	84
Structure of Compact Bone	85
Structure of Spongy or Cancellous Bone	88
Bone Formation/Ossification	88
Self-assessment Exercise	94
Practical No. 6 Connective Tissue III: Bone	96
<b>7. LYMPHOID TISSUE</b>	<b>103</b>
Introduction	103
Immunoglobulins	103
<b>Thymus</b>	<b>106</b>
General Features	106
Components/Structure	106
Characteristic Features	109
Functions	109
<b>Lymph Node</b>	<b>109</b>
General Features	109
Components/Structure	109
Functions	111
<b>Spleen</b>	<b>112</b>
General Features	112
Components/Structure	112
Theories of Splenic Circulation	114
Functions	116
<b>Palatine Tonsil</b>	<b>116</b>
Self-assessment Exercise	119
Practical No. 7 Lymphoid and Haemopoietic Tissue	122
<b>8. MUSCULAR TISSUE</b>	<b>131</b>
Introduction	131
Types	131
<b>Skeletal Muscle</b>	<b>131</b>
General Features	131
General Architecture	131
Structure of a Skeletal Muscle Fibre	133
Contraction Mechanism	134
Types of Skeletal Muscle Fibres	135
Motor End-plates	136
Muscle Spindles	136
<b>Smooth Muscle</b>	<b>137</b>
<b>Cardiac Muscle</b>	<b>137</b>

Self-assessment Exercise	141
Practical No. 8 Muscular Tissue	143
Demonstration of Special Slides	146
<b>9. NERVOUS TISSUE</b>	<b>147</b>
Introduction	147
Anatomical Classification of Nervous System	147
Classification of Neurons	147
Structure of a Neuron (Multipolar)	148
<b>Ganglia</b>	<b>153</b>
Neuroglia (in CNS)	155
<b>Cerebral Cortex</b>	<b>155</b>
General Features	155
Structure	156
<b>Cerebellar Cortex</b>	<b>158</b>
General Features	158
Structure	158
Self-assessment Exercise	161
Practical No. 9 Nervous Tissue	163
<b>10. BLOOD VESSELS</b>	<b>173</b>
Introduction	173
Types of Blood Vessels	173
Structure	173
<b>Arteries</b>	<b>173</b>
General Features	174
Structure	174
<b>Arteriole</b>	<b>178</b>
General Features	178
Structure	178
<b>Capillaries</b>	<b>178</b>
General Features	178
Structure	178
Functions of Capillary Endothelium	179
<b>Venule</b>	<b>180</b>
General Features	180
Structure	180
<b>Veins</b>	<b>180</b>
General Features	180
Structure	180
Self-assessment Exercise	183
Practical No. 10 Blood Vessels	185
<b>11. INTEGUMENTARY SYSTEM</b>	<b>189</b>
Introduction	189
Functions of Skin	189
Types of Skin	189
Structure	190
Epidermis	190
Glands of Skin	196
Appendages of Skin	198
Skin Receptors	200
Self-assessment Exercise	202
Practical No. 11 Skin	204

<b>12. DIGESTIVE SYSTEM</b>	<b>211</b>
Introduction	211
<b>Oral Cavity</b>	<b>211</b>
General Features	211
Structure of Oral Mucosa	211
<b>Lips</b>	<b>212</b>
<b>Gingiva</b>	<b>212</b>
<b>Teeth</b>	<b>213</b>
Histological Structure of a Tooth	213
<b>Tongue</b>	<b>216</b>
Taste Buds	218
<b>Gastrointestinal Tract (GIT)</b>	<b>221</b>
General Plan of Gastrointestinal Tract	221
<b>Oesophagus</b>	<b>222</b>
General Features	222
Structure	222
<b>Stomach</b>	<b>223</b>
General Features	223
Structure	223
Salient Features of Each Region of Stomach	226
<b>Small Intestine</b>	<b>227</b>
General Features	227
Structure	228
Salient Microscopic Features of Each Region of Small Intestine	229
<b>Large Intestine</b>	<b>230</b>
General Features	230
Structure	230
Salient Features of Each Region of Large Intestine	232
<b>Glands Associated with Digestive System</b>	<b>233</b>
<b>Salivary Glands</b>	<b>234</b>
General Features	234
Structure	234
<b>Liver</b>	<b>237</b>
General Features	237
Structure	237
Regeneration of Liver	241
<b>Pancreas</b>	<b>241</b>
General Features	241
Structure	241
<b>Gall Bladder</b>	<b>244</b>
General Features	244
Structure	244
Self-assessment Exercise	245
Practical No. 12 Digestive System	248
I: Oral Cavity	248
II: Oesophagus and Stomach	252
III: Intestine	258
IV: Glands	265
<b>13. URINARY SYSTEM</b>	<b>271</b>
Introduction	271
<b>Kidney</b>	<b>271</b>
General Features	271
Macroscopic Features	271

Microscopic Structure	272
Juxtaglomerular Apparatus (JGA)	278
<b>Ureter</b>	<b>279</b>
General Features	279
Structure	279
<b>Urinary Bladder</b>	<b>279</b>
General Features	279
Structure	280
<b>Urethra</b>	<b>282</b>
Female Urethra	282
Self-assessment Exercise	283
Practical No. 13 Urinary System	285
<b>14. MALE REPRODUCTIVE SYSTEM</b>	<b>291</b>
Introduction	291
<b>Testis</b>	<b>291</b>
General Architecture of Testis	291
Seminiferous Tubules	293
Spermatogenic Cells	293
Interstitial Tissue and Leydig Cells	295
<b>Genital Ducts</b>	<b>296</b>
Epididymis	296
Vas Deferens (Ductus Deferens)	297
Ejaculatory Duct	297
<b>Accessory Sex Glands</b>	<b>298</b>
Seminal Vesicle	298
Prostate	299
Bulbourethral Gland	300
<b>Penis</b>	<b>300</b>
Gross Features	300
Microscopic Structure	302
Self-assessment Exercise	303
Practical No. 14 Male Reproductive System	306
<b>15. FEMALE REPRODUCTIVE SYSTEM</b>	<b>313</b>
Introduction	313
<b>Ovary</b>	<b>313</b>
General Features	313
Structure	313
Development of Ovarian Follicle	314
<b>Uterine Tube (Fallopian Tube)</b>	<b>320</b>
General Features	320
Structure	320
<b>Uterus</b>	<b>321</b>
General Features	321
Structure	321
Cyclic Changes in the Endometrium	321
Cervix of Uterus	323
<b>Vagina</b>	<b>324</b>
General Features	324
Structure	324
<b>Mammary Gland (Breast)</b>	<b>325</b>
General Features	325
Gross Structure	325
Histological Structure	325



<b>Placenta</b>	<b>328</b>
General Features	328
Structure	329
<b>Umbilical Cord</b>	<b>330</b>
General Features	330
Structure	330
Self-assessment Exercise	331
Practical No. 15 Female Reproductive System I and II	334
<b>16. RESPIRATORY SYSTEM</b>	<b>343</b>
Introduction	343
General Structure of the Conducting Portion of the Respiratory Tract	344
Structural Changes in the Conducting Portion of the Respiratory Tract (from Larynx to Bronchiole)	344
<b>Nasal Cavity</b>	<b>344</b>
General Features	344
Structure	345
<b>Pharynx</b>	<b>346</b>
General Features	346
Structure	346
<b>Larynx</b>	<b>347</b>
General Features	347
Structure	347
<b>Trachea</b>	<b>348</b>
General Features	348
Structure	348
<b>Principal Bronchus</b>	<b>350</b>
<b>Lungs: Intrapulmonary Bronchus and Its Subdivisions and Lung Parenchyma</b>	<b>350</b>
General Features	350
Structure	350
Self-assessment Exercise	356
Practical No. 16 Respiratory System	358
<b>17. ENDOCRINE GLANDS</b>	<b>361</b>
Introduction	361
<b>Pituitary (Hypophysis Cerebri)</b>	<b>361</b>
General Features	361
Development	362
<b>Thyroid</b>	<b>367</b>
General Features	367
Development	367
Structure	367
Synthesis and Secretion of Thyroid Hormones	369
Effect of Thyroid Hormones	369
<b>Parathyroid</b>	<b>370</b>
General Features	370
Development	370
Structure	370
<b>Adrenal (Suprarenal)</b>	<b>372</b>
General Features	372
Development	372
Structure	372
<b>Pineal Body (Epiphysis)</b>	<b>375</b>
General Features	375
Structure	375
Functions	375

Self-assessment Exercise	377
Practical No. 17 Endocrine Glands	379
<b>18. SPECIAL SENSES</b>	<b>385</b>
Introduction	385
<b>Eye</b>	<b>385</b>
General Features	385
Structure	385
<b>Ear</b>	<b>396</b>
General Features	396
Structure	396
Self-assessment Exercise	404
Practical No. 18 Special Senses	406
<b>Appendix: Some Important Cells: Their Location, Features and Functions</b>	<b>413</b>
<b>Index</b>	<b>429</b>

"This page intentionally left blank"

# 1

# HISTOLOGICAL TECHNIQUES AND MICROSCOPY

## INTRODUCTION

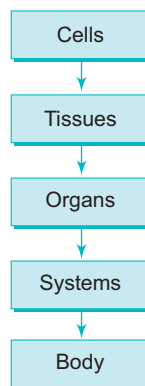
Before we study the various histological techniques, let us quickly familiarise ourselves with the basics of histology.

The term Histology is derived from the Greek words, *histos*, meaning “web” (tissue) and *logos* meaning “the study of”. Today the term histology is used not only for the study of tissue alone but also for the study of cells and fine structure of organs and can collectively be called microscopic anatomy. The study of histology provides a structural basis for functional correlation of an organ or tissue and is a necessary prerequisite to the study of the abnormal tissue (pathology).

## GENERAL ARCHITECTURE OF THE BODY

- Cells are the functional and building units of all living organisms and are held together by intercellular junctions and matrix.
- In multicellular organisms, tissues are collections of specialised cells with associated intercellular matrix for performing specific functions.
- There are four basic types of tissues in the body and each one performs a specific function:
  1. Epithelial tissue – protection
  2. Connective tissue – support
  3. Muscular tissue – contraction
  4. Nervous tissue – conduction

Thus the tissues form building blocks of the organs (e.g. *kidney, liver, ovary*) and they constitute the various functional systems (Flowchart 1.1) of the body (e.g. *digestive system, urinary system, reproductive system, etc.*).



Flowchart 1.1 Architecture of the body.

## UNITS OF MEASUREMENT USED IN HISTOLOGY

### For Light Microscopy

- The term micrometer ( $\mu\text{m}$ ) is being used nowadays instead of micron ( $\mu$ ).
- 1 micrometer or micron = 0.001 mm or  $10^{-6}$  m.

## For Electron Microscopy

- The term nanometer (nm) is being used nowadays instead of angstrom (Å°).
- 1 nanometer = 0.001 (µm or 10<sup>-9</sup> m).
- 1 angstrom = 0.1 nm or 10<sup>-10</sup> m.

## INTERPRETATION OF A SECTION

- When a thin section is examined under microscope only two-dimensional image is seen. It is actually a slice cut through parts of three-dimensional objects like cells, fibres and tubes (blood vessels and ducts) which are oriented randomly.
- It is often difficult to interpret the orientation of these structures in sectional view, because the plane of section may not pass through exactly, either transversely or longitudinally. This results in variation in the appearance of the cells, fibres and tubes depending on the plane of section.
- In order to comprehend the three-dimensional architecture of a structure from a two-dimensional section, it is necessary to study sections cut in different planes (Fig. 1.1). Serial sectioning of the tissue is prepared and studied in a sequential order to get information about the three-dimensional architecture of the structures.

## PROCESSING OF TISSUES FOR LIGHT MICROSCOPY (PARAFFIN WAX EMBEDDING)

- Tissues are processed by the following procedure to obtain thin translucent sections so that they can be examined under microscope by transillumination.

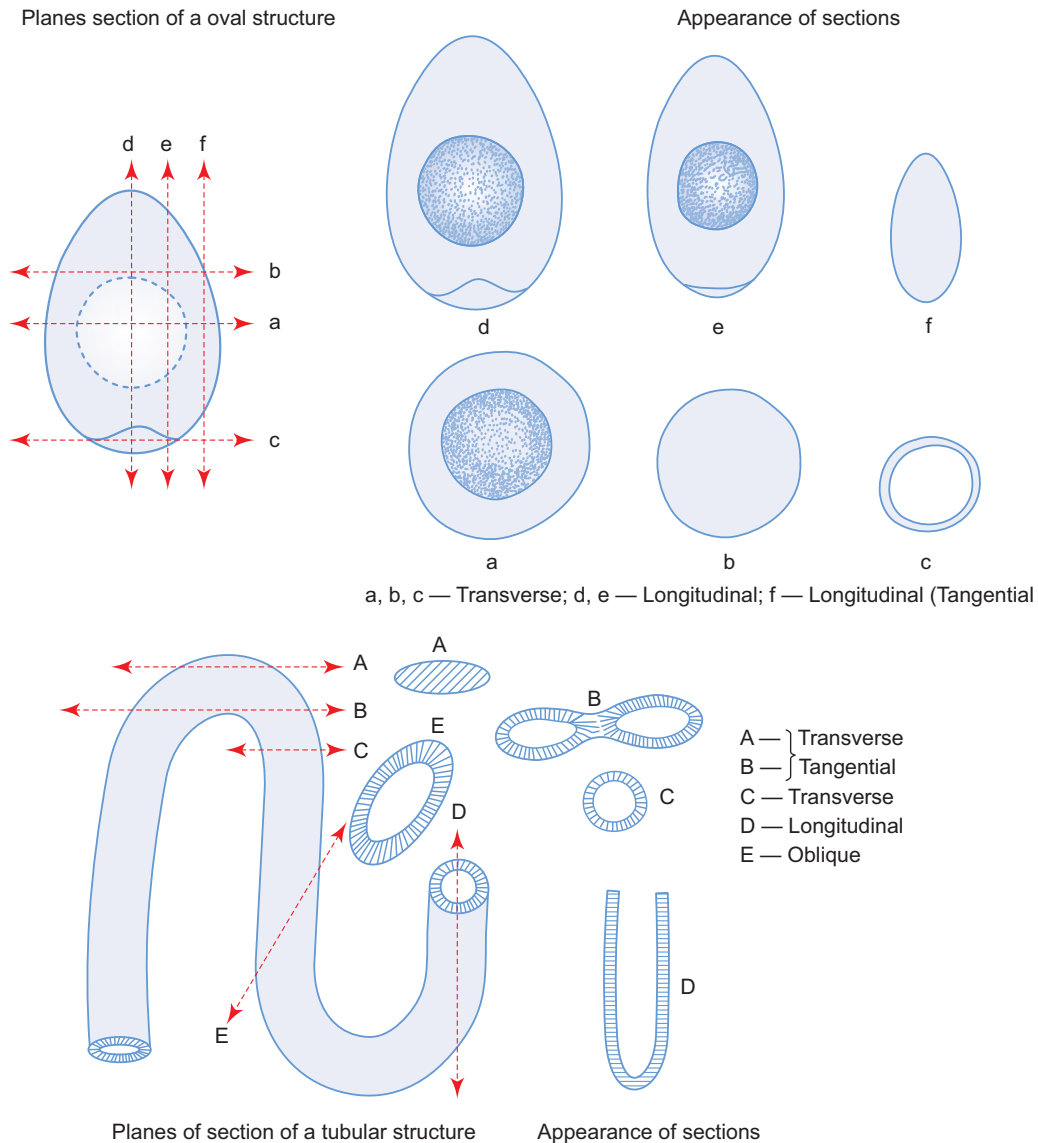
### Fixation and Fixatives

- Chemical substances like formalin, mercuric chloride, acetic acid, picric acid and glutaraldehyde are used as fixatives to preserve tissues.
- All fixatives have both desirable and undesirable effects.
- A combination of these fixatives is often prepared to get the maximum desirable effect. Such combinations commonly used are:
  1. Bouin's fluid (formalin, acetic acid and picric acid)
  2. Formal sublimate (formalin and mercuric chloride)
  3. Helly's fluid (formalin, mercuric chloride and potassium dichromate)
  4. Zenker's fluid (acetic acid, mercuric chloride and potassium dichromate)
- Small pieces of fresh tissues are placed in common fixatives like 10% neutral formal saline for 24 hours.
- The purpose of fixation is
  - to preserve the morphology and chemical composition of the tissue,
  - to prevent autolysis and putrefaction,
  - to harden the tissue for easy manipulation,
  - to solidify colloidal material, and
  - to influence staining.

After fixation, some hard tissues like bone and tooth, which contain large amount of calcium salts, require an additional step called **decalcification** before they are subjected for dehydration. Decalcification makes the hard tissues soft, enabling them to be cut with microtome. For decalcification, several decalcifying agents are used, namely 10% nitric acid, 5% trichloroacetic acid and ethylene diamine tetra acetic acid (EDTA).

### Dehydration

- Water from the tissues is removed in a gradual manner by immersing the tissues in ascending grades of alcohol, viz. 50%, 70%, 90% and absolute alcohol, in order to embed it in paraffin wax which is not miscible in water. Tissue remains in each of these grades for 30–60 minutes.



**Fig. 1.1** Appearance of sections of oval and tubular structures in various planes.

## Clearing

- After dehydration the tissue is treated with a paraffin solvent (clearing agent) like xylene or toluene for 2-3 hours. These agents penetrate and replace the alcohol from the tissue and make it translucent (clear).

## Embedding

- In order to obtain thin sections with microtome, tissue is infiltrated with embedding medium which gives a rigid consistency to the tissue.
- The various embedding media are paraffin wax, celloidin, gelatin, plastic resins (for EM), etc. Paraffin is the routinely used embedding medium for light microscopy.
- Embedding involves two steps, namely, impregnation and casting or block making.

### A. Impregnation

- After clearing, the tissue is impregnated with molten paraffin wax (at 58°–60 °C) in a hot air oven for 2 hours with three changes. The melting point of paraffin wax is 56 °C.

**B. Casting or block making**

- After impregnation, the tissue is placed in 'L' moulds containing molten paraffin. The molten wax cube with the tissue is allowed to cool and the paraffin block is then removed from the mould.

**Section Cutting (Microtomy)**

- 5–7 µm-thick sections are cut with a rotary microtome.
- The cut paraffin sections are affixed to albuminised glass microslides after flattening the sections over warm water.
- The microslides with sections are either air dried or dried in an incubator overnight at 37 °C and stored for staining at room temperature.

**STAINING PROCEDURE**

- Staining is done routinely by using a basic and an acidic dye that stain tissue components selectively.
- Tissue components that stain more readily with basic dyes are termed *basophilic* and are blue in colour and those with an affinity for acid dyes are termed *acidophilic* and are pink/orange in colour.
- The basic dyes are haematoxylin, toluidine blue and methylene blue. The acidic dyes are eosin, orange G and acid fuchsin.
- Of these dyes, the combination of haematoxylin and eosin (H&E) is most commonly used in histological staining procedure. However, special stains like periodic acid Schiff reagent (PAS), osmic acid, Mallory and Masson's, trichrome stains are being used to selectively identify certain tissue components.
- Haematoxylin usually stains the acid component (nucleus) of the cell, blue or black, whereas eosin stains the basic components present in the cytoplasm, pink.

**Deparaffinization**

- To remove the paraffin from the section, the slides are treated with xylol. Three changes are necessary, each for 3–5 minutes.

**Hydration**

- The slides are passed through the following series to hydrate the sections:
 

– Absolute alcohol	–	5 min (with 2 changes)
– 90% alcohol	–	3 min
– 70% alcohol	–	3 min
– 50% alcohol	–	3 min
[Wash in] Distilled water	–	3 min

**Staining**

- For differential staining (the commonly used technique), following steps are involved: A staining with **haematoxylin** for 5–7 minutes.
  - Washing well in running tap water until the section becomes blue.
  - Differentiation with 1% acid alcohol for 5 seconds.
  - Washing in running tap water again, until the section becomes blue.
  - Staining with 1% **eosin** for 1 minute.

**Dehydration**

- The stained sections are dehydrated in the following series:
 

– 50% alcohol	–	10 sec
– 70% alcohol	–	10 sec
– 90% alcohol	–	30 sec
– Absolute alcohol	–	5 min (with 2 changes)

## Clearing and Mounting

- The sections are cleared in xylene and mounted in DPX.

## MICROSCOPY

Once the paraffin sections are stained with haematoxylin and eosin (H&E) or with some special stains, it can be viewed through a light microscope. Its various parts and their functions are enumerated in Practical No. 1. Moreover, it is important that the student should have the basic knowledge of the principles of some special microscopes that are being used under certain condition.

### Basic Principles of Some Special Microscopes

#### Dark Ground (Dark Field) Microscope

Dark-ground microscope is a modified light microscope where the objects are examined by dark ground illumination. Dark ground illumination is obtained simply by inserting a small circle of black paper in the centre of the filter carrier of the condenser. The central rays which would normally pass through the object and into the objective are cut off and the peripheral rays from the condenser pass through the object, but do not enter the objective; the only light entering the objective will be that scattered (refracted) by the object, which makes the object bright and self-luminous against a dark background with a high degree contrast.

This microscope is used to examine extremely minute particles (colloid suspension) or large transparent objects (e.g. living protozoa, crystals, etc.) which are otherwise invisible with ordinary light microscope. This phenomenon is similar to the appearance of dust particles floating in a beam of sunlight in a dark room.

#### Phase-contrast Microscope

This microscope has been developed based on the fact that light passing through any transparent object mounted in a medium of a different refractive index slows down and changes its direction. Within the cell, different organelles exhibit different refractive indices and consequently alter the phase of the light that passes through them to different extents. These phase differences are transformed into differences of light intensity (by means of a special optical system) so that structures within the cells become visible in high contrast and with good resolution. So this microscope is being used to view any transparent living biological specimens. (There is no need to stain the specimen.)

#### Polarizing Microscope

Polarizing microscope is a modified light microscope with two *Polaroid filters*. The first filter is placed below the condenser and is called *polarizer* and the second filter is placed between the objective and the eyepiece and is called *analyser*. When both polarizer and analysers are kept with their main axes at right angle to one another, no light passes, resulting in a darkfield effect. However, when structures oriented in a linear (e.g. bones, muscle, collagen, nerve fibres) or radial fashion (e.g. lipid droplets, starch granules) are examined, they appear as bright structures against a dark background because they are able to rotate the direction of the vibration of polarized light. The capacity to rotate the direction of the vibration of the polarized light is called *birefringency* and is present in crystalline substances or biological materials containing oriented molecules.

#### Electron Microscopes

The basic principle behind the electron microscope is that it uses shorter wavelengths of electrons instead of light rays to achieve a very high resolution, as low as 3Å. This enables one to view fine structural details of cells and organelles. The electrons are deflected/scattered by a series of electromagnetic lens in a manner similar to light deflection by glass lens of optical microscope.

Electrons are produced by heating a metal filament (cathode) at high temperature (60–100 kv) in vacuum and are accelerated between the cathode and the anode forming a beam of electrons that passes through an aperture in the anode. This beam of electrons (primary or incidental electrons) is made to pass through the specimen (ultrathin section mounted on a copper mesh grid) by a *condenser coil* or *lens*. As it impinges upon the specimen, different types of electrons and electromagnetic waves are emitted/scattered as a result of various types of atoms present in the specimen (Fig. 1.2).



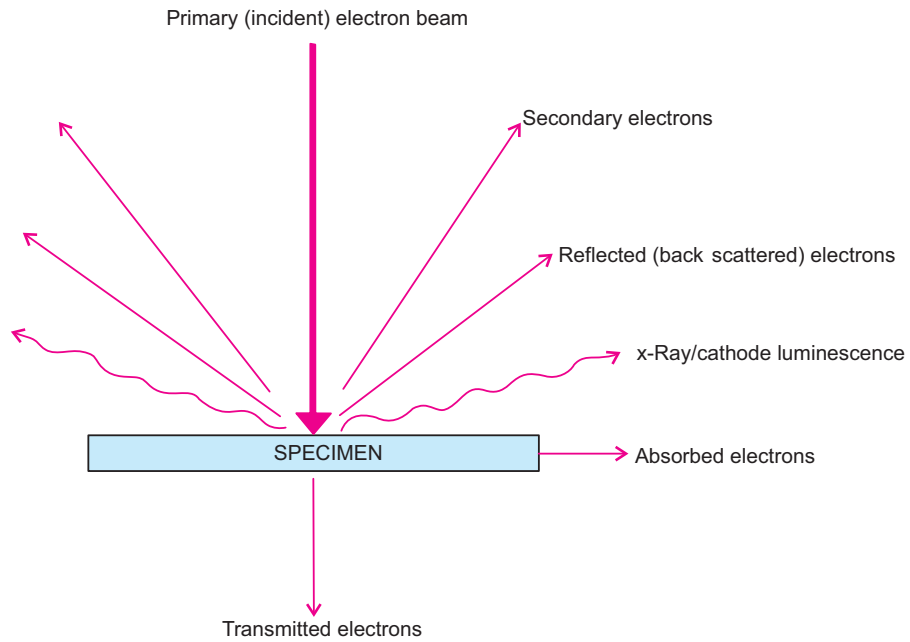


Fig. 1.2 Specimen – Electron interactions.

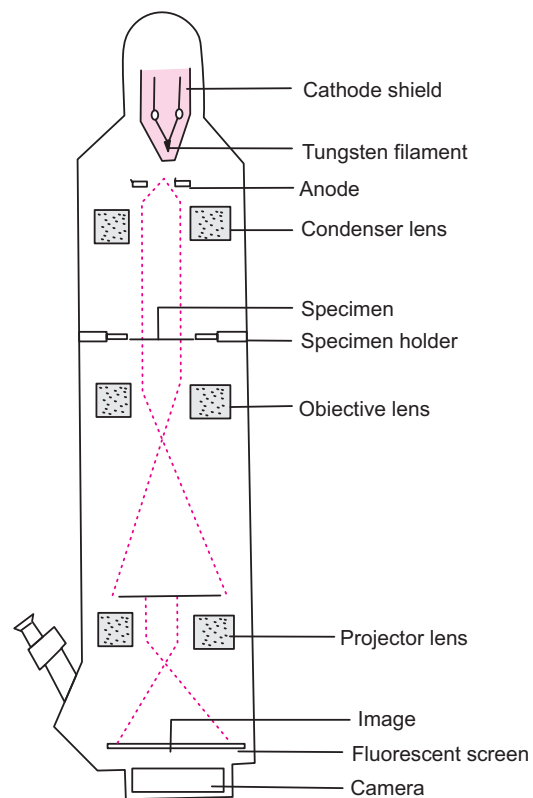


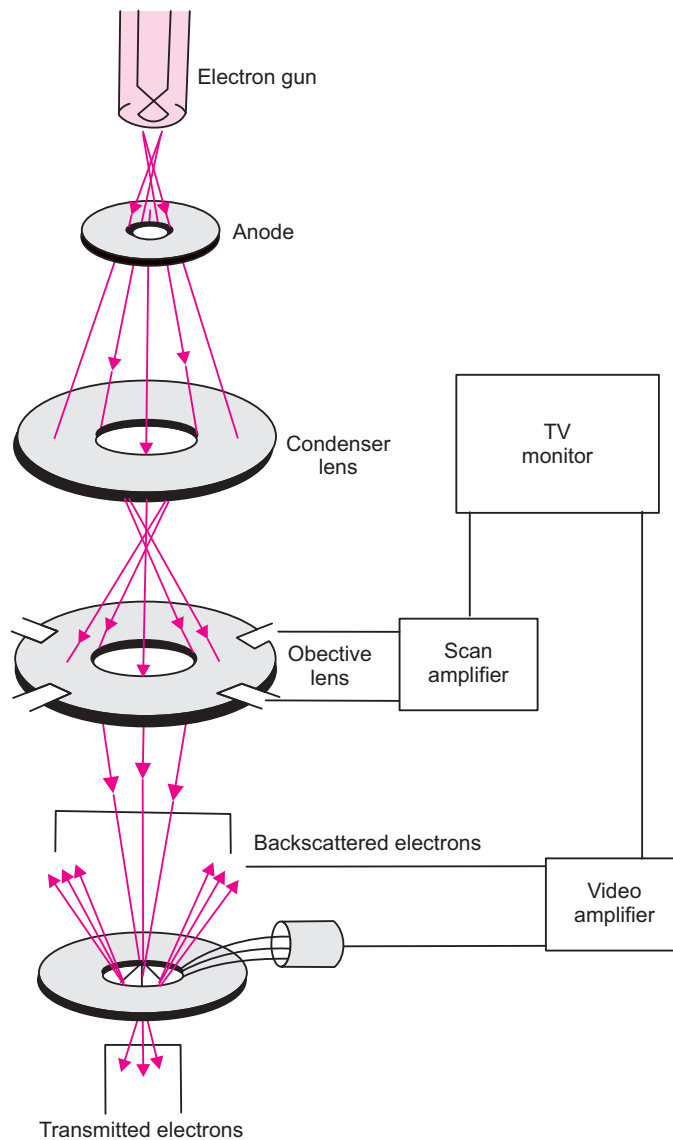
Fig. 1.3 Components and optical path of a transmission electron microscope.

### A. Transmission electron microscope (TEM)

Transmission electron microscope utilizes the transmitted electrons that penetrate the specimen and are produced due to scattering of incidental primary electrons. These transmitted electrons are focused by an *objective coil* or *lens*. The image obtained is further enlarged by one or two *projector coil* or *lens* and is finally projected on a fluorescent screen or photographic film to produce *electromicrograph*. This type of electron microscope is called transmission electron microscope (Fig. 1.3).

### B. Scanning electron microscopes (SEM)

In scanning electron microscope, the electrons do not pass through the specimen because of its thickness and because of a coating formed by heavy metals (e.g. gold). SEM differs from TEM basically in utilizing only the reflected (backscattered) and secondary electrons which are deflected back at varying angles as a result of interaction between the gold coated surface and the primary incident beam of electrons falling on it. These electrons are collected by special detectors that make electrical signals to a television tube which gives a 3-dimensional image of the specimen surface (Fig. 1.4). So SEM is an effective tool to study the surface topography of a specimen. This microscope has less resolution than TEM (i.e. about 200 Å).



**Fig. 1.4** Optical path in a scanning electron microscope.

# Self-assessment Exercise

## I. Write Short notes on:

- (a) Fixation and fixatives
- (b) Haematoxylin and eosin staining technique
- (c) Light microscopy

## II. Choose the best answer:

1. While processing the tissues for paraffin embedding, dehydration is done by immersing the tissue in
  - (a) alcohol only
  - (b) xylol only
  - (c) mixture of alcohol and xylol
  - (d) formalin
2. One micrometer ( $\mu\text{m}$ ) is equal to
  - (a) 0.001 mm
  - (b) 0.001 m
  - (c)  $10^{-9}$  m
  - (d)  $10^{-10}$  m
3. Haematoxylin is a basic dye and it stains
  - (a) the basic components of a cell only
  - (b) the acidic components of a cell only
  - (c) both basic and acidic components of a cell
  - (d) none of these
4. The optical part(s) of a light microscope involved in magnification is the
  - (a) condenser and filter
  - (b) eyepiece only
  - (c) objective only
  - (d) both objective and eyepiece

## III. State whether the following statements are true (T) or false (F):

1. Tissue is a collection of cells specialised to perform a specific function ( )
2. The purpose of fixing a tissue is to prevent autolysis and putrefaction ( )
3. Melting point of paraffin wax is  $80^\circ\text{C}$  ( )
4. Deparaffinization is done by treating the section with xylene ( )
5. While staining a section, the microslides are stained first with eosin ( )

## Answers

II. 1. a    2. a    3. b    4. d

III. 1. (T)    2. (T)    3. (F)    4. (T)    5. (F)

# Practical No. 1

## Light Microscope and Histological Technique

1. Identify the various parts of the light microscope (compound) (Plate 1:1), draw a labelled diagram of the microscope and elucidate functions of each part.

a. Mechanical parts and their functions

- (i) Base or foot – for stability
- (ii) Limb – to carry the body tube, stage, substage and mirror
- (iii) Body tube or draw tube – to hold eyepiece above and the objectives below
- (iv) Rotating nose piece – to hold the objectives
- (v) Coarse adjustment screw – for bringing the section into focus with low power objective
- (vi) Fine adjustment screw – for focusing the section with high power objective
- (vii) Stage (plane)/(mechanical) – to keep the microslide
- (viii) Substage – to carry the condenser
- (ix) Illuminating apparatus/mirror – to direct the light rays to the condenser

b. Optical parts (3 systems of lens) and their functions

- (i) Condenser – to converge the parallel light rays into focus on the plane of the section
- (ii) Objective – to magnify the section and project its image in the direction of the eyepiece
- (iii) Eyepiece – to magnify the image formed by the objective and to project it onto the viewer's retina.

*Total magnification = magnifying power of objective × eyepiece power*

2. Practice to focus a slide under low (L/P) and high power (H/P) objectives.

**Steps to focus a section:**

- Turn the low power objective (×10) in position and check that all optical systems are in the same straight line.

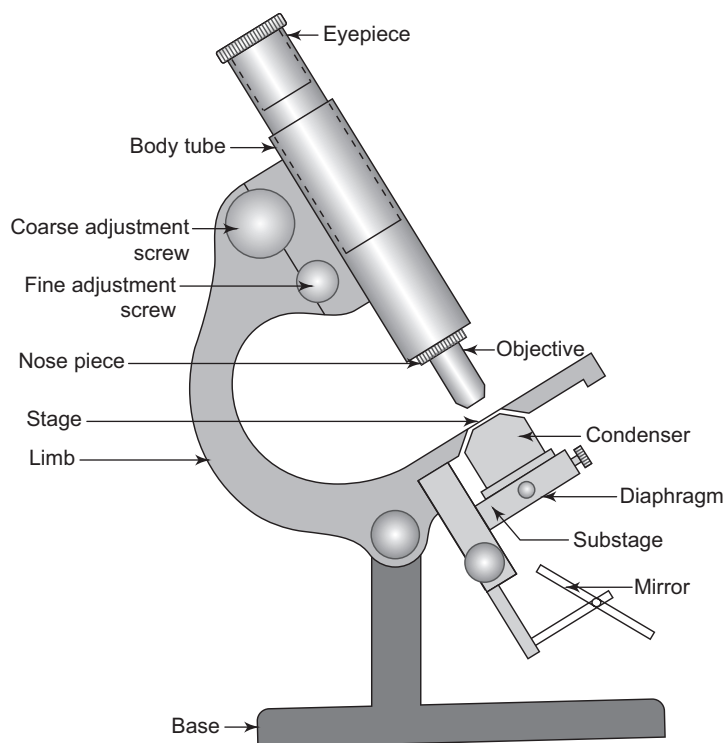
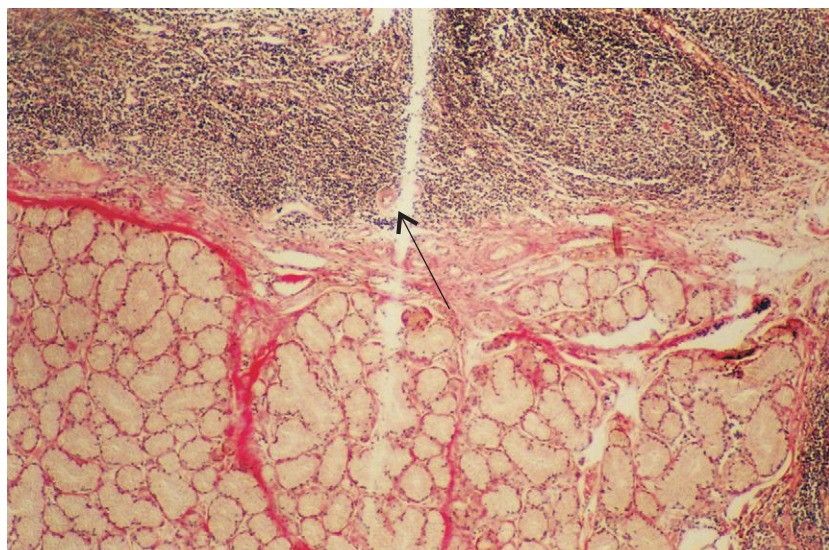


Plate 1:1

Schematic diagram of a light microscope.

- Illuminate the field with light by turning the mirror towards the light source (if the microscope has inbuilt light, switch on the power).
  - Clean the microslide with a dry cloth and identify the coverslip surface.
  - Keep the slide on the stage with the coverslip surface facing up. See that the section is in line with the optical system.
  - Slowly lower the body tube using coarse adjustment screw till the object is focused.
  - Now turn the fine adjustment screw either clockwise or anticlockwise till the object is sharply focused.
  - For viewing under high power, the condenser may be lifted up and the diaphragm aperture may be reduced. Now bring the feature of interest (to be magnified) in the section to the centre of the field and turn the nosepiece so that the high power objective ( $\times 40$ ) is in line with the light pathway (a click sound is heard when the objective is in correct position).
  - Use the fine adjustment screw for fine focusing. Never use the coarse adjustment screw while using high power, because the working distance between the slide and the objective is very little and the coverslip is likely to be broken unless care is taken (see Plate 1:4).
  - Repeat the exercise till you become familiar with focusing.
3. *Demonstration of various steps involved in processing tissues for light microscopy.*
  4. *Demonstration of "histological artifacts" (Plates 1:2–1:7). The artifacts are shown by arrows.*

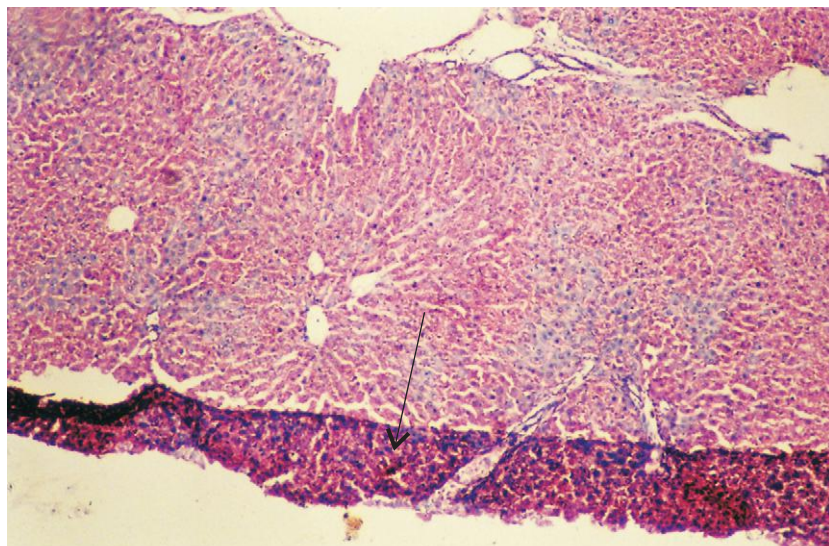
X40



**Plate 1:2** Linear tear in the section.

Due to nick in the microtome knife.

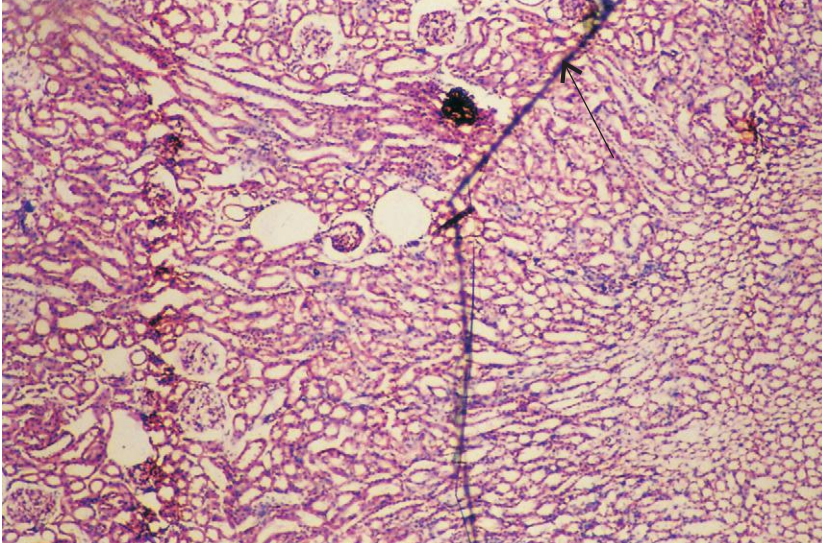
X40



**Plate 1:3** Folding in the section.

Due to improper spreading of section over hot water bath.

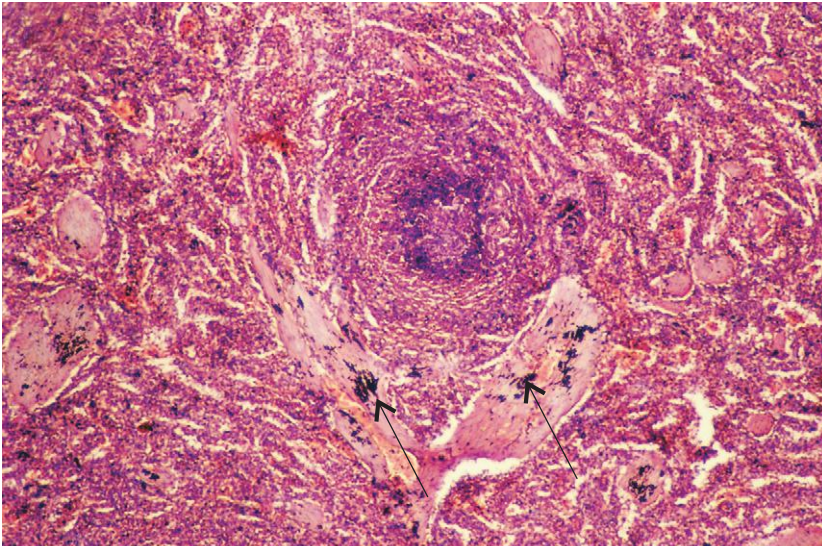
X40



**Plate 1:4** Crack in the coverslip.

Due to pressing of coverslip, usually with objective lens while focusing.

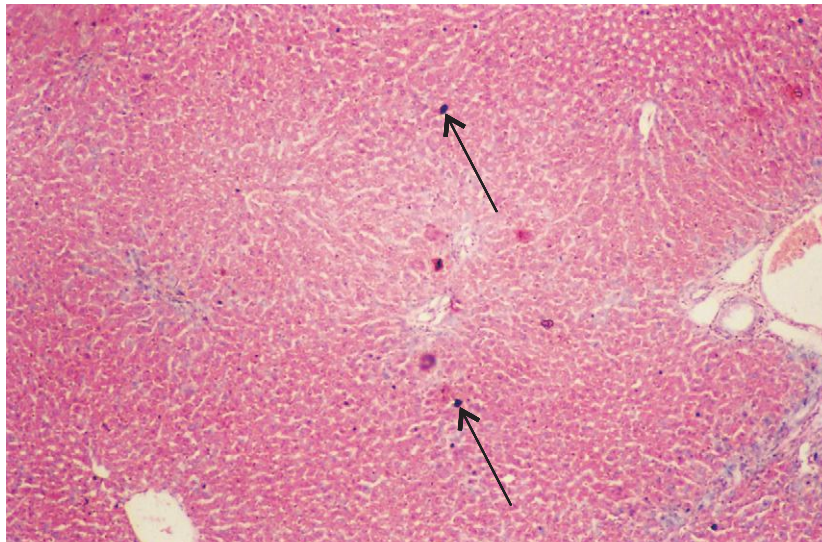
X40



**Plate 1:5** Stain particles.

Stain is not filtered before staining.

X40



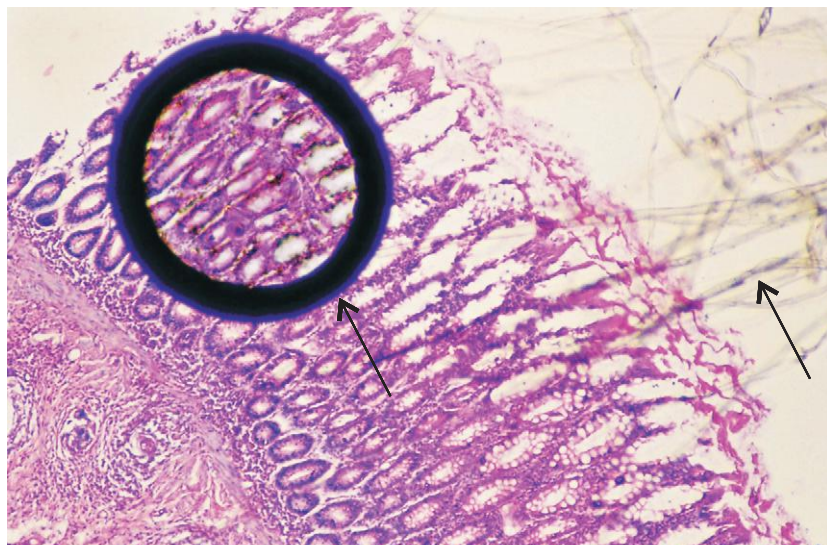
**Plate 1:6** Dust particles.

Microslide not cleaned properly.

X40

**Plate 1:7** Air bubble and cotton thread.

Due to defective mounting.



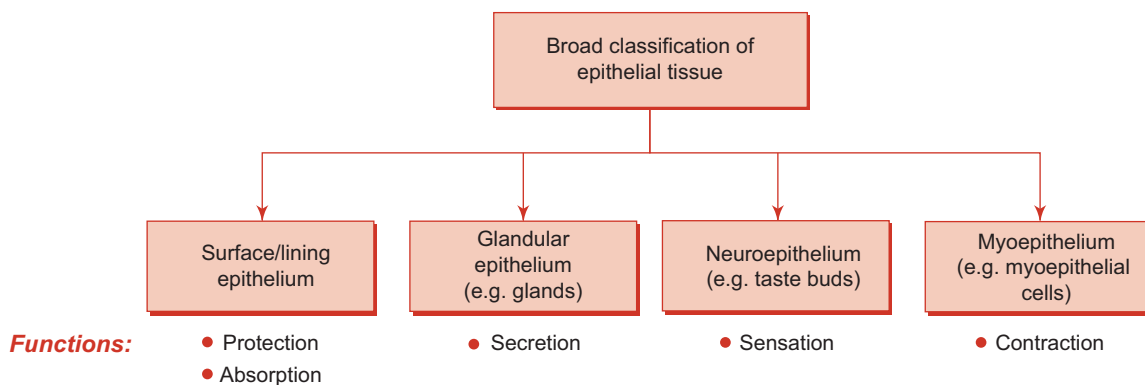
# 2

## EPITHELIAL TISSUE

Epithelium is a **sheet of cells** that covers the external surface of any solid structure and the internal surface of any hollow tubular (e.g. lumen/cavities) structure. Thus it serves as a **barrier membrane** separating the underlying tissue from various external and internal environments.

### CLASSIFICATION OF EPITHELIAL TISSUE

On the basis of the function(s) performed, epithelial tissue can be broadly classified into four types (see Flowchart 2.1).



**Flowchart 2.1** Classification and functions of epithelial tissue.

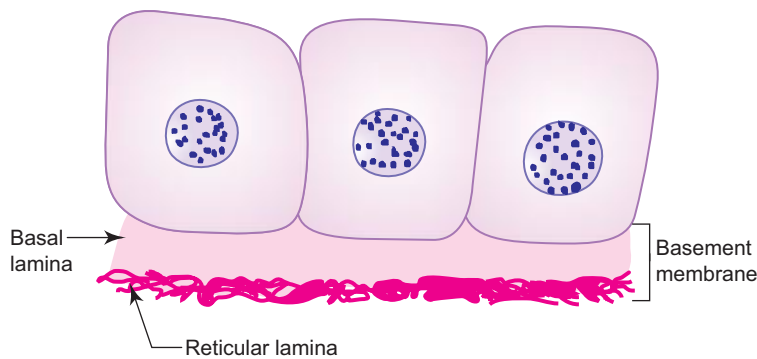
The present chapter will deal with surface or lining epithelium.

### SURFACE (OR) LINING EPITHELIUM

#### GENERAL FEATURES

- Epithelium, the ‘cellular sheet’, is made of either single layer or many layers of cells.
- Epithelial cells are adherent to each other by means of junctional complexes (*vide infra*).
- Very little intercellular material is found between the cells.
- The deep surface (basal) of the epithelium rests on a basement membrane, which separates it from the vascular connective tissue.
- Basement membrane (Fig. 2.1) is made up of
  - (a) *basal lamina* (amorphous substance) – product of epithelium
  - (b) *reticular lamina* (reticular fibres) – product of connective tissue.
- The superficial surface (apical) of the epithelium is free and exposed to air or fluid and often shows modifications (i.e. presence of microvilli or cilia) depending upon the function it is destined to perform.





**Fig. 2.1** Components of basement membrane.

- No blood vessels nor lymphatics are found in the epithelium; nourishment is provided by diffusion from the adjacent supporting tissues.
- Epithelium has good regenerative capacity.
- Its nuclear shape corresponds to cell shape (nuclei are oval in columnar cells, round in cuboidal and polyhedral cells, and flat in squamous cells).
- Epithelium invaginates/infolds and subsequently grows in the underlying connective tissue, thus specialising as glands.
- Epithelium may undergo morphological and functional changes from one type to another type (metaplasia).
- Functions: Protection, absorption, secretion, excretion, lubrication, sensation and reproduction.
- Epithelium is derived from all three germ layers (skin – ectoderm; respiratory and digestive systems – endoderm; cardiovascular system – mesoderm).

## INTERCELLULAR JUNCTIONS (JUNCTIONAL COMPLEXES)

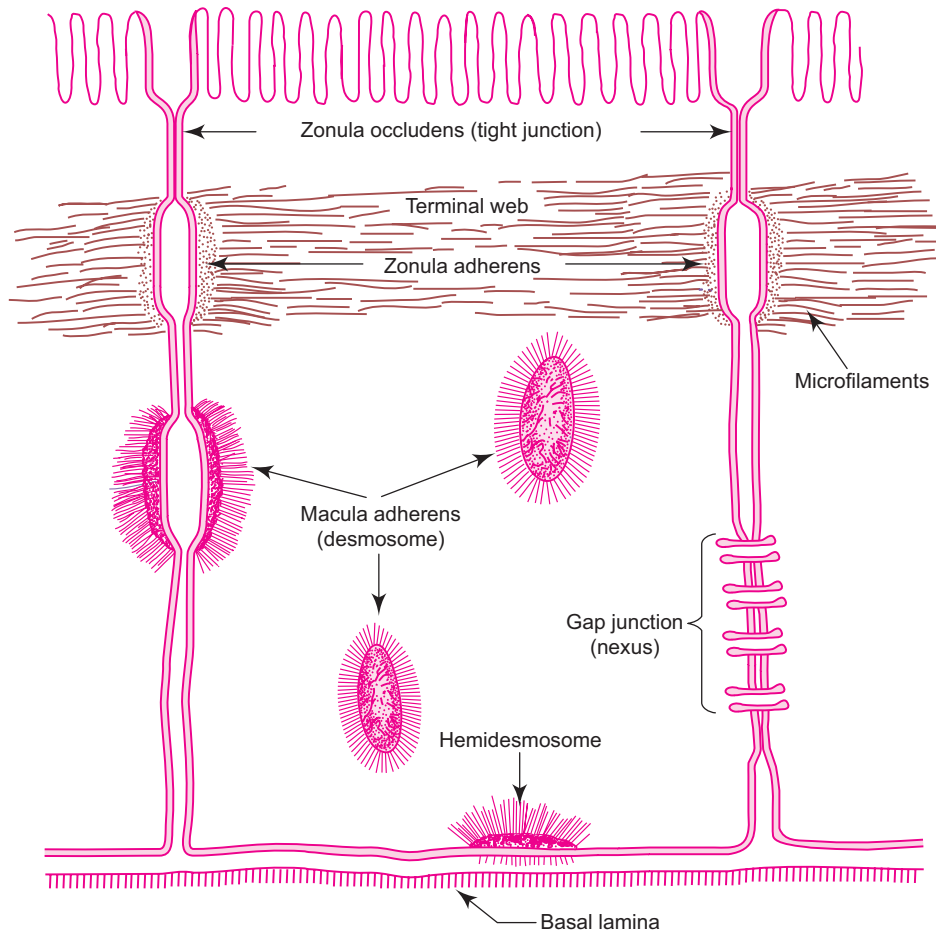
- Epithelial cells are adherent to one another by the binding action of the intercellular *cell adhesion molecules* (CAM) found in the interval between the plasma membranes of adjacent cells.
- The cell adhesion molecules are formed by glycoprotein and proteoglycan.
- The quality of intercellular adhesion is increased in those epithelial cells which are subjected to mechanical trauma (e.g. *skin*). Calcium ions are important in maintaining this cellular cohesion.
- In addition to this binding effect of CAM and ions, the plasma membrane of epithelial cells exhibit some specialisations that form intercellular junctions (junctional complexes). Following four junctional complexes are described below (Fig. 2.2):

### 1. Zonula occludens (tight junction)

- This junction is located near the apical part of the cell, where the outer surface of the plasma membrane of the cell fuses with that of the neighbouring cell, obliterating the intercellular space completely.
- It is in the form of a band or belt encircling the apical part of each cell.
- It serves as a barrier device giving a sealing effect to the epithelium, preventing passage of materials through the intercellular space from the lumen of the viscus (e.g. *intestine, urinary bladder*).

### 2. Zonula adherens

- This junction is present immediately below the zonula occludens and its opposing plasma membranes are separated by a gap, 20 nm wide.
- It also completely encircles the cell like zonula occludens.
- It is characterized by the presence of dense plaque-like material on the cytoplasmic surface of plasma membranes of the junction.
- Microfilaments (actin) are seen embedded in the dense plaque and are continuous with filaments of terminal web in the apical cytoplasm. It provides rigidity to the apex of the cell.



**Fig. 2.2** Intercellular junctions (junctional complexes).

### 3. Macula adherens (desmosome) and hemidesmosome

- Desmosomes are the third component of junctional complexes.
- They are scattered over the lateral surfaces of epithelial cells in the form of discs.
- The opposing plasma membranes are separated from each other by a gap of 30 nm and is bridged by transmembrane proteins. On the cytoplasmic side of the opposing membranes there is a prominent electron dense plaque (*attachment plaque*) giving attachment to intermediate filaments (some filaments may make hairpin bends and return to cytoplasm). This junction provides firm adhesion between cells, which are subjected to friction (e.g. *epidermis of skin*).
- Hemidesmosomes are half desmosomes found on the basal surface of the epithelial cell binding it to the subjacent basal lamina.

### 4. Gap junction (nexus)

- Gap junction is seen on the lateral surface of the epithelial cells, where adjacent plasma membranes are closely apposed.
- Each junction contains numerous transmembrane protein channels (*connections*) that permit the passage of inorganic ions and other small molecules from the cytoplasm of one cell to another. They are involved in exchange of chemical messengers in cell recognition and differentiation. They are also probably involved in passage of nutrients to cells which are farther away from nutritional source.

## SURFACE MODIFICATIONS OF EPITHELIAL CELLS

- Luminal surface of epithelial cells may be modified to perform specific functions, *viz.* glycocalyx, microvilli, stereocilia and cilia.
- The different modifications and the role played by them are enumerated in Table 2.1.

**Table 2.1** Surface modifications of epithelial cells

Surface modifications	Functions
1. Glycocalyx (cell coat/ fuzzy coat)	<ul style="list-style-type: none"> <li>Glycocalyx is a surface coat over the absorptive epithelium of small intestine. It is rich in polysaccharides and also contains proteins and hydrolytic enzymes</li> <li>Concentrates ions prior to absorption (intestine)</li> <li>Acts as receptor sites for hormones and enzymes</li> </ul>
2. Microvilli (brush border/ striated border)	<ul style="list-style-type: none"> <li>Microvilli are minute finger-like projections of the plasma membrane (see Table 2.2)</li> <li>Increase the surface area for absorption (intestine)</li> <li>Transport the absorbed material (by the microfilaments in the central core)</li> <li>Participate in the digestion of carbohydrates</li> </ul>
3. Stereocilia	<ul style="list-style-type: none"> <li>Stereocilia are very long, thick microvilli, nonmotile, may show branching</li> <li>Increase the surface area for absorption (epididymis)</li> <li>Help perception of stimuli (internal ear)</li> </ul>
4. Cilia	<ul style="list-style-type: none"> <li>Cilia are long hair-like projections of plasma membrane (see Table 2.2)</li> <li>Beat towards one direction, thereby moving the entangled particles from the surface (beat towards pharynx in respiratory tract and towards uterus in uterine tube)</li> </ul>

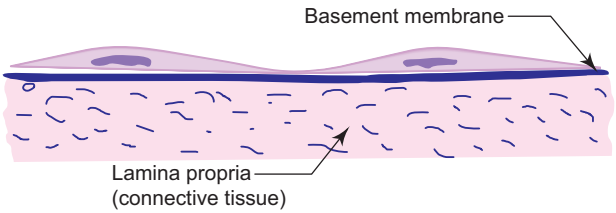
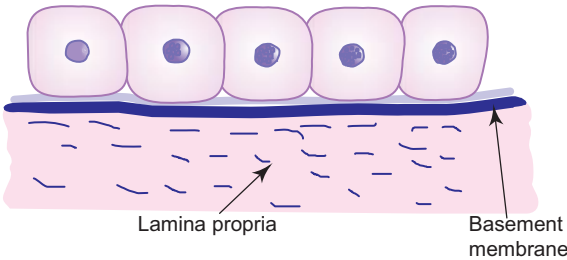
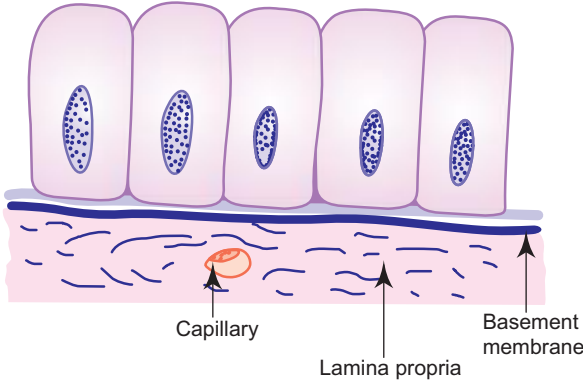
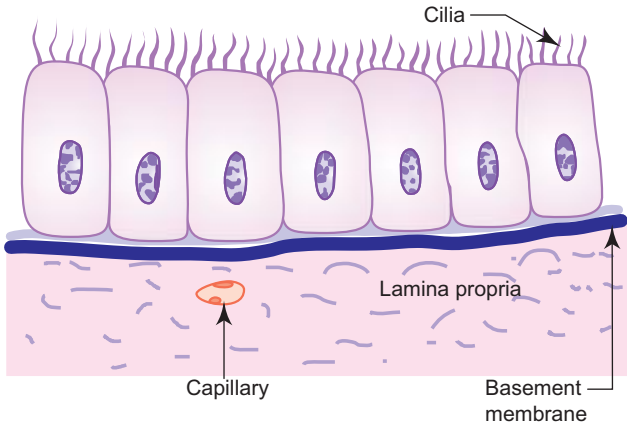
**Table 2.2** Differences between microvilli and cilia

	Microvilli	Cilia
<i>Diagram</i>		
	<b>Columnar Cell with Microvilli</b>	<b>Columnar Ciliated Cell</b>
<i>Length</i>	0.5–1.0 μm	5–10 μm
<i>Diameter</i>	0.1 μm	0.2 μm
<i>Motility</i>	Nonmotile	Motile
<i>Central core</i>	Contain microfilaments	9 + 2 Pattern of microtubules
<i>Functions</i>	Absorption	Driving the entangled particles: transport in one direction
<i>Example</i>	Intestinal epithelium, proximal convoluted tubules of the kidney	Respiratory tract, uterine tube, ependyma

## CLASSIFICATION OF LINING EPITHELIUM

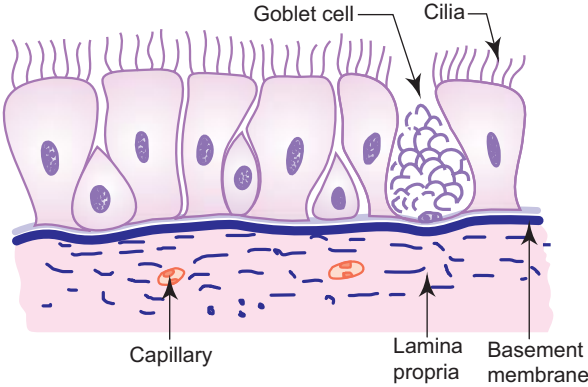
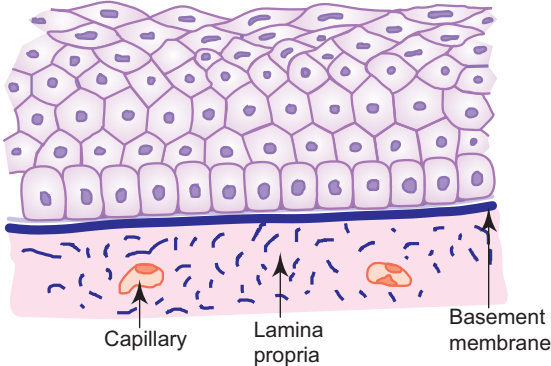
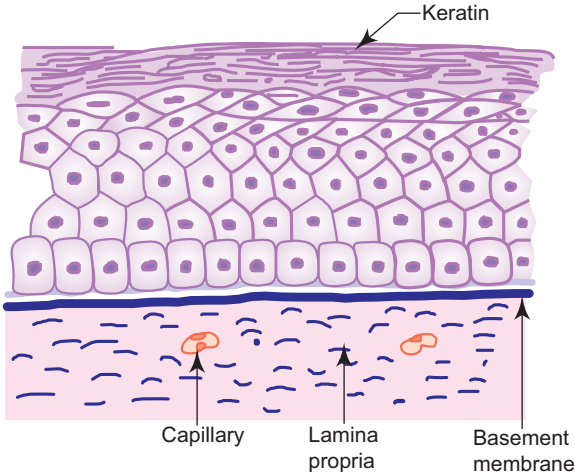
Epithelium is classified based on the number of cell layers and the shape of the cells on the free surface (Table 2.3). Characteristics of each type of epithelium are described in the practical section.

**Table 2.3** Classification of lining epithelium

Based on cell layer	Based on cell shape	Occurrence	Functions
<b>A. SIMPLE (S.)</b> One layer (Box 2.1, Box 2.2)	<b>S. Squamous</b> Cells are flat plates 	<ul style="list-style-type: none"> <li>• Endothelium (lining of blood vessels)</li> <li>• Mesothelium (lining of body cavities)</li> <li>• Lung alveolus</li> <li>• Parietal layer of Bowman's capsule</li> </ul>	<ul style="list-style-type: none"> <li>• Active transport by pinocytosis</li> </ul>
	<b>S. Cuboidal</b> Cells have same height and width 	<ul style="list-style-type: none"> <li>• Thyroid follicles</li> <li>• Kidney tubules</li> <li>• Pigmented layer of retina</li> <li>• Germinal layer of ovary</li> </ul>	<ul style="list-style-type: none"> <li>• Secretion</li> </ul>
	<b>S. Columnar (nonciliated)</b> Cells are tall, column-like 	<ul style="list-style-type: none"> <li>• Stomach</li> <li>• Intestine</li> <li>• Gall bladder</li> </ul>	<ul style="list-style-type: none"> <li>• Absorption</li> <li>• Secretion</li> </ul>
	<b>S. Columnar (ciliated)</b> Cells are tall, column-like and with cilia 	<ul style="list-style-type: none"> <li>• Uterine tube</li> </ul>	<ul style="list-style-type: none"> <li>• Transport</li> <li>• Secretion</li> </ul>

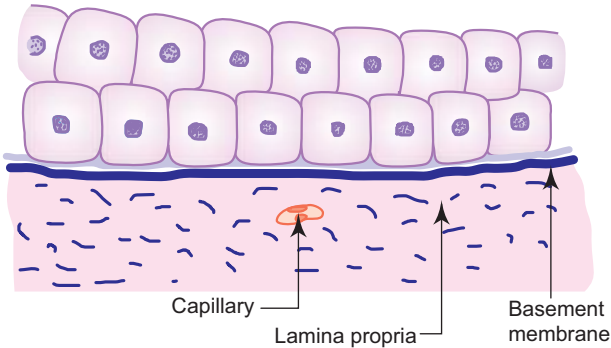
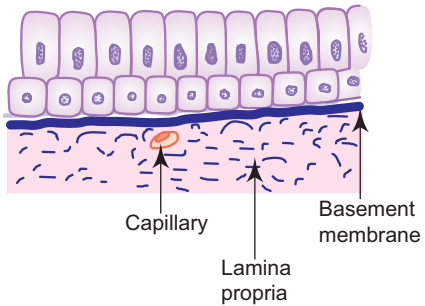
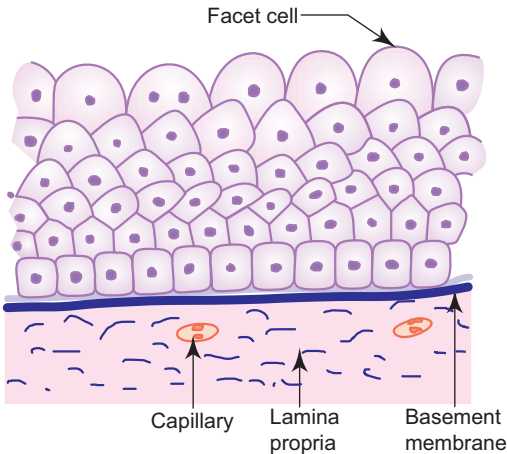
(Contd.)

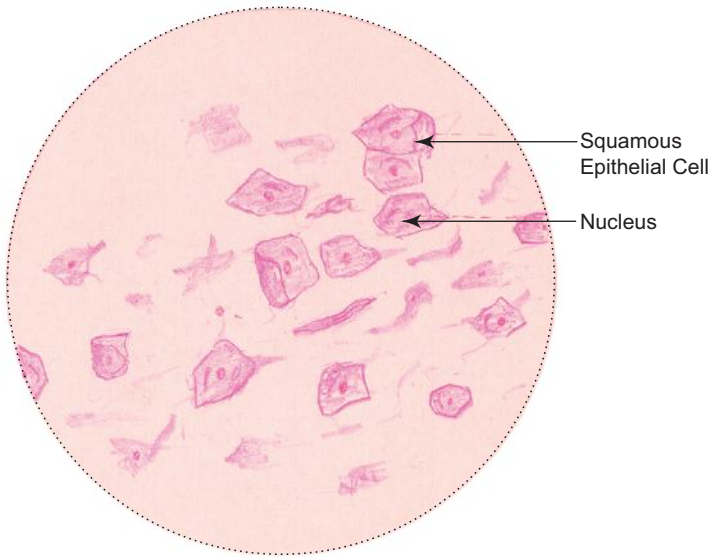
**Table 2.3** (Contd.)

Based on cell layer	Based on cell shape	Occurrence	Functions
<b>B. PSEUDO-STRATIFIED</b> <i>False stratification</i> (Box 2.3)	<b>Pseudostratified</b> <i>Columnar (ciliated)</i>	<ul style="list-style-type: none"> <li>• Nasal cavity</li> <li>• Trachea</li> <li>• Bronchi</li> </ul>	<ul style="list-style-type: none"> <li>• Transport</li> <li>• Protection</li> <li>• Secretion</li> </ul>
			
<b>C. STRATIFIED (Str.)</b> <i>More than one layer</i> (Box 2.4 to Box 2.6)	<b>Str. Squamous</b> <i>Nonkeratinized</i>	<ul style="list-style-type: none"> <li>• Mouth cavity</li> <li>• Oesophagus</li> <li>• Vagina</li> <li>• Anal canal</li> </ul>	<ul style="list-style-type: none"> <li>• Protection</li> </ul>
			
			

(Contd.)

**Table 2.3** (Contd.)

Based on cell layer	Based on cell shape	Occurrence	Functions
	<b>Str. Cuboidal</b>	<ul style="list-style-type: none"> <li>• Sweat ducts</li> </ul>	<ul style="list-style-type: none"> <li>• Protection</li> </ul>
	 <p>Capillary Lamina propria Basement membrane</p>		
	<b>Str. Columnar</b>	<ul style="list-style-type: none"> <li>• Palpebral conjunctiva</li> </ul>	<ul style="list-style-type: none"> <li>• Protection</li> </ul>
	 <p>Capillary Lamina propria Basement membrane</p>		
	<b>Transitional (urothelium)</b>	<ul style="list-style-type: none"> <li>• Ureter</li> <li>• Urinary bladder</li> </ul>	<ul style="list-style-type: none"> <li>• Protection</li> </ul>
	 <p>Facet cell Capillary Lamina propria Basement membrane</p>		

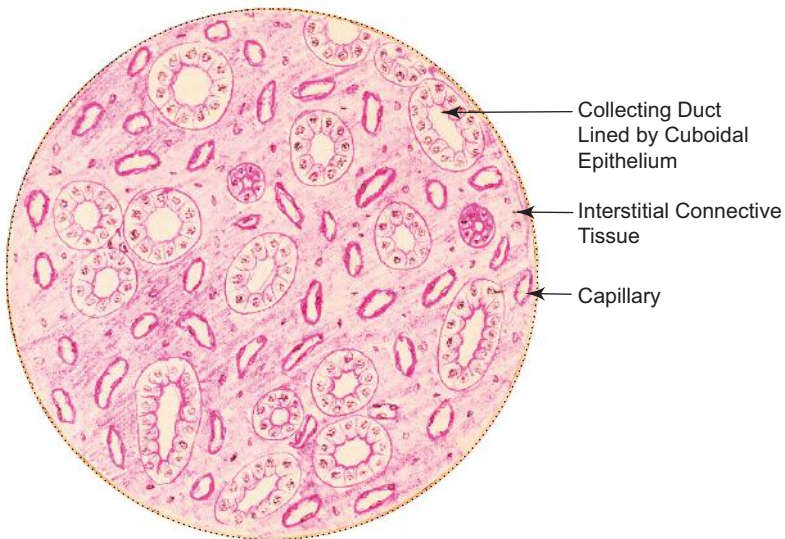


**Buccal smear**

**Box 2.1 Buccal Smear.**

*Presence of*

- (i) flat polygonal cells with centrally placed spherical nucleus.



**Cuboidal epithelium, e.g. collecting duct of kidney**

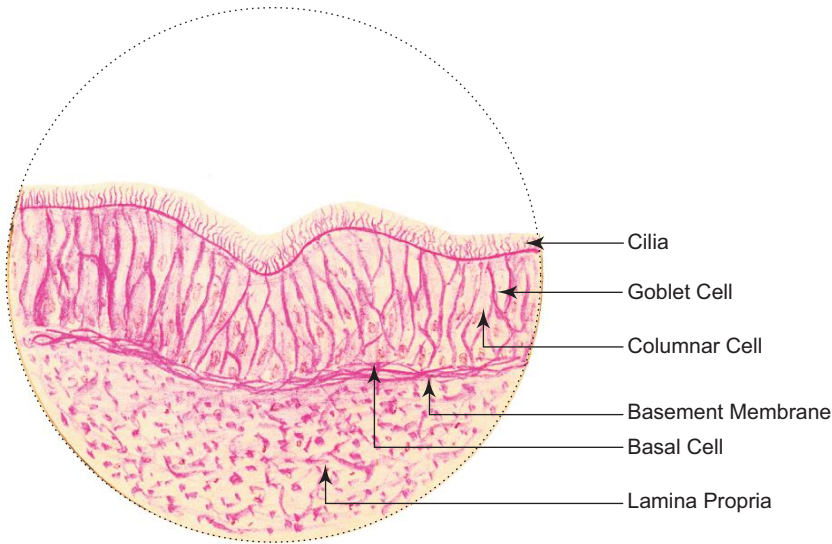
**Box 2.2 Cuboidal Epithelium.**

*Presence of*

- (i) cuboidal cells with centrally placed round nucleus.

Under certain conditions, one type of epithelium may change into another type. For example, in heavy smokers, the ciliated columnar epithelium lining the respiratory tract may transform into stratified squamous epithelium. This process is called **metaplasia**. Metaplasia is not restricted to epithelial tissue, it can occur in connective tissue as well.

*(Contd.)*

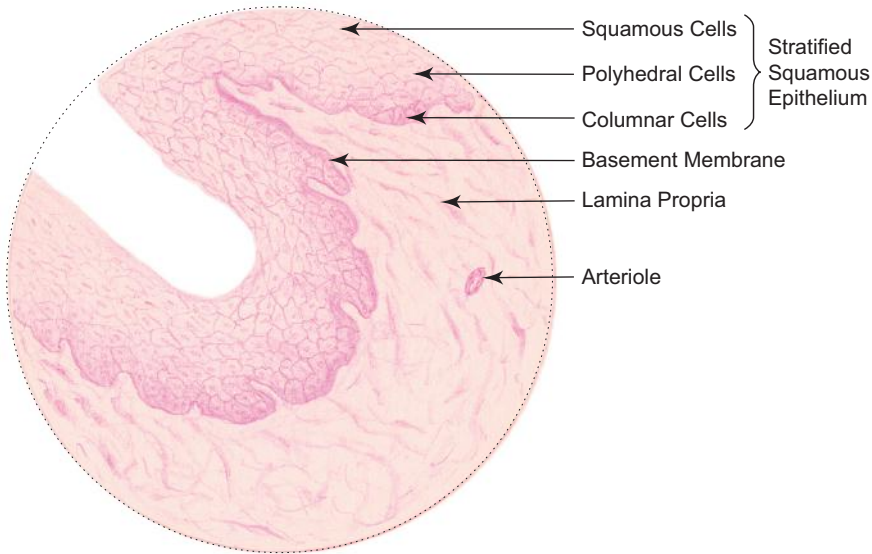


Pseudostratified ciliated columnar epithelium, e.g. *trachea*

**Box 2.3 Pseudostratified Ciliated Columnar Epithelium.**

*Presence of*

- (i) cells of different shapes and height lying on basement membrane;
- (ii) hair-like processes (cilia) on the free surface of the epithelium.



Stratified squamous epithelium, e.g. *oesophagus*

**Box 2.4 Stratified Squamous Epithelium.**

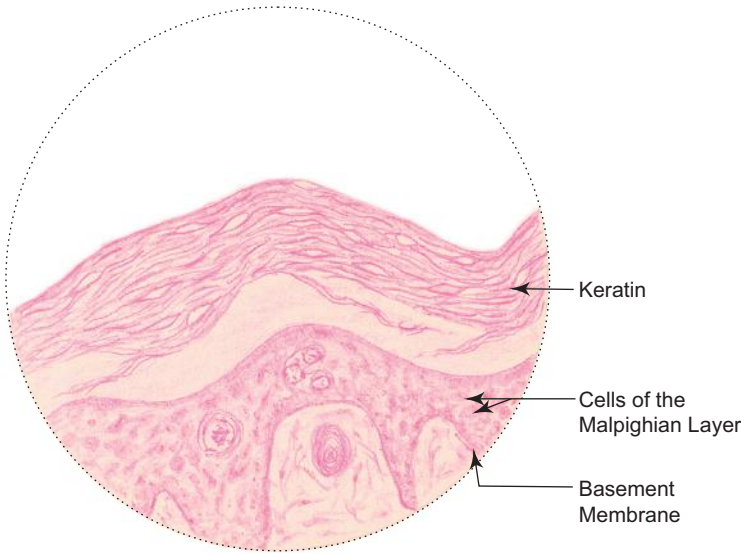
*Presence of*

- (i) many layers of cells;
- (ii) flat cells (squamous) with elliptical nuclei in the superficial layer.

(Contd.)

Epithelial tissue can give origin to both benign (**papilloma**) and malignant (**carcinoma**) tumours. Malignant tumour arising from epithelial tissue accounts for 90% cancers in adults.



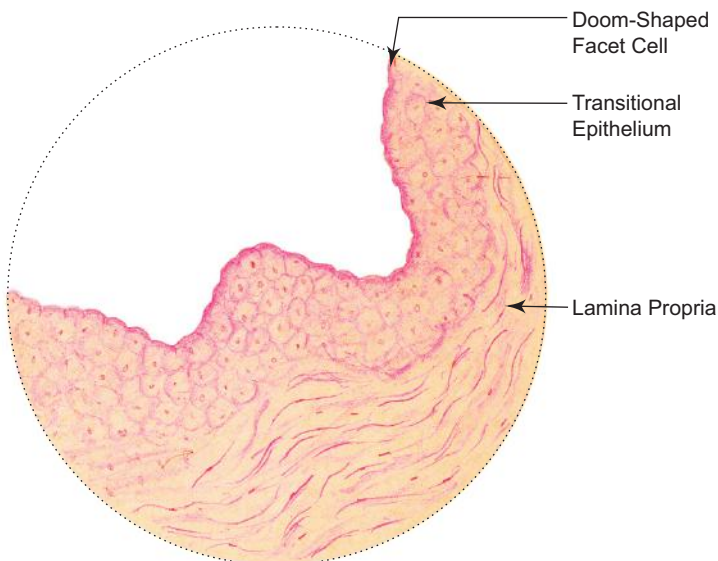


**Stratified squamous keratinized epithelium, e.g. epidermis**

**Box 2.5 Stratified Squamous Keratinized Epithelium.**

*Presence of*

- (i) many layers of cells;
- (ii) dead flat scaly cells in the superficial zone (stratum corneum).



**Transitional epithelium, e.g. urinary bladder**

**Box 2.6 Transitional Epithelium.**

*Presence of*

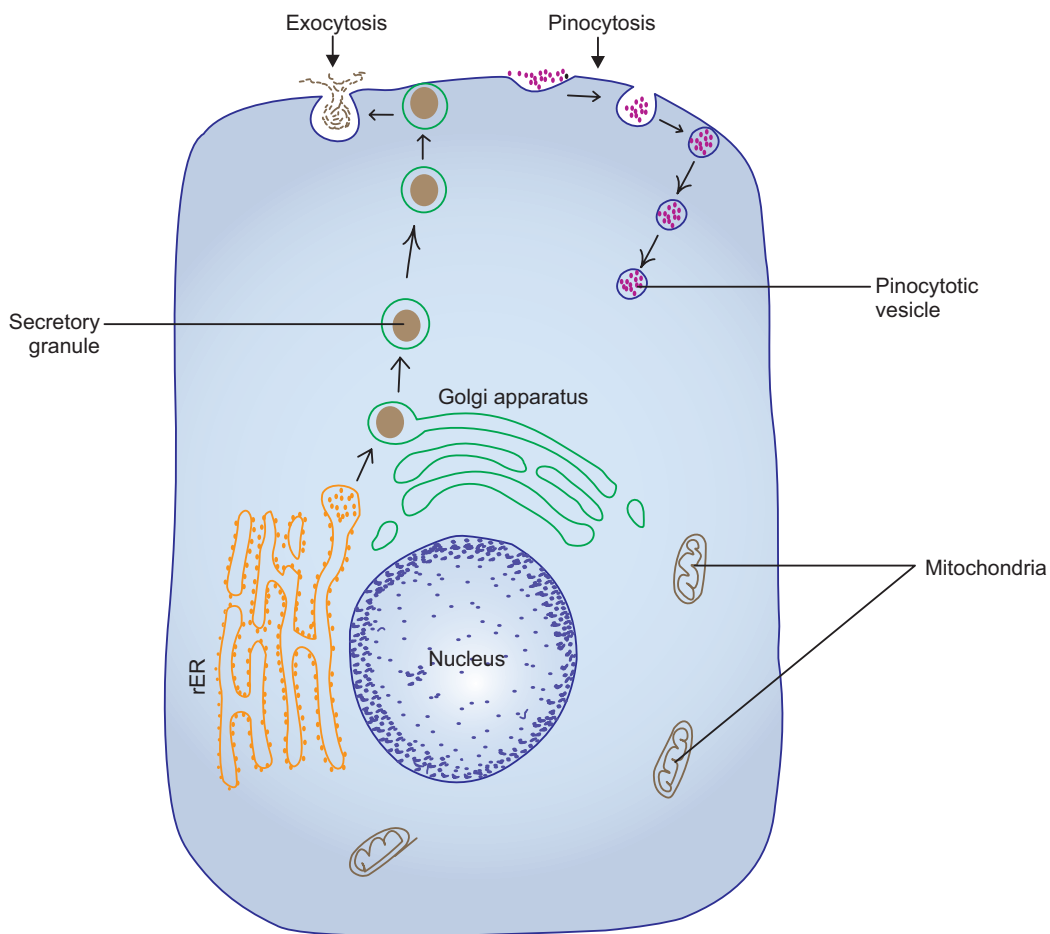
- (i) many layers of cells of varying shape;
- (ii) cells of superficial layer—are large and umbrella-shaped giving a scalloped margin to the luminal surface of the epithelium;
- (iii) cells of deeper layers—are small and so their nuclei are situated close to one another.

## SOME BIOLOGICAL PHENOMENA OF THE CELL

Cells are the functional building units of all living organisms. Mammalian cells exhibit a wide range of morphological and functional specializations to suit their external and internal environment. Study of the cell by means of electron microscope gives a lot of information about its ultrastructure and its organelles. With the use of modern techniques like electromicroscopy, autoradiography and immunohistochemical staining, the functional activities of the cells are better understood.

### Exocytosis

Exocytosis is the process by which synthesized molecules and other substances leave the cell. This process is associated with the fusion of vesicles containing synthesized materials with the plasma membrane and liberating their contents to the extracellular space, e.g. merocrine secretion of glands (Fig. 2.3). The membrane that is added to the plasma membrane by exocytosis is recovered into the cytoplasm by endocytosis and re-used by membrane bound organelles, as well as membrane lost or damaged during normal metabolic activities of the cell.



**Fig. 2.3** Exocytosis and pinocytosis.

### Endocytosis

Endocytosis is the process by which either small or large molecules enter the cell via vesicles formed from the plasma membrane. Both pinocytosis and phagocytosis fall under this category.

## Pinocytosis (Gr. Cell Drinking)

Pinocytosis is the process by which extracellular interstitial fluid and small protein molecules are taken into the cell via small vesicles which are pinched off from plasma membrane. These vesicles are less than 150 nm in diameter. Though pinocytosis is performed by virtually every cell, these vesicles are especially numerous in the endothelium of blood vessels and in smooth muscle cells.

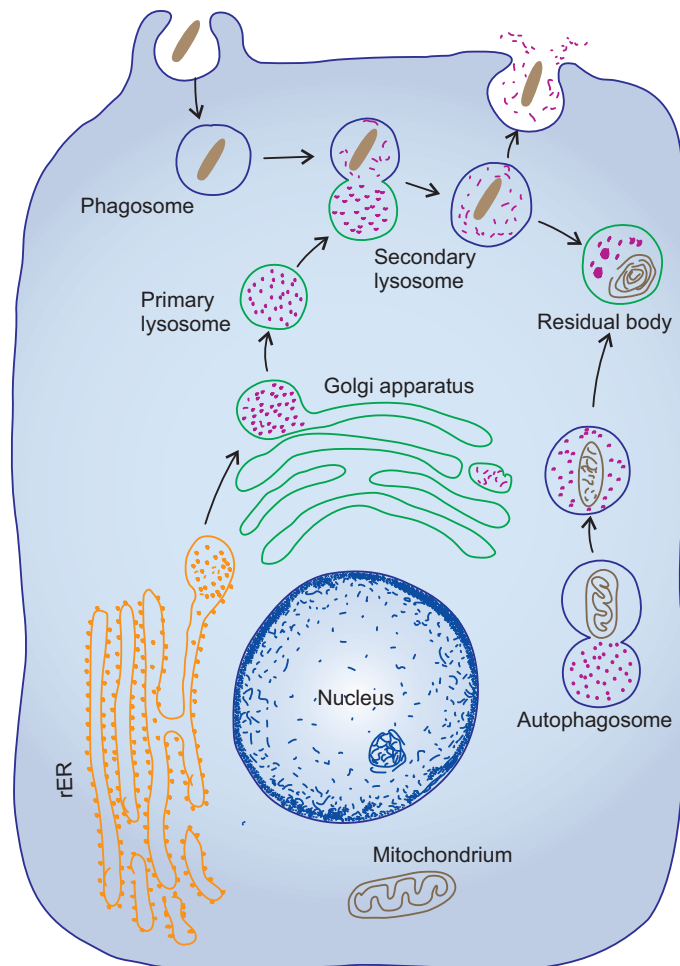
Substances to be pinocytosed first make contact with the extracellular surface of the plasma membrane, then the surface becomes indented and finally the invaginated portion pinches off from the membrane to become a pinocytotic vesicle within the cell (Fig. 2.3).

The capillary endothelium is involved in transporting nutrients and oxygen from the blood plasma through pinocytotic vesicles into the interstitial fluid. In the same way, interstitial fluid containing dissolved carbon dioxide is also taken up by pinocytosis for transportation across the endothelial cell wall in the opposite direction. It takes about 2–3 minutes for the pinocytotic vesicles to cross the wall.

## Phagocytosis (Gr. Cell Eating)

Phagocytosis is the process by which large particles such as cell debris, bacteria and other foreign materials are ingested into the cell through large vesicles called phagosomes. Phagocytosis is generally a receptor mediated process performed by a specialized group of cells belonging to the mononuclear phagocytic system.

During phagocytosis, phagocytic cells put forth cytoplasmic processes called pseudopodia that surround and engulf the foreign particle forming a *phagosome* or *endocytotic vesicle*. This vesicle detaches from the plasma membrane and is found free in the cytoplasm. The phagosome then fuses with the *primary lysosome* to form a *secondary lysosome* (Fig. 2.4). Lysosomal



**Fig. 2.4** Phagocytosis.

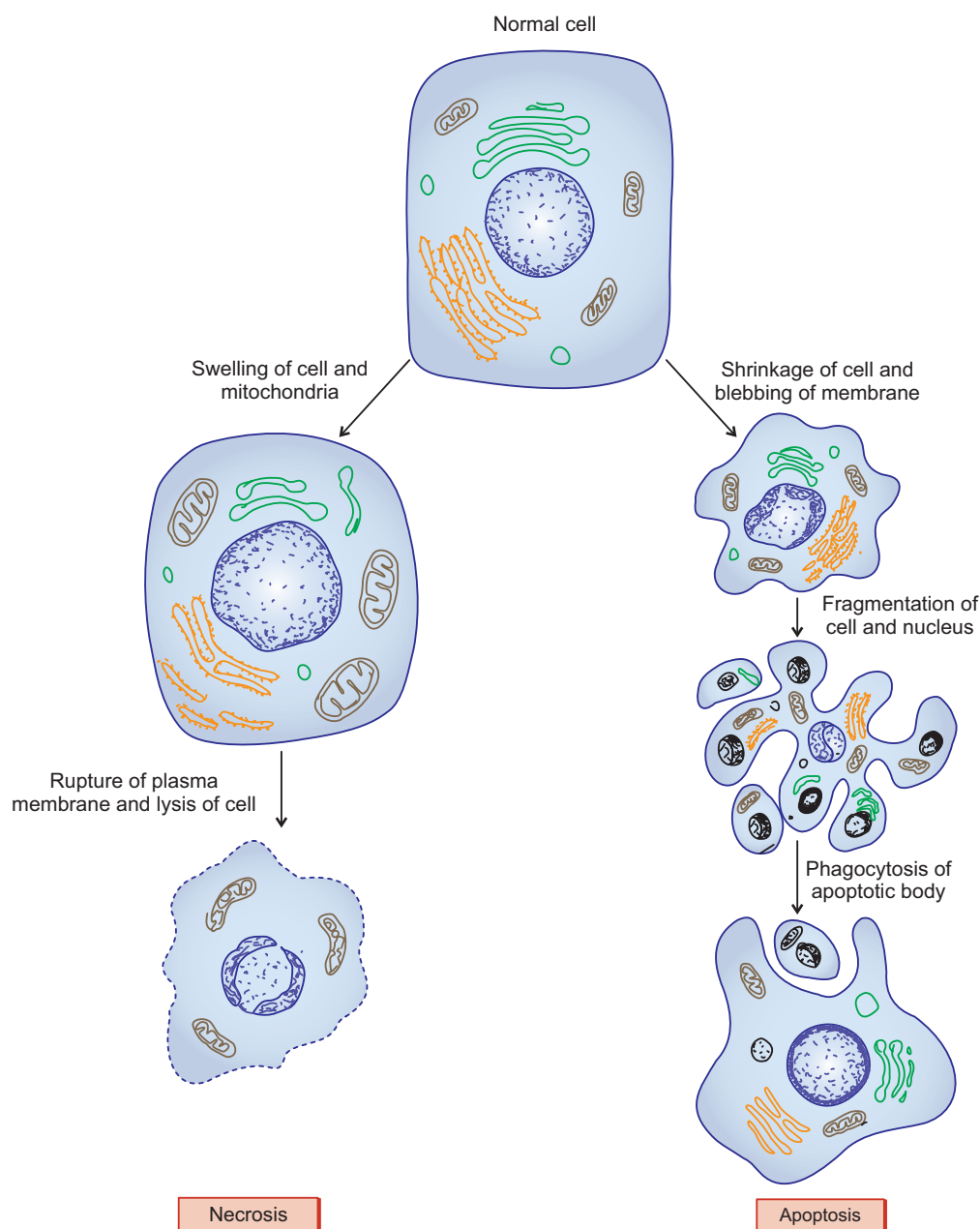
enzymes digest the engulfed material. When the digestion is complete, lysosomal membrane may rupture, discharging its contents into the cytoplasm. Undigested material may remain within the membrane-bound vesicles called *residual bodies*, the contents of which may be discharged at the cell surface by exocytosis or with advancing age they may accumulate in the cytoplasm and appear as brown *lipofuscin granules* (age pigments).

Lysosomes are also involved in digestion of aged or worn out organelles, a process known as *autophagy* (Fig. 2.4). The products of degradation are re-utilised by the cell for metabolic processes.

## Cell Death

### Necrosis

Death of the cells due to tissue injury is called necrosis. Necrotic cells swell and subsequently rupture resulting in formation of cell debris. This induces an inflammatory response at the site of injury.



**Fig. 2.5** Necrosis and apoptosis.

## Apoptosis (Programmed Cell Death/Regulated Cell Suicide)

Cell division and differentiation are balanced by cell death during growth and development of the organism. Apoptosis is a central mechanism controlling multicellular development in regulating the number of cells that mediate a particular activity (e.g. separation of the developing digits during morphogenesis). It also ensures that inappropriate or insufficient cells are eliminated.

The morphological changes exhibited by apoptotic cells are very different from those seen in necrotic cells (Fig. 2.5):

- Apoptotic cells shrink.
- Their plasma membranes undergo blebbing without any loss (i.e. they are intact).
- Their nuclei and chromosomes fragment, forming apoptotic bodies.
- Since the plasma membrane is intact, their intracellular contents are not released into the extracellular environment, so the inflammatory reactions are avoided.

## Cell Cycle

A single fertilized egg (zygote) divides repeatedly by mitosis to form a collection of daughter cells (morula) and these cells are progressively specialized for a variety of functions to produce the terminally differentiated cells of mature tissue (e.g. muscular tissue). However, most tissues retain a small population of relatively undifferentiated cells (*stem cells*) that are capable of undergoing mitotic division as and when required.

According to the mitotic activity displayed by the cells, human adult cells can be divided into three categories, *viz.* static or terminally differentiated cells, facultative divider cells and continually renewing cells. The static or *terminally differentiated cells* do not undergo mitosis (e.g. neurons). They leave the cell cycle after mitotic phase and enter into a quiescent phase, *G<sub>0</sub> phase*. In contrast, *facultative divider cells* enter the *G<sub>0</sub> phase* but retain the capacity to re-enter the cycle when suitably stimulated (e.g. liver cells). The last variety, *continually renewing cells*, display regular mitotic activity throughout the life span (e.g. epithelial cells of various tracts, cells of epidermis, etc.).

The interval between two successive mitotic divisions is known as *cell cycle*. The cell cycle is divided into two principal phases—a short mitotic phase, *M phase* and a long nondividing *interphase*. The interphase is further divided into *G<sub>1</sub>*, *S* and *G<sub>2</sub>* phases. The length of these phases is variable. In general, the time taken for *S*, *G<sub>2</sub>* and *M* is relatively constant and they are 6–8; 2–4 and 1–2 hours, respectively. In contrast, the duration of *G<sub>1</sub>* shows considerable variation ranging from 2 hours to several days.

**M**—mitosis consisting of prophase, metaphase, anaphase and telophase.

**G<sub>1</sub> (First gap phase)**—is longer than the other phases of the cell cycle.

It is period when cells respond to growth factor by generating molecular machinery necessary for another cycle (once the cycle is initiated it cannot be reversed).

**S (synthesis phase)**—period of DNA synthesis (replication of the genome).

**G<sub>2</sub> (second gap phase)**—is relatively short phase. In this the cell prepares for mitotic division.

# Self-assessment Exercise

## I. Write short notes on:

- (a) Classification of lining epithelium
- (b) Transitional epithelium
- (c) Surface modifications of epithelial cells
- (d) Microvilli and cilia, highlighting their differences

## II. Fill in the blanks:

1. The morphological and functional changes in epithelium from one type to another type is called \_\_\_\_\_
2. The simple squamous epithelial lining of cardiovascular system is called \_\_\_\_\_
3. The simple squamous epithelial lining of serous membrane and synovial membrane is called \_\_\_\_\_
4. The basement membrane of an epithelium is made up of two layers, namely, \_\_\_\_\_ and \_\_\_\_\_

## III. Choose the best answer:

1. 9+2 pattern of microtubules (axoneme) is present in
  - (a) glycocalyx
  - (b) microvilli
  - (c) stereocilia
  - (d) cilia
2. Transitional epithelium is found in
  - (a) uterus
  - (b) urinary bladder
  - (c) gallbladder
  - (d) vagina
3. In pseudostratified columnar epithelium
  - (a) all cells are attached to basement membrane
  - (b) all cells do not reach the surface
  - (c) the nuclei are situated at different levels
  - (d) all of the above are correct
4. Stomach is lined by
  - (a) simple columnar epithelium
  - (b) stratified squamous epithelium
  - (c) pseudostratified columnar epithelium
  - (d) simple cuboidal epithelium
5. Glycocalyx present in the absorptive epithelium of small intestine
  - (a) increases the surface area for absorption
  - (b) transports the absorbed material
  - (c) concentrates ions prior to absorption
  - (d) participates in the digestion of carbohydrates

**IV. State whether the following statements are true (T) or false (F):**

1. Epithelium serves as a barrier membrane separating the organism from external and internal environments ( )
2. Microvilli are present in cells which are involved in absorption ( )
3. Cilia contain microfilaments in the central core ( )
4. Stereocilia are motile structures and beat towards one direction ( )
5. The shape of the epithelial cell can be identified based on the shape of its nucleus ( )

**V. Match the items of column 'A' with those of column 'B':**

Column 'A'		Column 'B'
A. <i>Epithelium</i>		<i>Function</i>
1. Surface	( )	(a) Secretion
2. Glandular	( )	(b) Sensation
3. Neuro	( )	(c) Contraction
4. Myo	( )	(d) Protection
B. <i>Surface modification</i>		<i>Occurrence</i>
1. Microvilli	( )	(a) Sperm
2. Stereocilia	( )	(b) Respiratory epithelium
3. Cilia	( )	(c) Intestinal epithelium
4. Flagellum	( )	(d) Epididymis
C. <i>Epithelium</i>		<i>Example</i>
1. Simple squamous	( )	(a) Epidermis
2. Simple cuboidal	( )	(b) Oesophagus
3. Simple ciliated columnar	( )	(c) Trachea
4. Pseudostratified ciliated columnar	( )	(d) Thyroid follicle
5. Stratified squamous nonkeratinized	( )	(e) Uterine tube
6. Stratified squamous keratinized	( )	(f) Lung alveolus

**Answers**

**II.** 1. Metaplasia    2. Endothelium    3. Mesothelium    4. Basal lamina and reticular lamina

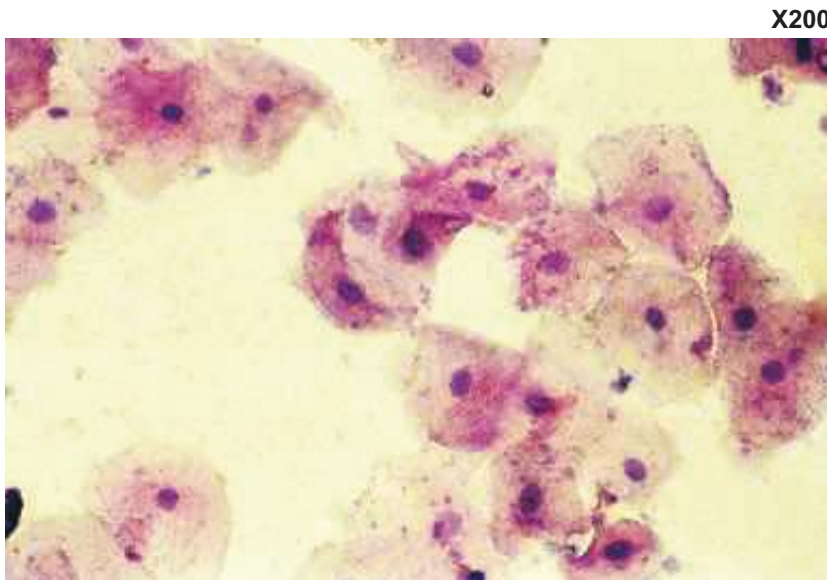
**III.** 1. d    2. b    3. d    4. a    5. c

**IV.** 1. (T)    2. (T)    3. (F)    4. (F)    5. (T)

**V.** A. 1. d    2. a    3. b    4. c  
 B. 1. c    2. d    3. b    4. a  
 C. 1. f    2. d    3. e    4. c    5. b    6. a

# Practical No. 2.I

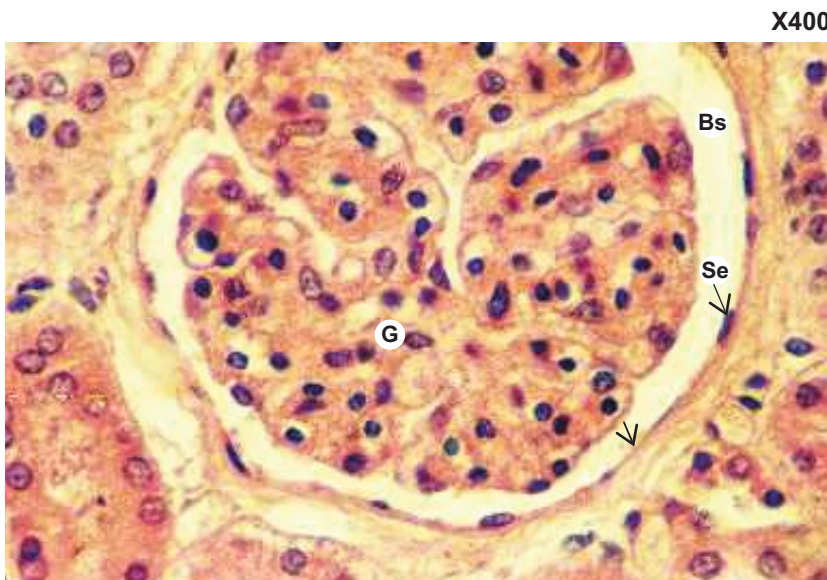
## Epithelial Tissue I: Simple Epithelium



**Plate 2.I:1** Surface view of the squamous cells (e.g. buccal smear).

Note the following features:

- Flat, polygonal shape of the cells.
- Round, centrally placed nucleus.



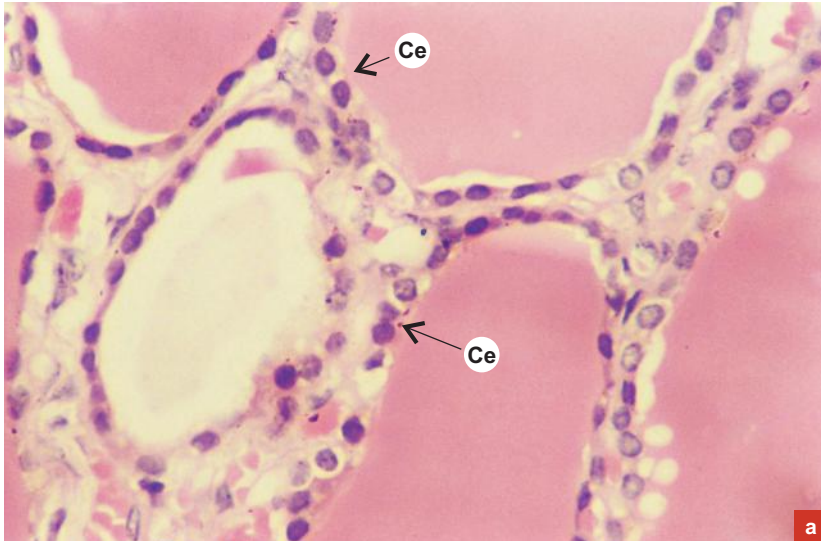
**Plate 2.I:2** Simple squamous epithelium: profile view (e.g. parietal layer of Bowman's capsule of renal corpuscle).

Examine a section of the cortex of kidney and note the following features:

- Under low power (L/P; refer to chapter 13) identify a renal corpuscle, which appears as a large rounded structure.
- Each corpuscle is made up of a central darkly stained tuft of capillaries (glomerulus [G]) surrounded by a space (urinary/Bowman's space [Bs]), which is limited externally by parietal layer of Bowman's capsule (arrow-head).
- Examine the parietal layer of Bowman's capsule at magnification  $\times 400$  to see the simple squamous epithelial lining (Se).
- Though the epithelial cells are spindle-shaped, their outlines cannot be seen distinctly. However, their shape may be ascertained by the dark **flattened nuclei** and scanty cytoplasm.



X400



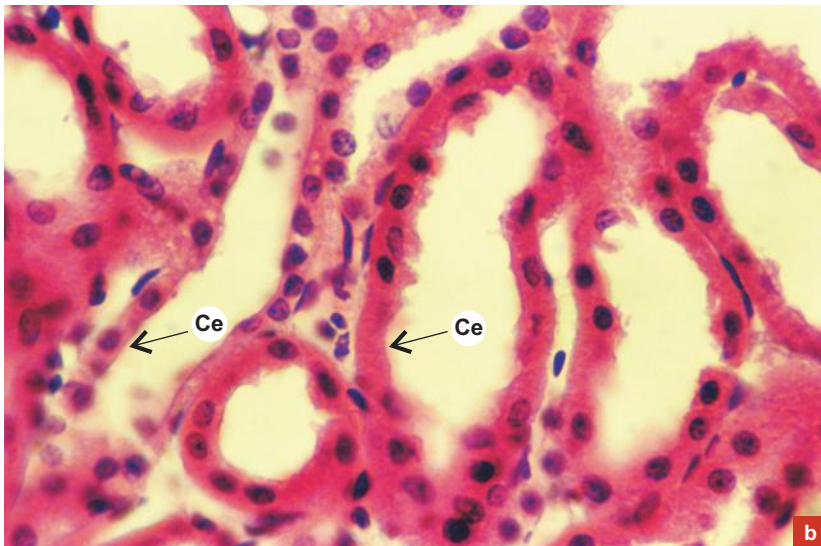
a

**Plate 2.I:3** Simple cuboidal epithelium (e.g. thyroid follicles and kidney tubules).

Examine the slides of thyroid gland/kidney cortex under L/P (refer to chapters 13 and 17) to see the general topography.

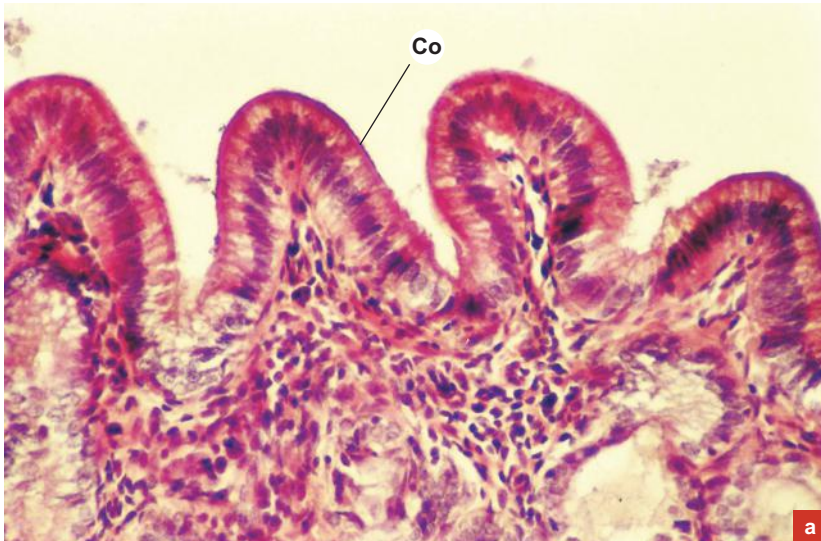
- Identify the thyroid follicles (Plate 2.I:3a)/ renal tubules (Plate 2.I:3b) of varying sizes, shapes and staining intensity.
- Examine them at magnification  $\times 400$  to see the lining epithelium, which is of simple cuboidal variety (Ce).
- Due to poor preservation, the outline of cuboidal cells are often not visible. However, the cuboidal shape of the cells can be ascertained by the **round nuclei** of the cells seen as a ring of nuclei around the lumen of the follicle/tubule.

X400

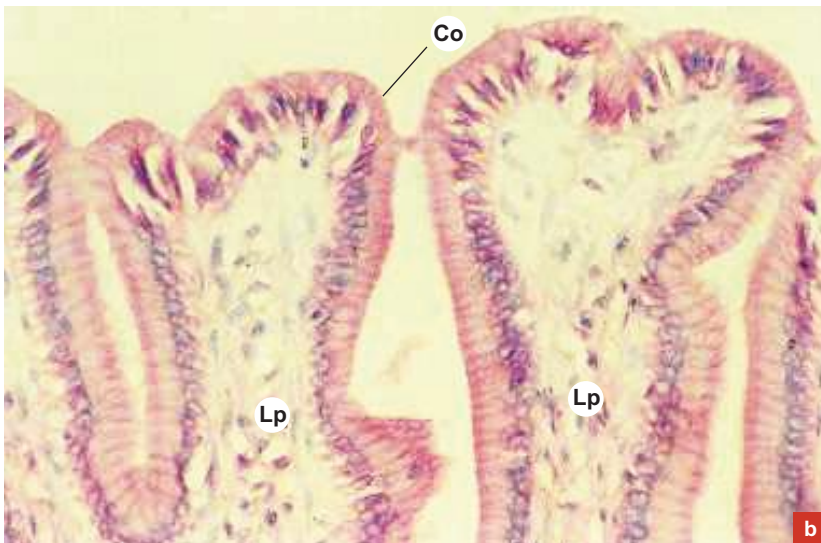


b

X200



X200

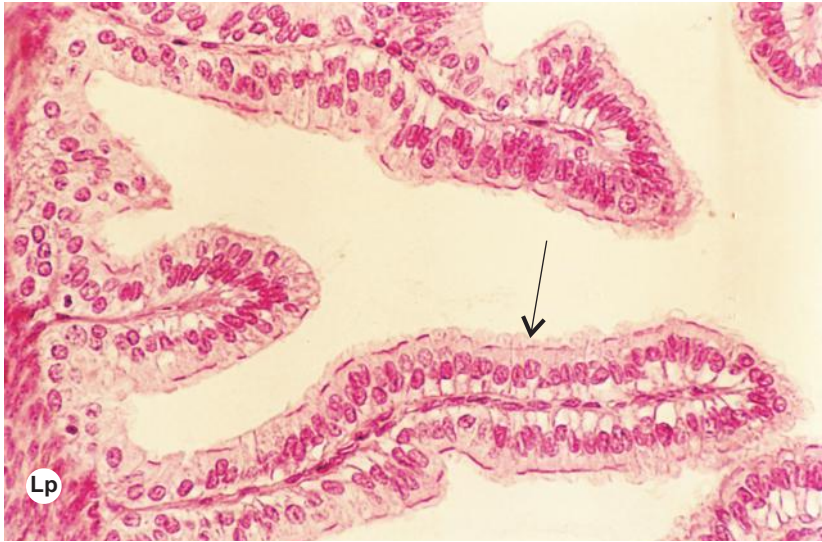

**Plate 2.1:4** Simple columnar nonciliated epithelium (e.g. lining of *Gall bladder and stomach*).

Examine the luminal surface of gall bladder (a) or stomach (b) under L/P (refer to chapter 12) and note the following features:

- Mucosal folds lined by simple columnar epithelium.
- The epithelium (**Co**) of mucosal fold at magnification  $\times 200$  shows **oval nuclei** of the columnar cells lying close to and perpendicular to the basement membrane forming a single row of oval nuclei.
- The large supra nuclear part of the cytoplasm of columnar cells is eosinophilic and distinct.

X200

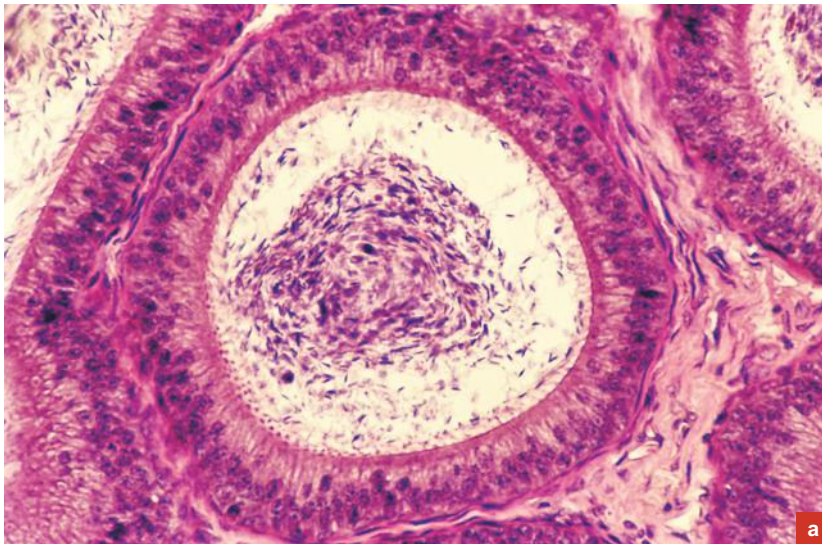


**Plate 2.1:5** Simple columnar ciliated epithelium (e.g. lining of Fallopian tube).

Examine the slide and note the following features:

- A section of uterine tube shows a lot of mucosal folds projecting into the lumen. Examine a fold at magnification  $\times 200$ .
- Note that most of the epithelial cells are provided with cilia (arrow) on their luminal surface, Lp = lamina propria.

X200

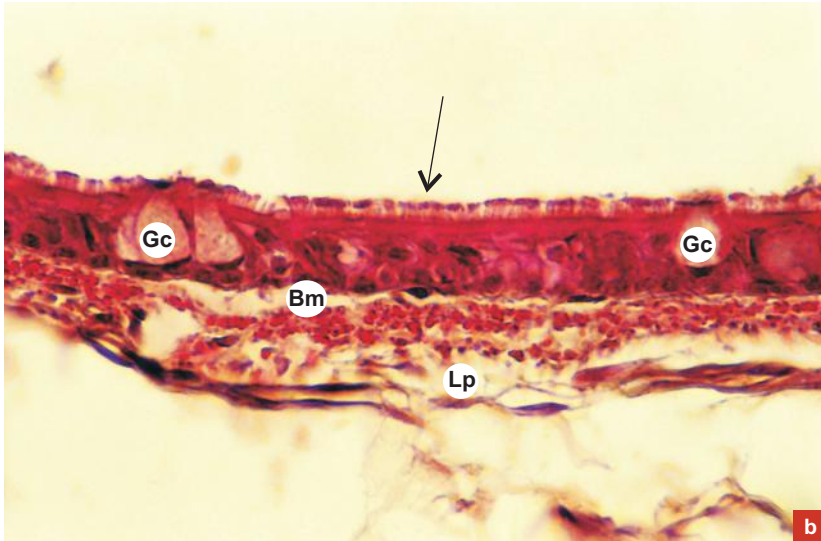


**Plate 2.1:6a** Pseudostratified columnar epithelium with stereocilia (e.g. epididymis); H&E staining.

Examine the epithelial lining of ductus epididymis and note the following features:

- In this epithelium, though the nuclei are situated at various levels, the cells are not really stratified (not superimposed).
- This is because the cells are of different shapes and height and many of them do not reach the surface. However, all of them are attached to the basement membrane.
- Those which reach the surface are columnar cells and are provided with stereocilia (Plate 2.1:6a).

X200



b

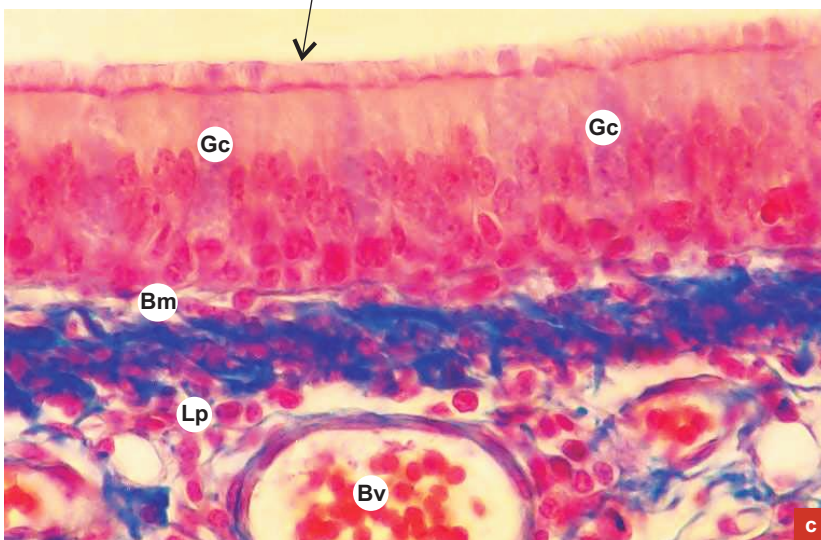
**Plate 2.1:6  
b and c**

Pseudostratified columnar epithelium with true cilia (e.g. lining of respiratory tract; H&E staining and special stain).

Examine the mucosal lining of the trachea and note the following features in the epithelium.

- The arrangements of the cells are the same as in the lining of epididymis (Plate 2.1:6a) but the columnar cells that reach the surface are provided with true cilia (**arrow**).
- Mucus secreting goblet cells (**Gc**; flask-shaped) are also found in the epithelium of respiratory tract (Plate 2.1:6b and c).
- The basement membrane (**Bm**) is very thick. **Lp** = lamina propria; **Bv** = blood vessel.

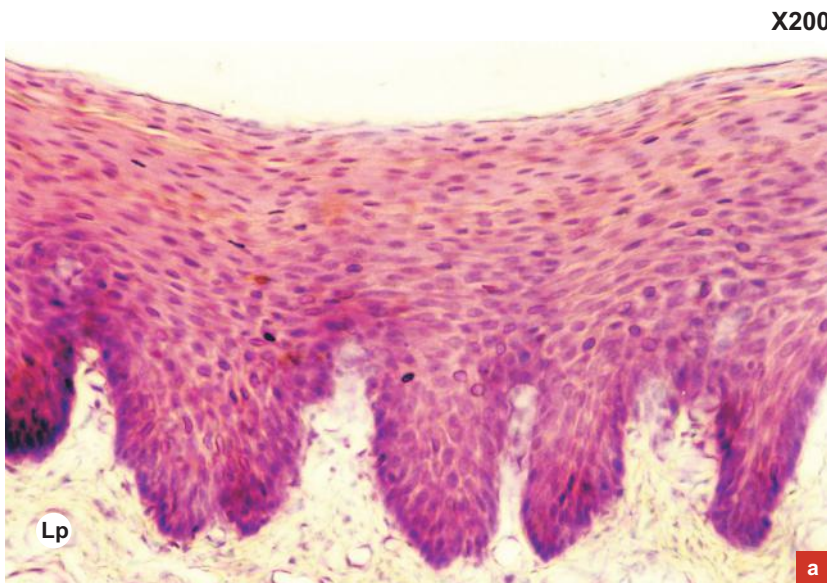X200



c

# Practical No. 2.II

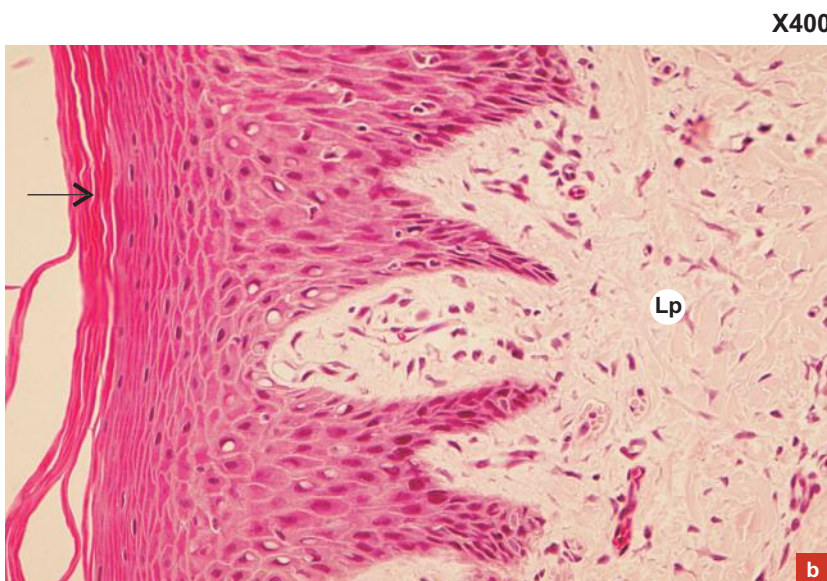
## Epithelial Tissue II: Stratified Epithelium



**Plate 2.II:1a** Stratified squamous epithelium (nonkeratinized) e.g. lining of oesophagus.

Examine the lining of oesophagus and note the following features:

- Under L/P (refer to chapter 12) see the smooth luminal surface and undulated basal surface of the epithelium.
- It is made up of several layers of cells.
- The shape and disposition of nuclei in these layers at magnification  $\times 200$  shows (Plate 2.II:1a)
  - oval in the basal layer
  - round in the intermediate layers
  - flat in the superficial layer – these indicate the types of cells constituting the epithelium, i.e. basal layer is columnar, intermediate layer is polyhedral, and the superficial layer is squamous
- There is no superficial keratinized zone.

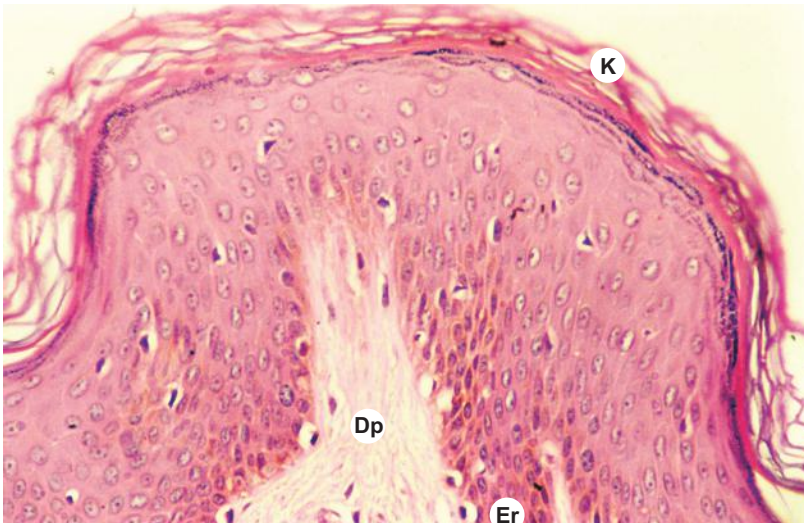

**Plate 2.II:1b** Stratified squamous epithelium (parakeratinized) e.g. masticatory mucosa.

Under high power examine the lining epithelium of masticatory mucosa from either hard palate or gingiva (Plate 2.II:1b) and note the following features:

- Luminal surface of the epithelium is partly keratinized (arrow).
- Its basal surface is uneven due to the presence of deep connective tissue papillae of lamina propria (Lp).
- It is made of several layers of cells. The shape and disposition of nuclei in these layers are same as that in Plate 2.II:1a.

X200

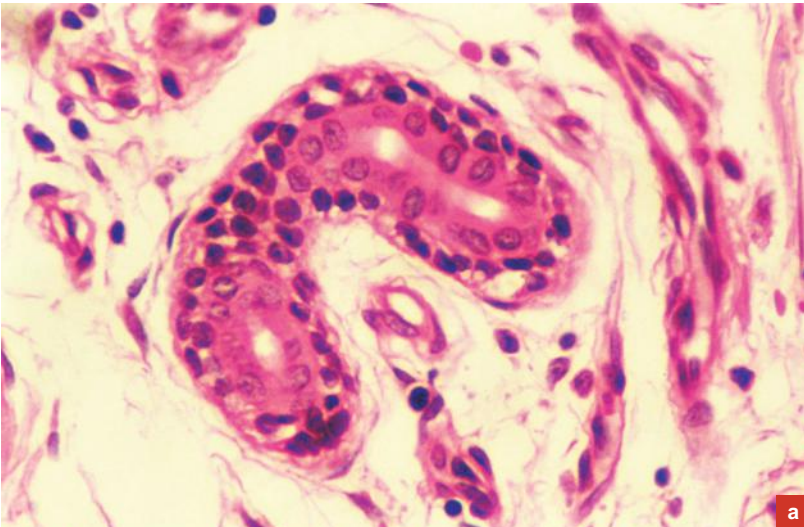


**Plate 2.II:2** Stratified squamous epithelium (keratinized) (e.g. epidermis of skin).

Examine the slide under L/P (refer to chapter 11) and H/P (Plate 2.II:2) and note the following features:

- It is a dry epithelium.
- It is made of many layers of cells.
- See the superficial non-nucleated keratinized zone (**k**).
- This zone is made of dead, flat, scale-like (horny) cells filled with keratin for protection.
- The deep nucleated zone shows various layers of cells as described under nonkeratinized epithelium.
- The basal surface of the epithelium is uneven due to the presence of epidermal ridges (**Er**) and dermal papillae (**Dp**).

X400

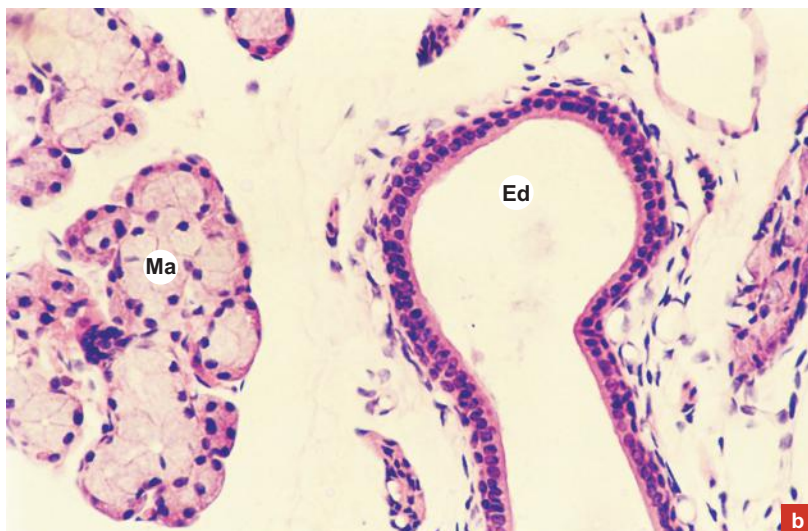


**Plate 2.II:3 a and b** Stratified cuboidal epithelium, e.g. duct of sweat gland and interlobar excretory duct of salivary gland.

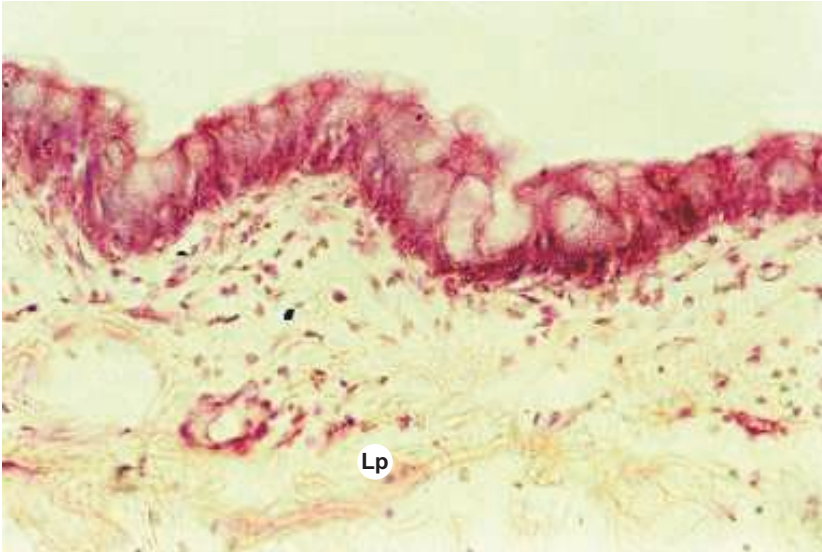Examine the slides and note the following features:

- The ducts of sweat gland are made of double layer of cuboidal cells.
- The ducts can be identified by their size (smaller) and staining characteristics (darker) from the glandular parts which are larger in size and lightly stained.
- The excretory duct (**Ed**) of salivary gland is also lined by double layer of cuboidal cells (Plate 2.II:3b).  
**Ma** = mucous acini.

X200



X200

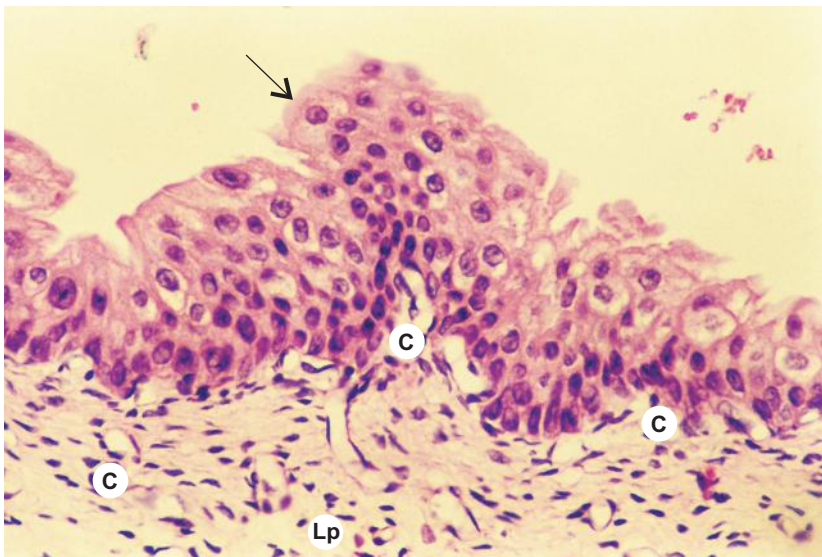


**Plate 2.II:4** Stratified columnar epithelium (e.g. *palpebral conjunctiva*).

Examine the slide and note the following features:

- The inner surface of the eyelid is covered by conjunctiva (mucous membrane) whose epithelium is of stratified columnar variety with goblet cells interspersed.
- Identify the type of epithelium present on the external surface of the eyelid.  
Lp = lamina propria.

X200



**Plate 2.II:5** Transitional epithelium (e.g. *lining of urinary bladder*).

Examine the lining of urinary bladder and note the following features:

- In the empty bladder the epithelium is made of 5–6 layers of cells.
- The superficial cells (facet cells) are **rounded** (dome-like, **arrow**) and change their shape according to the degree of distention of the bladder.
- Often these cells are **binucleate**.
- Plasma membrane of the superficial cells are thickened on the luminal aspect to form **cuticle**, which is responsible for the osmotic barrier between urine and tissue fluid.
- In the distended bladder the epithelium is made of 3 or 4 layers of cells with superficial cells becoming squamous.  
Lp = lamina propria; C = capillary.

# 3

# GLANDS

A gland is an organ of secretion made of specialised secretory cells derived from surface epithelium on which it opens.

## GENERAL FEATURES

- Glands can be present as discrete organs or in the layers of viscera.
- The secretory cells of the glands form functional units called secretory end pieces, which are either flask shaped (acini) or cylindrical in shape (tubules).
- It is epithelial in origin.
- The fluid secreted by the gland contains enzymes, hormones, mucus or fat.
- The rate of secretion is modulated by nervous and hormonal influences.
- The secretory end pieces of some exocrine glands are surrounded by star-shaped contractile cells that lie between the secretory cells and the basement membrane. They are called myoepithelial cells as they share characteristics of both epithelial and muscle cells.

## DEVELOPMENT (FIG. 3.1)

- Glands arise as invagination of the epithelium into the underlying vascular connective tissue.
- The distal part of the invagination forms the glandular portion or *secretory end piece*, which is functionally an active portion.
- The proximal part forms the *excretory duct* which opens on the surface of the epithelium from which it is developed.
- Some cells get detached from the epithelial surface and form ductless glands or endocrine glands.

## CLASSIFICATION OF GLANDS

A variety of criteria can be used for classifying glands. These are as follows:

### A. Based on the site of secretion

1. **Exocrine gland** – secretes its products onto a surface through ducts, e.g. *salivary glands*.
2. **Endocrine gland** – secretes its products into the bloodstream, e.g. *thyroid glands*.
3. **Paracrine gland** – secretes its products into the local extracellular space affecting the surrounding cells, e.g. *enteroendocrine cells of gastrointestinal tract (GIT)*.

### B. Based on the number of cells

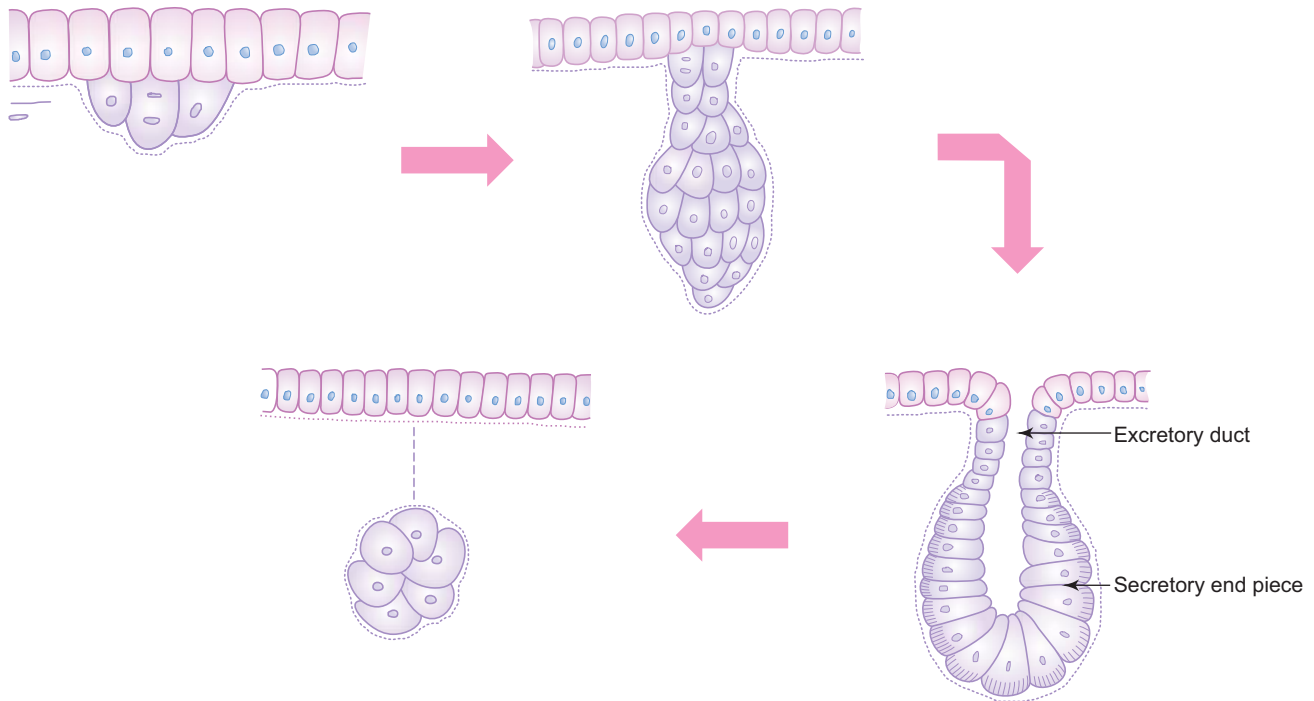
1. **Unicellular gland** – composed of a single cell, e.g. *goblet cells* in the respiratory and intestinal tracts.
2. **Multicellular gland** – composed of many cells, e.g. *all glands other than goblet cells*.

### C. Based on the number of ducts and shape of secretory end piece

1. **Simple gland** – has one duct.
2. **Compound gland** – has minor and major ducts.

The types of simple and compound glands are illustrated in Flowchart 3.1.





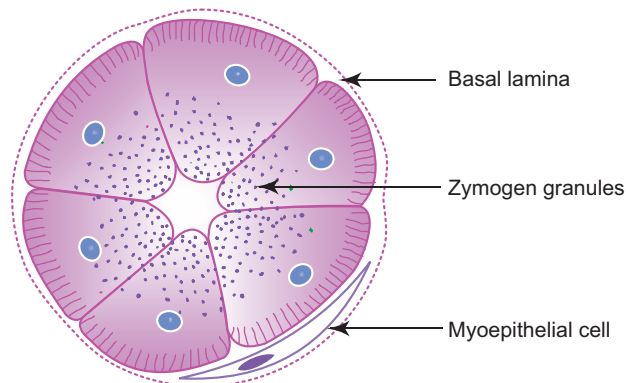
**Fig. 3.1** Development of glands.

**D. Based on the mode of secretion**

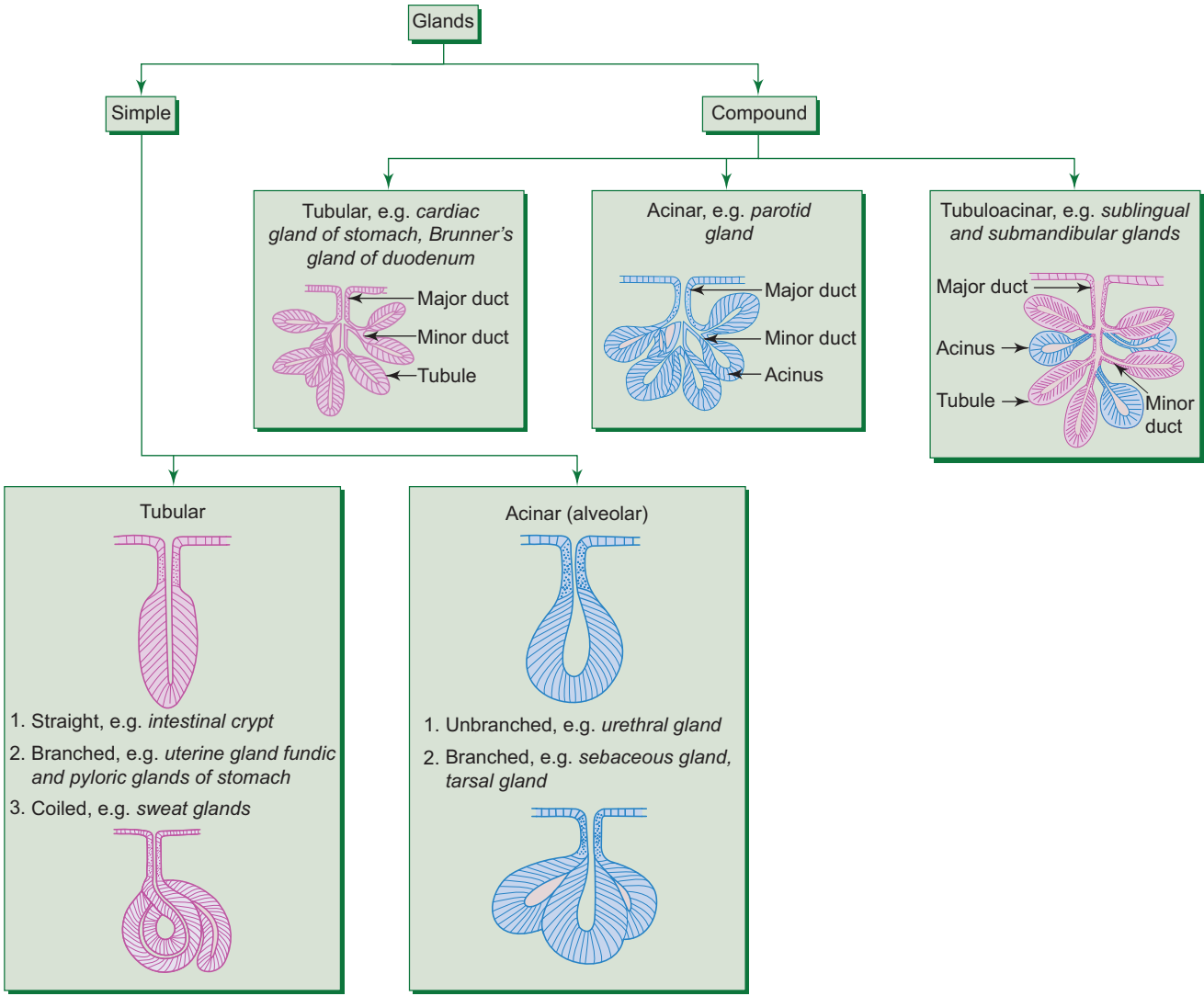
1. **Merocrine gland** – secretory cells release their contents by exocytosis (**no loss of cytoplasm**), e.g. most of the *compound glands*.
2. **Apocrine gland** – apical part of the cytoplasm of the secretory cells is lost in the process of secretion (**partial loss of cytoplasm**), e.g. lactating *mammary gland*, *sweat gland* in the axilla and external genitalia.
3. **Holocrine gland** – secretory cells burst out pouring their contents, resulting in the death of the cells (**complete loss of cytoplasm**), e.g. *sebaceous gland*, *tarsal gland*.
4. **Cytocrine gland** – cells are released as secretion, e.g. *testis (spermatozoa)*.

**E. Based on the nature of secretion**

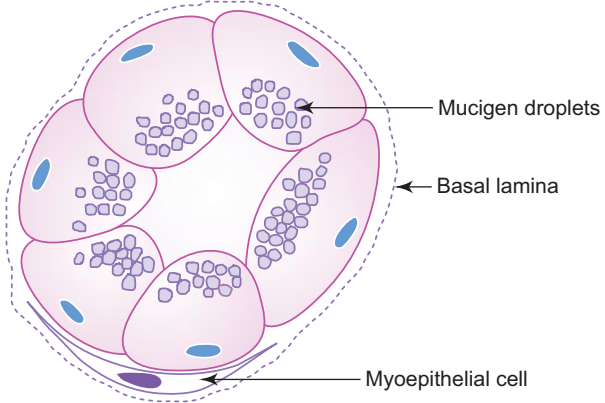
1. **Serous gland** – secretes thin watery material rich in enzymes, e.g. *parotid salivary gland* (Fig. 3.2; Box 3.1).



**Fig. 3.2** Serous acinus.



**Flowchart 3.1** Classification of glands, based on the number of ducts and shape of secretory end pieces.

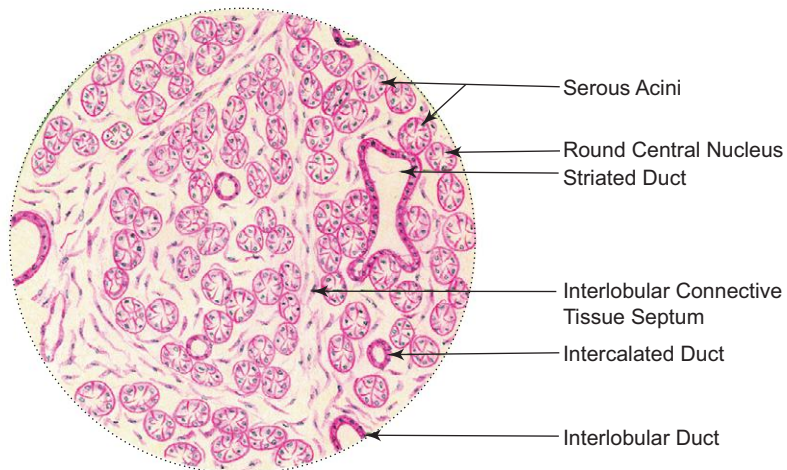


**Fig. 3.3** Mucous acinus.

**Box 3.1 Serous Gland (Parotid Salivary Gland).**

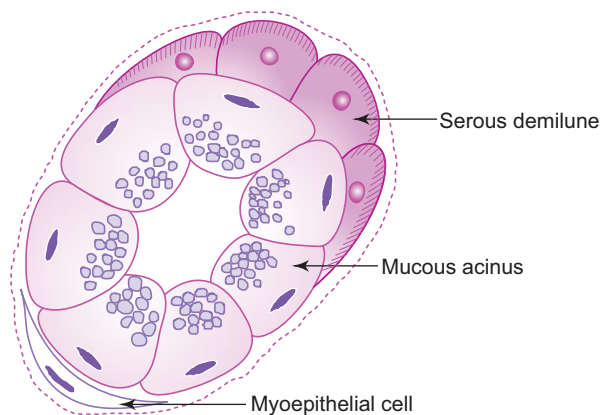
Presence of

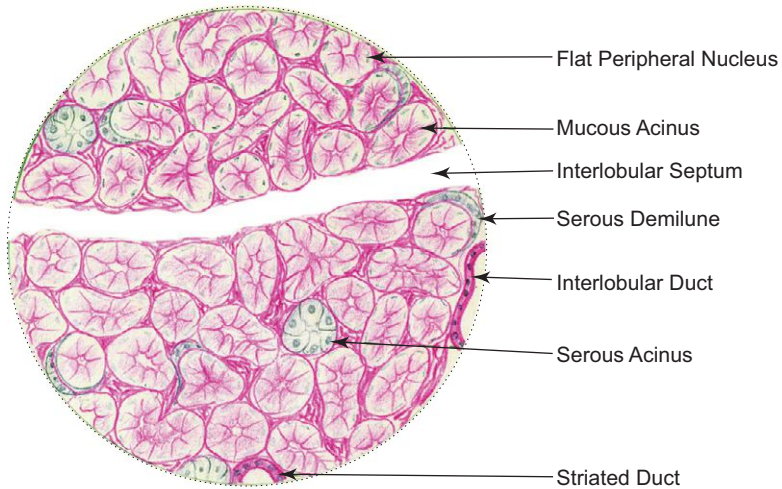
- (i) darkly stained **serous acini** with **narrow lumen**;
- (ii) **round, centrally placed nuclei** in the serous cells;
- (iii) well-developed duct system.

**Serous gland (Parotid salivary gland)**

2. **Mucous gland** – secretes thick viscous material for protection and lubrication, e.g. *sublingual salivary gland* (Fig. 3.3; Box 3.2).
3. **Mixed gland (seromucous)** – secretes watery and viscous material from both, serous and mucous acini, e.g. *submandibular salivary gland* (Box 3.3; Fig. 3.4).

The distinguishing features of serous and mucous acini are presented in Table 3.1.

**Fig. 3.4 Seromucous acinus (mixed).**

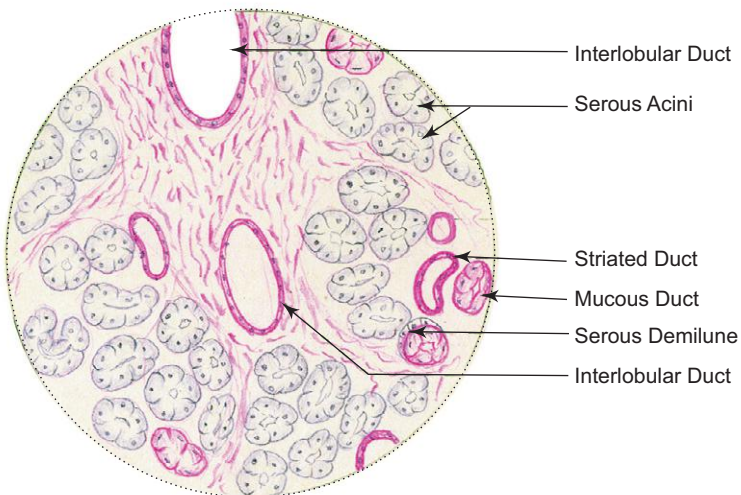


**Mucous gland (Sublingual salivary gland)**

**Box 3.2 Mucous Gland (Sublingual Salivary Gland).**

*Presence of*

- (i) lightly stained mucous acini/tubules with **large lumen**;
- (ii) **flat, peripheral nuclei** in the mucous cells;
- (iii) poorly developed duct system.



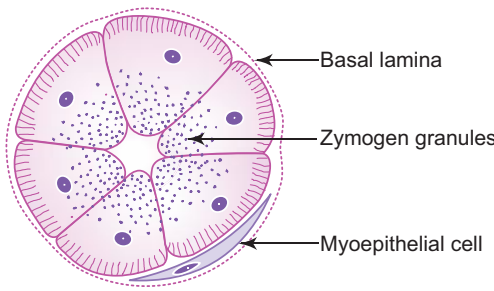
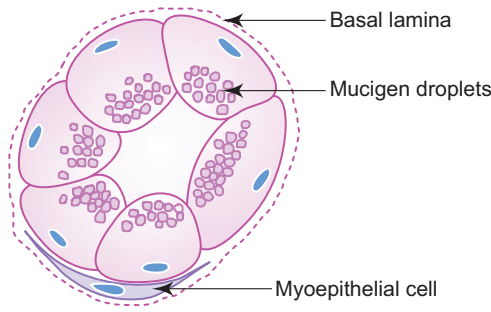
**Mixed gland (Submandibular gland)**

**Box 3.3 Mixed Gland (Submandibular Gland).**

*Presence of*

- (i) both darkly stained **serous** and lightly stained **mucous acinus**;
- (ii) **serous demilune** (crescent-shaped patch of serous cells);
- (iii) moderately developed duct system.

**Table 3.1** Differences between serous and mucous acini

	Serous acinus	Mucous acinus
Diagram	 <p>Labels: Basal lamina, Zymogen granules, Myoepithelial cell</p>	 <p>Labels: Basal lamina, Mucigen droplets, Myoepithelial cell</p>
Consistency for secretion	Thin watery	Thick viscous
Nature of secretory granules	Zymogen granules	Mucigen droplets
Shape and position of nucleus	Round, central	Flat, peripheral
Size of lumen	Small	Large
Appearance of cell boundaries	Indistinct	Distinct
Staining reaction with haematoxylin and eosin	Darkly stained	Lightly stained
Functions	Enzyme action	Protection and lubrication
Example	Parotid gland	Sublingual gland

## GENERAL ARCHITECTURE OF A COMPOUND GLAND

- Most glands are composed of either serous or mucous secretory cells or are of both types. These cells form secretory end pieces which are flask shaped (acini) or cylindrical (tubules) in shape. The end pieces are often associated with contractile *myoepithelial cells*, whose function is to express the secretion.
- The secretory end pieces and their associated ducts of the gland form *parenchyma*.
- The connective tissue framework of the gland which supports the parenchyma forms the *stroma*.
- **Parenchyma** is composed of
  - secretory end pieces (acini/tubules/tubulo-acini)
  - ducts (intralobular, interlobular, main excretory duct).
- **Stroma** is composed of
  - capsule
  - septae (interlobular, interlobar)
  - loose intralobular connective tissue supporting the parenchyma.

Malignant tumours arising from glandular epithelial tissue are called adenocarcinomas.

# Self-assessment Exercise

## I. Write short notes on:

- (a) Serous gland
- (b) Mucous gland
- (c) Mixed gland
- (d) Mucous and serous acini, highlighting differences between them

## II. Fill in the blanks:

1. Goblet cell is an example of \_\_\_\_\_ gland.
2. When there is a partial loss of cytoplasm from the secretory cells in the process of secretion, the gland is said to be \_\_\_\_\_ gland.
3. The contractile cell associated with secretory acinus is called \_\_\_\_\_
4. Sebaceous gland is an example of \_\_\_\_\_ gland.
5. The crescentic patch of serous cells associated with mucous acinus in a mixed salivary gland is called \_\_\_\_\_

## III. Choose the best answer:

1. Serous gland can be identified by the presence of serous acinus with
  - (a) small lumen
  - (b) large lumen
  - (c) flat peripheral nuclei
  - (d) mucigen droplets
2. When there is a complete loss of cytoplasm resulting in death of the secretory cell during the process of secretion, the gland is said to be
  - (a) merocrine
  - (b) apocrine
  - (c) holocrine
  - (d) cytotrine
3. Immunoglobulin A is found in the secretion of which of the following?
  - (a) Sublingual salivary gland
  - (b) Parotid salivary gland
  - (c) Submandibular salivary gland
  - (d) Palatine gland
4. The isotonic primary saliva is converted into hypotonic saliva by secreting and absorbing certain ions by the
  - (a) excretory duct
  - (b) secretory acini
  - (c) interlobar duct
  - (d) striated duct

5. The percentage of volume of saliva secreted by submandibular gland is
- (a) 70
  - (b) 40
  - (c) 25
  - (d) 5

**IV. State whether the following statements are true (T) or false (F):**

- 1. Simple gland has many ducts ( )
- 2. Glands are specialised epithelial derivatives ( )
- 3. Mucous gland secretes thin watery secretion ( )
- 4. In a glandular organ, 'stroma' denotes connective tissue framework, whereas 'parenchyma' denotes secretory acini and associated ducts ( )
- 5. Presence of striated secretory duct is the unique feature of salivary gland ( )

**V. Match the items of column 'A' with those of column 'B':**

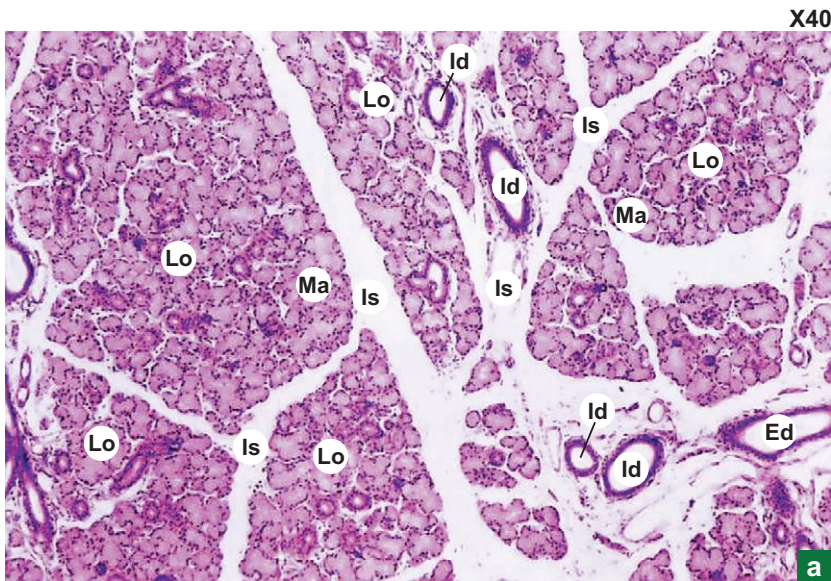
Column 'A'		Column 'B'
<i>Type of gland</i>		<i>Example</i>
1. Mucous	( )	(a) Parotid gland
2. Serous	( )	(b) Thyroid gland
3. Mixed	( )	(c) Sweat gland
4. Endocrine	( )	(d) Submandibular gland
5. Simple coiled tubular	( )	(e) Sublingual gland

**Answers**

- II.** 1. Unicellular      2. Apocrine      3. Myoepithelial cells      4. Holocrine      5. Serous demilune
- III.** 1. a      2. c      3. b      4. d      5. a
- IV.** 1. (F)      2. (T)      3. (F)      4. (T)      5. (T)
- V.** 1. e      2. a      3. d      4. b      5. c

# Practical No. 3

## Glandular Epithelium: The Salivary Glands



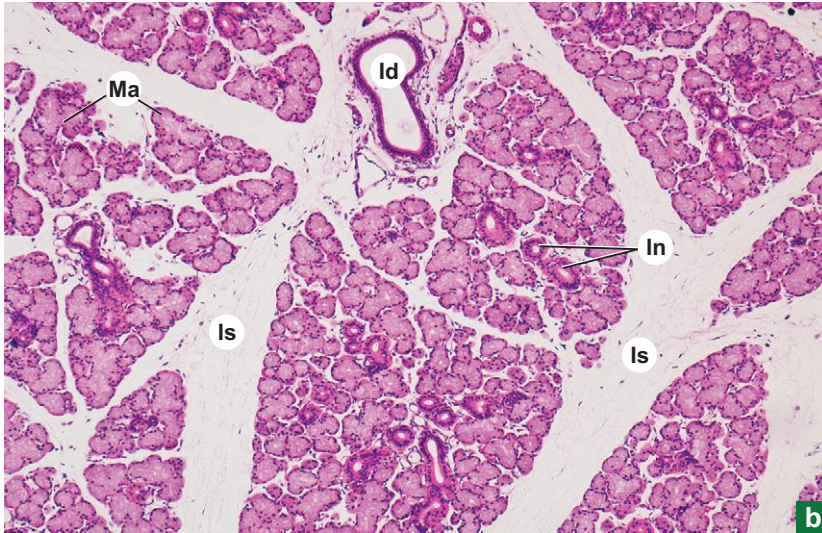### Plate 3:1a Salivary gland.

Examine a section of salivary gland under scanner (Plate 3:1a) and appreciate the general architecture of the gland.

- Note the fibrous capsule surrounding the gland sending interlobular septae (**Is**) dividing it into many lobules (**Lo**).
- Identify the larger excretory ducts (**Ed**) and medium-sized interlobular ducts (**Id**) in the septum and the small eosinophilic intralobular ducts and lightly-stained secretory acini (**Ma**) in the lobule.



X100



b

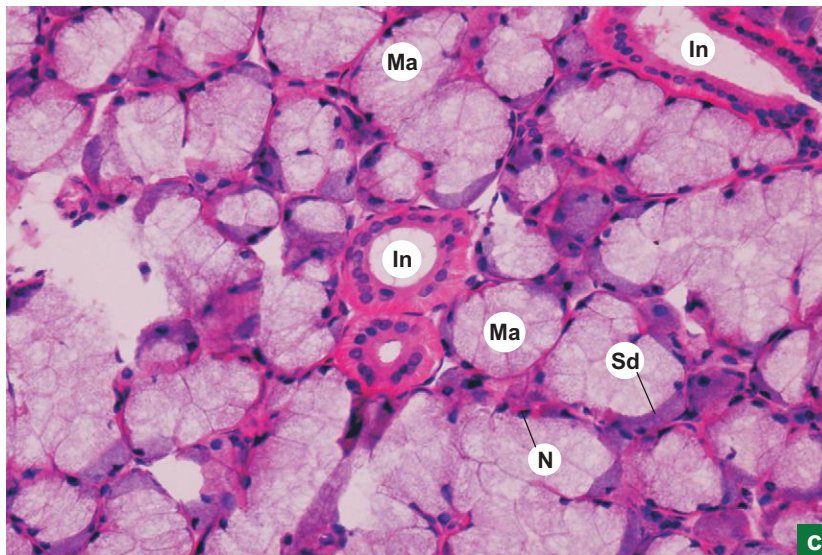
**Plate 3:1** Mucous gland (e.g. sub-lingual salivary gland).  
b and c

At low and high magnifications (Plate 3:1b and c), observe the secretory end piece (mucous acinus) and note its features:

- *Lightly-stained* cuboidal mucous cells, forming *mucous acinus (Ma)*.
- *Flat peripherally-placed nucleus (N)* in each cell.
- *Large lumen* of the acinus – can be easily identified.
- Some mucous acini are associated with darkly stained crescentic patch of serous cells called *serous demilune (Sd)*.

Among the acini identify the large eosin-stained intralobular ducts (**In**; striated or secretory ducts) lined by simple columnar epithelium and the small intercalated ducts lined by cuboidal epithelium.

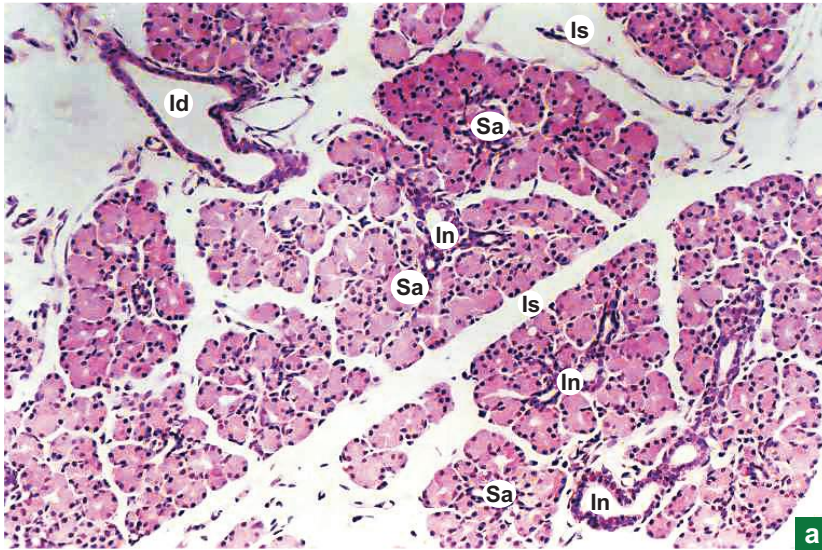
X400



c

The **striated ducts** exhibit basal striations which are due to the basal infoldings of plasma membrane and longitudinal orientation of mitochondria (characteristics of an ion transporting cell). These ducts secrete potassium into primary saliva and absorb sodium making the isotonic primary saliva, hypotonic. They also secrete immunoglobulin A.

X100



a

**Plate 3:2** Serous gland (e.g. *parotid gland*)  
a and b

At low magnification (Plate 3:2a), observe the architecture of the gland.

Note the intercalated duct (Ic); intralobular duct (In); interlobular duct (Id); interlobular septum (Is).

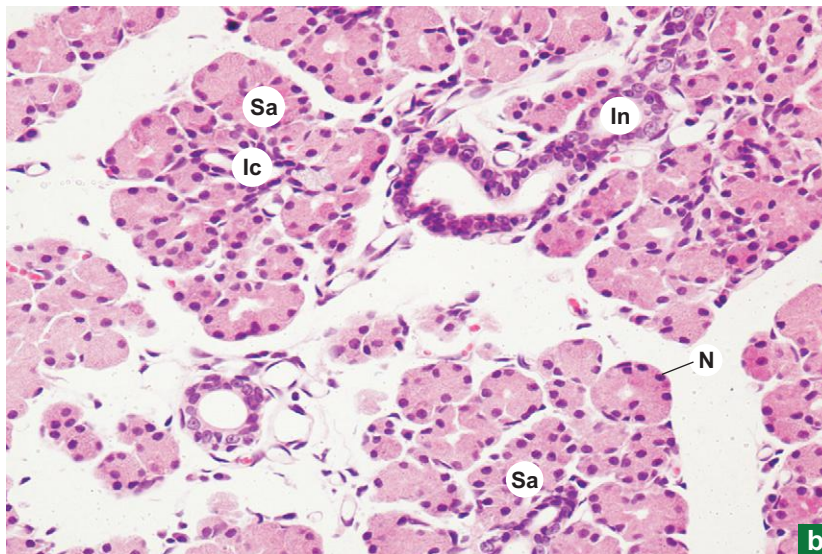
At high magnification (Plate 3:2b), observe the secretory end piece (serous acinus) and note the following features:

- Darkly-stained pyramidal serous cells forming serous acinus (Sa).
- Round centrally-placed nucleus (N) in each cell.
- Small lumen of the acinus; lumen is very small and may not be visible.

Note the small intercalated duct (Ic) arising from the acinus. These ducts end in striated duct (In).

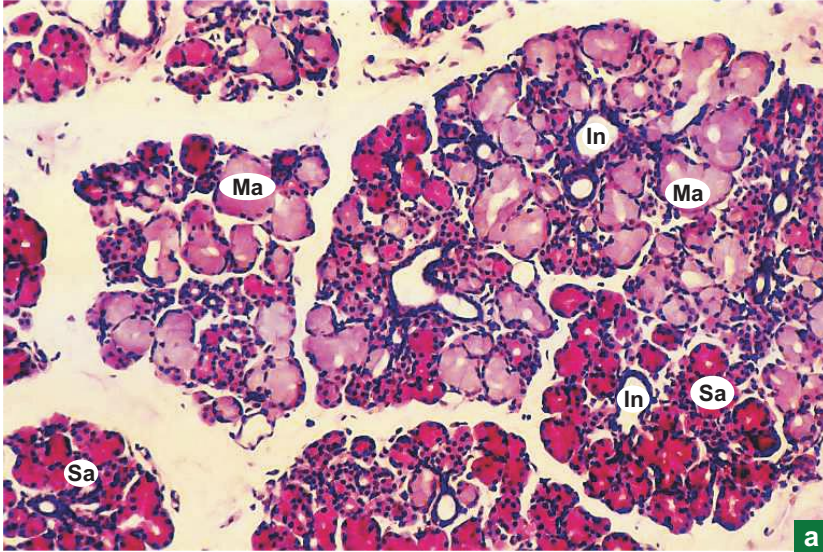
Compare this slide with the previous one and note the differences between serous and mucous acini (refer to text).

X400



b

X100



**Plate 3:3** Mixed gland (e.g. submandibular salivary gland).  
**a and b**

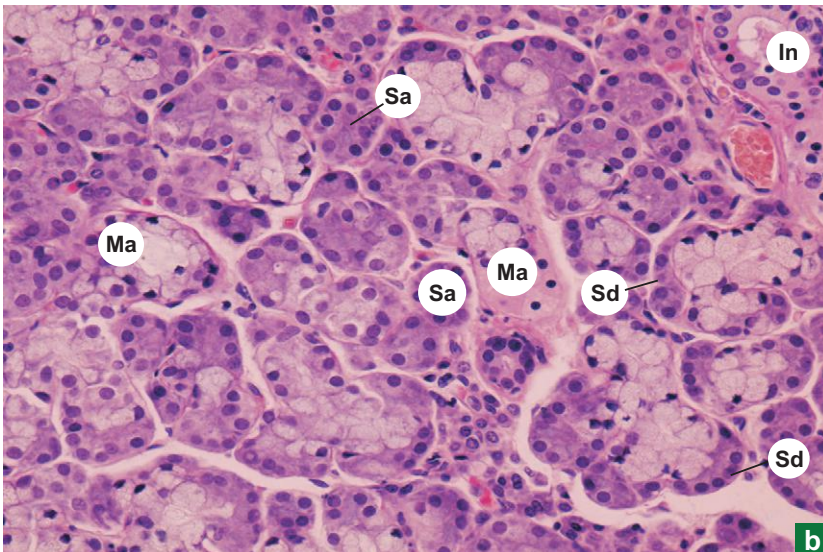
At low magnification (Plate 3:3a) appreciate the architecture as well as mixed nature of the gland.

It shows darkly-stained areas made up of serous acini (Sa) and lightly-stained areas made up of mucous acini (Ma). (Do not confuse adipose tissue for mucous acini.) Intralobular ducts (In) are seen among acini.

At high magnification (Plate 3:3b), observe the secretory end pieces (serous acini, mucous acini, serous demilunes) and note their features:

- The serous (Sa) and mucous acini (Ma) can be identified by their staining reaction, size of lumen, and shape and position of nuclei as stated in the text.
- The mucous acini are often associated with darkly-stained, crescentic patch of serous cells called *serous demilune* (Sd) of Giannuzzi. Identify this semilunar serous demilune adherent to a mucous acinus.

X400



## *Exercise*

Compare the slides of salivary glands (Plates 3:1 to 3:3) and enumerate their salient features.

Characteristics of salivary glands: sublingual, parotid and submandibular

<b>Sublingual</b>	<b>Parotid</b>	<b>Submandibular</b>
Mixed gland but predominantly made of mucous acini	Purely serous gland	Mixed gland but predominantly made of serous acini
Compound tubuloacinar gland	Compound acinar gland	Compound tubuloacinar gland
Poorly developed duct system	Well-developed duct system (mainly striated ducts)	Moderately developed duct system
Very few adipose cells	More infiltration of adipose cells	Moderate number of adipose cells
Thick viscous secretion protective and lubricative in function	Secretes thin watery secretion rich in enzymes and antibodies (IgA)	Intermediate in consistency
Constitutes 5% of volume of saliva	Secretion constitutes 25% of volume of saliva	Constitutes 70% of volume of saliva

"This page intentionally left blank"

# 4

## CONNECTIVE TISSUE

Connective tissue is one of the basic tissues which gives structural and metabolic support to other tissues and organs of the body. It connects other tissues.

### GENERAL FEATURES

- Connective tissue is made of
  - (a) cells,
  - (b) fibres, and
  - (c) ground substance.
- Unlike other tissues, the major constituent of connective tissue is its extracellular matrix.
- This extracellular matrix gives connective tissue its strength.
- Although all types of connective tissue have the same basic structure, their physical properties depend on the composition of the extracellular matrix.

### CLASSIFICATION OF CONNECTIVE TISSUE (BASED ON STRUCTURE AND FUNCTION)

Connective tissue can broadly be classified into following four categories:

#### A. Ordinary connective tissue

##### 1. Loose areolar connective tissue (Box 4.1)

- It is a vascular, delicate, flexible connective tissue where the fibres are loosely arranged.
- It serves as a packing material by filling spaces between various tissue components of an organ and giving it a shape, e.g. *subperitoneal tissue, endomysium, lamina propria*.

##### 2. Dense collagenous connective tissue

- It is a tough tensile connective tissue where the collagen fibres are densely packed giving strength and resistance to traction forces. It is of the following two types:
  - (a) *Regular* (Box 4.2), where the collagen fibres are densely packed in an orderly manner, e.g. *tendon, ligament, aponeurosis*.
  - (b) *Irregular* (Box 4.3), where the collagen fibres are densely packed but oriented in all directions, e.g. *dermis of skin*.

##### 3. Connective tissue with special properties

- It encompasses following types of tissues:
  - (a) *Elastic tissue* (Box 4.4), is a specialised dense connective tissue made mainly of elastic fibres. It is found in places where elasticity is required apart from strength, e.g. *ligamentum nuchae*.
  - (b) *Muroid tissue*, is the embryonic connective tissue representing a stage in the development of adult connective tissue from mesenchyme, e.g. *Wharton's jelly*.
  - (c) *Reticular tissue*, is a modified form of loose connective tissue made of reticular fibres and cells. It provides the architectural framework for some cellular organs, e.g. *stroma of lymphoid organ*.
  - (d) *Adipose tissue* (Box 4.5), e.g. *hypodermis (panniculus adiposus)*. Refer to page 63 for details.

**B. Scleral connective tissue**

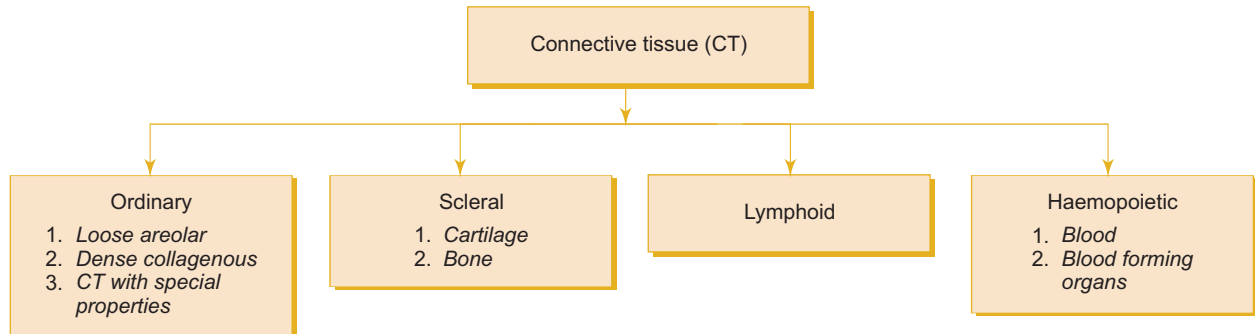
- It is a stiff connective tissue where the matrix is solidified.
- It provides the general framework of the body. Scleral connective tissue is of the following two types:

1. **Cartilage** (refer to chapter 5).
2. **Bone** (refer to chapter 6).

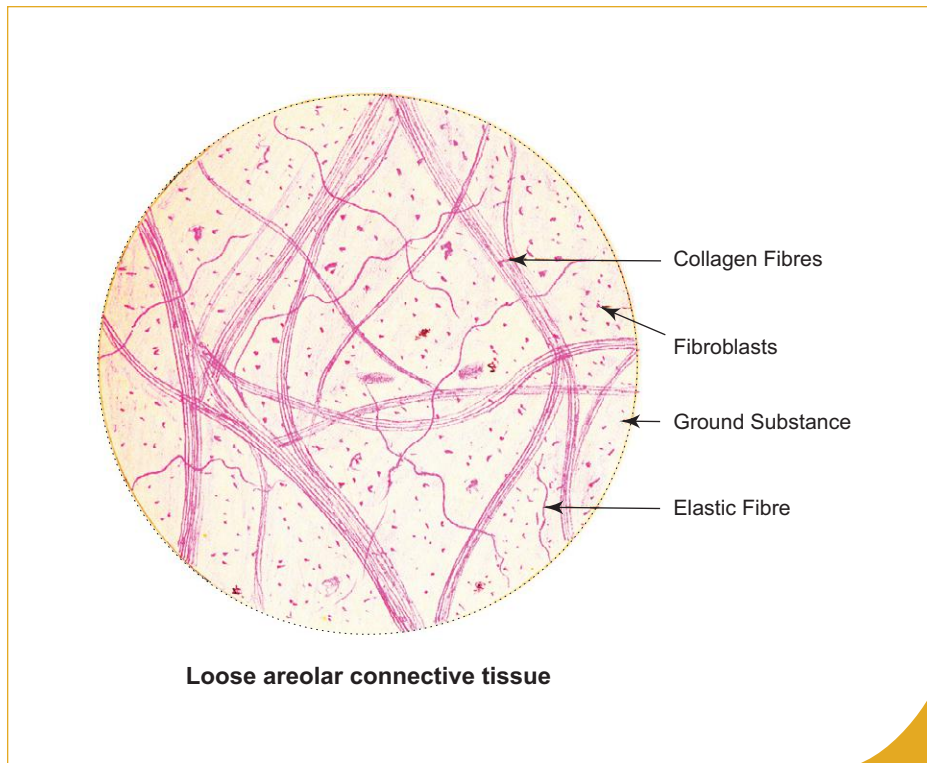
**C. Lymphoid tissue** (refer to chapter 7)**D. Haemopoietic tissue**

- This refers to blood and blood forming organs. (Refer to a *textbook of Physiology* for description.) The classification of connective tissue is summarised in Flowchart 4.1.

The present chapter discusses the ordinary connective tissue.



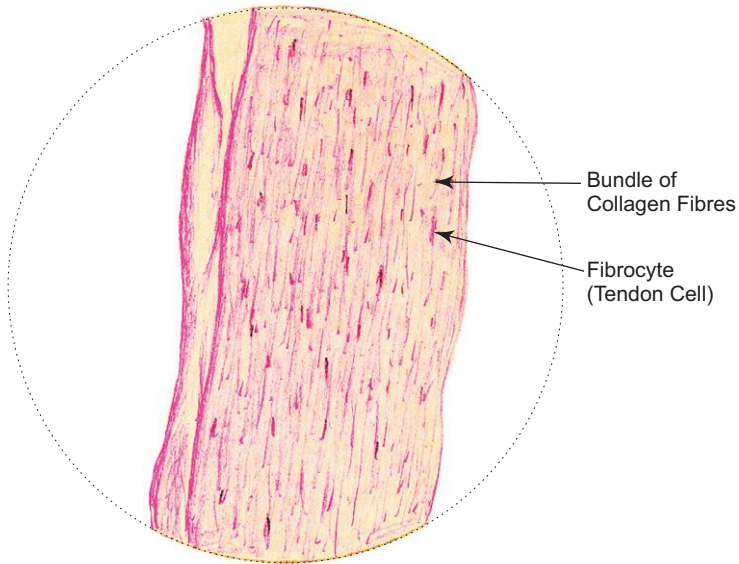
**Flowchart 4.1** Classification of connective tissue.



**Box 4.1** Loose Areolar Connective Tissue.

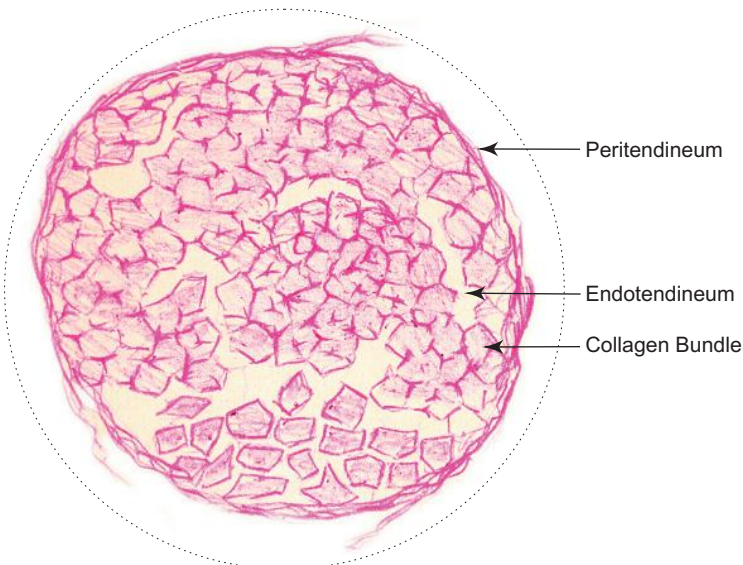
*Presence of*

- few **loosely arranged** collagen and elastic fibres;
- large number of connective tissue cells** (fibroblasts, fibrocytes, mast cells, etc.);
- large amount of ground substance.



L.S.

Dense regular collagenous connective tissue (Tendon)



C.S.

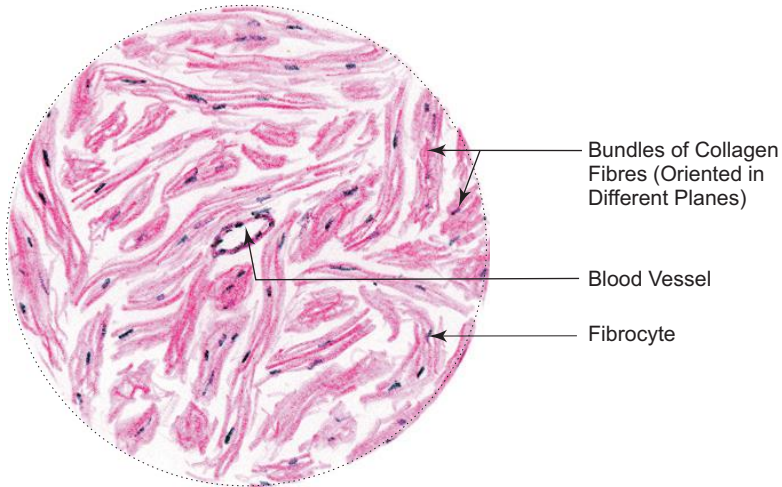
Dense regular collagenous connective tissue (Tendon)

**Box 4.2** Dense Regular Collagenous Connective Tissue (Tendon).

*Presence of*

- (i) bundles of **parallel collagen** fibres;
- (ii) **rows of tendon cells** (fibrocytes) between the fibre bundles;
- (iii) less amount of ground substance.



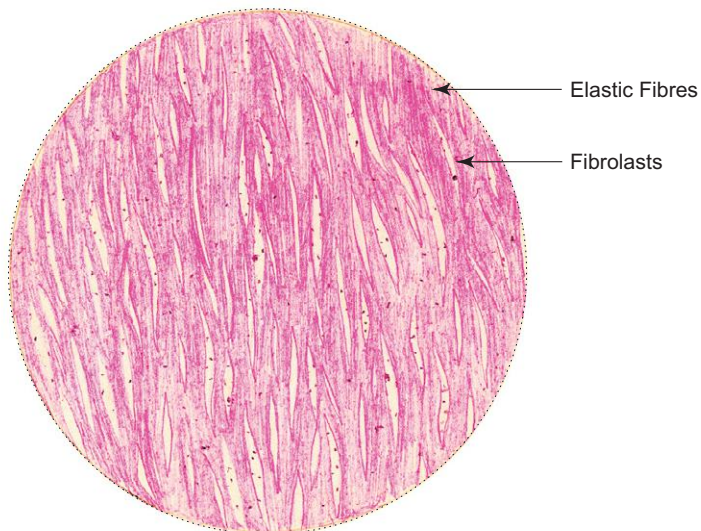


Dense irregular collagenous connective tissue

**Box 4.3** Dense Irregular Collagenous Connective Tissue (Dermis of Skin).

Presence of

- (i) irregular bundles of collagen fibres cut at different planes;
- (ii) less cells and ground substance.



Dense elastic connective tissue, e.g. *ligamentum nuchae*

**Box 4.4** Dense Elastic Connective Tissue.

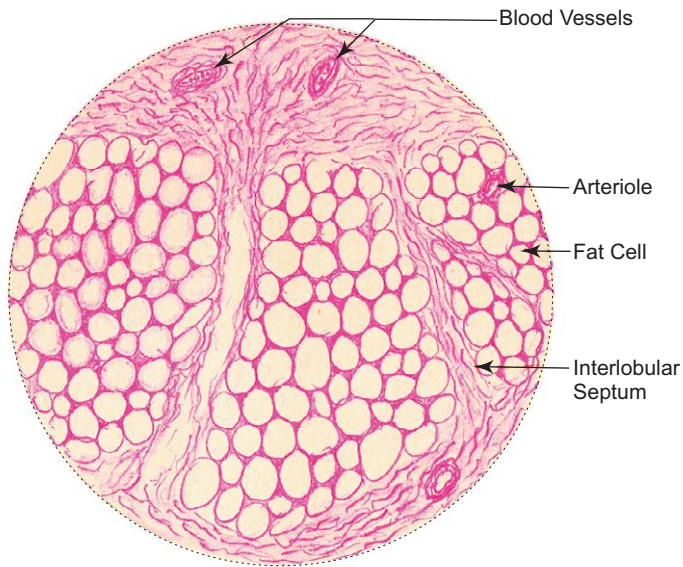
Presence of

- (i) branching refractile bundles of elastic fibres;
- (ii) less cells and ground substance between fibre bundles.

**Box 4.5 Adipose Tissue.**

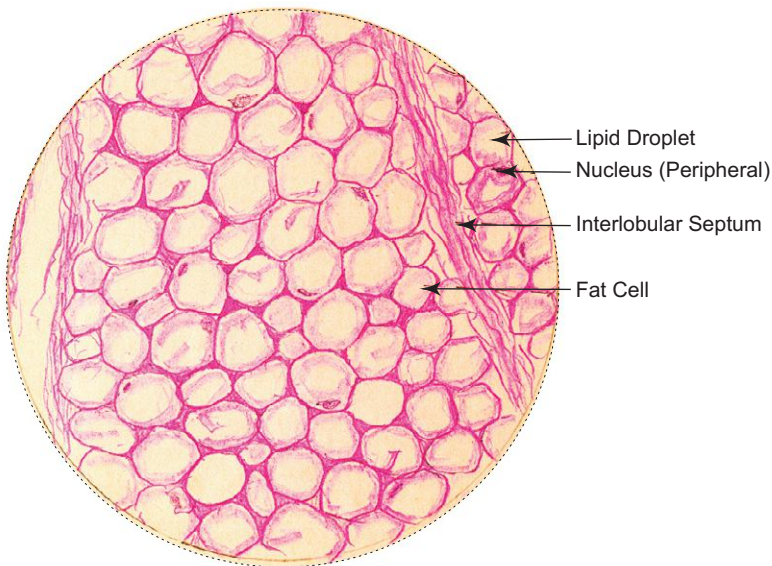
*Presence of*

- (i) empty space in each fat cell giving a **honeycomb appearance** (empty space is due to dissolution of lipid droplet);
- (ii) thin rim of cytoplasm and **eccentrically placed nuclei**;
- (iii) lobules separated by septa.



**L/P**

**Adipose tissue**



**H/P**

**Adipose tissue**

## ORDINARY CONNECTIVE TISSUE

### Composition of Connective Tissue

- Connective tissue is composed of three elements, namely, cells, fibres and ground substance.

**Cells:** Various types of cells are present in the connective tissue. These are grouped into fixed and free cells, each group performing a special function.

#### Fixed cells (intrinsic cells)

1. Fibroblasts and fibrocytes
2. Undifferentiated mesenchymal cells
3. Fat cells (adipocytes)
4. Fixed macrophages (histiocytes)

*Fixed cells are responsible for production and maintenance of extracellular matrix.*

#### Free cells (extrinsic cells/wandering cells)

5. Free macrophages
6. Plasma cells
7. Mast cells
8. Leucocytes—migrated from blood

*Free cells are responsible for tissue reaction to injury or invasion of microorganisms.*

**Fibres:** The fibres of connective tissue are of the following three types:

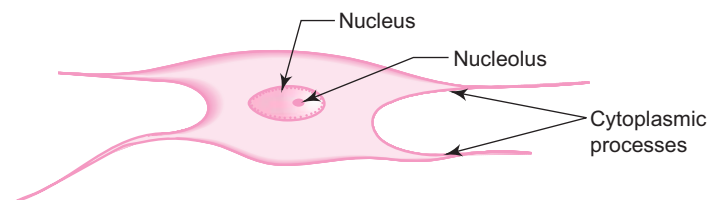
1. Collagen
2. Elastic
3. Reticular

**Ground Substance:** This refers to the gel-like material in which cells and fibres of connective tissue are embedded.

### Cells

#### 1. Fibroblasts (Fig. 4.1)

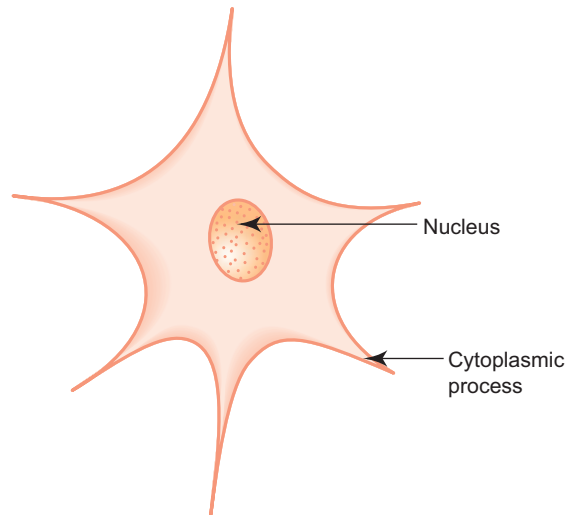
- Most commonly seen cells; are flat and fusiform in shape with slender processes.
- Contain large oval euchromatic nucleus with prominent nucleolus.
- Responsible for the formation of fibres and ground substance.
- Often associated with collagen fibres.
- Old inactive fibroblasts are called *fibrocytes*. They have dark elongated nuclei and acidophilic cytoplasm.
- Specialised contractile fibroblasts are called *myofibroblasts* and are seen at the sites of wounds.



**Fig. 4.1** Fibroblast.

#### 2. Undifferentiated mesenchymal cells (Fig. 4.2)

- Stellate in shape with delicate cytoplasmic processes.
- Pluripotent cells, which develop into new cell types when stimulated.

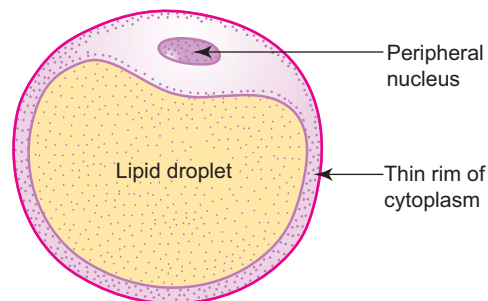


**Fig. 4.2** Mesenchymal cell.

- Resemble fibroblasts.
- Found along the periphery of blood vessels, therefore they are also called *adventitial cells*.

### 3. Fat cells (adipocytes; Fig. 4.3)

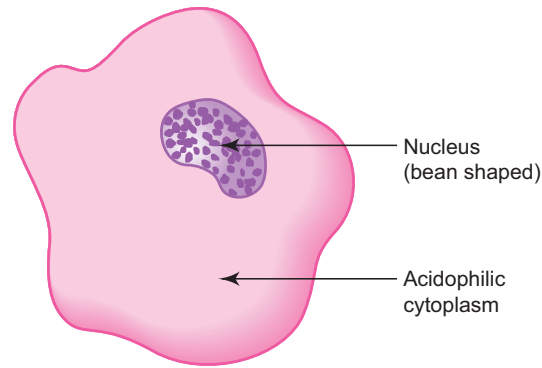
- Store energy (lipid).
- Are large cells (50  $\mu\text{m}$ ). Each cell contains a large single lipid droplet (unilocular) which is dissolved by xylol during preparation of a section, leaving a large empty space and a thin rim of cytoplasm and peripheral nucleus—resembles a signet ring.
- Incapable of division.
- Aggregate to form adipose tissue.
- Are supported by reticular fibres.



**Fig. 4.3** Adipocyte.

### 4. Fixed macrophages or histiocytes (Fig. 4.4)

- Are irregular in shape with numerous filopodial processes.
- Have dark eccentrically placed indented nucleus.
- Have acidophilic cytoplasm containing many lysosomes.
- Are derived from blood monocytes.
- Are involved in *phagocytosis*—play a role in the local defense of the body against bacterial invasion.
- Form part of the mononuclear phagocytic system.
- Can be stained with vital dyes (India ink, trypan blue).
- Activate B lymphocytes to form antibodies.
- Under pathological condition many macrophages group around a large foreign body and fuse together to form a multinucleated *giant cell*.



**Fig. 4.4** Macrophage.

**5. Free macrophages**

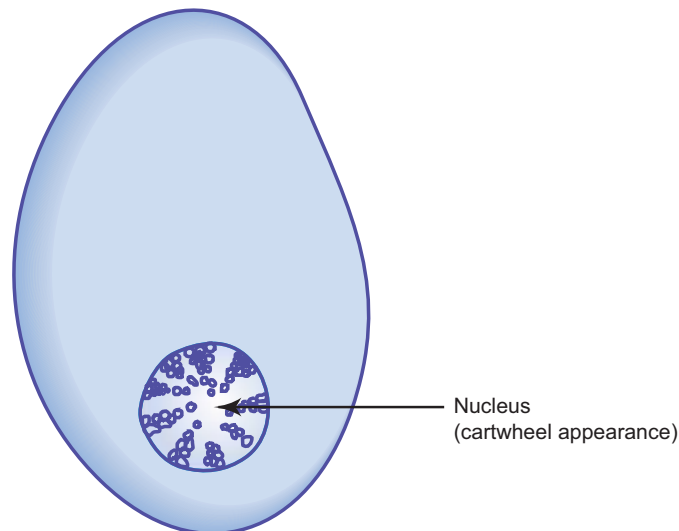
- During antigenic stimulation or inflammation, the fixed macrophages withdraw their processes and become free macrophages.

**6. Plasma cells (Fig. 4.5)**

- Are oval cells with basophilic cytoplasm.
- Have eccentrically placed nucleus with clumps of heterochromatin distributed around the periphery of the nucleus—giving a cartwheel appearance.
- Are derived from B lymphocytes.
- Their life span is about 2 weeks.
- Are involved in the defense of the body by producing antibodies (*immunoglobulins*).
- These antibodies may be temporarily stored in large vacuoles as *Russell bodies* when seen under light microscope.
- The plasma cells are found more in the lamina propria of gastrointestinal and respiratory tracts, which are the possible sites of entry of bacteria and foreign bodies. Thus, they form an *immunological barrier* along with lymphocytes just deep to the epithelium in the lamina propria.

**7. Mast cells (Fig. 4.6)**

- Are round or fusiform cells with centrally placed round nucleus.



**Fig. 4.5** Plasma cell.

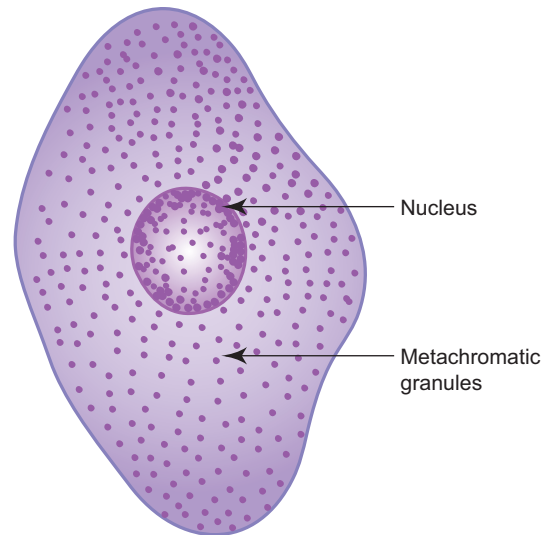


Fig. 4.6 Mast cell.

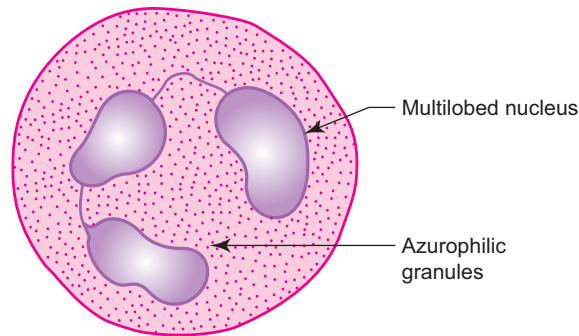
- Are found along small blood vessels.
- Their cytoplasm is filled with metachromatic granules.
- These granules contain *histamine*, a vasodilator and *heparin*, an anticoagulant.
- Functionally they resemble blood basophils, so often called *connective tissue basophils*.
- Are involved in inflammatory reactions, allergies and hypersensitive states.

In *anaphylaxis* (hypersensitivity/exaggerated reaction to foreign body), mast cells release histamine in response to antigen. Histamine causes dilation of blood capillaries and increased permeability, which results in drop in blood pressure. Respiratory distress may also occur due to oedema of mucous membrane of the respiratory tract and contraction of smooth muscles of bronchi.

Recent evidence suggests that there are two types of mast cells present in connective tissue. One type is called **connective tissue mast cell**, found in the skin and peritoneal cavity and is larger (10–12  $\mu\text{m}$ ) than **mucosal mast cell**. The cytoplasmic granules contain heparin. The second type is called mucosal mast cell, found in the lamina propria of intestine and in the lungs. They are smaller in size (5–10  $\mu\text{m}$ ) and the cytoplasmic granules contain chondroitin sulphate instead of heparin.

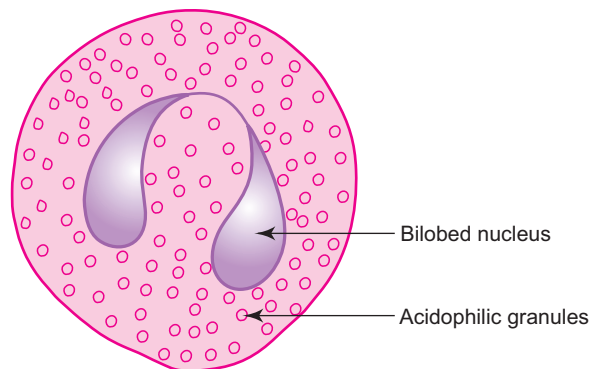
## 8. Leucocytes

- Nucleated white blood corpuscles which migrate to connective tissue from blood vessels through a process called *diapedesis*.
- Are found in large numbers during *inflammatory* condition.
- Exhibit amoeboid movement.
- Perform *phagocytosis* or mediate immune response to specific foreign material or pathogens.
- Thus, they are involved in *defense* of the body against foreign invaders.
- Are classified into two main groups based on nuclear shape and cytoplasmic granules: 1. granular leucocytes (neutrophils, eosinophils, basophils—named according to their staining properties), and 2. mononuclear leucocytes (lymphocytes and monocytes).
  - **Neutrophils** (Fig. 4.7) form the first line of cellular defense against bacteria by engulfing and destroying them. They increase in number during acute inflammation. Dead neutrophils are called *pus cells*.



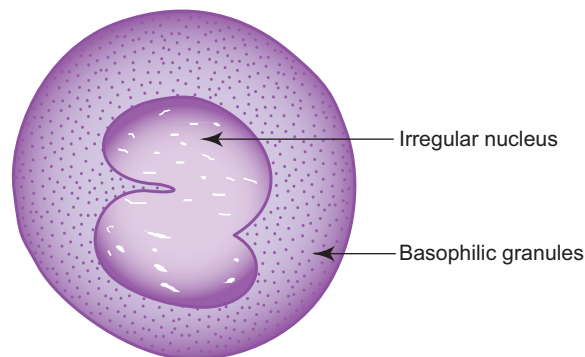
**Fig. 4.7** Neutrophil.

- **Eosinophils** (Fig. 4.8) are involved in selective phagocytosis of antigen antibody complex. They are attracted chemotactically to the site of inflammation by the substances released from basophils and mast cells. They increase in number in allergic condition and in parasitic infection.



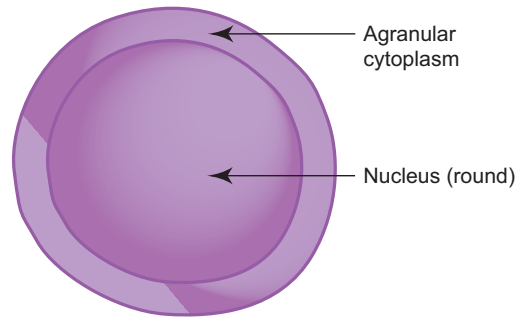
**Fig. 4.8** Eosinophil.

- **Basophils** (Fig. 4.9) are functionally similar to mast cells. They contain histamine and heparin granules. In response to antigen, histamine is liberated inducing an inflammatory response.



**Fig. 4.9** Basophil.

- **Lymphocytes** (Fig. 4.10) are the smallest cells of the connective tissue with dark spherical nuclei and a thin rim of basophilic cytoplasm. They mediate immune response to antigen. They increase in number during chronic inflammatory conditions.



**Fig. 4.10** Lymphocyte.

## Fibres

### 1. Collagen fibres (Fig. 4.11)

- Are composed of a protein called *collagen* which constitutes 30% of the dry body weight.
- Occur singly or in bundles, e.g. *tendon*, *aponeurosis*, etc.
- Collagen fibres do not branch.
- Run in a wavy course.
- Are white in colour when fresh.
- Each collagen fibre consists of small parallel *fibrils*.
- Under electron microscope (E/M) each fibril consists of bundles of parallel *microfibrils* which show cross striations at 64 nm intervals.
- Each microfibril is composed of molecules of *tropocollagen* which are responsible for the striations.
- Each tropocollagen is about 260 nm long and 1.5 nm thick.
- Each tropocollagen molecule is made of three polypeptide chains called alpha units. Tropocollagen is synthesised by fibroblasts and released into the extracellular space where they get polymerised to form collagen fibrils.
- Collagen is not only synthesised by fibroblasts but also by other cells, namely,
 

Chondroblasts	–	in cartilage
Osteoblasts	–	in bone
Smooth muscle	–	in blood vessels, etc.
Odontoblasts	–	in the tooth
- Collagen on denaturation (boiling) gives *gelatin*.
- Though more than 25 types of collagen have been identified based on their molecular composition, morphological characteristics, distribution and function, the most common types only are mentioned here. These are:
 

Type I	–	found in bones, tendons, dermis, etc.
Type II	–	found in cartilage
Type III	–	found in reticular fibres
Type IV	–	found in basement membranes
Type V	–	found in blood vessels and foetal membranes

### 2. Elastic fibres (Fig. 4.12)

- Are composed of protein called *elastin*.
- Elastin is synthesised by fibroblasts and smooth muscle cells (in blood vessels).
- Fibres occur singly and not in bundles.
- Branch and anastomose forming a network.
- Can be stretched (1½ times).




- Are yellow in colour when fresh.
- Are found in ligamentum nuchae, ligamentum flava, large arteries, etc.

### 3. Reticular fibres (Fig. 4.13)

- Are very thin immature collagen fibres, found to be continuous with collagen fibres (appear first in wound healing).
- Are structurally similar to collagen fibres.
- Form supportive framework of lymphoid organs and glands.
- Can be stained black with silver salts. Therefore, they are called *argyrophilic* fibres.
- Are composed of collagen type III.

### Ground Substance

- It is a transparent, homogeneous viscous solution.
- Fills the space between cells and fibres.



**Fig. 4.11** Collagen fibres.



**Fig. 4.12** Elastic fibres.



**Fig. 4.13** Reticular fibres.

- Acts as a molecular sieve facilitating diffusion of metabolites between blood and tissues.
- Is composed mainly of
  - (a) *mucopolysaccharides* (glycosaminoglycans), namely hyaluronic acid, heparan sulphate, etc. The mucopolysaccharides are responsible for the consistency and viscosity of the ground substance, which serves as a physical barrier to spread of infection.
  - (b) *structural glycoproteins*, namely, fibronectin (in dermis), chondronectin (in cartilage) and laminin (in basement membrane). They play an important role in adhesion of cells to the neighbouring structures.
  - (c) *water* and *electrolytes*, involved in maintenance of fluid balance.

## Functions

Connective tissue serves multiple purposes. The following are the main functions of connective tissue:

- *Support*: Connective tissue gives structural and mechanical support to the body by binding the cells and organs together.
- *Packing*: Loose areolar connective tissue fills the spaces between cells of various tissues and gives shape to the organ.
- *Storage*: Adipose tissue is the storehouse of energy (lipid) and about 9 calories can be liberated from every gram of adipose tissue. Loose areolar connective tissue stores water and electrolytes.
- *Transport*: The connective tissue matrix serves as a medium through which nutrients and metabolic wastes are exchanged between cells and blood.
- *Repair*: Connective tissue has great regenerative capacity following destruction caused by wound or infection. Myofibroblasts are involved in contraction of wound and fibroblasts are involved in laying down of matrix and fibres which fill the space formed by injury. The excess tissue formed during the repair process remains as a 'scar'.
- *Defense*: Most of the cells of connective tissue are involved in the defense of the body either by phagocytosis of foreign body or by producing specific antibodies against antigen.

## Adipose Tissue

### General Features

- Adipose tissue is a special type of connective tissue formed by aggregation of fat cells (adipocytes). It constitutes 15–20% of body weight in men and 20–25% in women.
- It is found subcutaneously (in the hypodermis) throughout the body except over the eyelid, penis, scrotum and lobule of auricle.

### Functions

- Is a reservoir of energy.
- Gives shape to the body and keeps some organs in position.
- Acts as a shock absorber.
- Gives thermal insulation to the body because it is a bad conductor of heat.

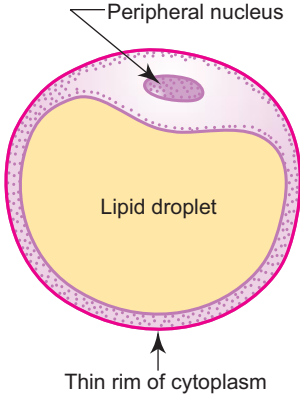
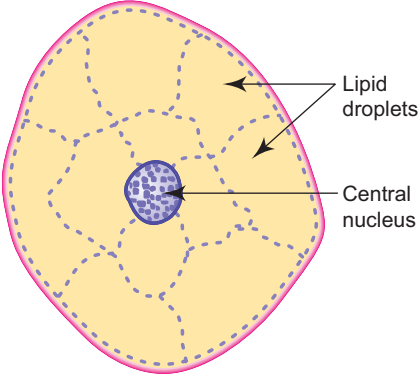
### Types

Adipose tissue is of following two types:

1. Yellow (white) or unilocular adipose tissue (adult type).
2. Brown or multilocular adipose tissue (embryonic type).

The features of both the types of adipose tissue are summarised in Table 4.1.

**Table 4.1** Comparison between the two types of adipose tissues

	Yellow adipocyte	Brown adipocyte
<i>Diagram</i>	 <p>Peripheral nucleus</p> <p>Lipid droplet</p> <p>Thin rim of cytoplasm</p>	 <p>Lipid droplets</p> <p>Central nucleus</p>
<i>Size and shape of the cell</i>	Big rounded cell	Small polygonal cell
<i>Number of lipid droplets</i>	Single—unilocular	Many—multilocular
<i>Shape and position of nucleus</i>	Flat peripheral nucleus	Spherical central nucleus
<i>Mitochondria</i>	Few	Many with long cristae
<i>Cytochrome content in mitochondria</i>	Low	High
<i>Endoplasmic reticulum</i>	Well developed	Not well developed
<i>Vascularity</i>	Less vascular	Highly vascular
<i>Distribution</i>	Widespread—found in adults	Limited—found only in foetuses and newborns
<i>Function</i>	Store house of energy	Production of heat (that protects the newborn against cold)

Obesity in adults is due to excessive accumulation of fat. This may result from either an excessive accumulation of fat in adipocytes, hypertrophic obesity or an increase in the number of adipocytes, hyperplastic obesity.

Benign tumours of adipocytes (lipomas) are very common in human beings. Microscopically, the lipoma is composed of adipocytes and large number of either blood vessels (**angiolipoma**) or of fibrous tissue (**fibrolipoma**);

# Self-assessment Exercise

## I. Write short notes on:

- (a) Connective tissue cells involved in defense of the body
- (b) Fibres of connective tissue
- (c) Yellow and brown fat, highlighting the differences between the two

## II. Fill in the blanks:

1. Macrophages are derived from \_\_\_\_\_
2. Antibodies produced by the plasma cells are temporarily stored inside the cell as \_\_\_\_\_
3. Exaggerated reaction to antigen in hypersensitivity state is known as \_\_\_\_\_
4. The process by which leucocytes migrate from blood to connective tissue is called \_\_\_\_\_
5. Fibroblasts involved in contraction of wound are called \_\_\_\_\_

## III. Choose the best answer:

1. Plasma cells are derived from
  - (a) monocytes
  - (b) basophils
  - (c) T lymphocytes
  - (d) B lymphocytes
2. Which of the following is *not true* about fixed macrophage (histiocyte)? It
  - (a) contains many lysosomes
  - (b) has basophilic cytoplasm
  - (c) can be stained with vital dyes
  - (d) is involved in phagocytosis
3. Large number of elastic fibres are present in
  - (a) tendon
  - (b) ligamentum nuchae
  - (c) basement membrane
  - (d) aponeurosis
4. Which of the following is *not true* about collagen? It
  - (a) constitutes 30% of the dry body weight
  - (b) is synthesised by fibroblasts
  - (c) is composed of mucopolysaccharides
  - (d) gives gelatin on denaturation
5. The fat cell of multilocular adipose tissue (brown fat) is characterised by the presence of
  - (a) spherical central nucleus and many lipid droplets
  - (b) flat peripheral nucleus and single lipid droplet
  - (c) flat central nucleus and single lipid droplet
  - (d) thin rim of cytoplasm

**IV. State whether the following statements are true (T) or false (F):**

1. The basic components of connective tissue are cells, fibres and ground substance ( )
2. The viscosity of the ground substance is due to the presence of mucopolysaccharides ( )
3. The free cells of the connective tissue are responsible for production and maintenance of extracellular matrix ( )
4. Collagen fibres are yellow in colour when fresh ( )
5. Undifferentiated mesenchymal cells are also called adventitial cells ( )
6. Elastic fibres branch and anastomose forming a network ( )
7. Neutrophils increase in number during acute inflammation ( )
8. Elastic fibres are also called argyrophilic fibres because they can be stained with silver salts ( )
9. Lobules of auricle contain adipose tissue ( )
10. Fat cells are capable of division ( )

**V. Match the items of column 'A' with those of column 'B':**

<b>Column 'A'</b>	<b>Column 'B'</b>
A. <i>Type of connective tissue</i>	<i>Example</i>
1. Dense regular collagenous tissue ( )	(a) Ligamentum nuchae
2. Adipose tissue ( )	(b) Wharton's jelly
3. Mucoid tissue ( )	(c) Stroma of lymphoid organs
4. Reticular tissue ( )	(d) Hypodermis
5. Elastic tissue ( )	(e) Tendon
B. <i>Connective tissue cells</i>	<i>Function</i>
1. Fibroblast ( )	(a) Storage of lipid
2. Macrophage ( )	(b) Synthesis of immunoglobulins
3. Plasma cell ( )	(c) Release of histamine
4. Mast cell ( )	(d) Phagocytosis
5. Adipocyte ( )	(e) Synthesis of extracellular matrix
C. <i>Connective tissue cells</i>	<i>Features</i>
1. Adipocyte ( )	(a) Many filopodial processes
2. Macrophage ( )	(b) Eccentrically placed nucleus with a cartwheel appearance
3. Plasma cell ( )	(c) Many nuclei
4. Mast cell ( )	(d) Signet ring appearance
5. Giant cell ( )	(e) Contains metachromatic granules

**Answers**

- II.** 1. Blood monocytes      2. Russell bodies      3. Anaphylaxis      4. Diapedesis      5. Myofibroblasts
- III.** 1. d    2. b    3. b    4. c    5. a
- IV.** 1. (T)    2. (T)    3. (F)    4. (F)    5. (T)    6. (T)    7. (T)    8. (F)    9. (F)    10. (F)
- V.** A.    1. e    2. d    3. b    4. c    5. a  
 B.    1. e    2. d    3. b    4. c    5. a  
 C.    1. d    2. a    3. b    4. e    5. c

# Practical No. 4

## Connective Tissue I: Ordinary

X100

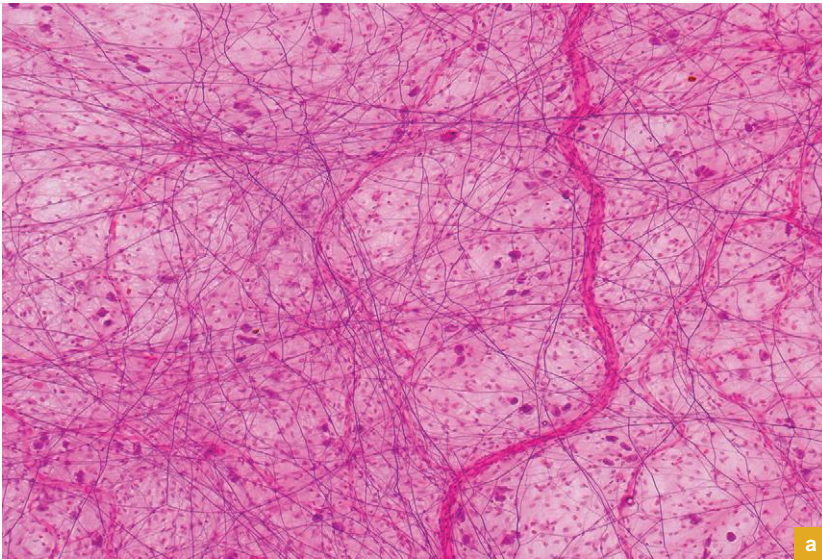


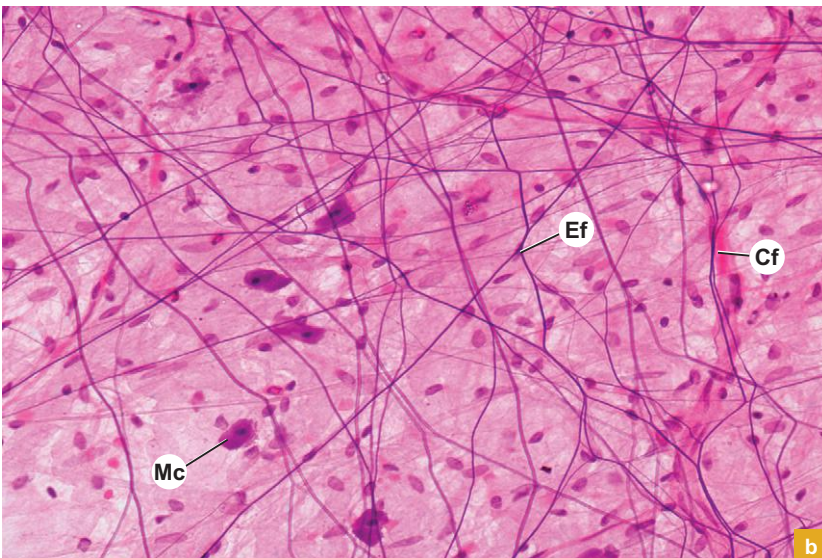
Plate 4:1  
a and b

Loose areolar connective tissue (e.g. subperitoneal connective tissue – spread).

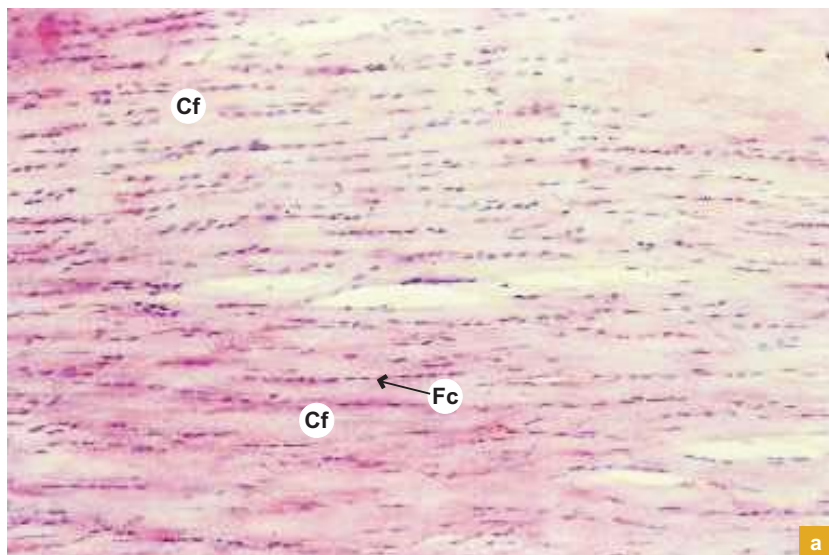
Examine the slide at low and high magnifications (Plate 4:1a and b) and note the following features:

- Few loosely arranged collagen (Cf) and elastic fibres (Ef). (Collagen fibres occur in wavy bundles, whereas elastic fibres are single and branching.)
- Large number of connective tissue cells. (Only their nuclei can be made out.) Note the degranulating mast cells (Mc).
- The faint background is the ground substance in which the cells and fibres are embedded.
- The various types of connective tissue cells can be identified by the shape and chromatin pattern of the nuclei. The cell outline is often difficult to make out.

X400



X100



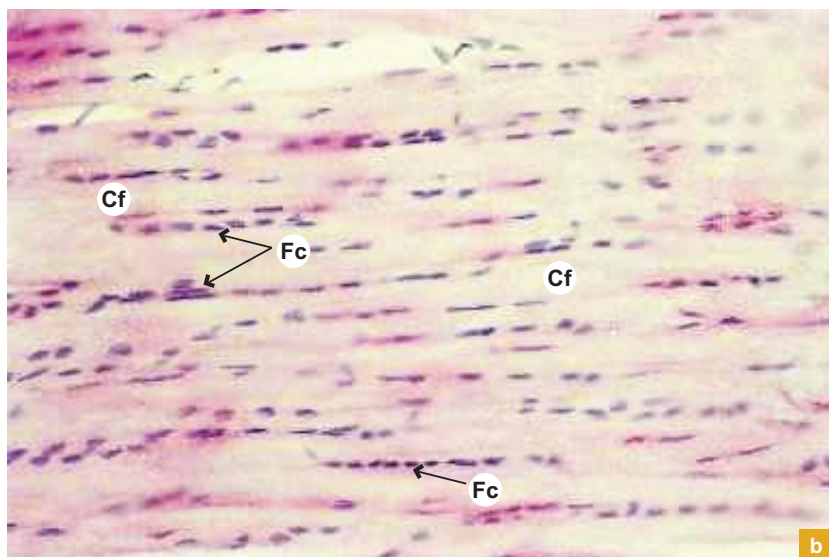
a

**Plate 4:2  
a and b****Dense regular collagenous  
connective tissue (e.g.  
tendon LS).**

Examine the longitudinal section of a tendon at low and high magnifications (Plate 4:2a and b) and note the following features:

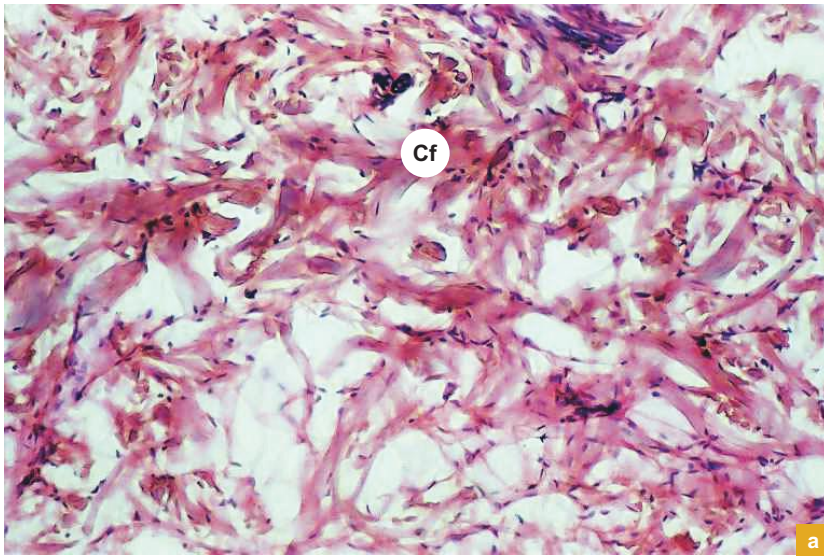
- Bundles of parallel collagen fibres (Cf).
- Rows of tendon cells/fibrocytes (Fc) between the fibre bundles. (Only their flattened nuclei can be made out.)
- Less amount of ground substance (restricted between bundles).

X200



b

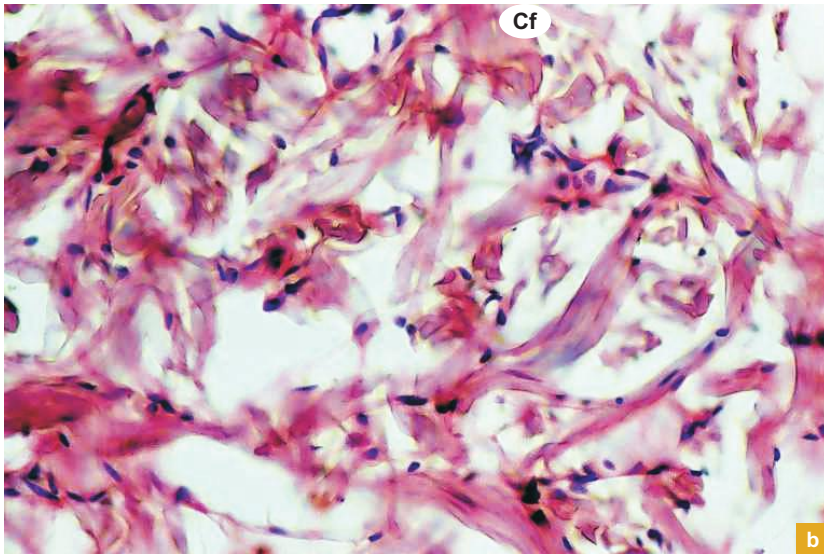
X100

**Plate 4:3  
a and b****Dense Irregular  
collagenous connective  
tissue (e.g. dermis of  
skin).**

Examine the deep reticular layer of the dermis at low and high magnifications (Plate 4:3a and b) and note the following features:

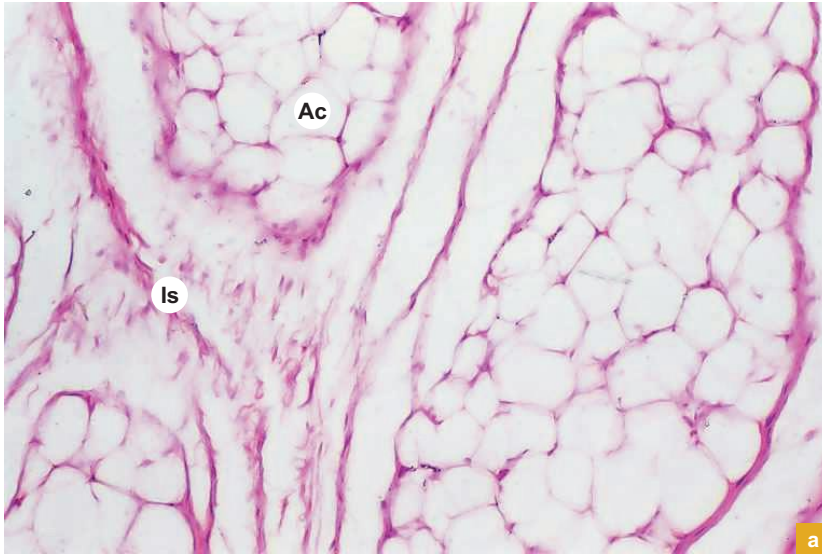
- Compactly packed irregular bundles of collagen fibres (Cf) cut at different planes.
- Thin elastic fibres (refringent).
- Less number of cells.

X200





X100



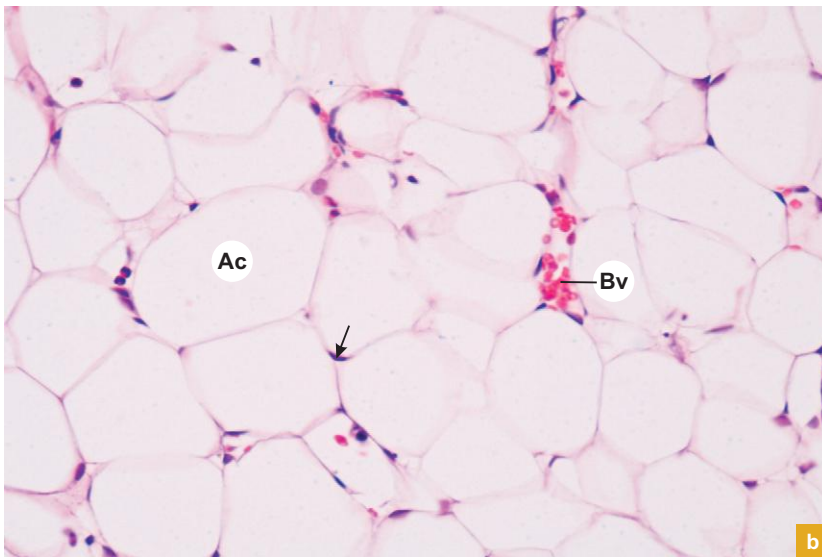
a

**Plate 4:4** Adipose tissue (e.g. hypodermis).  
**a and b**

Examine the subcutaneous fat at low and high magnifications (Plate 4.4a and b) and note the following features:

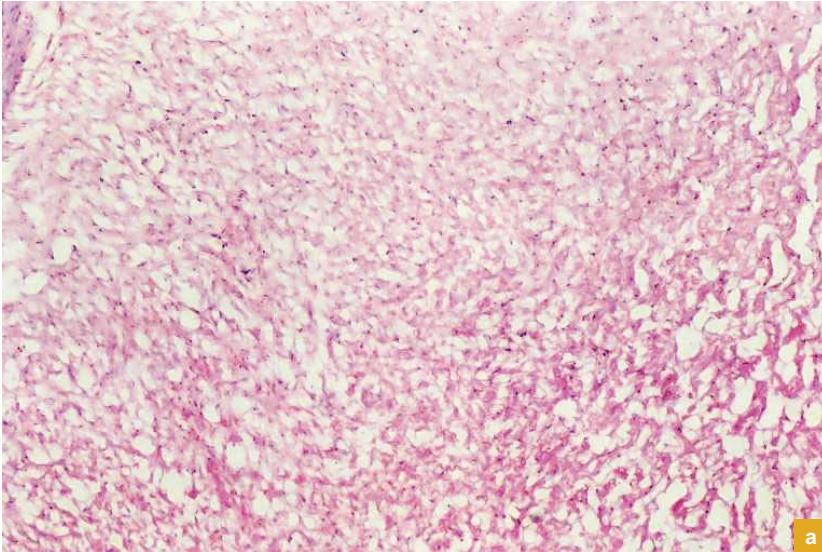
- The compactly packed adipocytes (**Ac**) forming lobules of adipose tissue separated by interlobular septum (**Is**) carrying blood vessels (**Bv**).
- Because of the dissolution of lipid droplets from the adipocytes by xylol during processing of the tissue, these cells appear as empty cells which give a honeycomb appearance to the tissue.
- Each cell has a flat peripheral nucleus (**arrow**) and a thin rim of cytoplasm (signet-ring appearance).

X400



b

X40



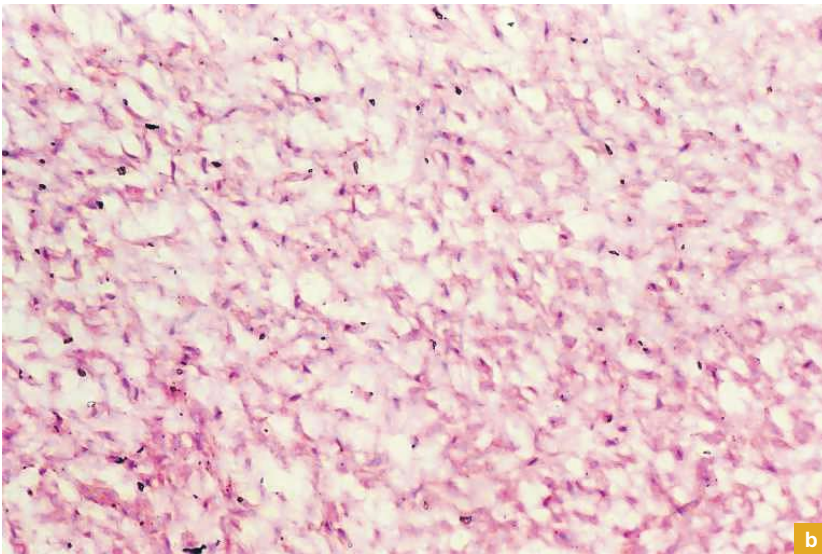
a

**Plate 4:5  
a and b****Mucoid tissue (e.g.  
*Wharton's jelly of  
umbilical cord*).**

Examine the slide at low and high magnifications (Plate 4:5a and b) and note the following features:

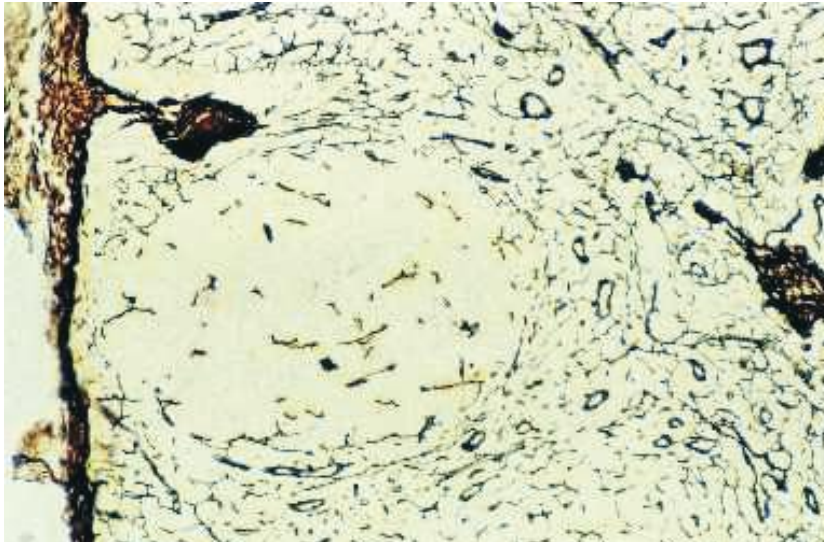
- Large faint background of amorphous ground substance.
- Fine immature widely separated collagen fibres and associated fibroblasts.

X100



b

X100




**Plate 4:6** Reticular Tissue (e.g. stroma of lymphoid organ – special stain).

Examine the stroma of a lymphoid organ specially stained for reticular tissue (Plate 4:6) and note the following features:

- In this preparation the reticular fibres are stained brown to black with silver salts.
- They form a meshwork in which the cellular parenchyma is entangled.

The parenchymatous cells are not visible in this preparation as they are not stained by this method. The reticular fibres are poorly stained with routine haematoxylin and eosin staining, but are stained black with some metallic salts like silver

X100



**Plate 4:7** Elastic tissue (e.g. elastic artery – special stain).

Examine a section of large artery specially stained for elastic fibres (Plate 4:7) and note the following features:

- The elastic fibres are stained brown to black.
- They are found in the middle coat (tunica media) of large artery.

# 5

## CARTILAGE

Cartilage is a firm and flexible type of scleral connective tissue in which the extracellular matrix has a firm consistency.

### GENERAL FEATURES

- Cartilage supports regions of the body that require varying degrees of flexibility.
- It is an avascular structure nourished by diffusion (lives anaerobically by glycolysis).
- No nerves are present (insensitive) in cartilage.
- Regeneration of cartilage is poor. Its damage results in a connective tissue scar.
- It is covered externally by a dense connective tissue sheath known as *perichondrium*, except over articular surface of cartilage in the joint cavities and over fibrocartilage (Fig. 5.1).
- Perichondrium is made up of two layers:
  1. Outer fibrous layer (vascular).
  2. Inner chondrogenic layer (cellular).
- Growth of the cartilage takes place by two mechanisms, viz.,
  1. **Appositional growth:** Differentiation and multiplication of chondrogenic cells in the perichondrium into chondroblast.

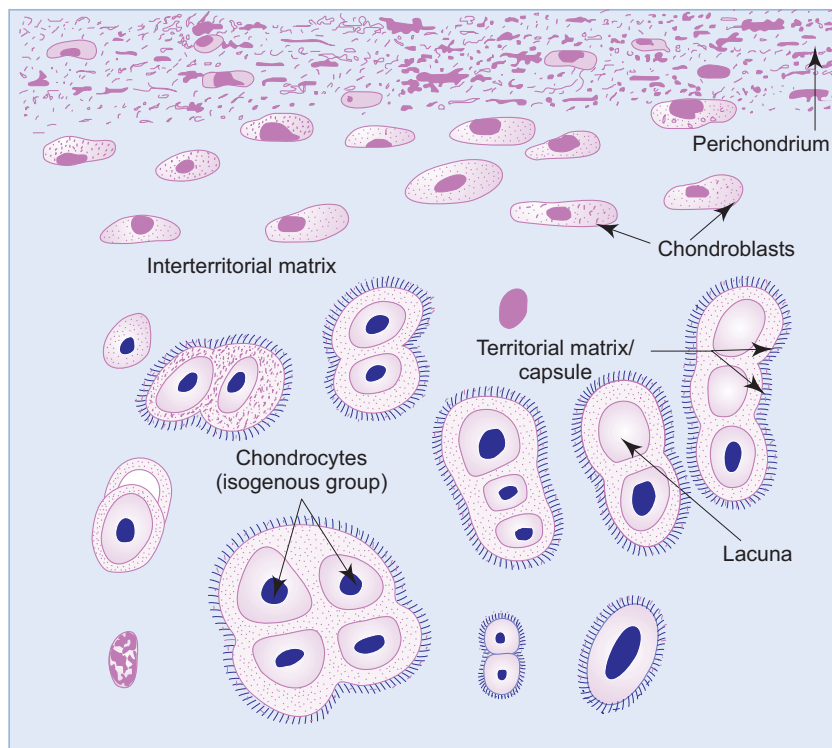


Fig. 5.1 Cartilage.

2. **Interstitial growth:** Multiplication of deeply placed chondrocytes (daughter cells so formed remain in clusters called *isogenous groups*).
- Growth of the cartilage depends mainly on the growth hormone which acts indirectly on it through somatomedin C produced in the liver.

## COMPONENTS

Like ordinary connective tissue cartilage is also made of

- (a) cells – chondrocytes,
- (b) fibres – collagen and elastic, and
- (c) ground substance – acid mucopolysaccharide (chondroitin sulphate).

## Chondrocytes (Fig. 5.1)

- The cells of cartilage are called chondrocytes (40 µm diameter).
- Are derived from mesenchymal cells.
- Are responsible for the production of fibres and ground substance (matrix).
- Are found in *lacunae*.
- Young cells are capable of multiplication.
- Old cells are incapable of multiplication but capable of secreting an enzyme, *alkaline phosphatase*, resulting in calcification of cartilage in old age.

## Fibres

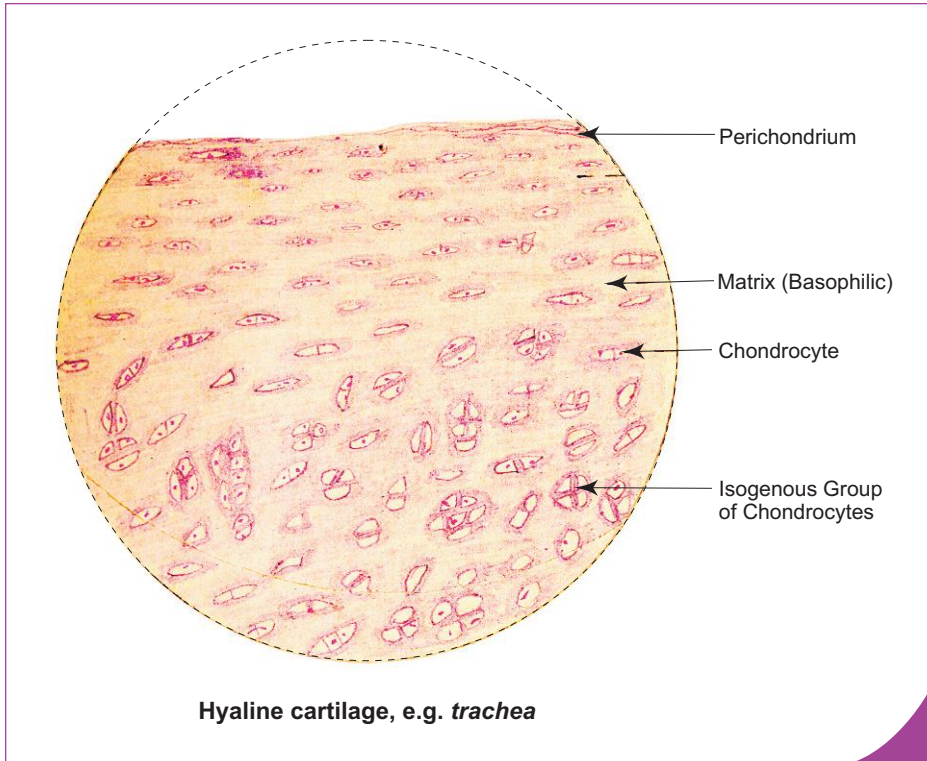
- The fibres embedded in the matrix are either collagenous or elastic. (Refer to chapter 4 for more information.)

## Ground Substance

- Ground substance is basophilic, metachromatic and PAS-positive.
- It is chemically composed of acid mucopolysaccharide (chondroitin sulphate), collagen type II, electrolytes and water.
- The physical property of cartilage mainly depends on the chemical composition of the matrix.
- Matrix can be divided into following two regions:
  1. *Capsule or territorial matrix* (immediately surrounding the cells)—is the newly formed matrix without fibres and is more basophilic.
  2. *Interterritorial matrix* (other areas between the cells)—is the old matrix with fibres and is less basophilic; Fig. 5.1).

## TYPES

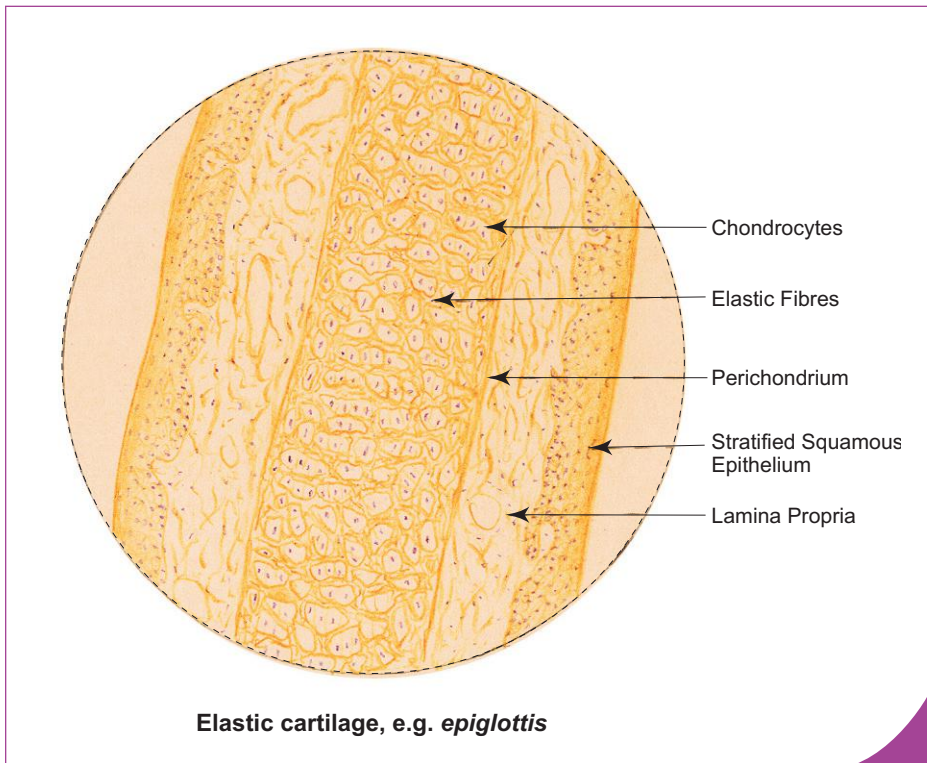
1. **Hyaline cartilage (Box 5.1):** It is characterised by the presence of highly basophilic *homogeneous matrix*. The matrix appears homogeneous because the collagen fibrils present in the matrix have the same refractive index as that of the ground substance. The other features are same as general features of cartilage, e.g. *costal cartilage, tracheal rings, thyroid and cricoid cartilages, articular cartilage, epiphyseal plate*.
2. **Elastic cartilage (Box 5.2):** It is characterised by the presence of *elastic fibres* in the matrix. The elastic fibres are thinner at the periphery and thicker and branching in the interior of the cartilage. Rest of the features are same as general features of cartilage, e.g. *ear pinna, external auditory meatus, auditory tube, epiglottis, corniculate and cuneiform cartilages*.
3. **Fibrocartilage (Box 5.3):** It is characterised by the presence of dense *bundles of collagen fibres* oriented in the direction of functional stress with *rows of chondrocytes* between the bundles. This cartilage does not have a perichondrium, e.g. *intervertebral disc, labrum glenoidale and labrum acetabulare*.



**Box 5.1 Hyaline Cartilage.**

Presence of

- (i) **homogeneous basophilic matrix** (territorial and interterritorial matrix);
- (ii) isogenous groups (**cell nests**) of chondrocytes;
- (iii) perichondrium covering the cartilage.



**Box 5.2 Elastic Cartilage.**

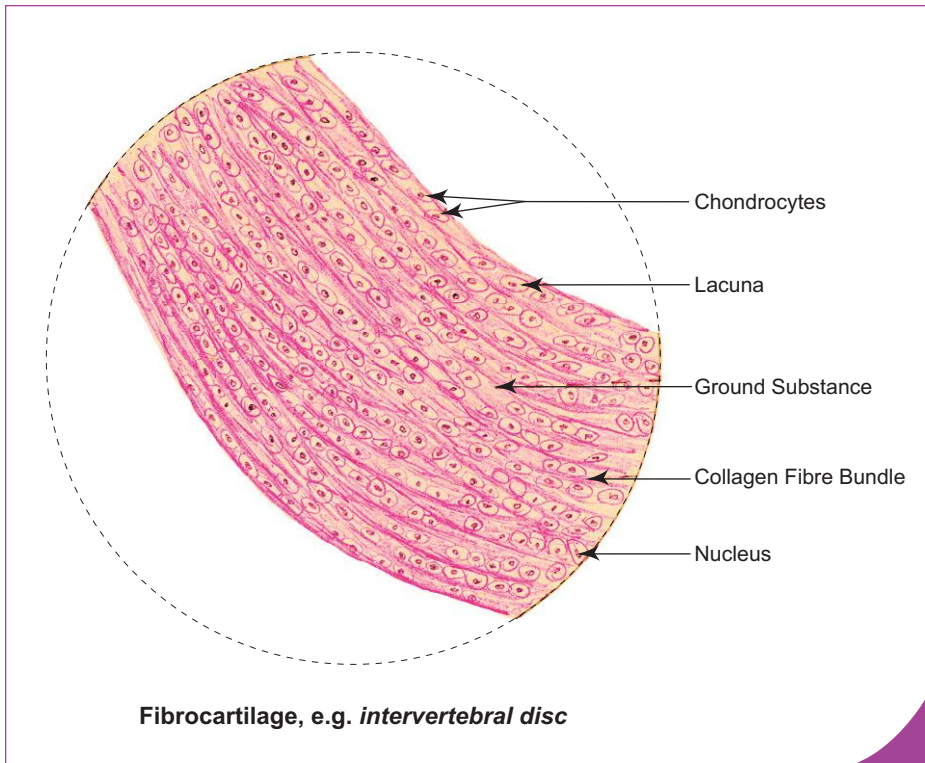
Presence of

- (i) **elastic fibres** in the matrix (non-homogeneous);
- (ii) closely packed **chondrocytes with eccentric nuclei**;
- (iii) perichondrium covering the cartilage.

**Box 5.3 Fibrocartilage.**

*Presence of*

- (i) dense bundles of collagen fibres;
- (ii) **chain of chondrocytes** (of similar size) between the collagen bundles;
- (iii) **absence of perichondrium.**



**FUNCTIONS**

- Supports soft tissues.
- Provides gliding area for the joint, facilitating movements (only of hyaline cartilage).
- Essential for growth of long bones (only of hyaline cartilage).

# Self-assessment Exercise

## I. Write Short notes on:

- (a) Hyaline cartilage
- (b) Elastic cartilage
- (c) Fibrocartilage

## II. Fill in the blanks:

1. The fibrous membrane that covers the cartilage is called \_\_\_\_\_
2. The newly formed extracellular matrix that surrounds the chondrocytes is called \_\_\_\_\_
3. Mature chondrocytes are capable of producing the enzyme \_\_\_\_\_
4. Growth of the cartilage takes place by these two mechanisms: \_\_\_\_\_ and \_\_\_\_\_

## III. Choose the best answer:

1. A section of hyaline cartilage can be identified by the presence of
  - (a) homogeneous matrix
  - (b) elastic fibres
  - (c) collagen fibres
  - (d) chondrocytes arranged in row
2. Elastic cartilage is present in
  - (a) tracheal ring
  - (b) epiglottis
  - (c) intervertebral disc
  - (d) costal cartilage
3. Perichondrium is absent in
  - (a) elastic cartilage and hyaline cartilage
  - (b) hyaline cartilage and cellular cartilage
  - (c) fibrocartilage and articular cartilage
  - (d) costal cartilage and ear pinna
4. Which of the following features is *not true* about cartilage?
  - (a) Firm and flexible
  - (b) Highly vascular
  - (c) Insensitive
  - (d) Poor in regeneration
5. Chondrocytes are
  - (a) derived from monocyte
  - (b) involved in phagocytosis
  - (c) polyhedral in shape
  - (d) found in lacunae



**IV. State whether the following statements are true (T) or false (F):**

1. Chondrocytes are found in lacunae ()
2. Cartilage has good regenerative capacity because of high vascularity ()
3. Chondrocytes secrete acid phosphatase ()
4. Hyaline cartilage is characterised by the presence of basophilic homogeneous matrix ()
5. Most of the long bones are formed from cartilage ()

**V. Match the items of column 'A' with those of column 'B':**

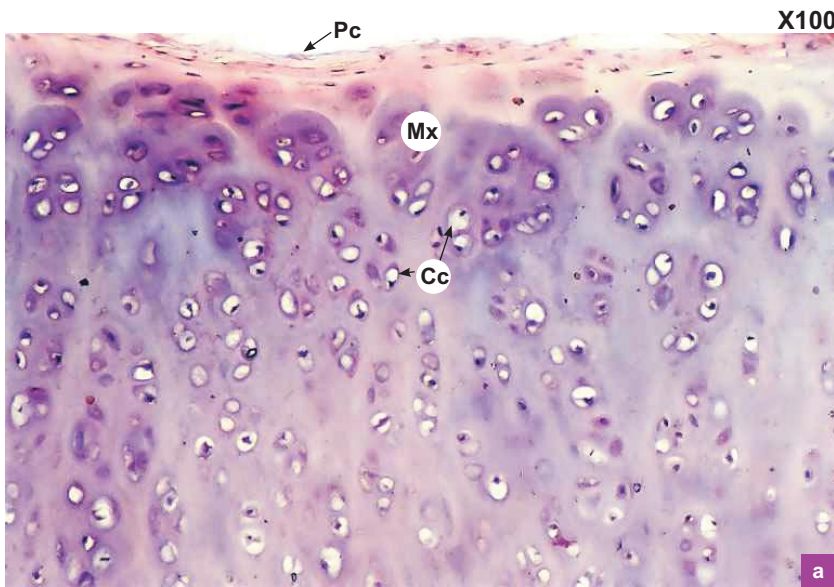
Column 'A'		Column 'B'
1. Hyaline cartilage	()	(a) Ear pinna
2. Elastic cartilage	()	(b) Isogenous group of chondrocytes
3. Fibrocartilage	()	(c) Costal cartilage
4. Cell nest	()	(d) Territorial matrix
5. Capsule	()	(e) Intervertebral disc

**Answers**

- II.** 1. Perichondrium                      2. Capsule or territorial matrix                      3. Alkaline phosphatase  
4. Appositional growth and interstitial growth
- III.** 1. a    2. b    3. c    4. b    5. d
- IV.** 1. (T)   2. (F)   3. (F)   4. (T)   5. (T)
- V.** 1. c    2. a    3. e    4. b    5. d

# Practical No. 5

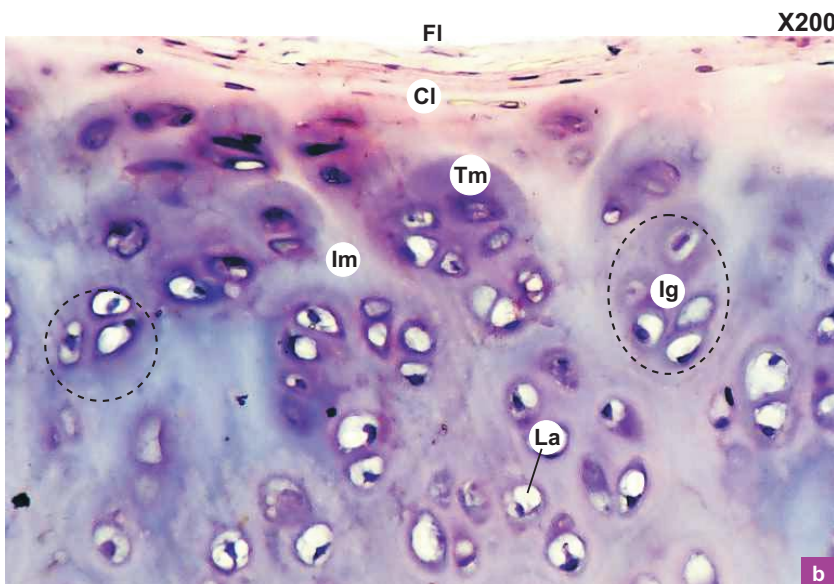
## Connective Tissue II: Cartilage



**Plate 5.1a** Hyaline cartilage  
(e.g. tracheal ring).

Examine the hyaline cartilage under low power (Plate 5.1a) and note the following structures:

- Perichondrial (Pc) covering on surface.
- Homogeneous basophilic matrix (Mx).
- Chondrocytes (Cc) embedded in matrix.

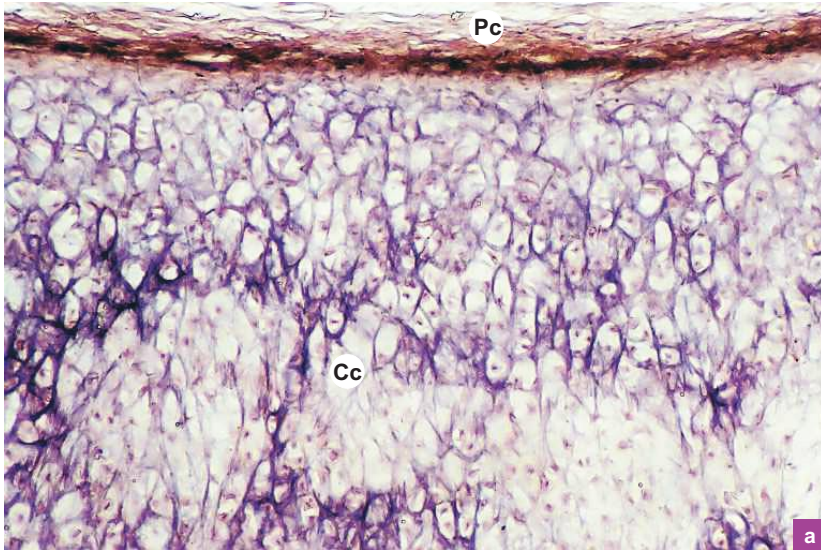


**Plate 5.1b** Hyaline cartilage  
(e.g. tracheal ring).

Examine the same cartilage under high power (Plate 5.1b) and note the following structures:

- Two layers of perichondrium—  
(a) outer fibrous layer (Fl), and  
(b) inner chondrogenic layer (Cl).
- Elliptical young chondrocytes—found immediately beneath the perichondrium.
- Large rounded, semicircular or angular old chondrocytes—found in clusters *isogenous groups* (Ig) in the deeper part of the cartilage.
- Space around each cell is the lacuna (La)—which becomes visible due to shrinkage of the cell.
- Deeply stained (more basophilic) matrix surrounding the cells in the lacunae forming the capsular or territorial matrix (Tm) and less basophilic interterritorial matrix (Im).
- Matrix—appears to be *homogeneous* because the collagen fibrils have the same refractive index as the ground substance.

X100



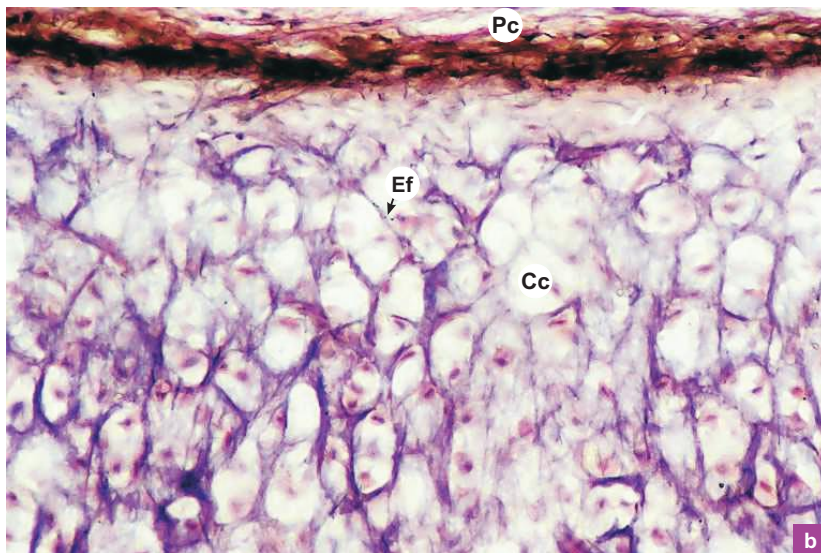
a

**Plate 5.2** Elastic cartilage (e.g. epiglottis).  
**a and b**

Examine the elastic cartilage under low power (Plate 5.2a) and high power (Plate 5.2b) and note the following structures:

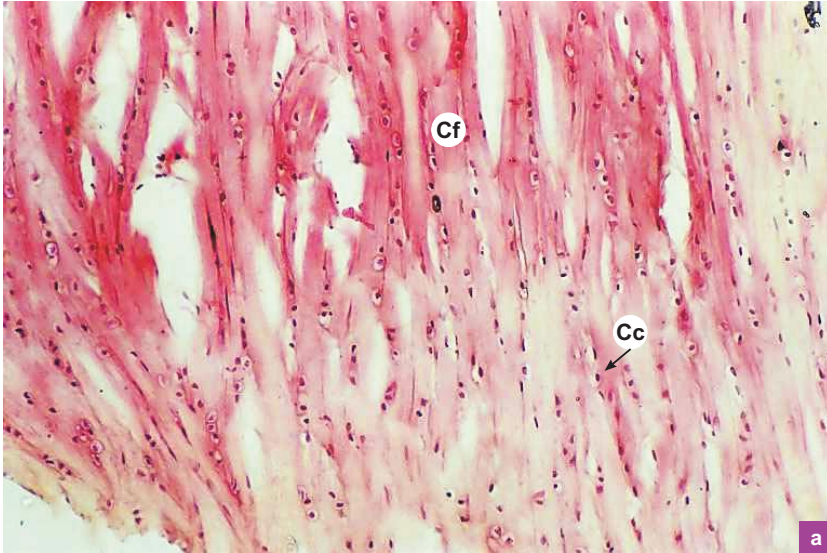
- The cartilage exhibits all the features of the hyaline cartilage except for the presence of *elastic fibres* (Ef; brown to black) in its matrix.
- The elastic fibres are thinner at the periphery and thicker and branching in the interior.
- Note the eccentrically placed nuclei of the *chondrocytes* (Cc).
- Note the perichondrium (Pc) on the surface.

X200



b

X100



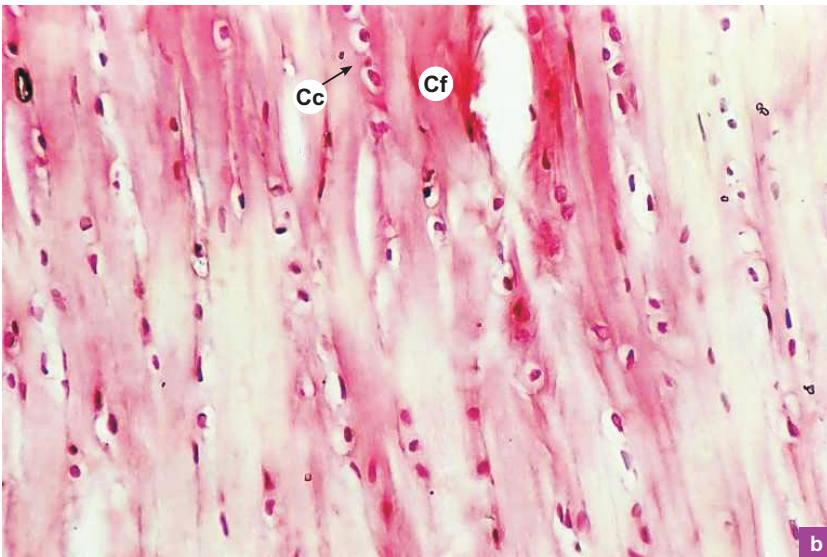
a

**Plate 5.3** Fibrocartilage  
(e.g. *intervertebral disc*).

Examine the fibrocartilage under low power (Plate 5.3a) and high power (Plate 5.3b) and note the following structures:

- Note the dense bundles of *collagen fibres* (Cf). (They are oriented in the direction of functional stress.)
- *Chondrocytes* (Cc) are distributed in rows between the bundles of collagen fibres (all the chondrocytes are small and of the same size).
- *No perichondrium*.
- *Compare this slide with the longitudinal section of tendon* (Plate 4:2a and b).

X200



b

"This page intentionally left blank"

# 6

# BONE

Bone is a rigid form of scleral connective tissue in which the extracellular matrix is impregnated with inorganic salts, mainly calcium phosphate and carbonate, providing hardness.

## GENERAL FEATURES

- Unlike ordinary connective tissue, bone is rigid and hard because the matrix is infiltrated with inorganic salts.
- Bone gives attachment to muscles and serves as a lever for muscular action.
- It bears body weight.
- It protects vital organs like brain, heart and lungs.
- Bone stores calcium, phosphate and other ions.
- It contains bone marrow, which is a haemopoietic tissue.

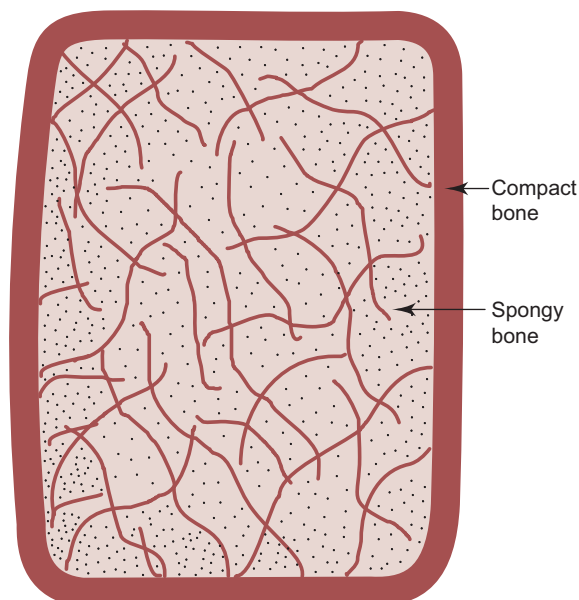
## TYPES OF BONE

*Morphologically*, bone consists of:

1. Externally, a solid shell of cortical bone called *compact* bone (found in shell of short bones, shaft of long bones and tables of flat bones).
2. Internally, a framework of trabeculae separated by marrow spaces called *spongy* or *cancellous* bone (found in short bones [Fig. 6.1], ends of long bones and diploë of flat bones).

*Microscopically*, compact bone consists of:

1. *Primary/immature/woven bone*—newly formed bone during growth and repair with low mineral content, e.g. callus.
2. *Secondary/mature/lamellar bone*—definite adult type after remodelling.



**Fig. 6.1** T.S. of short bone.

## BONE MEMBRANES

- The external and internal surfaces of bones are covered by membranes called periosteum and endosteum respectively.
  - They have osteogenic potential and are essential for growth and repair.
- 1. Periosteum**
    - It is a dense connective tissue membrane covering the external surface of bone, except on articular surfaces, sesamoid bones and at the attachments of tendons and ligaments.
    - Periosteum sends perforating fibres perpendicular to the bone surface to nail or anchor it to the cortical bone. These fibres are called *Sharpey's fibres*.
    - Periosteum also has two layers like perichondrium:
      - (a) Outer vascular fibrous layer.
      - (b) Inner cellular osteogenic layer.
    - It has rich nerve supply and is very sensitive.
    - It is involved in bone growth and repair and, therefore, care should be taken to preserve it during bone surgery.
  - 2. Endosteum**
    - It is a thin membrane of vascular loose connective tissue lining the medullary cavity in the long bones and marrow spaces in the cancellous bones. It extends as a lining into the canal system of a compact bone.
    - Cells of endosteum have osteogenic potential, i.e. they can differentiate into bone forming cells (osteoblasts) during repair and growth. So this layer should also be preserved during bone surgery.

## BONE COMPOSITION

- Like any other connective tissue, bone is made of cells, fibres and ground substance. In addition, its extracellular matrix is infiltrated with inorganic salts like calcium phosphate and calcium carbonate to provide hardness and rigidity.
- The mineral salts (calcium and phosphorus) form needle-like crystals of hydroxyapatite  $[\text{Ca}_{10}(\text{PO}_4)_6(\text{OH})_2]$ , which are 20–40 nm in length. The needles are arranged parallel to collagen fibres and partly within them.
- The organic components (collagen fibres and ground substance) give plasticity to bone, allowing it to remodel according to the functional demands placed upon it (orthodontic tooth movement).

### 1. Cells

- These are of the following types:
    - (a) Osteoprogenitor cells: They are young pluripotential cells derived from mesenchymal cells. They differentiate into osteoblasts and found along the blood vessels in the periosteal buds and in the endosteum.
    - (b) Osteoblasts
    - (c) Osteocytes
    - (d) Osteoclasts
- } See Table 6.1.

### 2. Fibres (95%)

- These are constituted of collagen fibrils which are composed of type I collagen.

### 3. Ground substance (5%)

- This is made of chondroitin sulphate, dermatan sulphate and a specific glycoprotein.
- The fibres and ground substance form the organic component of bone, which give elasticity and resilience.

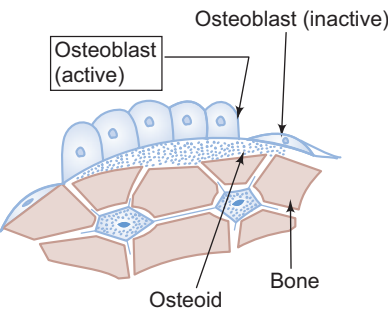
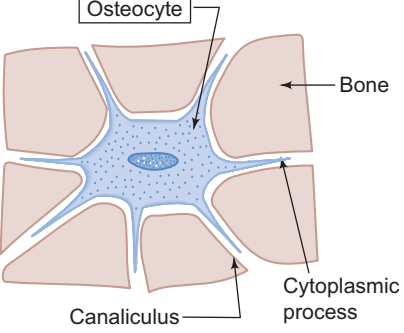
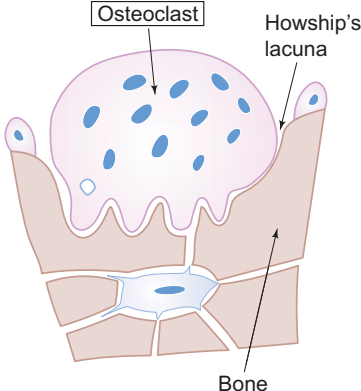
### 4. Inorganic components (Bone salts/Hydroxyapatite)

- These include:
  - (a) Calcium phosphate (85%).
  - (b) Calcium carbonate (10%).
  - (c) Other salts (5%).
- These inorganic components are deposited on and around collagen fibrils, which give hardness and rigidity to the bone.

## Decalcification

- It is the process of removal of inorganic components. As a result the bone becomes soft and flexible.

**Table 6.1** Bone cells (comparison)

	Osteoblasts	Osteocytes	Osteoclasts
<i>Diagram</i>			
<i>Function</i>	Bone former	Bone maintainer	Bone destroyer (resorption)
<i>Shape</i>	Young cells – cuboidal in shape	Mature cells – oval in shape with many cytoplasmic processes	Large irregular giant cells
<i>Cytoplasm</i>	Basophilic cytoplasm	Less basophilic cytoplasm	Acidophilic cytoplasm
<i>Nucleus</i>	Single, large, round euchromatic nucleus	Single, small elongated heterochromatic nucleus	Many nuclei (5–50)
<i>Location</i>	Found on the surface of bone	Found embedded in the bony matrix surrounded by lacuna and canaliculi	Found on the surface of the bone in Howship's lacuna
<i>Histochemical reaction</i>	Alkaline phosphatase activity – positive		Acid phosphatase activity – positive
<i>Electron microscopic structure</i>	More rough endoplasmic reticulum	Less rough endoplasmic reticulum	Abundant mitochondria and lysosomes
<i>Origin</i>	Derived from osteoprogenitor cells	Derived from osteoblasts	Derived from blood monocytes. Shows phagocytic activity

## Calcination

- It is the process of removal of organic components. As a result the bone becomes brittle and fragile.

## STRUCTURE OF COMPACT BONE

- Compact bone consists of three systems (sets) of bony lamellae arranged in an orderly manner:
  1. Circumferential system
    - Outer (periosteal)
    - Inner (endosteal)
  2. Haversian system or osteon
  3. Interstitial system

### Circumferential System (Fig. 6.2)

- Outer circumferential system consists of circular lamellae of bony matrix that lie immediately beneath the periosteum.
- Inner circumferential system also consists of circular lamellae of bony matrix that lie adjacent to the endosteum.
- Osteocytes are found between the lamellae in the lacunae.
- Both circumferential systems have the marrow cavity as the centre.
- The outer system has more lamellae than the inner system.
- Between the two circumferential systems are numerous Haversian and interstitial systems.



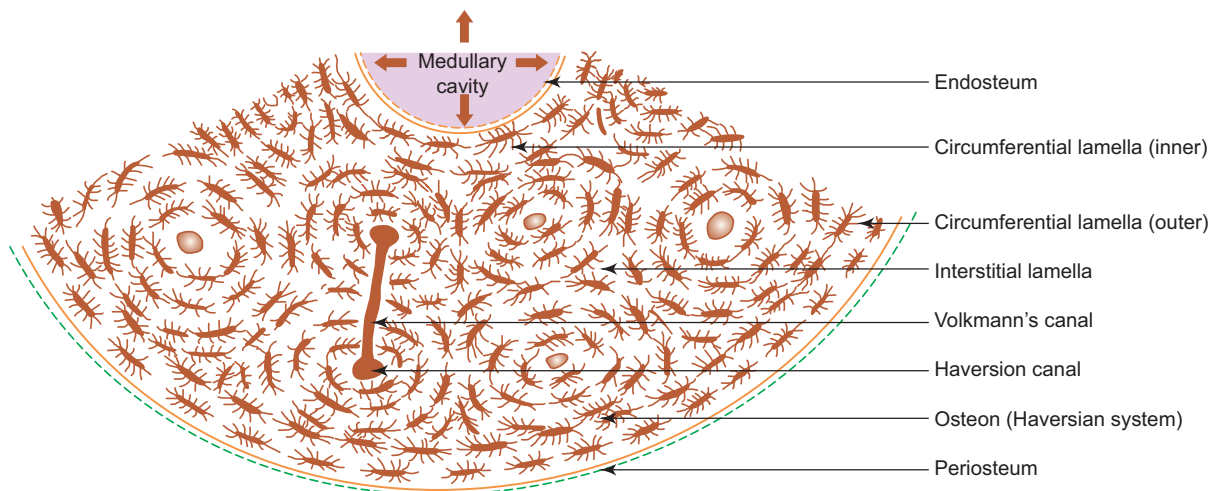


Fig. 6.2 Cross section of compact bone.

### Haversian System or Osteon (Fig. 6.3; Boxes 6.1 and 6.2)

- Haversian systems are found between the outer and inner circumferential systems of compact bone.
- They are long cylindrical, often branching principal structural units of compact bone.
- They lie parallel to the long axis of the shaft.
- Each system consists of a central canal, *Haversian canal*, surrounded by 4–20 concentric lamellae of bony matrix.
- The Haversian canal is lined by endosteum whose cells have osteogenic potential (osteoprogenitor cells).
- The canal contains blood vessels, nerves, lymphatics and loose connective tissue.
- The Haversian canals communicate with each other, with the periosteum and with the internal medullary cavity through transverse/oblique channels called *Volkmann's canals*. These canals are not surrounded by concentric bony lamellae. Instead they penetrate through the lamellae of Haversian system (Fig. 6.2).
- Each Haversian system is formed by successive deposition of bony lamellae around the neurovascular structures in the canal from the periphery inwards. So the diameter of Haversian canal is highly variable. The younger system has a larger canal, whereas the older one has a smaller canal and the most recently formed lamella is closest to the canal.
- The lamella contains collagen fibres which run in a spiral manner parallel to each other. However, they run at right angle to those lamellae on either side of it. This arrangement of fibres gives maximum rigidity and strength.
- Osteocytes are seen between lamellae in elliptical lacunae (Box 6.2).
- Many tiny canals called canaliculi radiate from the lacunae and anastomose freely with those of other lacunae and Haversian canal. These canaliculi contain filopodial processes of osteocytes and come into contact with the filopodial processes of neighbouring osteocytes. Thus, a system of complex communicating canaliculi is formed throughout the bony lamellae with communication with the vascular connective tissue of the Haversian canal, medullary cavity and periosteum. This arrangement helps to keep even the far off osteocytes alive.

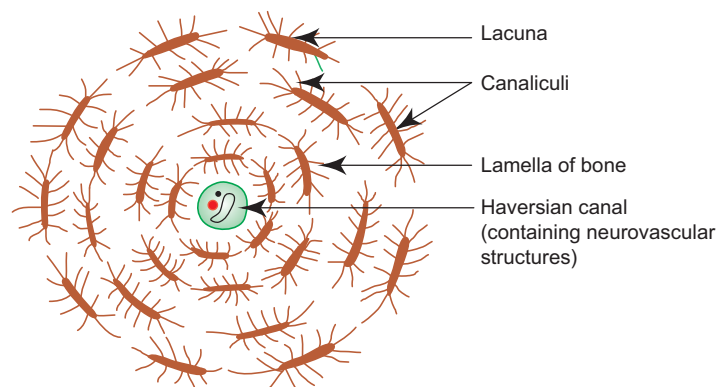
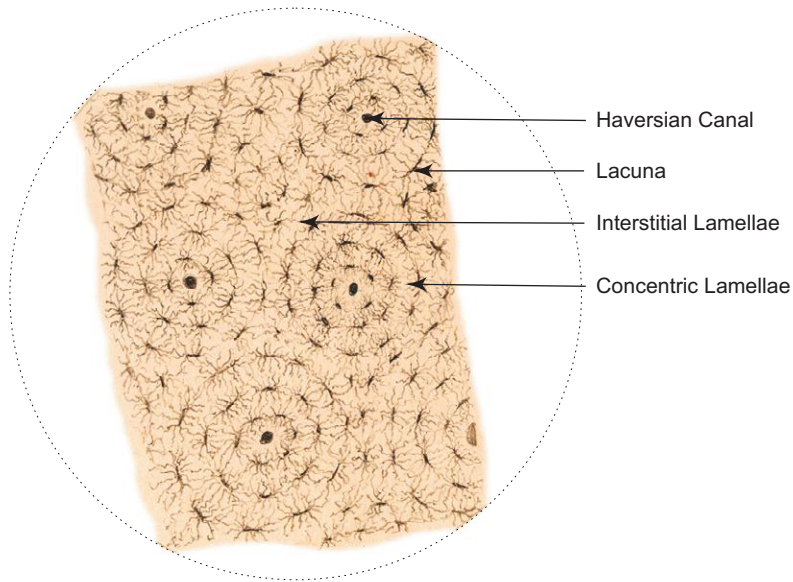


Fig. 6.3 Cross section of an osteon or Haversian system.

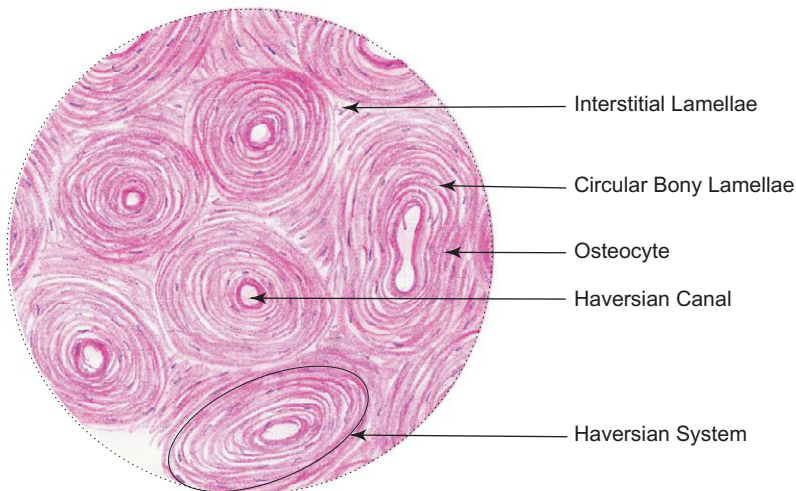


Compact bone, C.S. (Ground section)

**Box 6.1 Compact Bone – C.S. (Ground Section).**

Presence of

- (i) **Haversian systems** with Haversian canals and **concentric lamellae of bone matrix**;
- (ii) interstitial lamellae;
- (iii) lacunae and radiating canaliculi;
- (iv) Volkmann's canal.



Compact bone, C.S. (Decalcified section)

**Box 6.2 Compact Bone – C.S. (Decalcified Section).**

Presence of

- (i) **Haversian systems** with Haversian canals and **concentric lamellae of bone matrix**;
- (ii) interstitial lamellae;
- (iii) **osteocytes** between lamellae of bone.

Throughout life there is continuous destruction and rebuilding of Haversian system.

### Interstitial System

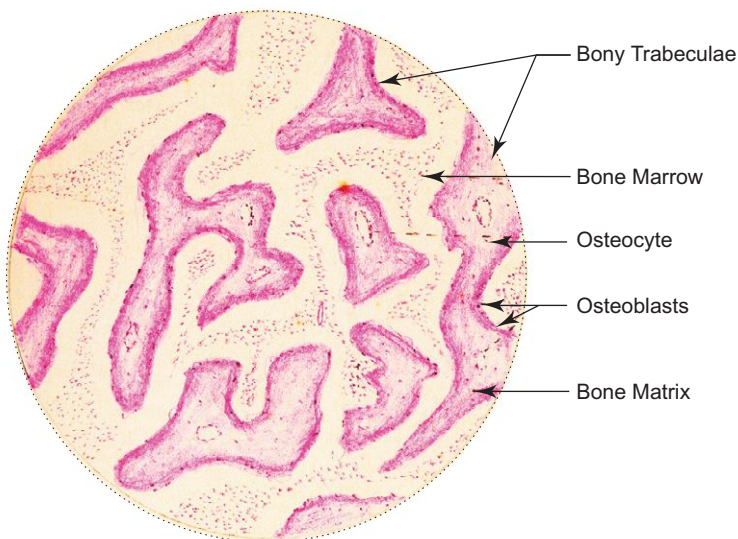
- Found occupying triangular intervals between Haversian systems.
- Formed of irregularly shaped groups of parallel lamellae.
- They are surviving remnants (fragments) of earlier Haversian systems which were destroyed during growth and remodeling of bone.

### STRUCTURE OF SPONGY OR CANCELLOUS BONE (BOX 6.3)

- Spongy bone is made of slender *bony trabeculae* that branch and anastomose with one another enclosing irregular *marrow spaces* between them which contain *bone marrow*.
- These trabeculae exhibit parallel lamellae of bony matrix and osteocytes in lacunae in between.
- The trabeculae are covered externally by vascular endosteum containing osteoprogenitor cells, osteoblasts and osteoclasts.

### BONE FORMATION/OSSIFICATION

- Ossification is the process by which bone is formed from a soft tissue model (condensed mesenchyme or hyaline cartilage model).
- This process usually starts at the centre of the model, from which it spreads until the whole model is converted into bone.
- Bones are formed by two methods, namely,
  1. *Intramembranous ossification*, i.e. bone formation from condensed mesenchyme—membrane model. e.g. *Flat bones* in the vault of skull, *clavicle*.
  2. *Endochondral ossification*, i.e. bone formation from cartilage—cartilage model. e.g. *Long bones* except *clavicle*.



Spongy or cancellous bone (Decalcified section)

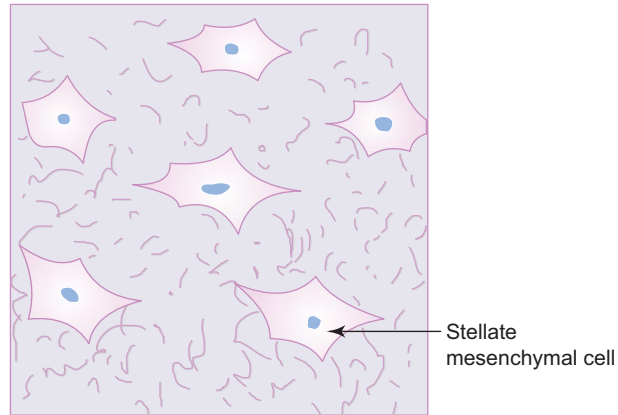
#### Box 6.3 Spongy or Cancellous Bone (Decalcified Section).

- presence of bony **trabeculae** separated by **marrow space** containing **bone marrow**;
- absence of Haversian** systems and lamellar arrangement;
- presence of osteoblasts and osteoclasts on the surface of bony trabeculae;
- osteocytes are seen embedded in the matrix of the trabeculae.

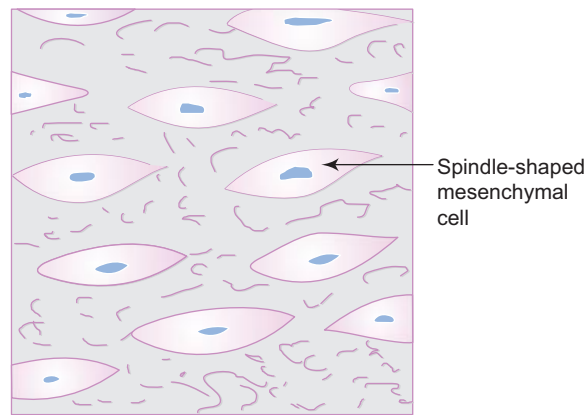
## Intramembranous Ossification

### Stage I: Condensation of mesenchyme

- Condensation of loose mesenchyme occurs in the area where bone formation is to take place.
- Here stellate mesenchymal cells (Fig. 6.4) become spindle-shaped cells (Fig. 6.5).



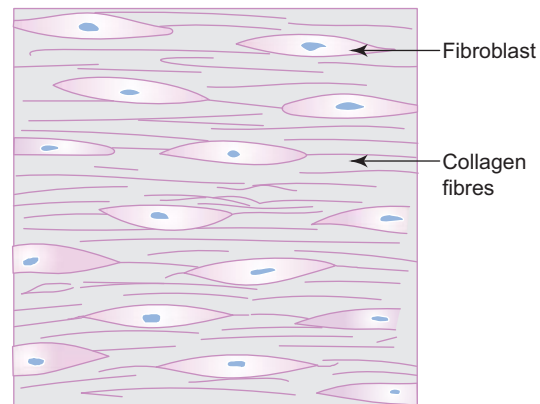
**Fig. 6.4** Loose mesenchymal tissue.



**Fig. 6.5** Condensed mesenchymal tissue.

### Stage II: Formation of membrane

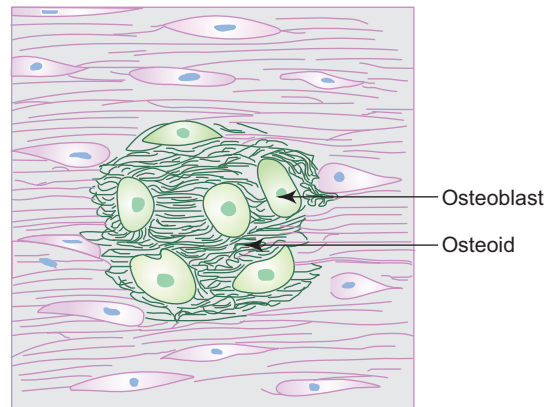
- The spindle-shaped mesenchymal cells differentiate into fibroblasts and begin to lay down collagen fibres and the area resembles a fibrous membrane (Fig. 6.6).



**Fig. 6.6** Fibrous membrane.

**Stage III: Differentiation of osteoblasts and formation of osteoid**

- The fibroblasts become differentiated into round osteoblasts and start laying down bone matrix which is uncalcified and is known as *osteoid* (Fig. 6.7).



**Fig. 6.7** Formation of osteoid and centre of ossification.

**Stage IV: Formation of calcified matrix and establishment of centre of ossification**

- The osteoblasts now start secreting alkaline phosphatase resulting in deposition of calcium salts as crystals of hydroxyapatite in osteoid converting it into calcified bone matrix.
- In this process some osteoblasts get trapped within the matrix and become osteocytes. The space in which osteocyte lies is called *lacuna*.
- The bone matrix extends in all directions within the membrane as bony spicules at the site of ossification.
- Several such sites arise simultaneously at the ossification centre and fusion of spicules gives the spongy structure.

**Stage V: Formation of Periosteum and endosteum**

- The vascular mesenchyme around the newly formed spongy bone condenses to form periosteum on the outer surface and endosteum on the inner surface.
- The osteogenic cells in the periosteum and endosteum differentiate into osteoblasts and start laying down bone matrix in the form of parallel lamellae of outer and inner tables of compact bony shell.

As the child grows, the shape and size of the bone is continuously being changed by osteoclasts (resorption) and osteoblasts (deposition). This process is called *remodeling*.

In infants the fontanelles are soft areas in the skull which correspond to the unossified part of the fibrous membrane.

**Endochondral Ossification**

- The long and short bones of the body, except clavicle, are formed by endochondral ossification.

**Stage I: Formation of mesenchymal model**

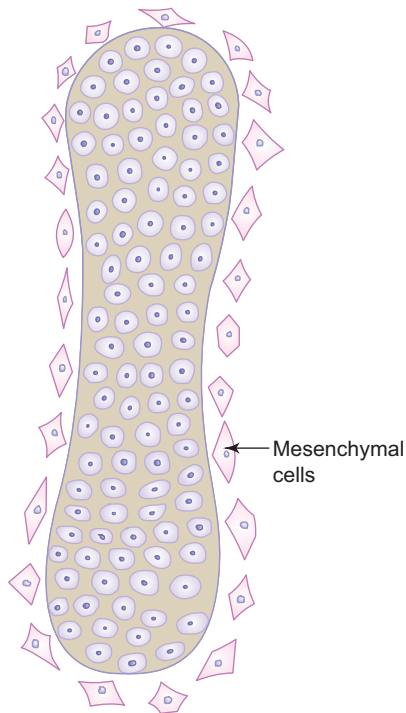
- The stellate mesenchymal cells become rounded and condensed in the area where long bone is to be formed (Fig. 6.8).

**Stage II: Formation of cartilage model**

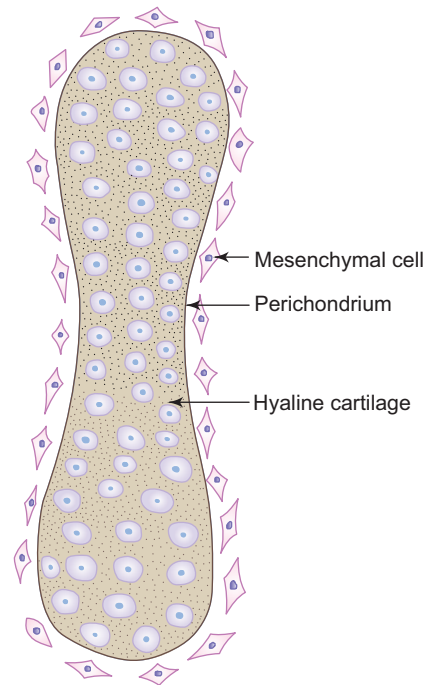
- The rounded mesenchymal cells become differentiated into chondroblasts and start laying down cartilage matrix. Perichondrium is also formed around the cartilage.
- Thus a model of hyaline cartilage is formed replacing the mesenchymal model (Fig. 6.9).

**Stage III: Appearance of primary centre of ossification and formation of diaphysis**

- During the 8th week of intrauterine life, primary centre of ossification begins in the middle of the cartilagenous shaft.



**Fig. 6.8** Mesenchymal model.



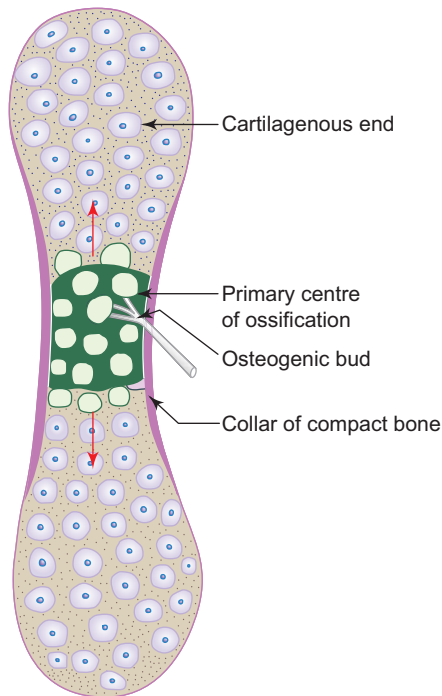
**Fig. 6.9** Cartilage model.

- The cartilage cells in this region increase in size (hypertrophy) and secrete alkaline phosphatase resulting in deposition of calcium salts in the intercellular matrix.
- Calcified matrix prevents diffusion of nutrients to the cells and as a result the hypertrophied chondrocytes die and disappear leaving behind empty lacunae called *areolae*.
- Meanwhile, on the surface, by means of intramembranous ossification within the perichondrium, osteoblasts differentiate and start laying down a collar of compact bone covered by periosteum. This subperiosteal collar of compact bone supports and strengthens the weak middle region of the shaft caused due to death of chondrocytes.
- A bud of vascular tissue derived from periosteum on the surface now grows towards the weak middle region. This bud is called *osteogenic* or *periosteal bud*, which carries along with it capillaries, osteoprogenitor cells, osteoblasts, osteoclasts, etc. (Fig. 6.10).
- The septae of calcified cartilage matrix between the areolae serve as support for laying down bone by the osteoblasts brought about by the periosteal bud.
- By the action of osteoblasts and osteoclasts spongy bone is formed in the centre of the shaft surrounded by periosteal collar of the compact bone (Fig. 6.10).
- Resorption of bone by osteoclasts occur at the centre resulting in formation of marrow cavity.
- The primary centre of ossification is now established in the centre of the shaft of the cartilaginous model.
- Diaphysis (shaft) is formed from the primary centre of ossification.

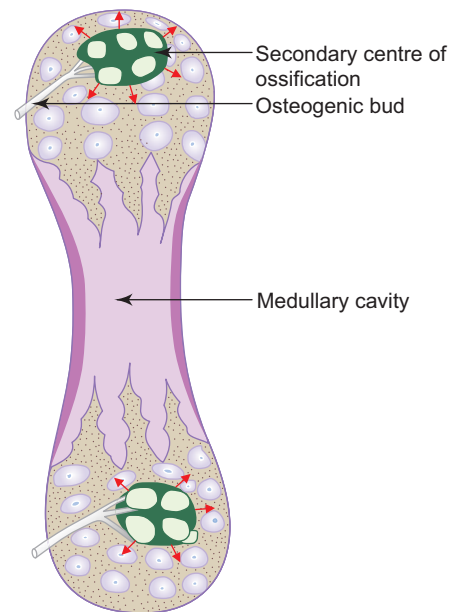
As the cartilaginous model continues to grow by proliferation of chondrocytes, the ossification extends towards each end of the model from the centre of the shaft.

#### **Stage IV: Appearance of secondary centres of ossification and formation of epiphysis**

- Secondary centres occur at the ends of the long bone after birth (except lower end of femur and upper end of tibia). The formation of secondary centre is similar to that of primary centre but its growth is radial (Fig. 6.11) instead of longitudinal. Furthermore, since the articular cartilage has no perichondrium, the equivalent of a bone collar is not formed here.
- Epiphysis is formed from the secondary centre of ossification.



**Fig. 6.10** Appearance of primary centre of ossification. (Arrows indicate the direction of spread of ossification.)



**Fig. 6.11** Appearance of secondary centres of ossification. (Arrows indicate the direction of spread of ossification.)

#### Stage V: Fusion of epiphysis with diaphysis

- Cartilage remains restricted to two places, namely, articular cartilage and epiphyseal plate.
- The articular cartilage remains cartilaginous throughout life at the ends of the bone, forming a smooth gliding surface for the synovial joints.
- The epiphyseal plate that intervenes between diaphysis and epiphysis continues to grow in length (thickness). At the same time conversion of cartilage into bone takes place at the diaphyseal surface of the cartilage. This surface of the epiphyseal cartilage shows five zones as described in the Practical No. 6 (Plate 6.5c).
- In the race between cartilage formation and bone formation at the epiphyseal plate, bone formation overtakes resulting in fusion of epiphysis and diaphysis (synostosis).

Features of a growing long bone are shown in Box 6.4.

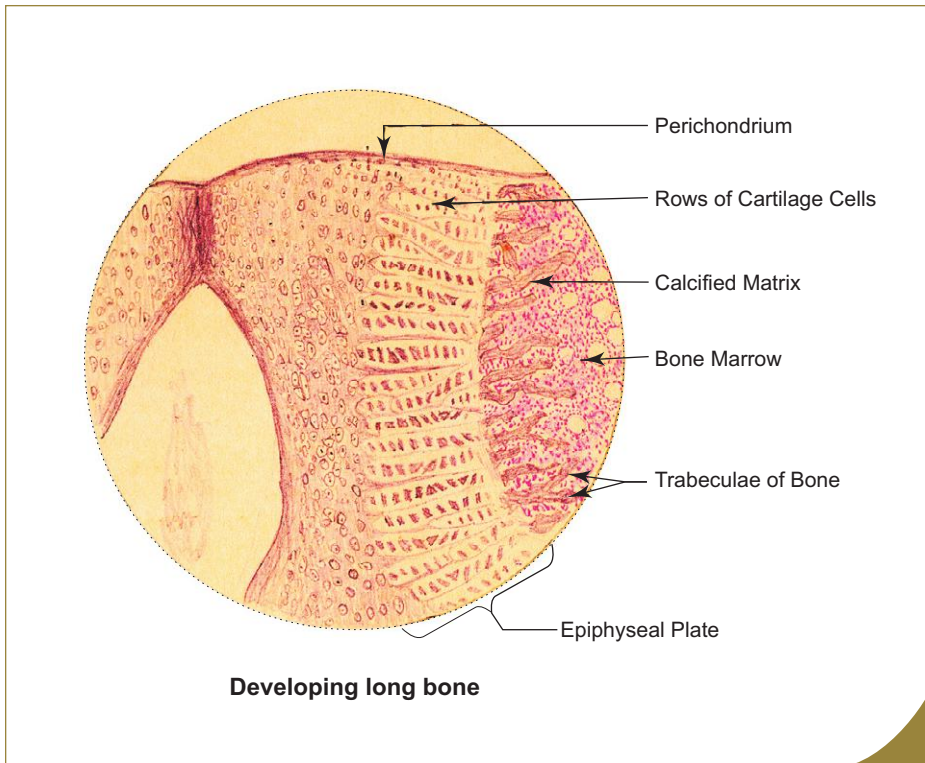
### Role of Vitamins in Bone Formation

- For normal development and maintenance of bone adequate intake of vitamins and minerals in the diet is necessary.
- The following vitamins are essential for normal bone growth:
  - 1. Vitamin D**
    - Necessary for absorption of calcium from small intestine.
    - Deficiency
      - in children → *rickets*, which is characterised by bowing of long bones due to loss of rigidity and hardness in the weight-bearing bones.
      - in adults → *osteomalacia*, which also causes softening of bone due to deficient calcification of matrix.
  - 2. Vitamin C**
    - Necessary for collagen synthesis.
    - Deficiency → *scurvy*, in which the compact and spongy bones are friable with subperiosteal bleeding.
  - 3. Vitamin A**
    - Necessary for ossification.

**Box 6.4** Developing Long Bone.

Presence of

- (i) **epiphyseal plate** of hyaline cartilage;
- (ii) **trabeculae of bone** projecting from epiphyseal plate;
- (iii) epiphyseal plate showing various **zones**.



- Deficiency → retardation of bone formation and growth.
- Excess → acceleration of ossification resulting in early fusion of epiphysis and diaphysis.  
*Both abnormalities result in short stature of the individual.*

**Role of Hormones in Bone Formation**

- Balanced endocrine activities are essential for normal bone growth.
- Any disturbance in the activities may lead to bone abnormalities.
  1. *Parathyroid hormone*—activates osteoclasts to resorb bone → ↑ calcium in blood.
    - Hyperparathyroidism → deposition of calcium in arterial walls and kidney.
  2. *Calcitonin*—inhibits bone resorption by osteoclasts → ↓ calcium in blood.
  3. *Growth hormone*—stimulates the growth of epiphyseal plate.
    - Deficiency → *Dwarfism*
    - Excess →
      - in children → *Gigantism*
      - in adult → *Acromegaly*



# Self-assessment Exercise

## I. Provide a detailed account on:

1. Histogenesis of long bones or Endochondral ossification
2. Histogenesis of flat bones or Intramembranous ossification

## II. Write short notes on:

1. Histology of compact bone
2. Osteon or Haversian system
3. Bone cells
4. Differences between osteoblasts and osteoclasts
5. Bone marrow

## III. Fill in the blanks:

1. The newly formed bone with low mineral content at the site of fracture is called \_\_\_\_\_
2. The process by which inorganic salts are removed from bone is called \_\_\_\_\_
3. The hardness and rigidity of the bone is due to the presence of \_\_\_\_\_
4. The periosteum that covers the bone is firmly attached to it by means of perforating fibres of \_\_\_\_\_
5. The adjacent Haversian canals are connected by \_\_\_\_\_
6. The newly formed unmineralised matrix is called \_\_\_\_\_
7. Deficiency of vitamin C leads to \_\_\_\_\_
8. Deficiency of vitamin D in children leads to \_\_\_\_\_
9. Osteoclasts are found in specialised depressions on the surface of the bone called \_\_\_\_\_
10. The thin vascular membrane that lines the medullary cavity is \_\_\_\_\_

## IV. Choose the best answer:

1. Periosteum is absent over the following *except*
  - (a) articular surface of bone
  - (b) sesamoid bone
  - (c) site of attachment of tendons and ligaments to the bone
  - (d) Outer table of flat bone
2. Osteocytes can be identified by the presence of
  - (a) many nuclei
  - (b) lacuna around the cell
  - (c) lysosomes
  - (d) ingested particles
3. Alkaline phosphatase activity can be demonstrated in
  - (a) osteoblasts
  - (b) osteocytes
  - (c) osteoclasts
  - (d) osteoprogenitor cells
4. Spongy bone can be identified histologically by the presence of
  - (a) Haversian canal and concentric bony lamellae
  - (b) bony trabeculae and marrow cavity

- (c) interstitial lamellae
  - (d) Volkmann's canal
5. The vitamin necessary for absorption of calcium from small intestine is
- (a) Vitamin A
  - (b) Vitamin C
  - (c) Vitamin D
  - (d) Vitamin E

**V. State whether the following statements are True (T) or False (F):**

- 1. Periosteum is essential for bone growth. ( )
- 2. Volkmann's canal that interconnects Haversian canals is surrounded by concentric lamellae of bone. ( )
- 3. Osteoclasts show alkaline phosphatase activity. ( )
- 4. Rickets is characterised by bowing of long bones due to deficient calcification. ( )
- 5. Flat bones are ossified from cartilage only. ( )
- 6. Diaphysis of long bone is formed from primary centre of ossification. ( )
- 7. Primary centre of ossification is set on arrival of periosteal bud and usually occurs during intrauterine life. ( )
- 8. Epiphyseal plate of a growing long bone is made of elastic cartilage. ( )
- 9. Union of epiphysis and diaphysis is known as synchondrosis. ( )
- 10. Epiphysis is formed from secondary centre of ossification. ( )

**VI. Match the items in Column 'A' with those of Column 'B':**

<b>Column 'A'</b>		<b>Column 'B'</b>	
1. Vitamin C	( )	(a) Increases calcium level in blood	
2. Vitamin D	( )	(b) Is necessary for collagen synthesis	
3. Calcitonin	( )	(c) Is necessary for absorption of calcium	
4. Parathormone	( )	(d) Decreases calcium level in blood	
5. Growth hormone	( )	(e) Acts on epiphyseal plate	

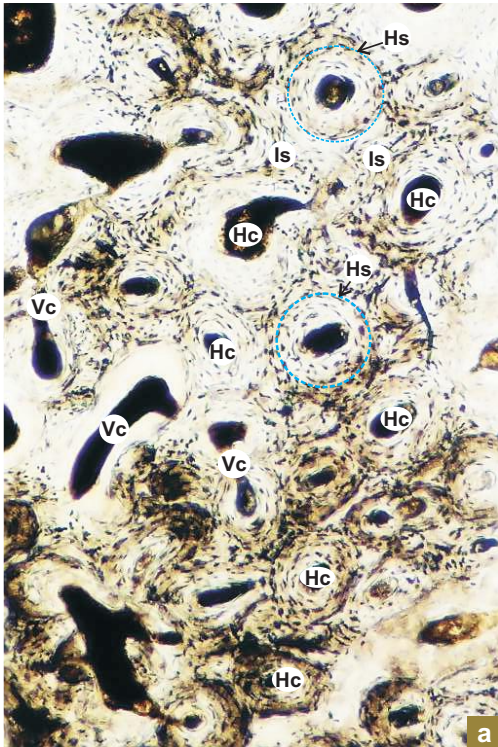
**Answers**

- III.** 1. Callus      2. Decalcification      3. Inorganic salts      4. Sharpey      5. Volkmann's canal  
 6. Osteoid      7. Scurvy      8. Rickets      9. Howship's lacuna      10. Endosteum
- IV.** 1. d    2. b    3. a    4. b    5. c
- V.** 1. (T)    2. (F)    3. (F)    4. (T)    5. (F)    6. (T)    7. (T)    8. (F)    9. (F)    10. (T)
- VI.** 1. b    2. c    3. d    4. a    5. e

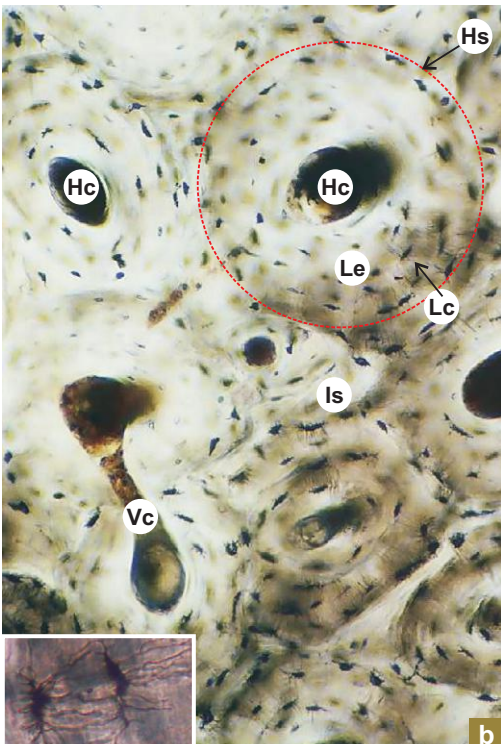
# Practical No. 6

## Connective Tissue III: Bone

X40



X100



**Plate 6:1**  
**a and b**

**C.S. of compact bone**  
**(ground section—**  
**unstained).**

In ground sections all cellular materials (organic) are destroyed during dry processing. So the canals, canaliculi and lacunae are devoid of cellular elements and are filled with air which appears black or brown during microscopic examination.

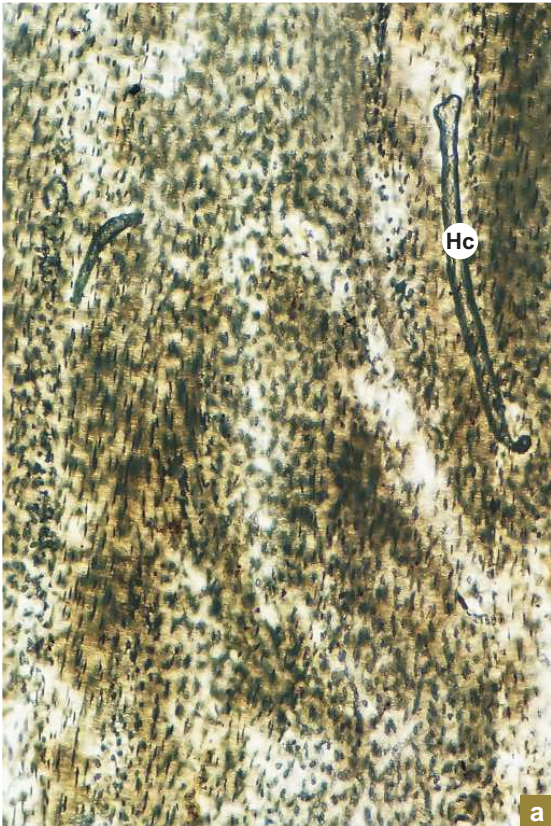
Identify the following structures in a ground section of compact bone under low magnification (Plate 6:1a):

- *Haversian systems (osteons; Hs)*—made of Haversian canal (Hc) surrounded by concentric lamellae of bone matrix.
- *Interstitial systems (Is)* occupying triangular interval between the Haversian systems.
- *Volkmann's canal (Vc)* interconnecting the adjacent Haversian canal (or it may connect medullary cavity also) may be seen penetrating the lamellae of Haversian systems (no concentric lamella around Volkmann's canal).

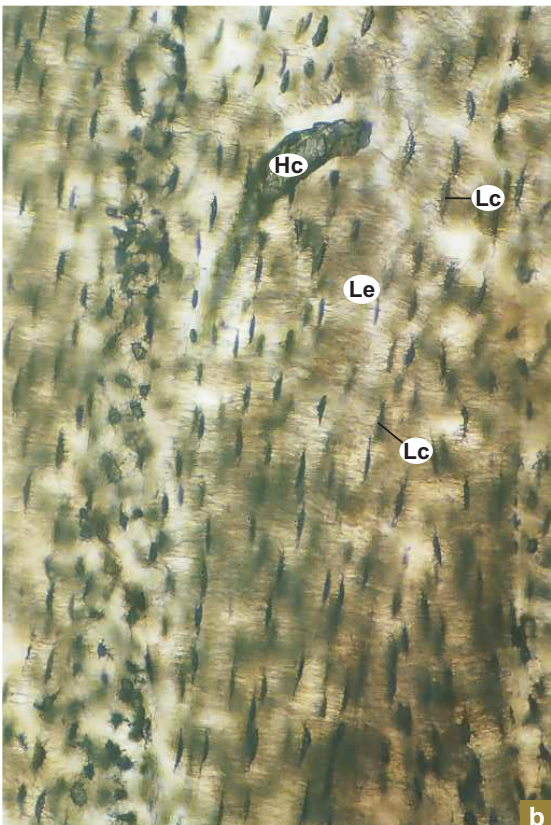
Examine a Haversian system (Hs) under high magnification (Plate 6:1b), which shows:

- A central canal (*Haversian canal, Hc*).
- *Concentric lamellae of bone matrix (Le)* around central canal.
- *Elliptical lacunae (Lc)* between lamellae of bone matrix.
- Fine *canaliculi* radiating from each lacuna to anastomose with those of adjacent lacunae (appear like legs of a spider) (inset).
- The boundary between each Haversian system is limited by a refractile line called *cement line* (modified bone matrix) (not seen).

X40



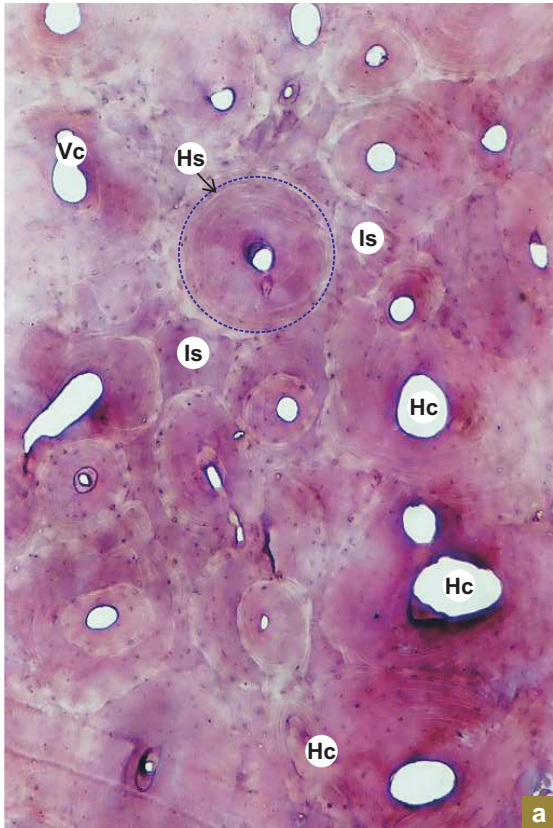
X100


**Plate 6:2**  
**a and b**
**L.S. of compact bone**  
**(ground section).**

Note the following features in a longitudinal section of compact bone (ground) under low and high magnifications:

- Longitudinally cut *Haversian canals* (**Hc**) parallel to the long axis of bone.
- *Lamellae of bone matrix* (**Le**) and rows of elliptical *lacunae* (**Lc**) are seen parallel to the Haversian canals.
- *Volkmann's canal* may be seen connecting the Haversian canals like the horizontal bar of letter 'H'.

X40



**Plate 6:3** C.S. of compact bone (decalcified section).  
**a and b**

In the decalcified section all the inorganic salts are removed and the cellular elements are preserved.

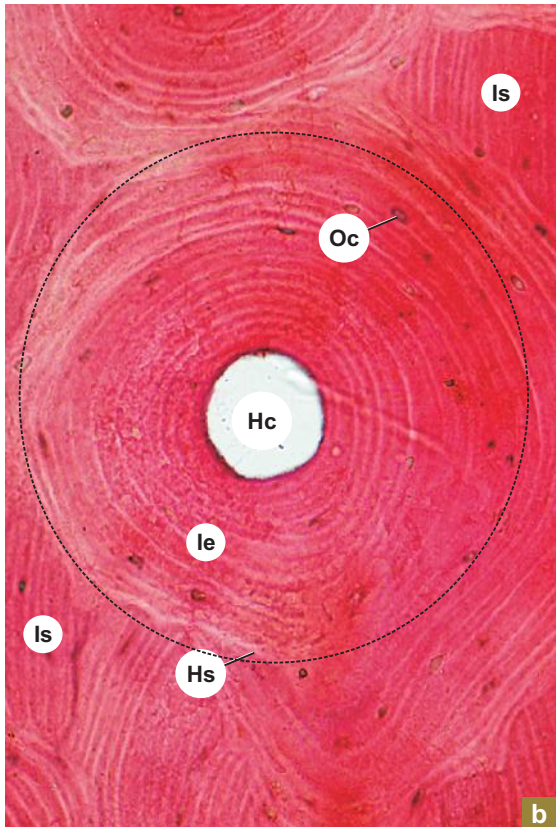
Identify the following structures:

- Haversian system (osteons; **Hs**).
- Interstitial lamellae (**Is**).
- Volkmann's canal (**Vc**).

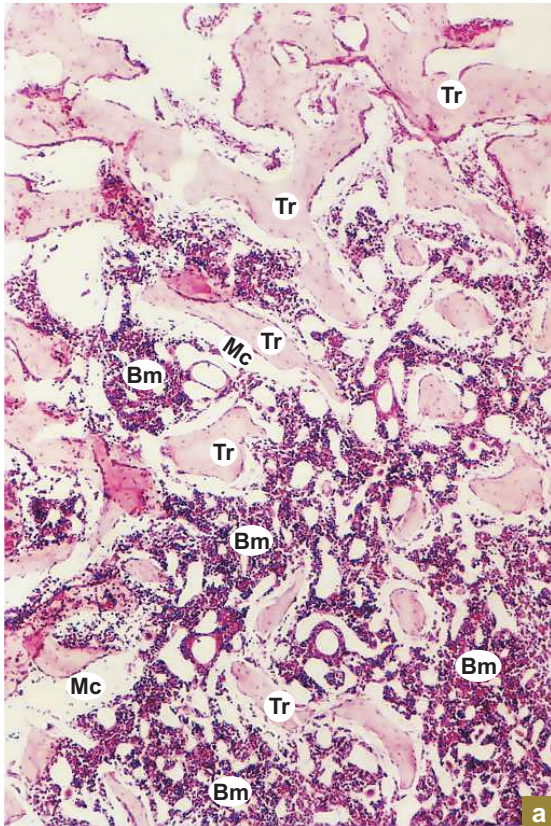
Each Haversian system shows:

- A central canal (*Haversian canal*; **Hc**) containing loose areolar tissue carrying neurovascular structures (not seen).
- Concentric lamellae of bone (**Le**) matrix.
- Osteocytes (**Oc**) in lacunae between the lamellae of bone matrix.

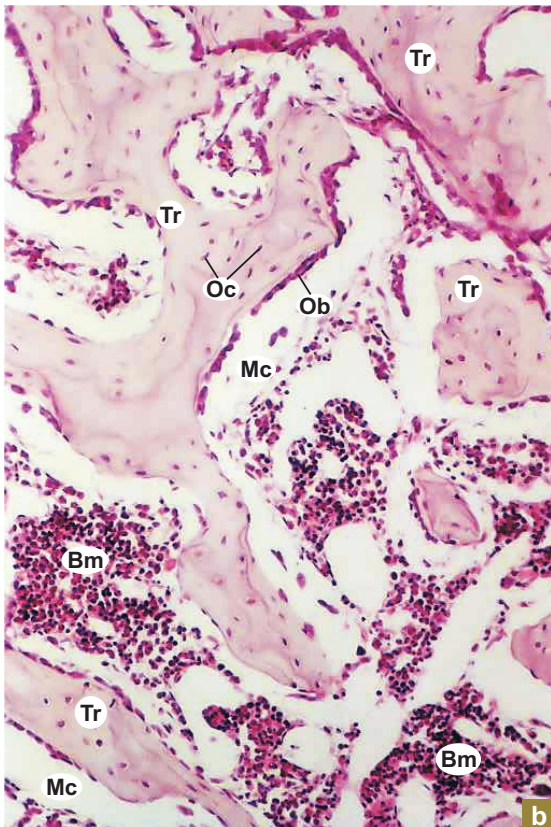
X40



X40



X200



**Plate 6:4**    **Spongy or cancellous**  
**a and b**        **bone.**

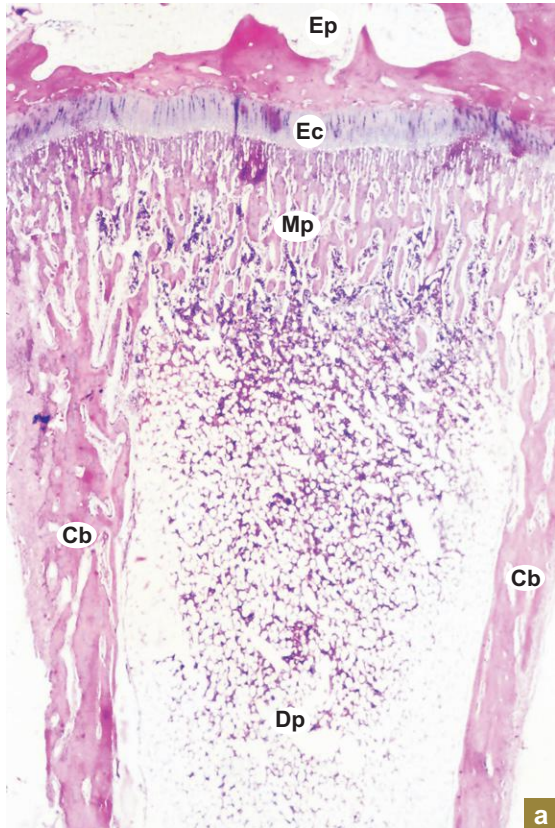
At low magnification (Plate 6:4a), identify the following structures:

- Slender irregular *trabeculae of bone* (**Tr**) separated by *marrow cavity* (**Mc**) containing *bone marrow* (**Bm**).

At high magnification (Plate 6:4b), identify the following structures:

- *Osteocytes* (**Oc**) in lacunae are embedded in the bone matrix of the trabeculae (**Tr**).
- *Osteoblasts* (**Ob**) and osteoprogenitor cells can be seen on the surface of the trabeculae (they are cuboidal when active and flattened when inactive).
- Large, multinucleated *osteoclasts* may be seen on eroded depression of bone, known as *Howship's lacunae* (not seen).
- Bone marrow (**Bm**) in marrow cavity (**Mc**).

X10



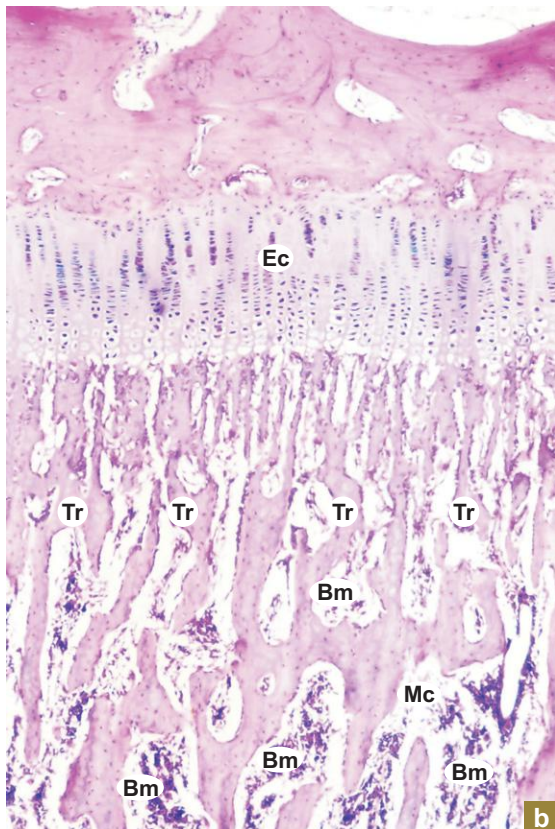
a

**Plate 6:5 Growing long bone (endochondral ossification).**  
**a and b**

Identify the various parts of a growing long bone under scanner (Plate 6:5a). At low magnification (Plate 6:5b), identify the following:

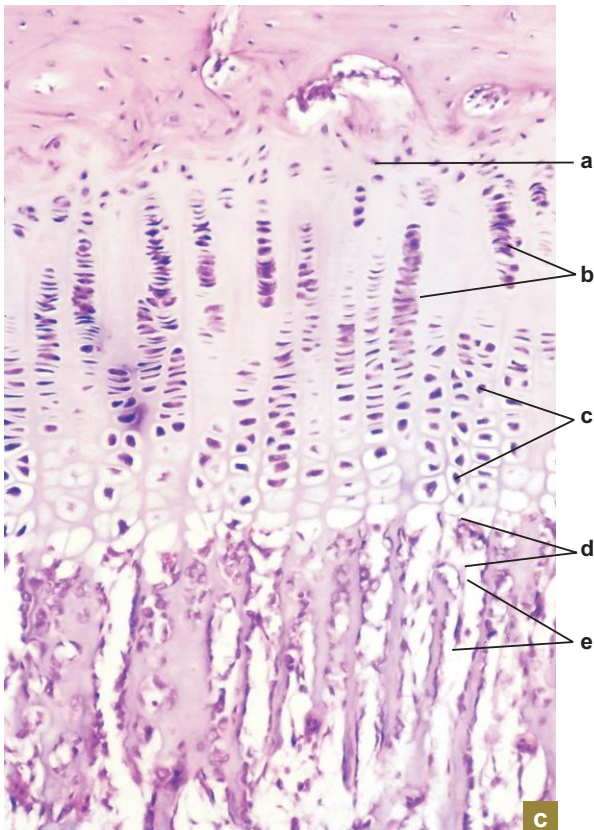
- Epiphyseal cartilage (**Ec**), epiphysis (**Ep**), metaphysis (**Mp**), diaphysis (**Dp**) and subperiosteal collar of compact bone (**Cb**).
- Young bony trabeculae (**Tr**) projecting from the diaphyseal surface of the epiphyseal cartilage (**Ec**). Note the marrow cavity (**Mc**) and bone marrow (**Bm**).

X40



b

X100

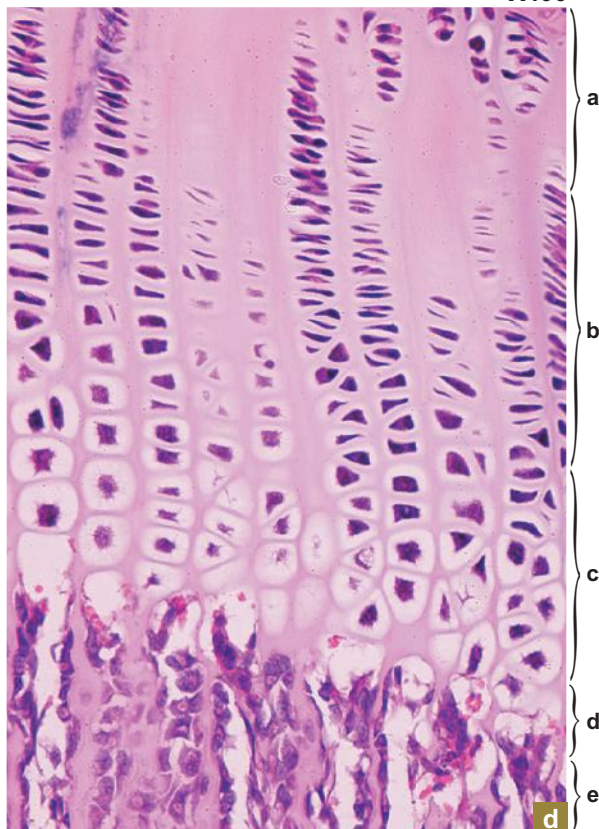


**Plate 6:5** Growing long bone (epiphyseal cartilage).

Identify the various zones in the epiphyseal cartilage at higher magnifications (Plate 6:5c and d). They are arranged as follows from the epiphyseal surface to diaphyseal surface:

- a = *Zone of resting cartilage* – chondrocytes are distributed singly or in groups.
- b = *Zone of proliferation* – chondrocytes are arranged in columns.
- c = *Zone of hypertrophy* – chondrocytes are increased in size and vacuolised.
- d = *Zone of calcification* – the matrix between the columns of cells is calcified.
- e = *Zone of ossification* – erosion of calcified matrix and invasion of osteoprogenitor cells from the marrow cavity and deposition of osteoid.

X400





"This page intentionally left blank"

# 7

## LYMPHOID TISSUE

### INTRODUCTION

Lymphoid system (immune system) consists of tissues and organs mainly made of lymphocytes, which protect the internal environment of the body against invasion of microorganisms by producing specific immune response. This immune response is activated only when the first two lines of defense, described below, fail to prevent the entry of microorganisms.

The first line of defense is provided by the *surface epithelium* constituted by the epidermis of skin that covers the body and the mucous membrane that lines the hollow visceral tracts which are exposed to the external environment. The antibacterial substances present in various secretions (tears, saliva, etc.) on the mucous membrane and the acidic environment present in the stomach and vagina inhibit the growth and entry of microorganisms into the underlying tissue.

The second line of defense comes into effect when there is breach of the epithelial surface due to injury (abrasion, burning, etc). The second line of defense is constituted by phagocytic cells, namely, macrophages and neutrophils present in the connective tissue (lamina propria, dermis). These cells exert a *nonspecific cellular* response by destroying the pathogenic bacteria by phagocytosis or by producing an antiviral substance, interferon, against multiplication of virus within cells. The site of pathogenic insult evokes a tissue reaction called *inflammation*.

The third line of defense is the *specific immune response* which gets activated when both the above mentioned lines of defence fail to check the invasion of pathogenic organisms. The specific immune response is evoked by lymphocytes.

Lymphocytes are of two types, namely, B and T. They are derived from common stem cells in the bone marrow. Though they are morphologically similar, they are functionally different.

B lymphocytes mature and become immunocompetent in the bone marrow, whereas T lymphocytes mature and become immunocompetent in thymus and migrate to other peripheral lymphoid organs.

They express their defense mechanisms in two main ways in response to antigen either separately or often together.

The defense mechanism mediated by B lymphocytes is called *humoral immune response*, in which the immunocompetent B lymphocytes encounter a specific antigen and become activated. These activated B lymphocytes proliferate and differentiate into plasma cells. The plasma cells secrete specific antibodies (immunoglobulins) into the blood and lymph against that particular antigen.

The other mechanism, *cellular immune response*, is mediated by T lymphocytes with the cooperation of macrophages and is involved in direct destruction of the invading pathogenic organism or antigen. T lymphocytes may also act indirectly by activating B lymphocytes to differentiate into plasma cells and secrete specific antibodies.

The mechanism of specific immune response is diagrammatically represented in Flowchart 7.1.

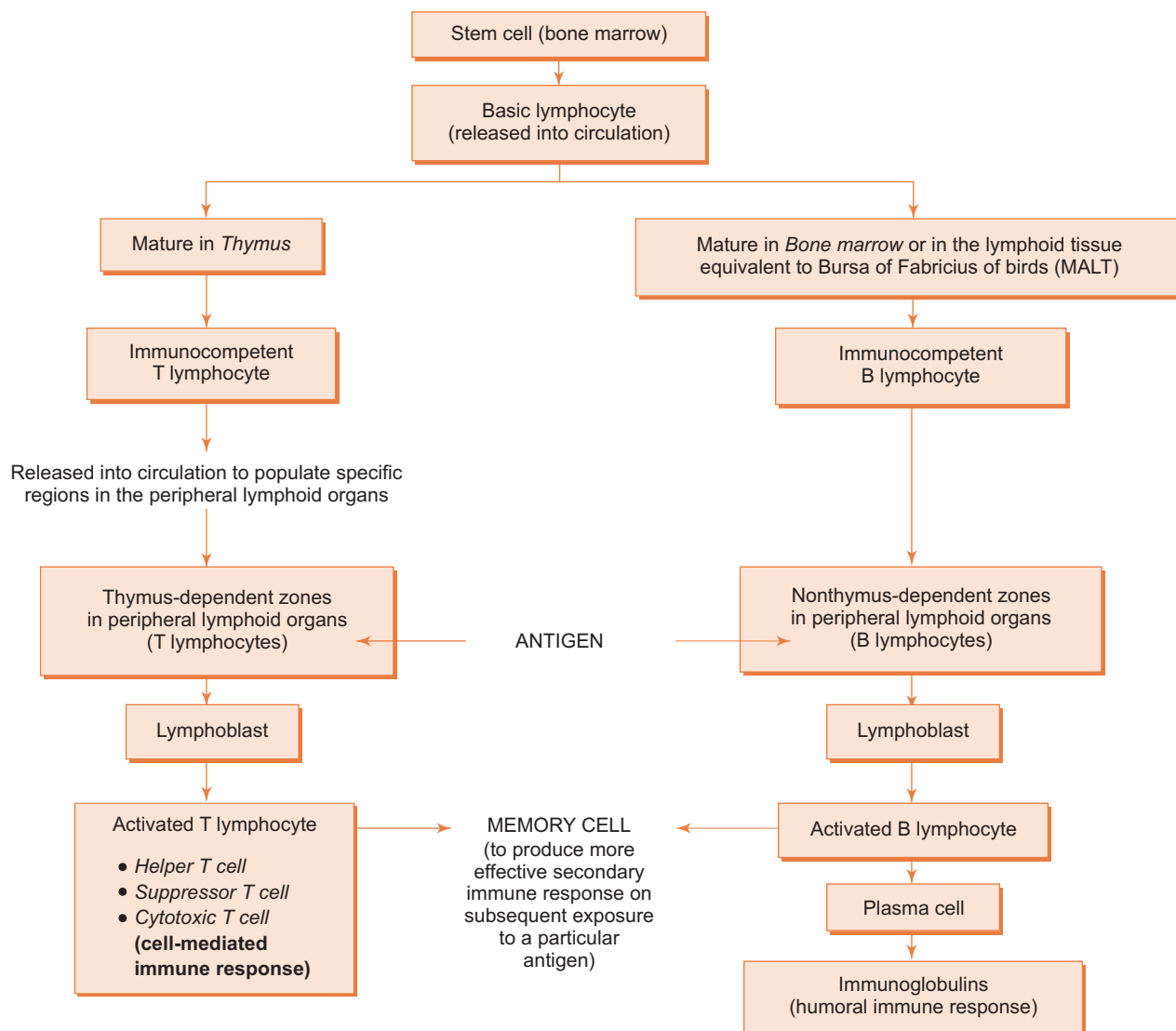
### IMMUNOGLOBULINS

- Immunoglobulins are circulating plasma glycoproteins secreted by plasma cells. They are also called antibodies.
- They interact specifically with antigens, initiating a complex immune response that protects the body from damage.

Five classes of immunoglobulins have been described in human beings.

#### 1. IgG

- Most abundant type forming 75% of serum immunoglobulin.
- Is the only immunoglobulin that crosses the placental barrier.
- Protects the newborn against infection.



**Flowchart 7.1** Specific immune response.

**2. IgA**

- Is the main immunoglobulin found in secretions (nasal, bronchial, intestinal, vaginal and secretions, tears, colostrum, saliva, etc.).
- Protects the mucous membrane and prevents the proliferation of microorganisms.
- Forms 10–15% of serum immunoglobulins.

**3. IgM**

- Constitutes about 5–10% of serum immunoglobulins.
- Found on the surface of B lymphocytes.
- First immunoglobulin to be produced in an initial immune response.
- Activates complement system.

**4. IgD**

- 0.2% of serum immunoglobulins function is not completely understood.
- Like IgM, it is found on the surface of B lymphocytes.

**5. IgE**

- 0.002% of serum immunoglobulins bind to the surface of mast cells, eosinophils and basophils.
- Participates in allergy and destruction of parasitic worms.

**Approximate percentage of lymphocytes in various lymphoid organs**

	B lymphocyte %	T lymphocyte %
Bone marrow	90	10
Thymus	0	100
Lymph node	40	60
Spleen	55	45
Blood	20	80

**Cells of the Immune System**

Cells of the immune system are of following types:

**1. B and T lymphocytes**

- Prime cells of the immune system.

**2. Natural killer (NK) cells**

- Morphologically similar to lymphocytes but functionally different.
- Attack virus infected cells, transplanted cells and cancer cells without prior stimulation.

**3. Macrophages and cells of mononuclear phagocytic system.****4. Antigen-presenting cells (APC) such as:**

- Langerhans' cell in epidermis.
- Follicular dendritic cells in lymphoid organs.
- M cells in epithelium of ileum.

**5. Neutrophils.****6. Mast cells and eosinophils.**

One of the primary causes of **acquired immunodeficiency syndrome (AIDS)** is the killing of helper T cells by the infecting human immunodeficiency virus (**HIV**). This suppresses patients' immune system rendering them susceptible to infection by microorganisms that usually do not cause any disease in immunocompetent individuals.

**Classification of Lymphoid Tissue**

Lymphoid tissue may be broadly classified into:

**A. Diffuse lymphoid tissue**

- It is constituted by a layer of diffusely arranged lymphocytes and plasma cells deep to epithelium in lamina propria of *digestive*, respiratory and urogenital tracts forming an immunological barrier against invasion of microorganisms.

**B. Dense lymphoid tissue**

- It is characterised by the presence of a large number of lymphocytes (plus few macrophages and plasma cells) arranged in the form of nodules.
- These nodules are found either in association with mucous membranes of viscera or as discrete encapsulated organs.

1. **MALT** (Mucosa associated lymphoid tissue; nonencapsulated)
  - In some places of the above tracts the lymphocytes aggregate to form conspicuous dense lymphatic nodules or follicles in the lamina propria or submucosa forming MALT.
    - Solitary nodules
    - Aggregated nodules (Peyer's patches)
    - Lymphoid nodules in vermiform appendix
    - Waldeyer's lymphoid ring at the entrance of pharynx
2. **Discrete lymphoid organs** (encapsulated)
  - These include the following organs:
    - Thymus
    - Lymph node
    - Spleen
    - Tonsil (palatine tonsil – Part of MALT)

### General Architecture of Lymphoid Organs

- Lymphoid organs consist of supporting framework (connective tissue) and parenchyma (lymphocytes).
- The supporting framework includes the capsule that covers the organ at the periphery; trabeculae/interlobular septae which enter into the organ carrying blood vessels and nerves, and reticulum which supports the cellular parenchyma.

## THYMUS

### GENERAL FEATURES

- Thymus is a central lymphoid organ. It is responsible for the development of immune system of body and is essential for the growth and development of other lymphoid organs.
- It is a bilobed organ, the lobes being unequal in size, present in the superior and anterior mediastinum of thorax.
- It has dual origin. Its lymphocytes arise from mesoderm, whereas the epithelial reticular cells arise from endoderm of III pharyngeal pouch. So it is called a 'lympho-epithelial organ'.
- Thymus is larger and well-developed in foetus and in early childhood. It attains its peak development at puberty and thereafter it starts involuting and is replaced by fibro-fatty tissue. Its weight is 12–15 gm at birth, 30–40 gm at puberty and 10–15 gm at 60 years.
- It has only efferent and no afferent lymphatic vessels.

### COMPONENTS/STRUCTURE

#### A. Supporting framework

1. Capsule
2. Interlobular septae
3. Cellular cytoplasmic reticulum—formed by epithelial reticular cells.

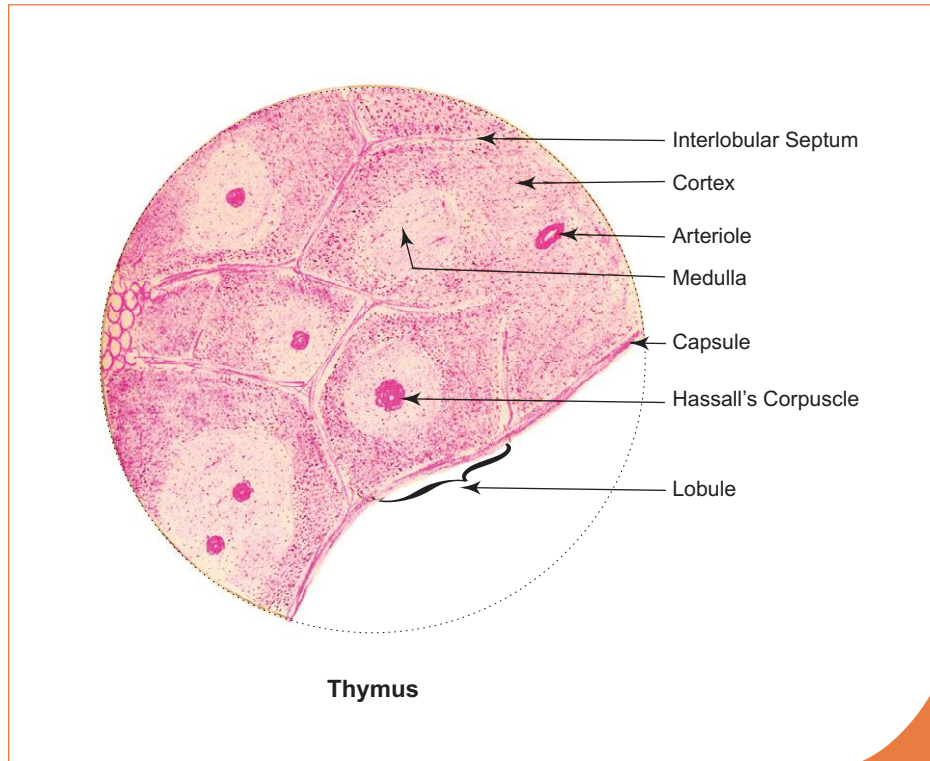
#### B. Lobules or Parenchyma

1. Cortex
2. Medulla and Hassall's corpuscle.

## Supporting Framework

### Capsule and Interlobular Septae

- Thin connective tissue capsule covers the thymus completely.
- The capsule sends septae into the interior dividing the lobe into incomplete lobules. The interlobular connective tissue septae carry blood vessels, nerves and lymphatics.
- Each lobule has a darkly stained cortex at the periphery and a lightly stained medulla in the centre (Box 7.1, Fig. 7.1).
- The medulla of one lobule becomes continuous with the medulla of neighbouring lobules, as seen in serial sections, and this confirms the presence of a central medulla for the lobe.



#### Box 7.1 Thymus.

Presence of

- many lobules of lymphoid tissue;
- darkly stained cortex and lightly stained medulla in each lobule;
- Hassall's corpuscles in the medulla.

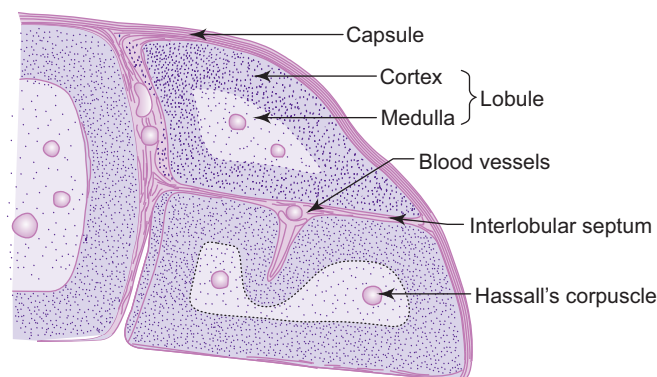


Fig. 7.1 Thymus.

### Cellular Cytoplasmic Reticulum/Epithelial Reticular Cells

- The supporting stroma of the organ within the lobule is formed by epithelial reticular cells (endodermal in origin).
- These are stellate cells and their cytoplasmic processes come in contact with the processes of neighbouring cells by means of desmosomes (Fig. 7.2).
- Thus they form a *cellular cytoplasmic reticulum* giving support to the lymphocytes of thymic lobules. (*This reticulum is different from the reticulum of other lymphoid organs where it is formed by reticular fibres.*)
- They can be easily identified by their large pale staining oval nuclei and eosinophilic cytoplasm.
- The cytoplasm contains secretory granules which are believed to liberate hormones, *thymosin* and *thymopoietin*.

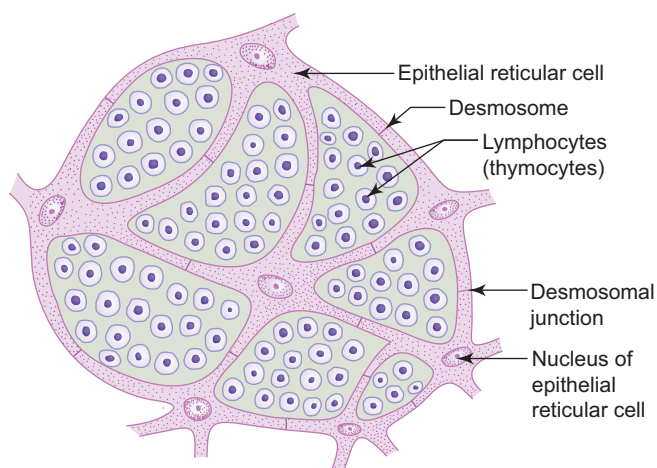


Fig. 7.2 Thymic reticulum.

### Lobules or Parenchyma

#### Cortex

- Each lobule shows a darkly stained cortex and a lightly stained medulla. The cortex is densely packed with lymphocytes (thymocytes), few macrophages and epithelial reticular cells.
- The outer part of cortex contains larger lymphocytes (lymphoblasts) which divide by mitosis to produce smaller lymphocytes which are pushed into the deeper part of the cortex.
- Of the vast number of lymphocytes produced in the cortex, only very few leave the thymus via post-capillary venules in the medulla as immunocompetent T lymphocytes and the rest (majority) die in the thymus itself. The reason for this cell death is not fully understood.
- The capillaries present in the cortex show a distinct, thick basement membrane and are surrounded by processes of epithelial reticular cells forming the so called *blood-thymus barrier*. It is believed that this barrier does not allow any blood borne antigen to come in contact with the maturing T lymphocytes, which otherwise may influence the developing T lymphocytes.

#### Medulla and Hassall's Corpuscle

- Medulla is lightly stained because the lymphocytes are less densely packed. For this reason the epithelial reticular cells in the medulla appear to be numerous.
- The most characteristic feature of the medulla is the presence of Hassall's corpuscles.
- Hassall's corpuscles are round lamellated acidophilic bodies (30–100 μm). They have a central homogeneous hyaline material surrounded by concentric layers of flattened epithelial cells. These cells are filled with keratin filaments.
- The number of Hassall's corpuscles increases with age and may show traces of calcification. Their function is not known and are the last one to undergo involution.

## CHARACTERISTIC FEATURES

Thymus has the following characteristic features by which it is differentiated from other lymphoid organs:

- Central lymphoid organ—essential for development of other lymphoid organs.
- Dual origin (lymphocytes from mesoderm and epithelial reticular cells from the endoderm).
- Supporting stroma is formed by ‘cytoplasmic reticulum’ derived from epithelial reticular cells.
- Formed only by T lymphocytes/thymocytes (no B lymphocytes).
- Divided into lobules of lymphoid tissue by interlobular septum (no lymphatic nodules).
- Has Hassall’s corpuscles.
- Produces many thymic hormones.
- Fully developed at birth.
- Involutates after puberty.

## FUNCTIONS

- It is a central lymphoid organ and is essential till puberty for the development of the immune system of the organism. After puberty the other lymphoid organs of the body are fully developed and thereafter it undergoes involution.
- Removal of thymus in newborn → failure of seeding of other lymphoid organs with immunocompetent T cells → deficiency in immunological competence to fight invading pathogens → infection → death.
- Epithelial reticular cells secrete hormones like thymulin, thymosin, thymopoietin, etc., which are involved in stimulation, proliferation and differentiation of T lymphocytes.
- Produces immunocompetent T lymphocytes which are involved in cell mediated immunity.

## LYMPH NODE

### GENERAL FEATURES

- Oval or bean-shaped structures situated along the course of the lymphatic vessels.
- They serve as filters of lymph, removing particulate matter and bacteria from lymph before it enters the CVS, thereby localizing and preventing the spread of infection.
- Lymph nodes are usually found in groups, especially in the axilla, inguinal region, root of lung, etc.
- Lymph node has many afferent lymphatic vessels which enter through the convex surface, whereas the efferent lymphatic vessels are one or two in number and leave through the concave depression, the hilum. The hilum also transmits nerves and blood vessels. The lymphatic vessels are provided with valves in such a way that lymph flows in one direction.

### COMPONENTS/STRUCTURE

#### A. Connective tissue framework

1. Capsule
2. Trabeculae
3. Reticular stroma (fibres)

#### B. Parenchyma

1. Cortex
2. Paracortex (inner cortex)
3. Medulla



## Connective Tissue Framework (Box 7.2; Fig. 7.3)

### Capsule and Trabeculae

- The organ is surrounded by a thin connective tissue capsule which sends trabeculae into the interior.
- Beneath the capsule is the subcapsular sinus which is traversed by reticular fibres and cells.
- The subcapsular sinus receives afferent lymphatic vessels and is continuous with trabecular sinuses found around the trabeculae.
- The trabecular sinuses become continuous with the medullary sinuses.

### Reticular Stroma

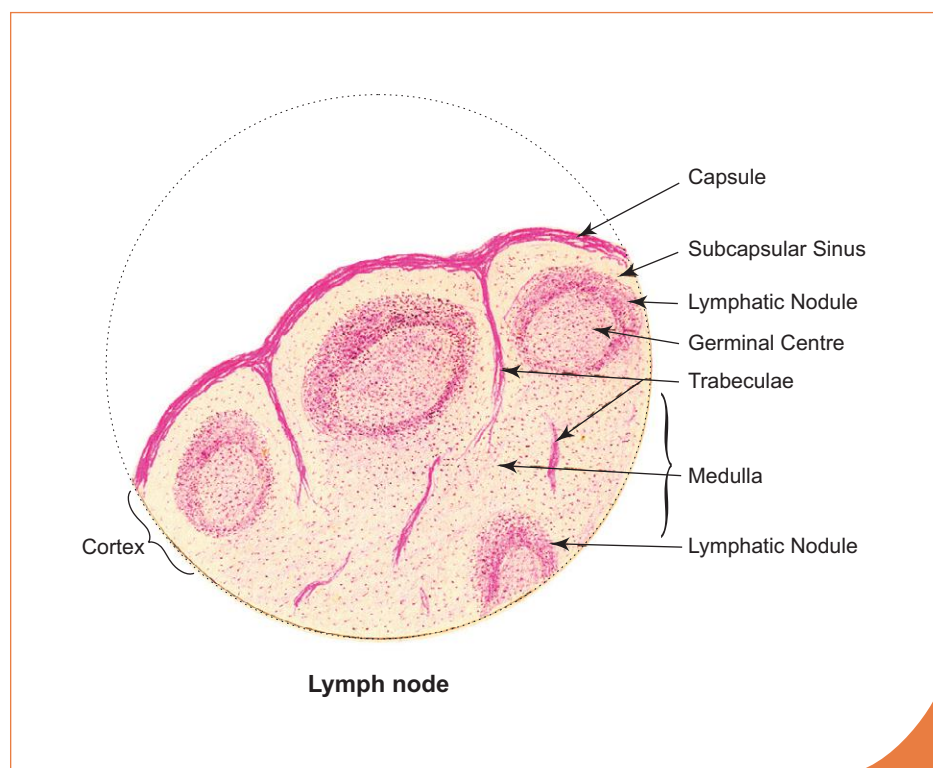
- It is made of reticular fibres and associated phagocytic reticular cells, forming a meshwork throughout the organ and is particularly dense in the cortex (for better understanding see Plate 7:1b).
- Gives structural support to lymphoid cells (parenchyma).

### Parenchyma (Fig. 7.3)

It is the lymphoid tissue present in cortex, paracortex and medulla.

### Cortex

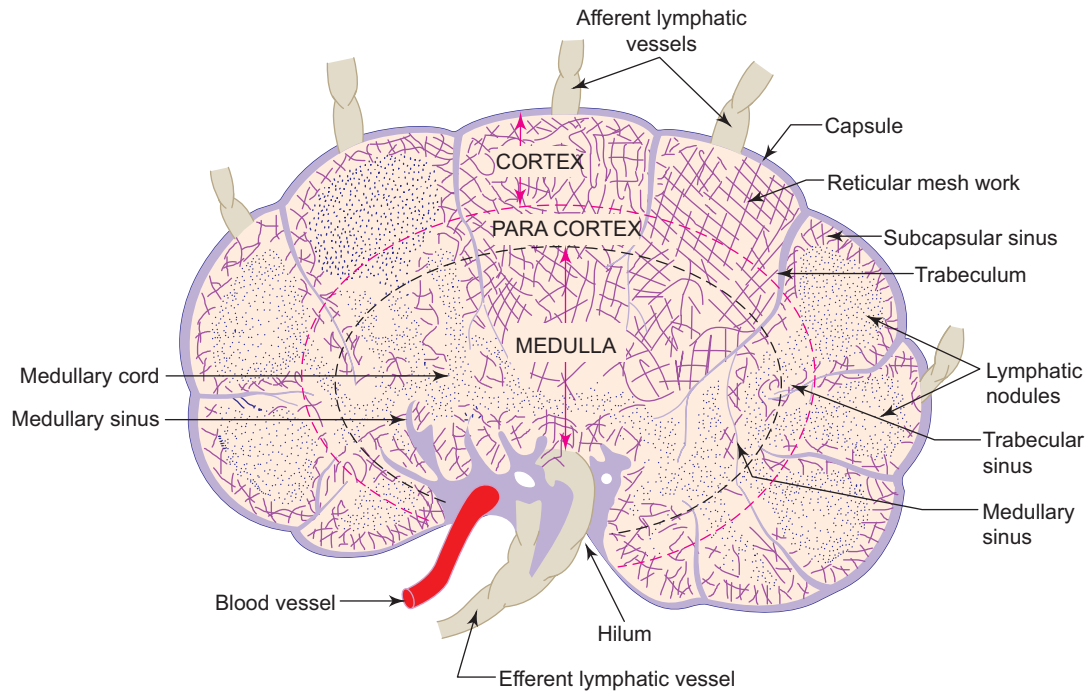
- The outer cortex is the peripheral part of the lymph node situated deep to the capsule. It contains the following structures:
  1. *Subcapsular sinus*—found beneath the capsule.
  2. *Lymphatic nodules*—with or without germinal centres formed mainly of B lymphocytes. A lymphatic nodule without a pale staining germinal centre is called *primary nodule*, whereas one with germinal centre is called *secondary nodule*.



### Box 7.2 Lymph Node.

Presence of

- lymphatic nodules in the cortex;
- subcapsular sinus;
- medullary cords and sinuses in the medulla;
- thin capsule.



**Fig. 7.3** Lymph node: connective tissue framework and parenchyma.

The germinal centre contains large lymphoblasts with more cytoplasm and lighter nuclei compared to lymphocytes which are at the periphery of the nodule.

### Paracortex

- It is the inner cortical zone, which does not have precise boundary with the outer cortex.
- It consists mainly of T lymphocytes and is called the thymus-dependent zone.
- Normally no nodules can be seen in the paracortex but sometimes discrete lymphatic nodules are seen.
- The dense lymphoid tissue in the paracortex becomes continuous with the medullary cords.

### Medulla

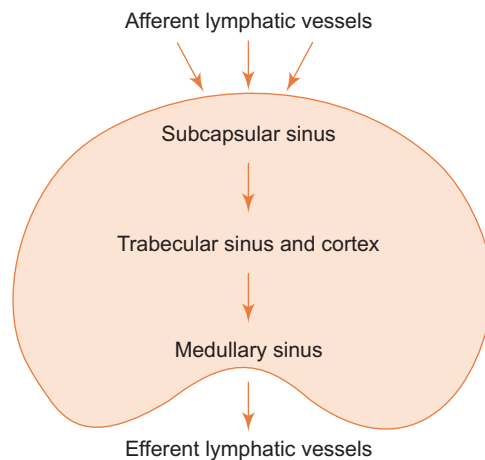
- Medulla has two components, the *medullary cords* and *medullary sinuses*.
- The *medullary cords* are branching and anastomosing cords of typical lymphoid tissue—made primarily of ‘B’ lymphocytes, few plasma cells and macrophages.
- The *medullary sinuses* are atypical lymphoid tissue disposed between the medullary cords. As in the subcapsular and trabecular sinuses, the medullary sinuses are traversed by reticular fibres providing support to macrophages, B lymphocytes and plasma cells. The medullary sinuses are lightly stained compared to the darkly stained medullary cords (with H & E). The medullary sinuses drain into the efferent lymphatic vessels found at the hilum.

### Flow of Lymph through Lymph Node

- The route of flow of lymph is diagrammatically represented in Flowchart 7.2.

### FUNCTIONS

- Filters the microorganisms from lymph, thereby localizing and preventing the spread of infection (defense).
- Produces lymphocytes.
- Produces antibodies.



**Flowchart 7.2** Flow of lymph.

## SPLEEN

### GENERAL FEATURES

- Spleen is the largest lymphoid organ present in the upper left part of abdominal cavity behind the stomach and is completely covered by peritoneum.
- Normally it is a blood-forming organ in foetal life and blood-destroying organ in postnatal life (graveyard of RBCs). Since it is in the bloodstream, it filters the blood from blood-borne antigens and microorganisms.

### COMPONENTS/STRUCTURE (BOX 7.3)

#### A. Connective tissue framework

1. Capsule
2. Trabeculae
3. Reticular stroma (fibres)

#### B. Parenchyma

1. White pulp (typical lymphoid tissue)
2. Red pulp (atypical lymphoid tissue)

### Connective Tissue Framework

#### Capsule

- Covers the spleen completely.
- Lies deep to the mesothelial covering (peritoneum).
- Is formed by dense collagenous connective tissue and few smooth muscle fibres. The smooth muscle fibres are more in some mammals. Contraction of these muscles cause pumping of blood from the spleen into the circulation. Spleen acts as a reservoir of blood.

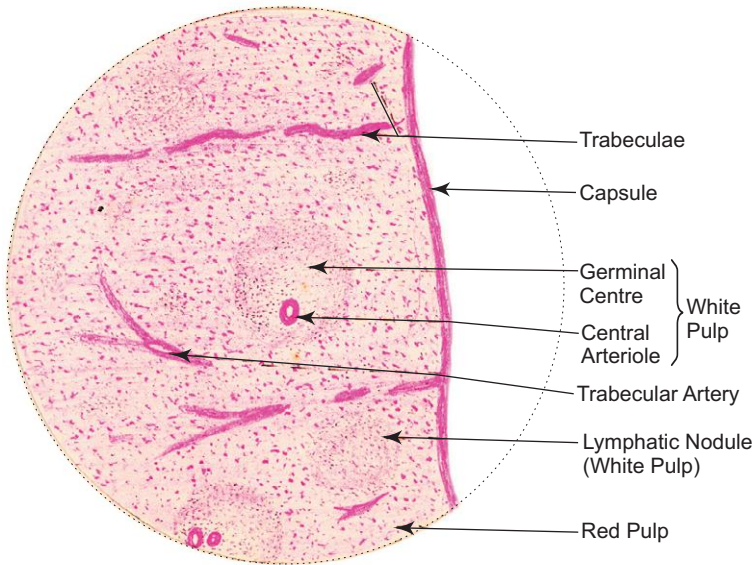
#### Trabeculae

- Trabeculae are given off from the capsule into the substance of spleen. They are thick and robust.
- Carry trabecular vessels which are branches of splenic vessels.

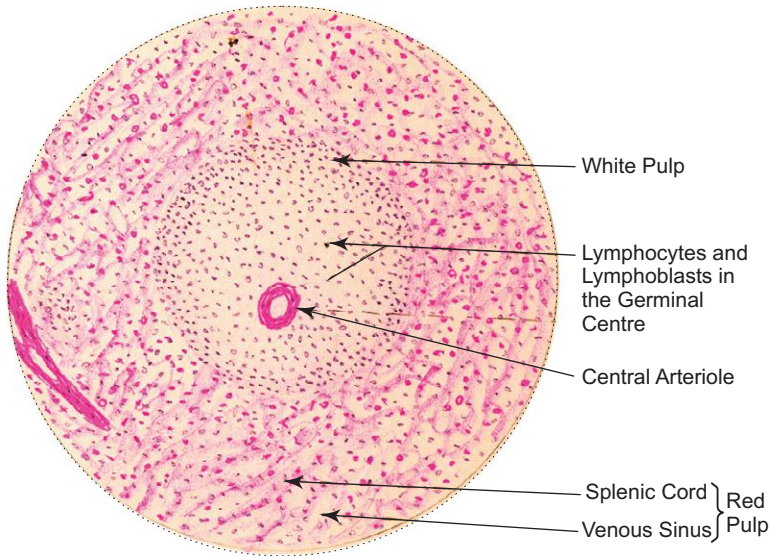
**Box 7.3 Spleen.**

*Presence of*

- (i) **white pulp** (lymphatic nodule) traversed by central arteriole;
- (ii) **Red pulp** containing splenic cords and sinusoids;
- (iii) **thick capsule** and trabeculae.



*L/p*  
**Spleen**



*H/p*  
**Spleen**

### Reticular Stroma

- Is made of reticular fibres and associated phagocytic reticular cells, forming a meshwork throughout the organ.
- Supports the cells of parenchyma.

### Parenchyma

- On examination with the naked eye, the interior of spleen shows rounded white/grey areas surrounded by red matrix. These round grey areas are called white pulp and the dark red matrix is called red pulp.

### White Pulp (Box 7.3)

- Microscopically, white pulp is made of aggregation of lymphoid tissue around a small artery or arteriole. This artery is a branch of trabecular artery that leaves the trabeculum and enters the pulp. On entering the pulp it is surrounded by lymphoid tissue, the *periarterial lymphatic sheath (PALS)*, populated by T lymphocytes, to become *central artery* or white pulp artery.
- Along the course of periarterial lymphatic sheath, there are large collections of B lymphocytes forming lymphatic nodules with germinal centres (white pulp). In these nodules the central artery occupies an eccentric position, but is still called the central artery.
- The lymphatic nodules (white pulp) are surrounded by an immunologically active zone containing many macrophages, few T lymphocytes and blood sinuses. This functional zone between the white and red pulp is called *marginal zone* (Fig. 7.5).
- The central artery or arteriole leaves the lymphatic sheath of white pulp and enters the red pulp, where it divides to form straight *penicillar arterioles*. Some of the penicillar arterioles may show thickening of the wall due to aggregation of macrophages, reticular cells and lymphoid cells; these thickenings are called *ellipsoids*. The penicilli terminate as arterial capillaries.
- The mode of termination of penicillar arterioles in the red pulp is a controversial subject and is discussed later.

### Red Pulp (Fig. 7.4)

- Red pulp is a modified lymphoid tissue, heavily infiltrated with all the cells of the circulating blood, giving a dark red colour to the tissue in fresh state.
- It is composed of irregular anastomosing *splenic cords of Bilroth* and broad *splenic venous sinuses* in between the cords.
- The *splenic cords* consist of spongy network of reticular fibres infiltrated with reticular cells, lymphocytes, macrophages, plasma cells and all elements of the circulating blood.
- The *splenic venous sinuses* are lined by highly elongated, spindle-shaped endothelial cells which lie parallel to the long axis of the sinuses on a discontinuous basement membrane. The structure of these venous sinuses can be compared to tall wooden barrels with both ends open and the endothelial cells being represented by the wooden staves, hence are described as *stave cells*. Externally, the sinuses are encircled by reticular fibres in a transverse direction like the steel bands holding together the staves of the wooden barrel.
- Since the spaces or gaps between the endothelial cells of the splenic sinuses are 2–3  $\mu\text{m}$  in diameter, only the flexible cells are able to pass easily to and from the cords and sinuses. A reduction in the flexibility of erythrocytes after 120 days seems to be signals for their destruction.

## THEORIES OF SPLENIC CIRCULATION

Two main theories have been proposed to explain the mode of termination of the arterial capillaries of the penicilli into the venous sinuses of the red pulp (Figs 7.4 and 7.5).

### Closed Circulation Theory

According to this theory, blood passes directly from the arterial capillaries into the splenic venous sinuses of the red pulp, i.e. the vascular system is continuous or closed.

From there blood enters the red pulp veins which join together and enter the trabeculae as trabecular veins. The trabecular veins join to form the splenic vein that emerges from the hilum of spleen.

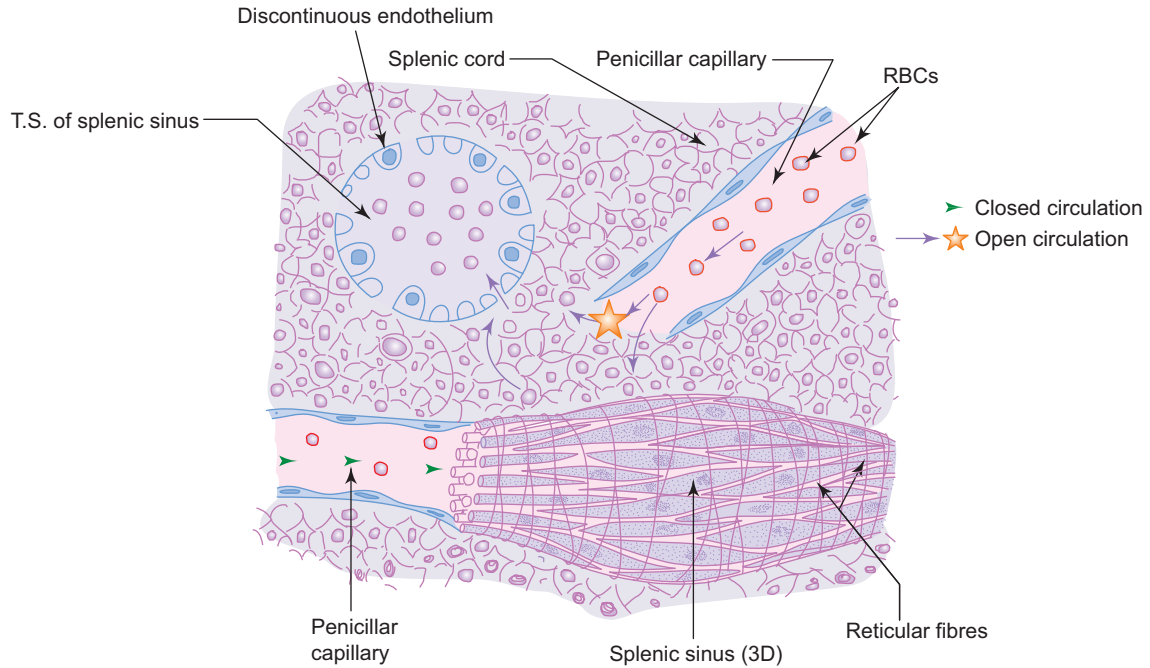


Fig. 7.4 Red pulp of spleen.

### Open Circulation Theory

According to this theory, blood passes from the arterial capillaries of penicilli into cords of Bilroth and from there into the sinuses through the spaces between endothelial cells. In this process the nonflexible old erythrocytes are retained in the cords and are engulfed by macrophages.

There is another compromise theory which states that the splenic circulation is closed in contracted spleen and open in distended spleen.

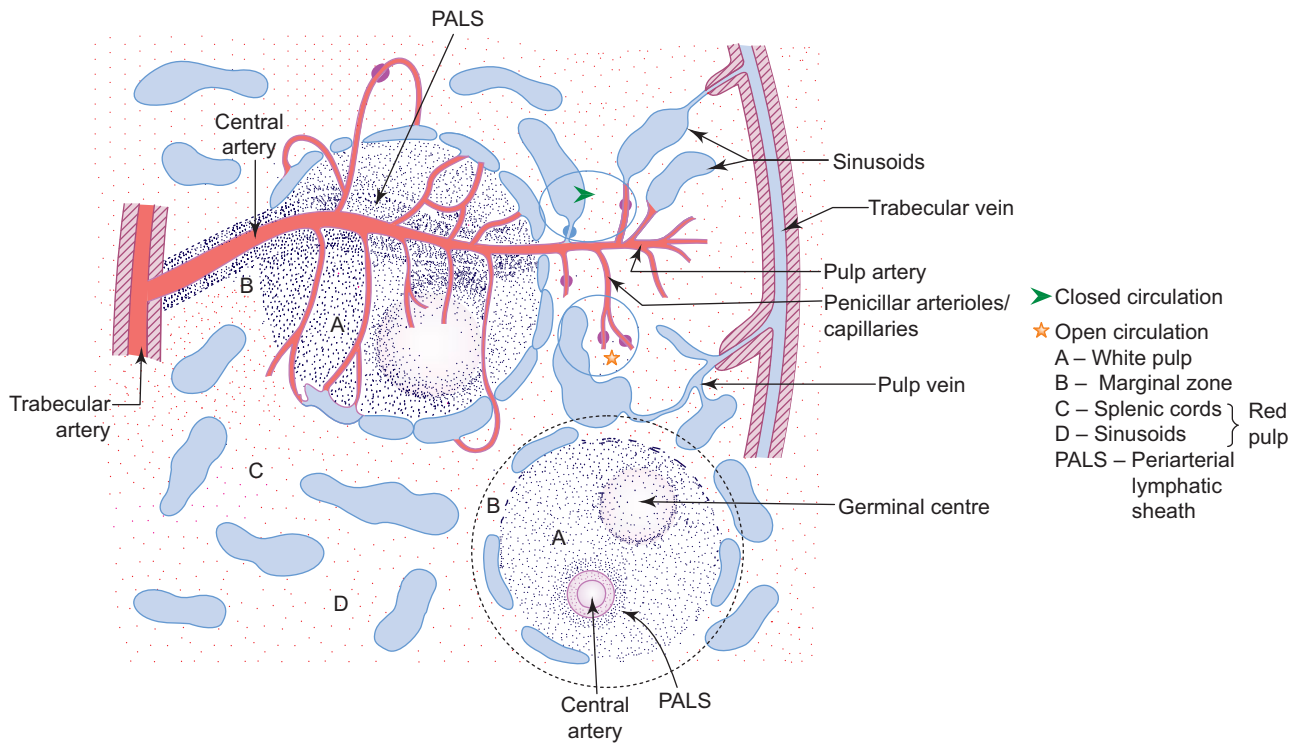


Fig. 7.5 Splenic circulation.

## FUNCTIONS

- Filtration of blood—filters the blood from antigens, microorganisms, aged platelets and aged and abnormal RBCs.
- Production of lymphocytes (defense of the body).
- Reservoir of blood (in some mammals).
- Acts as haemopoietic organ (in foetal life).
- Has role in phagocytosis of old RBCs—macrophages of spleen remove iron from the haemoglobin of aged RBCs, which is re-used for synthesis of haemoglobin in bone marrow.

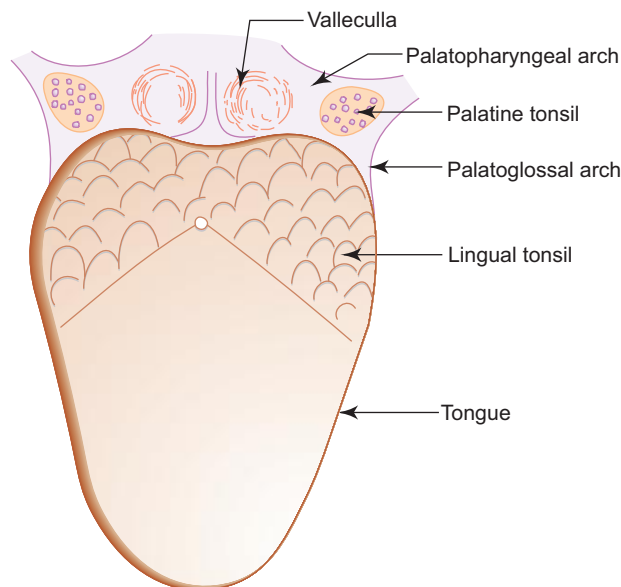
In spite of many functions, spleen can be surgically removed (splenectomy), if required. Removal does not cause any adverse effect.

Spleen may enlarge secondary to malaria and leukaemia.

In leukaemia, the spleen may reinitiate its haemopoietic function and undergo a process known as **myeloid metaplasia**.

## PALATINE TONSIL

- It is an almond-shaped structure situated on the lateral wall of the oropharynx in the tonsillar fossa, which is bounded by the palatoglossal arch in front and palatopharyngeal arch behind (Fig. 7.6). Its lateral surface, which lies on the tonsillar bed, is covered by a connective tissue capsule.



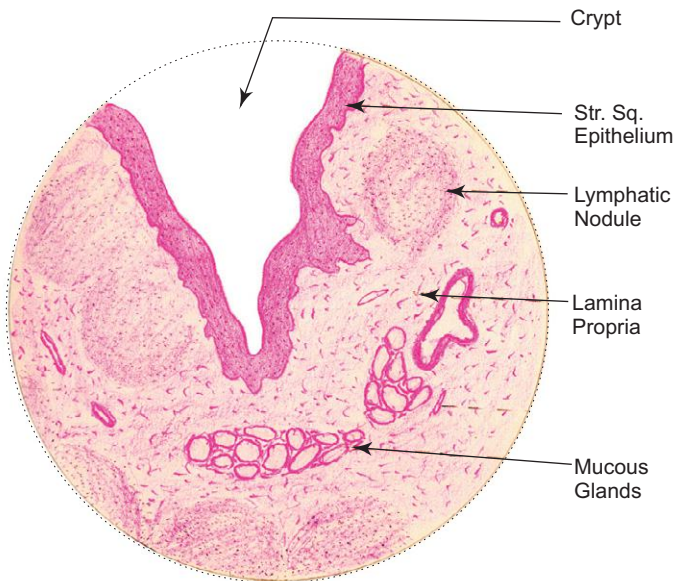
**Fig. 7.6** Location of palatine tonsil.

- Its medial exposed surface (facing the pharynx) shows many (10–15) small orifices, which lead into crypts inside the substance of tonsil. The medial surface and the crypts are lined by stratified squamous epithelium. On either side of the crypts, the lamina propria contains lymphatic nodules (Fig. 7.7).

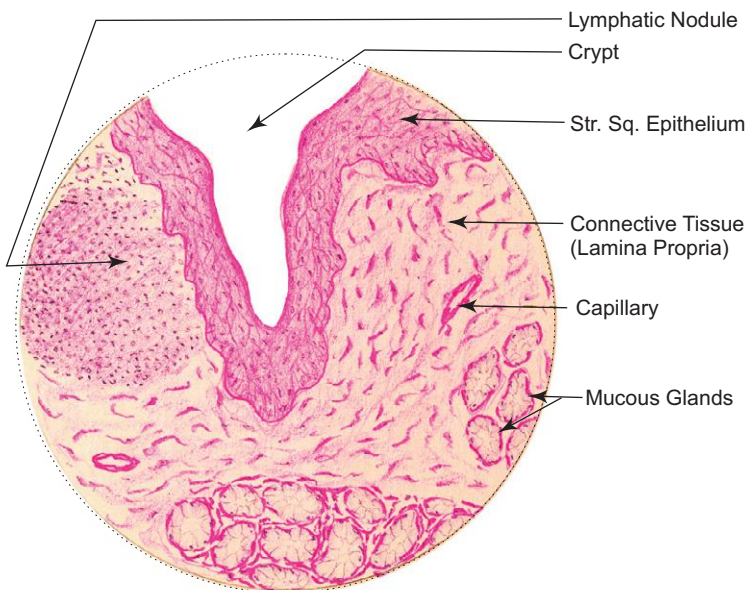
**Box 7.4 Tonsil.**

*Presence of*

- (i) **crypts** lined by **stratified squamous epithelium**;
- (ii) sub epithelial **lymphatic nodule**;
- (iii) **mucous glands**.

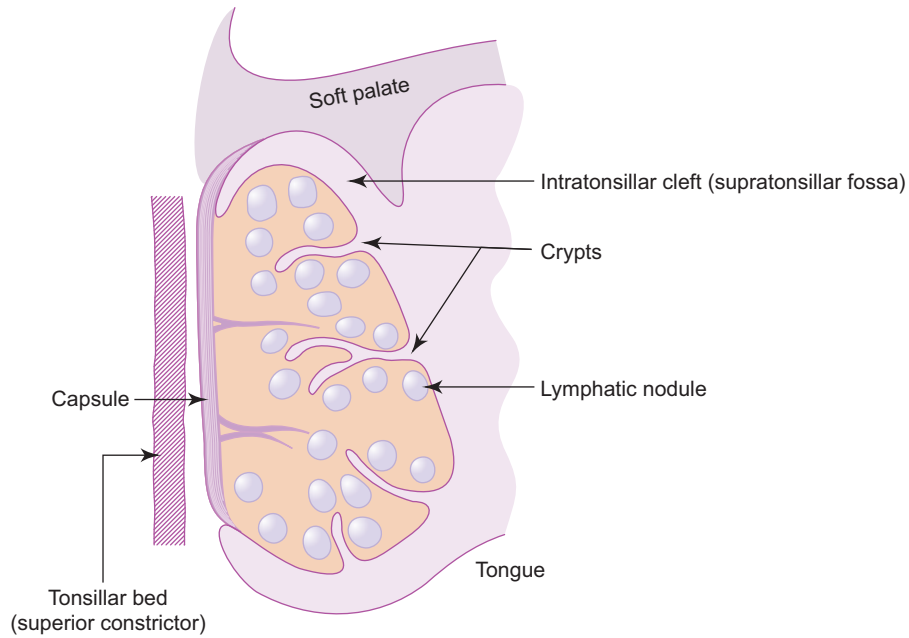


**L/P**  
**Tonsil**



**H/P**  
**Tonsil**





**Fig. 7.7** Coronal section of palatine tonsil.

- There are many mucous glands situated in the deeper part of tonsil outside capsule and their ducts open at the bottom of the crypts (Box 7.4); majority do not open in crypts, so chance of tonsillitis is more.
- Though tonsil belongs to the MALT, it is considered as an organ because it is partially surrounded by a capsule.

In tonsillitis, the mouth of the crypts may appear as purulent spot due to infection and pus formation.

# Self-assessment Exercise

## I. Write short notes on:

- (a) Histology of thymus
- (b) Palatine tonsil
- (c) Splenic circulation
- (d) Splenic pulps
- (e) Lymph node

## II. Fill in the blanks:

1. The defense mechanism mediated by B lymphocytes is called \_\_\_\_\_
2. The defense mechanism mediated by T lymphocytes is called \_\_\_\_\_
3. Plasma cells secrete \_\_\_\_\_
4. Red pulp of spleen is made of \_\_\_\_\_ and \_\_\_\_\_
5. Blood thymus barrier is found in \_\_\_\_\_ of lobule.

## III. Choose the best answer:

1. Thymus has the following features *except* that it
  - (a) is a central lymphoid organ
  - (b) has no reticular fibres and reticular cells
  - (c) involutes after puberty
  - (d) is formed by B lymphocytes
2. Thymus-dependent zone of a lymph node is
  - (a) cortex
  - (b) paracortex
  - (c) medullary cords
  - (d) medullary sinuses.
3. The main type of immunoglobulin present in various glandular secretions is
  - (a) IgG
  - (b) IgA
  - (c) IgM
  - (d) IgE
4. The percentage of T lymphocyte present in blood is
  - (a) 80
  - (b) 40
  - (c) 20
  - (d) 10
5. Which one of the following is *not* an antigen-presenting cell?
  - (a) Langerhans' cell
  - (b) Follicular dendritic cell

- (c) M cell
  - (d) Mast cell
6. White pulp of spleen can be identified differentially from the lymphatic nodule of lymph node by the presence of
- (a) germinal centre
  - (b) corona
  - (c) central arteriole
  - (d) lymphocytes
7. Crypts of palatine tonsil are lined by
- (a) simple squamous epithelium
  - (b) stratified squamous nonkeratinized epithelium
  - (c) pseudostratified columnar epithelium
  - (d) stratified squamous keratinized epithelium
8. Hassall's corpuscles are present in
- (a) lymph node
  - (b) spleen
  - (c) thymus
  - (d) tonsil
9. A section of lymph node can be identified by the presence of
- (a) thick trabeculae
  - (b) interlobular septum
  - (c) white pulp
  - (d) subcapsular sinus
10. Splenic sinuses are lined by
- (a) fenestrated endothelium
  - (b) discontinuous endothelium
  - (c) continuous endothelium
  - (d) columnar epithelium

**IV. State whether the following statements are true (T) or false (F):**

- 1. Interferon is an antiviral substance produced by macrophages ( )
- 2. B and T lymphocytes are morphologically similar but functionally different ( )
- 3. T lymphocytes acquire their immunocompetency in bone marrow ( )
- 4. B lymphocytes differentiate into plasma cells ( )
- 5. IgA is the most abundant type of immunoglobulin ( )
- 6. Mucosa-associated lymphoid tissue (MALT) in man can be considered equivalent to Bursa of Fabricius in birds ( )
- 7. Spleen has both afferent and efferent lymphatic vessels ( )
- 8. Palatine tonsil is completely covered by capsule ( )
- 9. Flow of lymph in a lymph node is in one direction ( )
- 10. Epithelial reticular cell of thymus is derived from endoderm ( )

**V. Match the items in column 'A' with those of column 'B':**

Column 'A'		Column 'B'	
1. Penicilli	( )	a. Central arteriole	
2. Splenic sinusoid	( )	b. T lymphocyte	
3. Periarterial lymphatic sheath (PALS)	( )	c. Discontinuous endothelium	
4. White pulp	( )	d. Ellipsoid	

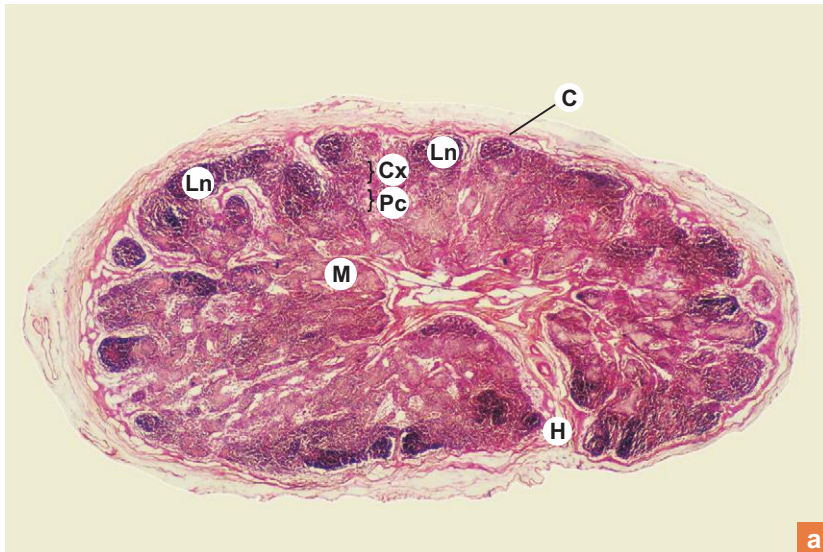
**Answers**

- II.** 1. Humoral immunity      2. Cell mediated immunity      3. Immunoglobulins (antibodies)  
 4. Splenic cords (Bilroth cords) and splenic sinuses      5. cortex.
- III.** 1. d    2. b    3. b    4. a    5. d    6. c    7. b    8. c    9. d    10. b
- IV.** 1. (T)    2. (T)    3. (F)    4. (T)    5. (F)    6. (T)    7. (F)    8. (F)    9. (T)    10. (T)
- V.** 1. d    2. c    3. b    4. a

# Practical No. 7

## Lymphoid and Haemopoietic Tissue

X10



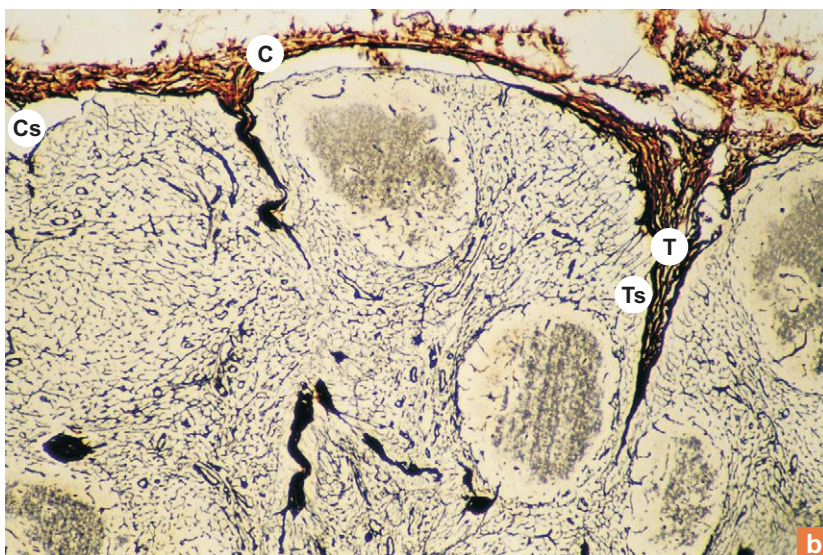
**Plate 7:1a**

**Lymph node (panoramic view).**

Plate 7:1a shows the panoramic view of the lymph node stained with H&E, depicting the architecture of the organ. Identify the following structures:

- **Thin Capsule (c)** that surrounds the lymph node.
- Darkly stained **cortex (Cx)** containing lymphatic nodules (**Ln**).
- Lightly stained **medulla (M)**.
- Dense **paracortex (Pc)** between cortex and medulla.
- The indented **hilum (H)** through which efferent lymphatics leave.

X40



**Plate 7:1b**

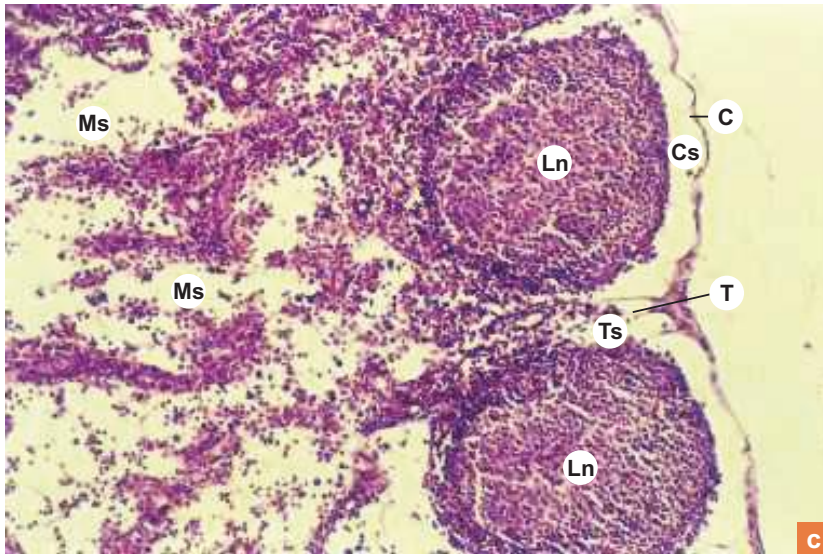
**Lymph node (reticular fibres).**

Plate 7:1b shows the low power view of the lymph node stained with special stain (silver) to show the reticular meshwork. The reticular network gives structural support to the lymph node. Identify the following structures:

- Capsule (**C**).
- Trabeculae (**T**).
- Subcapsular sinus (**Cs**).
- Trabecular sinus (**Ts**).
- Medullary sinus (not seen).

Note, the network is coarse (dense) in the cortical region and fine in the region of sinuses.

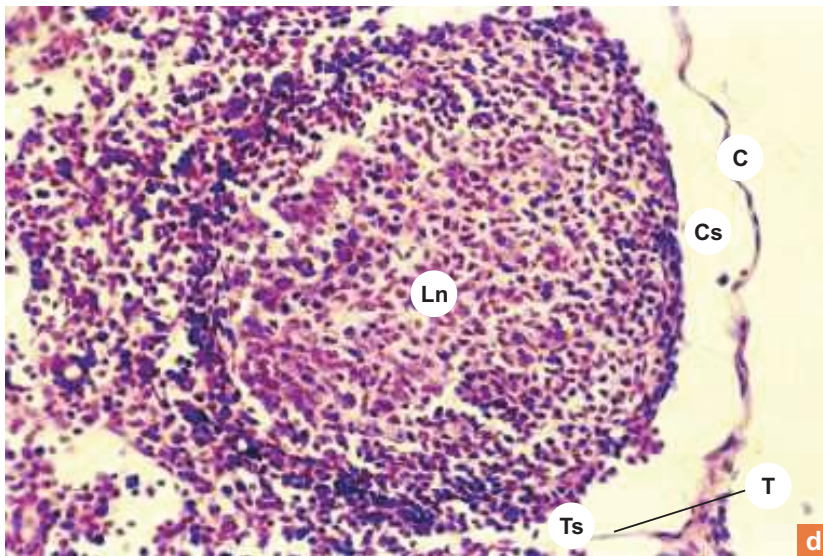
X40


**Plate 7:1** Lymph node (cortex).  
**c and d**

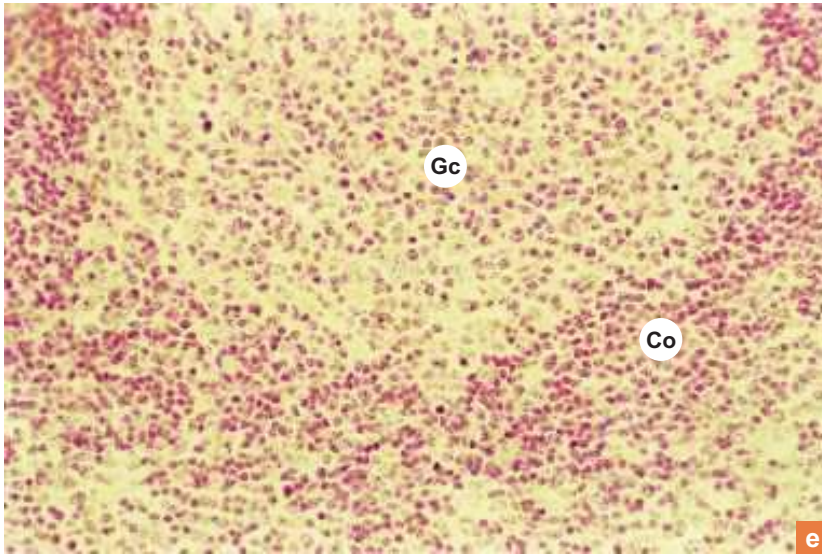
Examine the cortex of the lymph node at low (Plate 7:1c) and high (Plate 7:1d) magnification and identify the following structures:

- Thin capsule (C).
  - Subcapsular sinus (Cs).
  - Lymphatic nodules (Ln).
  - Trabeculum (T) and trabecular sinus (Ts).
- Ms = medullary sinus.

X100



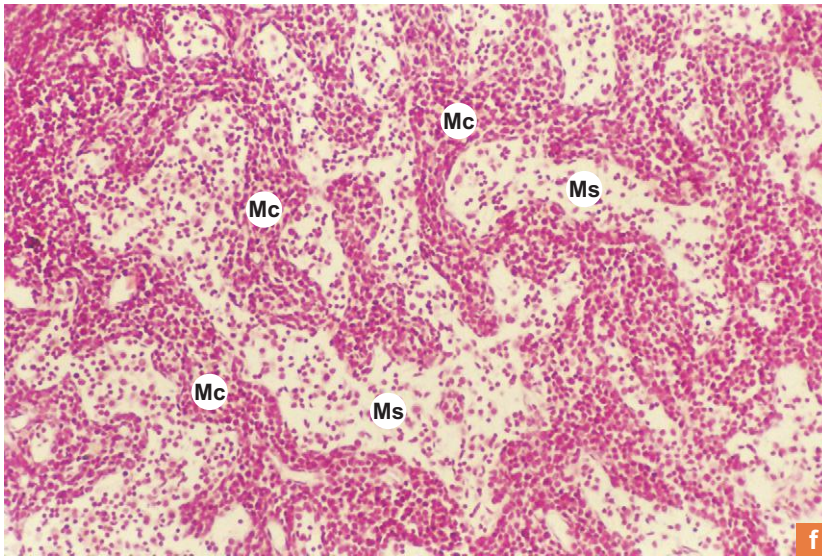
X200


**Plate 7:1e Lymphatic nodule (secondary).**

Examine a lymphatic nodule with germinal centre (secondary nodule) under high power (Plate 7:1e) and appreciate:

- The lightly stained germinal centre (**Gc**) made up of large lymphocytes (lymphoblasts) which may show mitotic division.
- The darkly stained corona (**Co**) made of small lymphocytes.

X100


**Plate 7:1f Lymph node (medulla).**

Examine the medulla (Plate 7:1f) and identify the following structures:

- The darkly stained *medullary cords* (**Mc**) (typical lymphoid tissue).
- The lightly stained *medullary sinuses* (**Ms**) (atypical lymphoid tissue).

X10

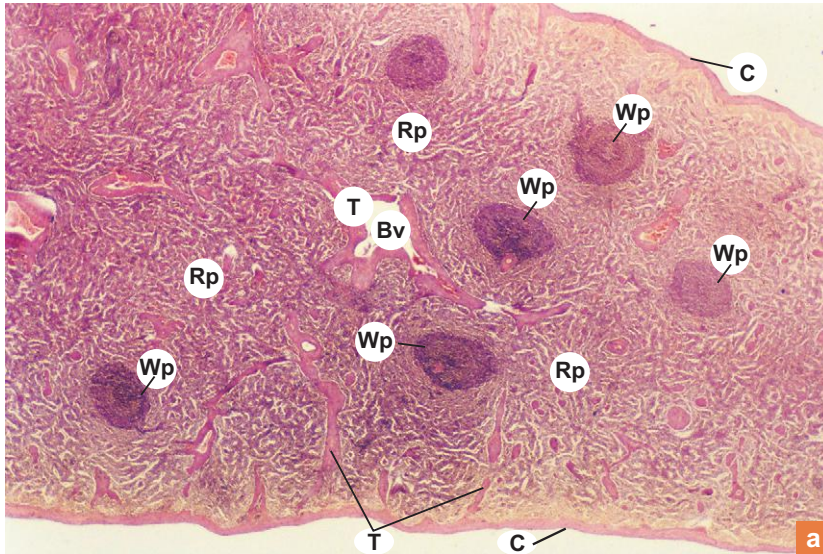


Plate 7:2a

Spleen (panoramic view).

Plate 7:2a shows the panoramic view of a section of spleen stained with H&E. Note the following structures:

- A thick capsule (C) covering the organ.
- Trabeculae (T) cut at different planes carrying trabecular blood vessels (Bv).
- Darkly stained round areas, the white pulp (Wp) is distributed randomly among the red pulp (Rp).

X40

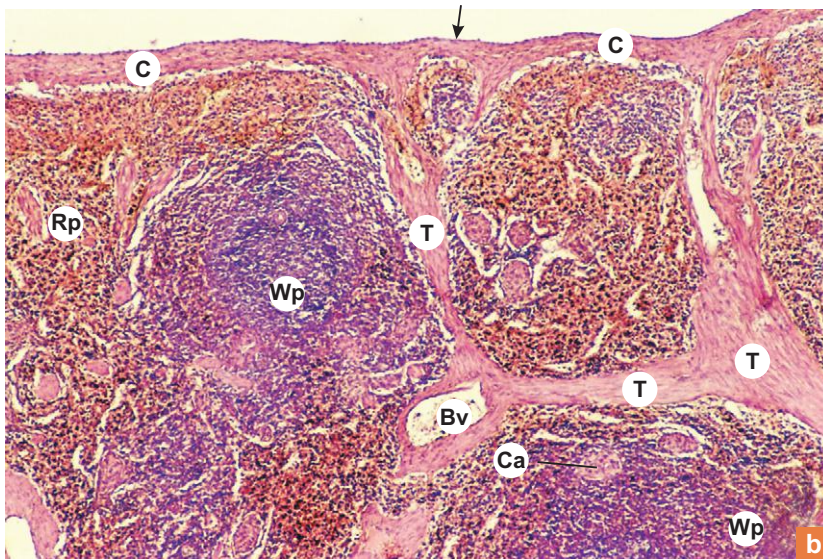


Plate 7:2b

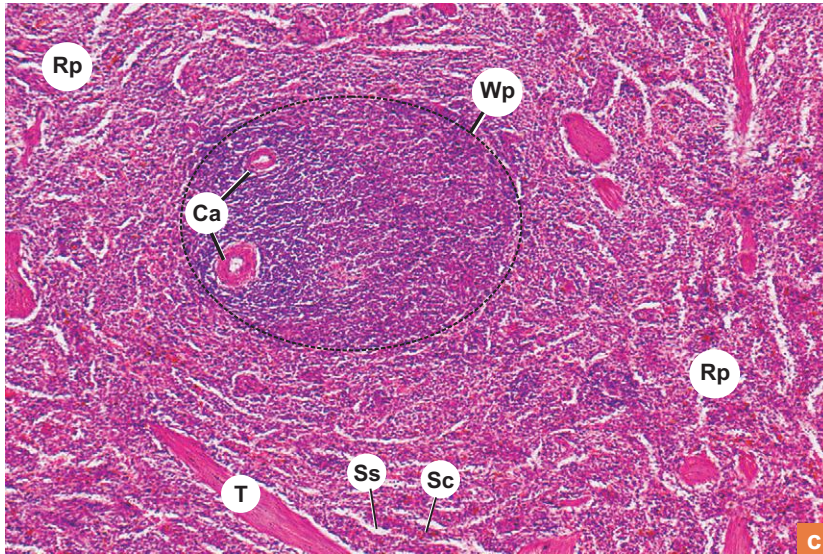
Spleen.

Examine the spleen at low magnification (Plate 7:2b) and identify the following structures:

- Thick fibroelastic capsule (C) covered externally by mesothelium (arrow).
- **Thick and robust trabeculae** (T) containing trabecular vessels (Bv).
- **White pulp** (Wp) traversed by an arteriole called central artery (Ca) which is often eccentrically placed.
- **Red pulp** (Rp) that fills the area between the white pulp.



X100



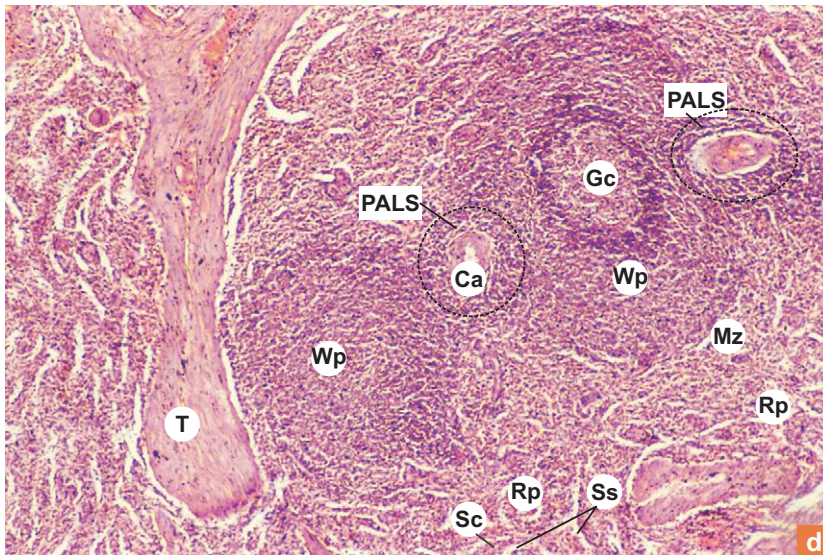
### Plate 7:2c Spleen (pulp). and d

Examine the parenchyma (pulp) at a still higher magnification (Plate 7:2c and d) and note the following:

- Red pulp (**Rp**), made of splenic cords (**Sc**) and sinuses (**Ss**).
- White pulp (**Wp**) made of lymphatic aggregation showing germinal centre (**Gc**), marginal zone (**Mz**) and periarterial lymphatic sheath (**PALS**) around the central artery (**Ca**).

**T** = trabeculae.

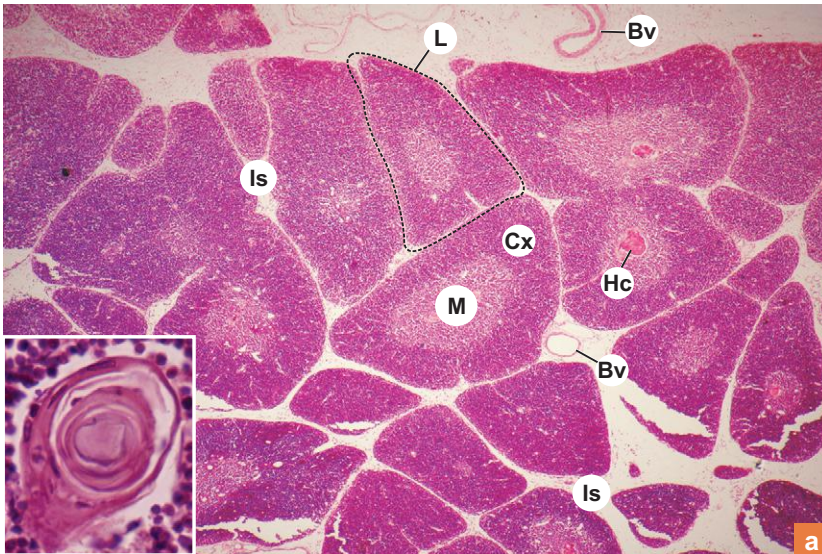
X100



The section of spleen differs from the section of lymph node because of the following features in the former:

- No differentiation of cortex and medulla.
- Lymphatic nodules (white pulp) are traversed by arteriole (central artery).
- No subcapsular or trabecular sinuses.
- The capsule and trabeculae are thicker and may contain smooth muscle fibres.
- Splenic sinuses are venous sinuses.
- No afferent lymphatic vessels.
- Spleen is in the bloodstream (not lymphatic).

X40

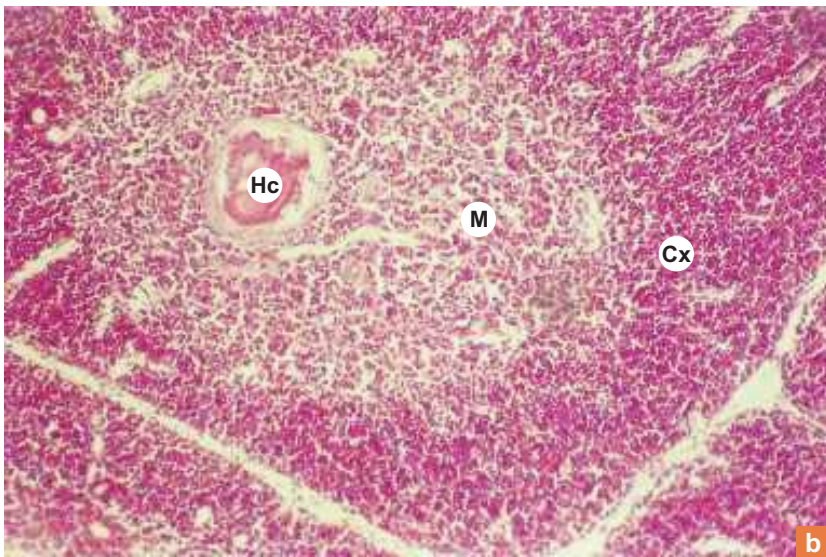

**Plate 7:3a** Thymus (Inset: Hassall's corpuscle).

At low magnification (Plate 7:3a) identify the following structures:

- The **lobules** (L), separated by interlobular connective tissue septum (Is) carrying blood vessels.
- The two distinct zones of the lobules; outer darkly stained **cortex** (Cx) and inner lightly stained **medulla** (M).

In the medulla, look for eosinophilic bodies, the **Hassall's corpuscles** (Hc) inset.

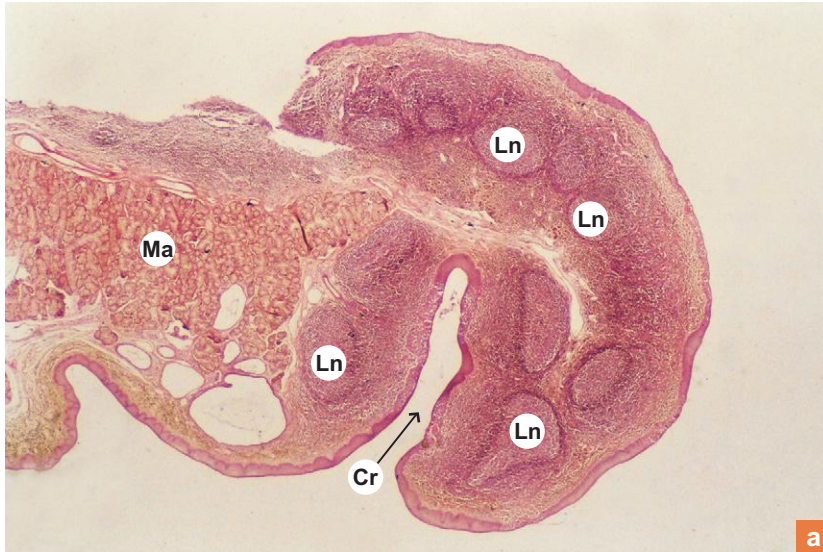
X100


**Plate 7:3b** Thymus.

At a higher magnification (Plate 7:3b) observe the cellular detail of the cortex and medulla of a lobule.

- The cortex (Cx) shows
  - densely packed lymphocytes/thymocytes (many) and
  - few pale stained macrophages and epithelial reticular cells.
- The medulla (M) shows
  - loosely packed lymphocytes/thymocytes (few) and pale-stained epithelial reticular cells,
  - postcapillary venules, and
  - lamellated eosinophilic bodies, the Hassall's corpuscles (Hc).

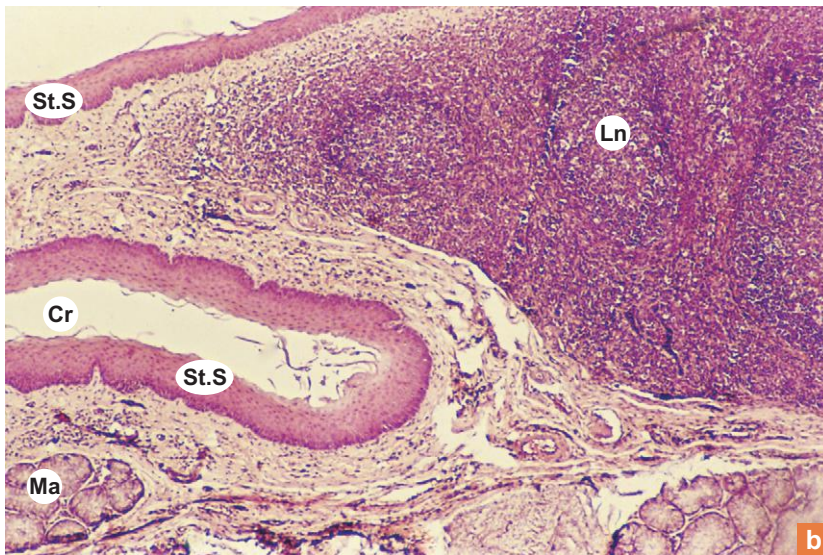
X10



**Plate 7:4a** Palatine tonsil  
(panoramic view).

Plate 7:4a shows the panoramic view of a tonsil. Note the crypts (Cr), lymphatic nodules (Ln) and mucous glands (Ma).

X40



**Plate 7:4b** Palatine tonsil.

Examine the slide at low magnification (Plate 7:4b) and note the following features:

- **Crypts (Cr)** lined by *stratified squamous epithelium*.
- The epithelium often shows erosion due to infiltration of lymphocytes.
- The **lymphatic nodules (Ln)** which may show germinal centres.
- Group of **mucous acini (Ma)**.

X100

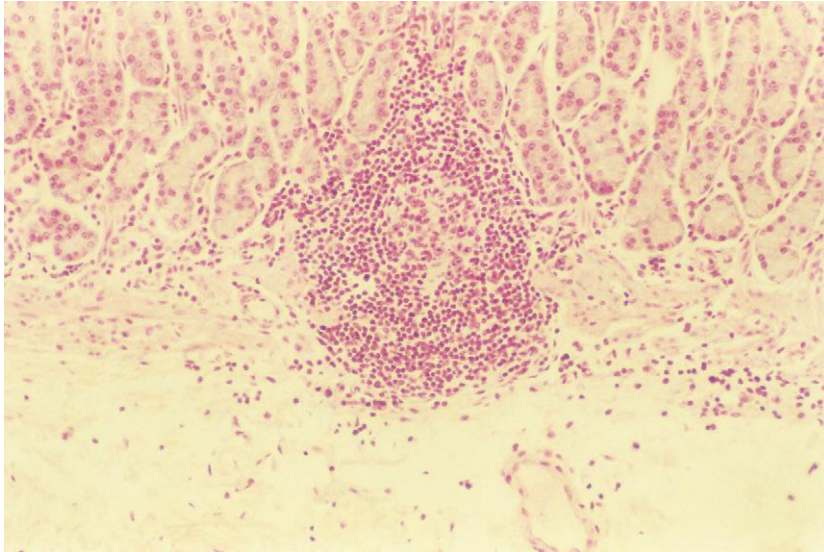
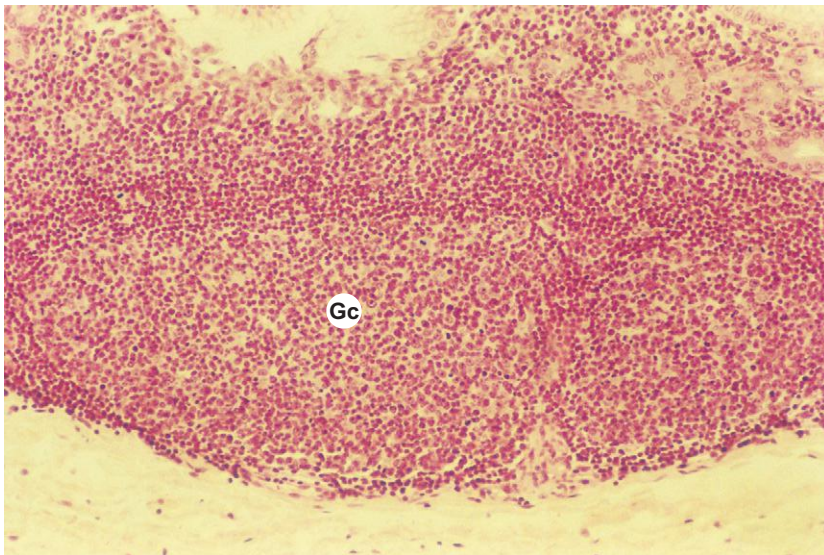
**Plate 7:5 Solitary lymphatic nodule.**

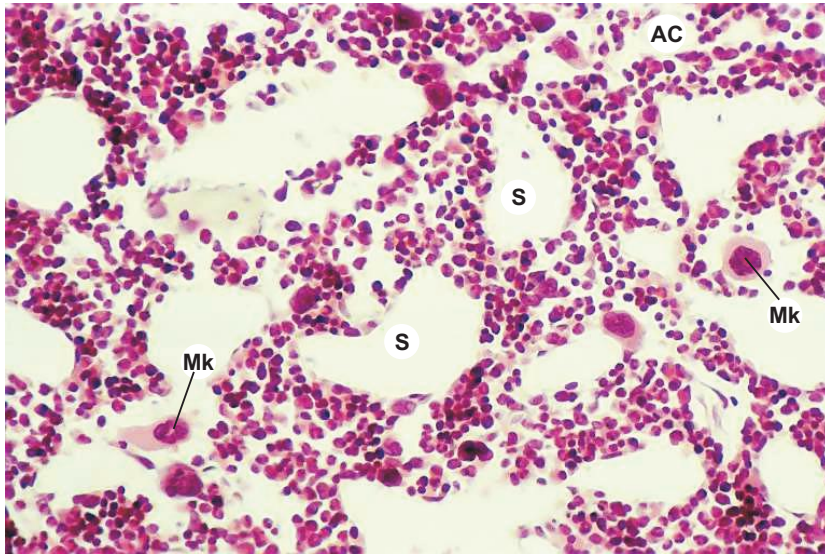
Plate 7.5 illustrates a small solitary lymphatic nodule in the lamina propria of stomach. Note the small germinal centre in the nodule.

X100

**Plate 7:6 Aggregated lymphatic nodule.**

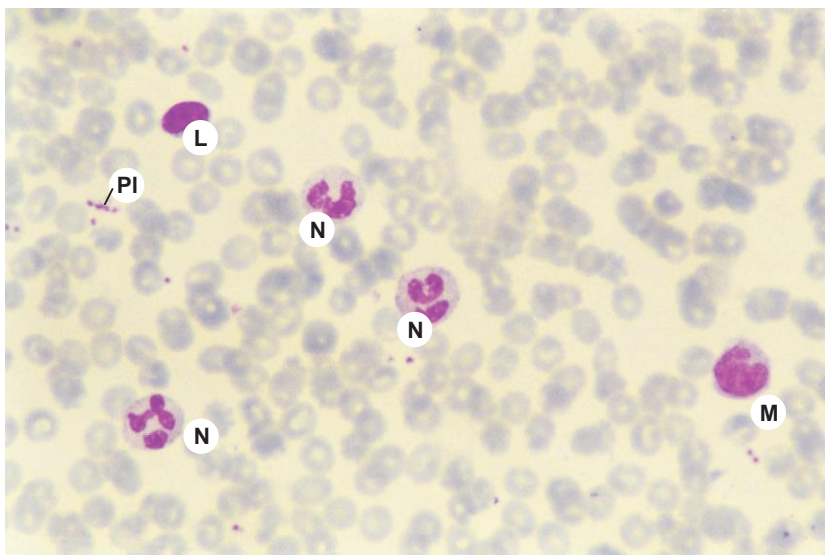
This micrograph (Plate 7:6) illustrates a group of three aggregated lymphatic nodules present in the submucosa of stomach. The nodules contain germinal centres (Gc).

X200

**Plate 7:7** Bone marrow.

A section of bone marrow (Plate 7:7) when examined at high magnification shows densely packed *haemopoietic cells* at different stages of maturation, pervaded by broad irregular *sinusoids* (S). The most prominent and easily identifiable cells in the bone marrow are the *megakaryocytes* (Mk). They are giant cells (80–100  $\mu\text{m}$ ) with large convoluted nucleus. The bone marrow is also infiltrated with large *adipocytes* (Ac).

X400

**Plate 7:8** Blood smear.

A blood smear at high magnification (Plate 7:8) presents various types of blood cells. The most abundant cells are the erythrocytes (red blood cells). These cells are of uniform size (7.5  $\mu\text{m}$ ) and do not possess nuclei. In addition to numerous erythrocytes, several leukocytes (white blood cells) can be identified in the smear. The various types of leukocytes can be identified, based on the nuclear characteristics, cytoplasmic granules and their staining quality. In this micrograph neutrophils (N), lymphocyte (L) and monocyte (M) are seen. (For further details refer to textbooks on Physiology.)

Pl = platelets.

# 8

# MUSCULAR TISSUE

## INTRODUCTION

A muscle is a collection of muscle fibres supported by connective tissue. Each muscle fibre is an elongated cell, which contains contractile proteins, mainly actin and myosin. Interaction amongst contractile proteins causes *contraction*, which is a unique function of muscular tissue. It is mesodermal in origin. Special terms have been used for the various cytoplasmic organelles of the muscle fibres:

- Plasma membrane—sarcolemma
- Cytoplasm—sarcoplasm
- Smooth endoplasmic reticulum—sarcoplasmic reticulum
- Mitochondria—sarcosomes

## TYPES

- There are following three types of muscles:
  1. Skeletal or striated muscle
  2. Cardiac muscle
  3. Smooth or visceral muscle
- Apart from the above three types there are contractile cells functioning as single cell units, namely,
  1. Myoepithelial cells (found in association with secretory acini)
  2. Myofibroblasts (involved in wound healing)
  3. Myoid cells (found around seminiferous tubules)

## SKELETAL MUSCLE

### GENERAL FEATURES

- The skeletal muscle fibres are elongated, cylindrical, multinucleated cells whose length varies from few millimetre to 35 cm and width from 10  $\mu\text{m}$  to 100  $\mu\text{m}$  (Box 8.1).

### GENERAL ARCHITECTURE

- The skeletal muscle fibres are supported by connective tissue framework which can be well appreciated in the cross section of a muscle (Fig. 8.1).
- The connective tissue framework carries blood vessels and nerves and also transmits the force of contraction through aponeuroses and tendons.

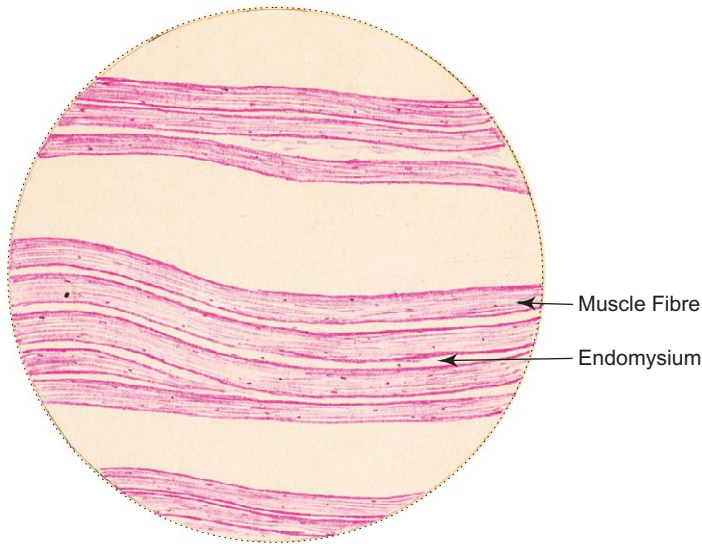
The framework of connective tissue provides support to muscle fibres in following manner:

- *Epimysium* – dense connective tissue sheath surrounding the entire muscle.
- *Perimysium* – connective tissue covering bundles of muscle fibres called fascicles.
- *Endomysium* – loose connective tissue composed of reticular fibres supporting individual muscle fibre.

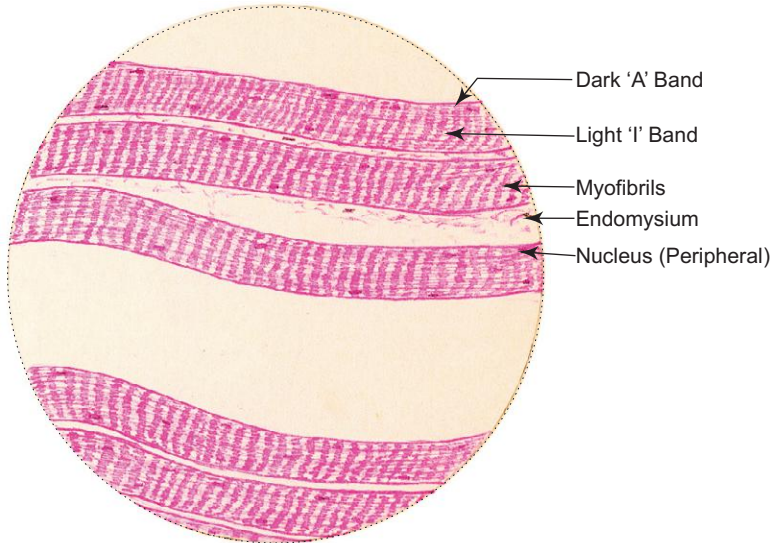
**Box 8.1** Skeletal Muscle (L.S.).

Presence of

- (i) **cross striations** (prominent) dark 'A' bands and light 'I' bands;
- (ii) **many, flat, peripheral nuclei**;
- (iii) long, parallel, cylindrical fibres **without branching**.



*L/P*  
Skeletal muscle (L.S.)



*H/P*  
Skeletal muscle (L.S.)

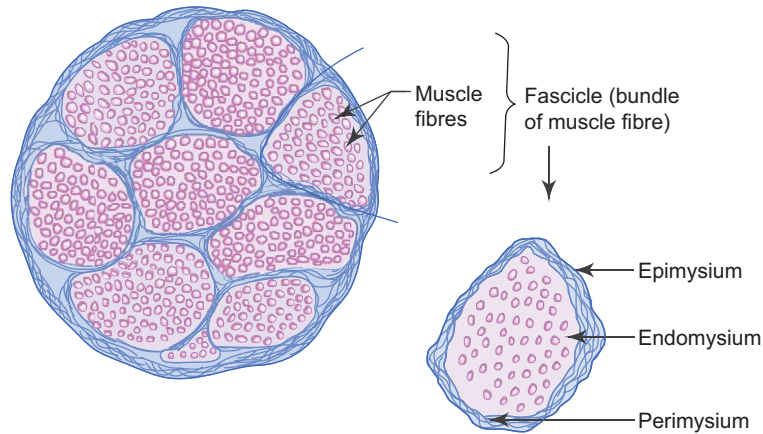


Fig. 8.1 Cross section of skeletal muscle.

## STRUCTURE OF A SKELETAL MUSCLE FIBRE

### Light Microscopic (LM) Observation

- Each muscle fibre is an elongated, unbranched cylindrical cell.
- It has many flat nuclei located just beneath the sarcolemma.
- It shows cross striations of alternate dark (A) and light (I) bands with Z line intersecting I band.
- Each muscle fibre is made of compactly packed long cylindrical *myofibrils* in the sarcoplasm arranged parallel to the long axis (Fig. 8.2).

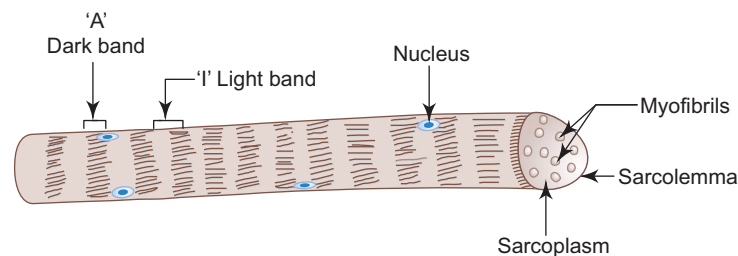


Fig. 8.2 Structure of a muscle fibre.

### Structure of a Myofibril under Electron Microscope (EM)

- The cross striations seen in a muscle fibre under LM is due to the presence of cross striations in the myofibrils. So each myofibril shows A (dark), I (light) and Z bands which are arranged in such a way as to give a muscle fibre cross striations (Fig. 8.3).
- The distance between two Z lines is a contractile unit called *sarcomere*.
- The cross striations seen in a myofibril under EM is due to the presence of orderly arrangement of contractile protein filaments (*myofilaments*) within it.



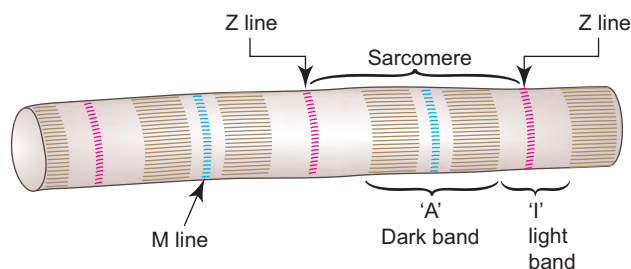


Fig. 8.3 Myofibril.

### Arrangement of Myofilaments in the Sarcomere (Fig. 8.4)

- The sarcomere consists of two types of myofilaments arranged parallel to the long axis of myofibril in a symmetrical fashion.
  - Thick filaments—composed mainly of the protein *myosin* and occupy the A band.
  - Thin filaments—composed mainly of the protein *actin* and also of tropomyosin and troponin. One end of each thin filament runs between and parallel to the thick ones in the A band for some distance. The other end of the filament is attached to the Z line in the I band.
- As a result of this arrangement of filaments, A band consists of thick filaments plus part of overlapping thin filaments and shows a lighter zone in the centre, the H band, composed of only thick filaments. I band consists of part of thin filaments that are not overlapping the thick filaments. M line is the region where lateral connections are made between adjacent thick filaments in the middle of the H band.

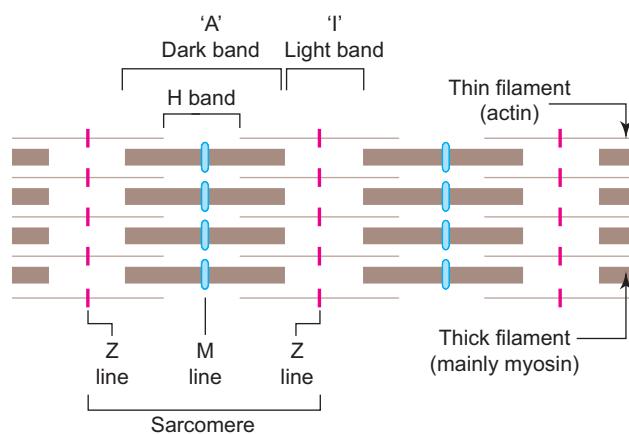


Fig. 8.4 Arrangement of myofilaments in sarcomere.

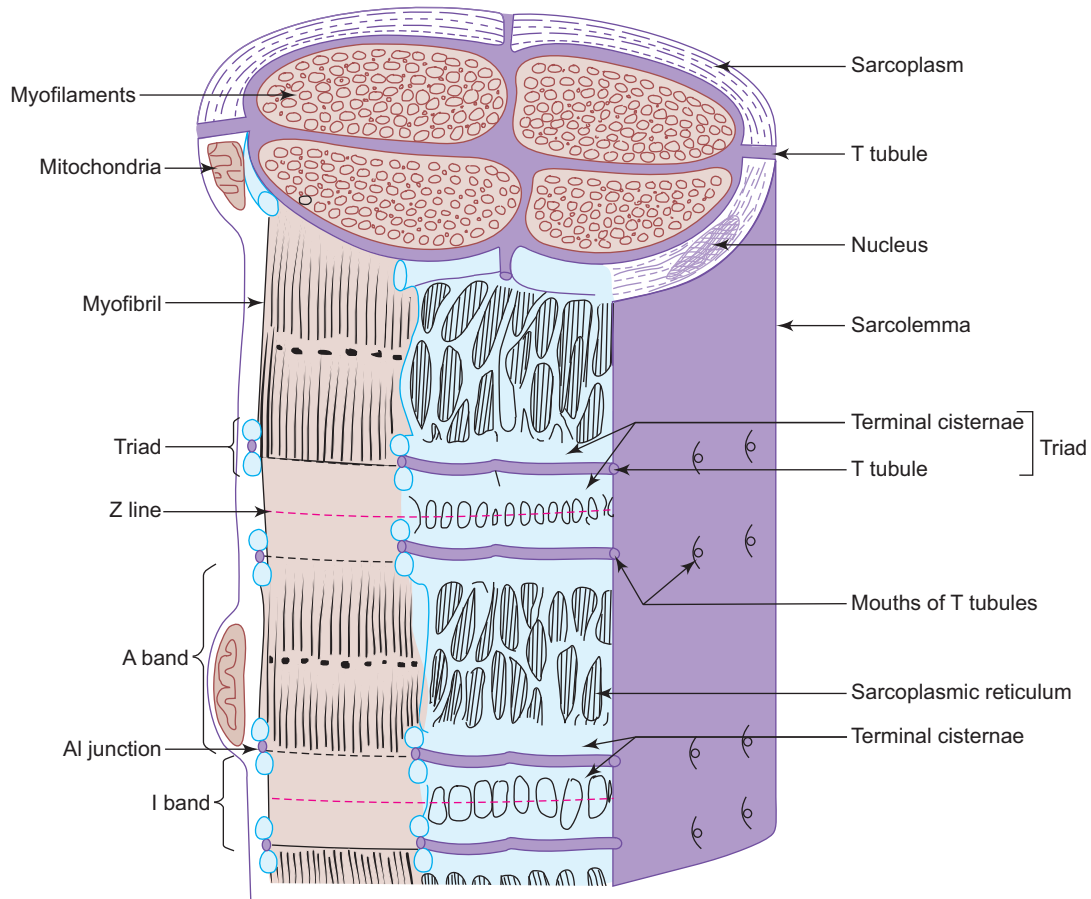
### CONTRACTION MECHANISM

During contraction there is **no shortening** of individual thick and thin myofilaments; but there is an increase in the degree of overlap between the filaments. In this regard, the widely accepted *sliding filament theory* proposed by Huxley states that under the influence of energy released from ATP and calcium ions released from sarcoplasmic reticulum, the thin and thick filaments slide over one another causing shortening of the sarcomere. Thus, in this process the A band remains constant in width whereas the I and H bands become narrow and the Z lines are drawn closer together.

### Transverse Tubule – Sarcoplasmic Reticulum Complex

To provide uniform contraction of all muscle fibres, the skeletal muscle possesses a system of *transverse (T) tubules*. These are finger-like invaginations of the sarcolemma extending into the sarcoplasm to surround each myofibril at the region of AI junction (it is the junction between A and I bands; Fig. 8.5). The T tubules are embraced on either side by the *terminal cisternae* of the *sarcoplasmic reticulum* forming a SR–T tubule–SR complex called *triad*, present at the junction of I and A bands of each sarcomere.

Depolarisation of the sarcolemma is rapidly disseminated throughout the sarcoplasm by the T tubule system, resulting in the release of calcium ions from the sarcoplasmic reticulum into the sarcoplasm causing contraction.



**Fig. 8.5** 3D structure of a skeletal muscle fibre showing triad.

### TYPES OF SKELETAL MUSCLE FIBRES

From morphological, histochemical and functional points of view, the skeletal muscle fibres can be classified into three types, namely, *red*, *white* and *intermediate*. The characteristic features of red and white fibres are presented in Table 8.1. The red and white colours are due to the presence of high and low content of *myoglobin* (analogous to haemoglobin) respectively.

**Table 8.1** Characteristics of red and white muscle fibres

Red muscle fibre (aerobic or type I)	White muscle fibre (anaerobic or type II)
1. High content of myoglobin and cytochrome	Low content of myoglobin and cytochrome
2. Many mitochondria	Few mitochondria
3. Rich blood supply	Poor blood supply
4. Succinate dehydrogenase myosin ATPase '+ve'	Succinate dehydrogenase myosin ATPase '-ve'
5. Slow and continuous contraction (not easily fatigued)	Rapid contraction (easily fatigued)
6. Smaller in diameter	Larger in diameter
7. e.g. Postural muscles	e.g. Extraocular muscles, flight muscles in birds

## MOTOR END-PLATES (BOX 8.2)

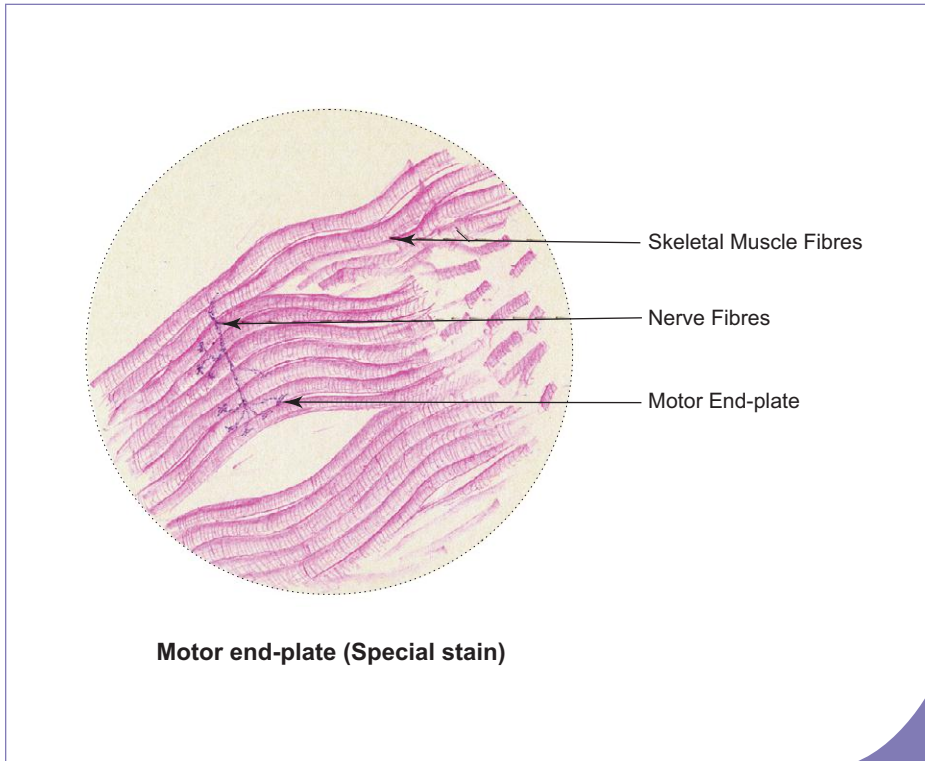
Skeletal muscle is richly innervated by myelinated motor nerves (axons). At the site of innervation, each axon divides into many terminal twigs that end in dilated bulbs called bouton terminals on the muscle surface. It is this specialised site where the axon terminates on the surface of skeletal muscle, that is called motor end-plate or neuromuscular junction. It is the site where the impulses from the axon are transmitted to the skeletal muscle fibres. The neurotransmitter released at the site is *acetylcholine*. (For more details refer to a Physiology textbook.)

**Myasthenia gravis** is an autoimmune disease characterised by progressive muscular weakness caused by reduction in the number of functionally active acetylcholine receptors at the neuromuscular junction. This reduction is caused by binding of the circulating antibodies to the acetylcholine receptors, thereby preventing the effective nerve muscle communication.

## MUSCLE SPINDLES

They are spindle-shaped encapsulated *stretch receptors* found in skeletal muscle lying parallel to the long axis of the muscle. Each muscle spindle is made of *intrafusal muscle fibres* and sensory nerve endings enclosed in a fusiform connective tissue capsule. The intrafusal fibres are smaller in diameter than the extrafusal muscle fibres (ordinary muscle fibres). The main function of the muscle spindle is to detect changes in the length of muscle fibres (*proprioceptive* function).

**Duchenne muscular dystrophy (DMD)** is a hereditary disease of skeletal muscle, which usually affects males. This disease is due to mutation of a gene responsible for formation of protein dystrophin on the inner surface of sarcolemma. The skeletal muscle becomes progressively weak from early childhood and by adolescence the person becomes immobile.



### Box 8.2 Motor End-plate (Special Stain).

Presence of

- (i) **skeletal muscle fibres** with cross striation;
- (ii) dark string-like myelinated **nerve fibres** ending in clusters of small swellings (motor end, plates) on the surface of muscle fibres;

## SMOOTH MUSCLE (Box 8.3)

Smooth muscle fibres are elongated spindle-shaped cells measuring 30  $\mu\text{m}$  in length in blood vessels to 200–500  $\mu\text{m}$  in pregnant uterus. They are nonstriated (smooth), involuntary and supplied by autonomic nervous system. Adjacent smooth muscle cells are in contact with each other through gap junctions which help to transmit the electric impulses from one cell to another, resulting in simultaneous contraction of the entire muscle. Smooth muscle fibres are found in the walls of hollow viscera (*viz.*, G.I.T., blood vessels, ureter, uterine tube, vas deferens, etc.) and also occur as separate entities like arrector pili, ciliaris, sphincter pupillae, etc.

## CARDIAC MUSCLE (Box 8.4)

Cardiac muscle shows many structural and functional characteristics intermediate between those of skeletal and smooth muscle. Though it exhibits cross striations, like skeletal muscle it is involuntary and contracts automatically like smooth muscle.

Cardiac muscle fibres are shorter than the skeletal muscle fibres and show branching pattern. They have one or two nuclei placed in the centre. The most striking feature of cardiac muscle is the presence of darkly staining transverse lines across the fibres called *intercalated discs* which are specialised cell junctions between the ends of adjacent muscle fibres. These cell junctions (gap junction and desmosomes) provide a mechanism by which the contractile stimuli pass from one cell to another causing the adjacent cell to contract simultaneously. Thus cardiac muscle acts as a *functional syncytium*.

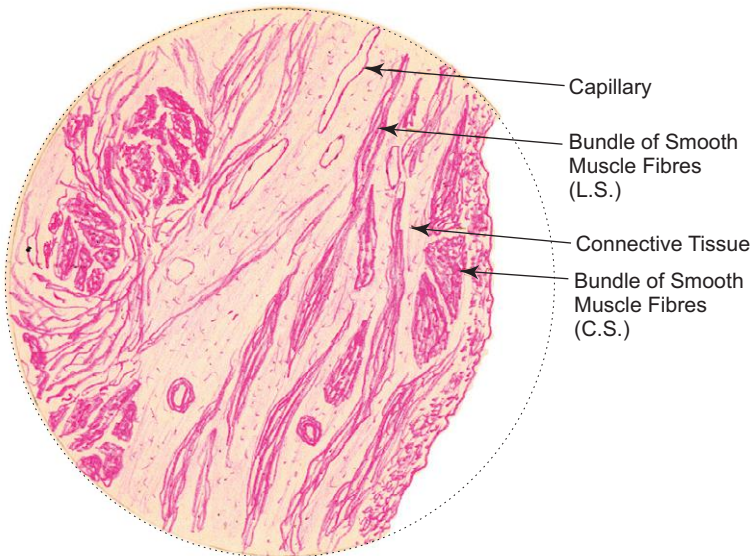
The conducting system of the heart (SA node, AV node, bundle of His and Purkinje fibres) is made of modified cardiac muscle fibres, which are thicker, larger and contain few myofilaments and found just deep to the endocardium.

The salient features of the three types of muscles are enumerated in Table 8.2.

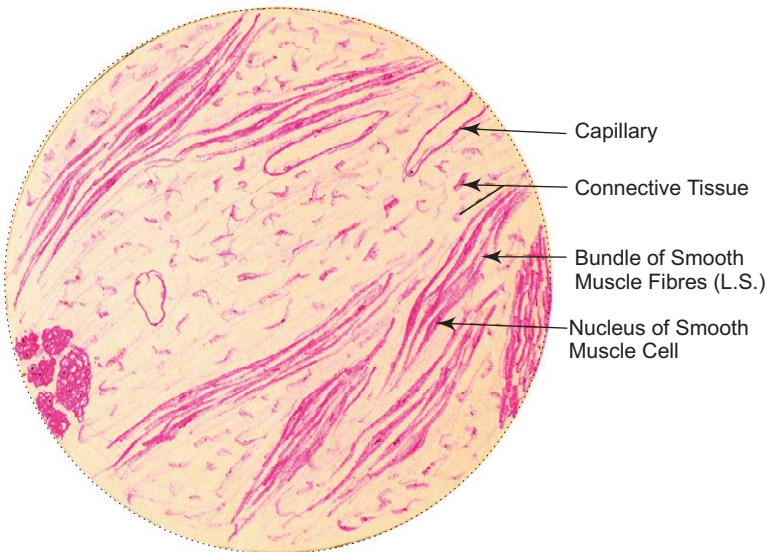
**Box 8.3 Smooth Muscle (L.S.).**

*Presence of*

- (i) elongated spindle-shaped cells;
- (ii) no striations;
- (iii) single elongated nucleus central in position.



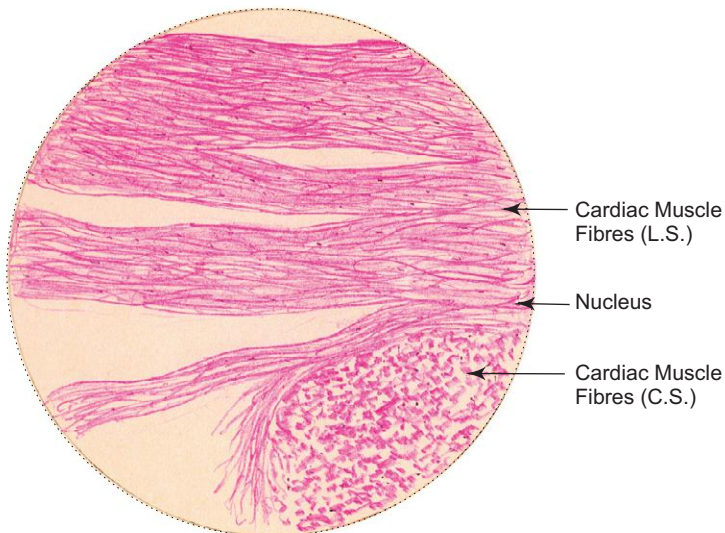
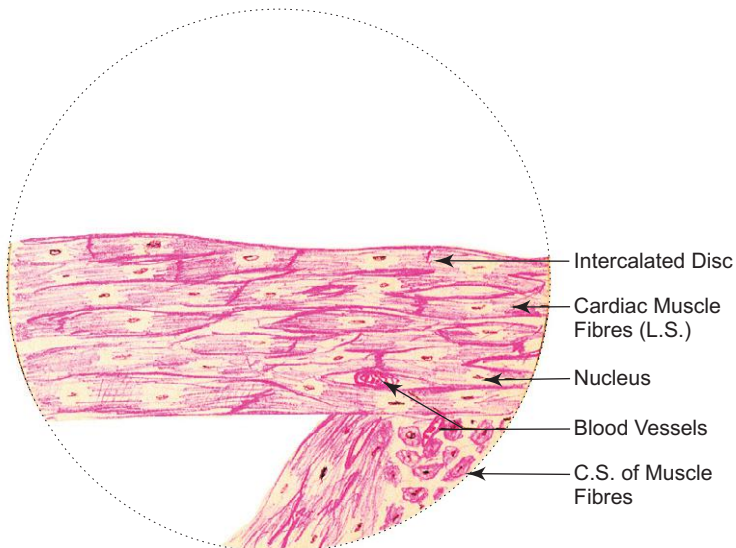
*L/P*  
**Smooth muscle (L.S.)**



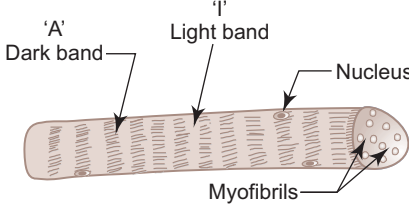
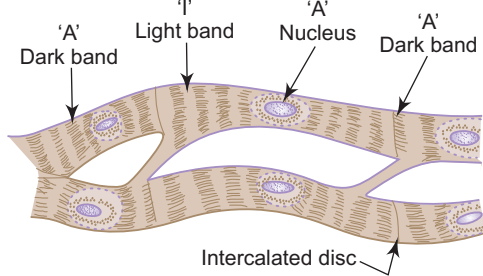
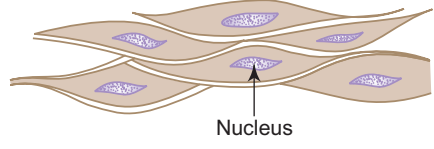
*H/P*  
**Smooth muscle (L.S.)**

**Box 8.4 Cardiac Muscle (L.S.).***Presence of*

- (i) **cross striations** with dark 'A' bands and light I bands (less prominent);
- (ii) **single, oval centrally placed nucleus;**
- (iii) **short, branching fibres.**

*L/P***Cardiac muscle (L.S.)***H/P***Cardiac muscle (L.S.)**

**Table 8.2** Comparison of various types of muscles

Skeletal muscle	Cardiac muscle	Smooth muscle (Visceral muscle)
		
<ol style="list-style-type: none"> <li>15–100 <math>\mu\text{m}</math> thick (uniform diameter)</li> <li>Long cylindrical fibres (up to 35 cm)</li> <li>Many flat, peripheral nuclei</li> <li>Striations well-defined (due to orderly arrangement of myofilaments)</li> <li>No intercalated discs</li> <li>T tubules present at A–I junction</li> <li>Sarcoplasmic reticulum (SR) forms triads</li> <li>Mitochondria—moderate</li> <li>Regeneration is restricted</li> <li>Contraction is under voluntary control (somatic innervation)</li> <li>Quick, forceful contraction</li> </ol>	<ol style="list-style-type: none"> <li>15 <math>\mu\text{m}</math> thick (uniform diameter)</li> <li>Short branched fibres (85–100 <math>\mu\text{m}</math>)</li> <li>One or two, oval, centrally placed nuclei</li> <li>Striations poorly defined</li> <li>Presence of intercalated discs</li> <li>T tubules present at Z line</li> <li>SR forms diads</li> <li>Mitochondria—more</li> <li>No regeneration</li> <li>Involuntary contraction (autonomic innervation)</li> <li>Continuous, rhythmic contraction</li> </ol>	<ol style="list-style-type: none"> <li>5–10 <math>\mu\text{m}</math> thick (no uniform diameter)</li> <li>Long fusiform fibres (30–200 <math>\mu\text{m}</math>)</li> <li>Single elongated central nuclei (corkscrew in contracted state)</li> <li>Nonstriated (smooth, no orderly arrangement of myofilaments which are obliquely disposed)</li> <li>–</li> <li>No T tubules, only caveolae (vesicles)</li> <li>–</li> <li>Mitochondria—less</li> <li>Extensive regeneration</li> <li>Involuntary contraction (autonomic innervation)</li> <li>Slow, sustained contraction or wave-like peristaltic contraction</li> </ol>

# Self-assessment Exercise

## I. Write short notes on:

- (a) Sarcomere
- (b) Cardiac muscle
- (c) Differences between skeletal and cardiac muscles

## II. Fill in the blanks:

1. The neurotransmitter released at motor end-plate is \_\_\_\_\_
2. The distance between the Z lines in a myofibril is called \_\_\_\_\_
3. The main contractile proteins present in a muscle fibres are \_\_\_\_\_
4. Smooth endoplasmic reticulum of a muscle fibre is called \_\_\_\_\_
5. The diameter of cardiac muscle is about \_\_\_\_\_

## III. Choose the best answer:

1. Which of the following muscle got good regenerative capacity?
  - (a) Red skeletal muscle
  - (b) White skeletal muscle
  - (c) Cardiac muscle
  - (d) Smooth muscle
2. The cardiac muscle can be identified by the presence of
  - (a) intercalated disc
  - (b) flat peripheral nuclei
  - (c) caveolae
  - (d) triads
3. The red skeletal muscle fibre is characterised by the presence of
  - (a) high content of myoglobin
  - (b) many mitochondria
  - (c) rich blood supply
  - (d) all of the above
4. Purkinje fibres of heart are made of
  - (a) autonomic nervous plexus
  - (b) collagen fibres
  - (c) modified cardiac muscle fibres
  - (d) modified nerve fibres
5. Loose connective tissue supporting the muscle fibres is called
  - (a) perimysium
  - (b) endomysium
  - (c) epimysium
  - (d) endoneurium



**IV. State whether the following statements are true (T) or false (F):**

1. The skeletal muscle fibre is an elongated multinucleated cell ( )
2. Myofibroblasts are contractile cells associated with secretory acini ( )
3. Perimysium surrounds the entire muscle ( )
4. T tubules are present at A-I junction in skeletal muscle ( )
5. Cardiac muscle fibres are shorter than the skeletal muscle fibres ( )

**V. Match the following items in column 'A' with those of column 'B':**

Column 'A'		Column 'B'
1. Skeletal muscle	( )	(a) Diad
2. Cardiac muscle	( )	(b) Proprioception
3. Smooth muscle	( )	(c) Conduction
4. Purkinje fibres	( )	(d) Triad
5. Muscle spindle	( )	(e) Caveolae

**Answers**

- II. 1. Acetylcholine      2. Sarcomere      3. Actin and Myosin      4. Sarcoplasmic reticulum      5. 15  $\mu$ m
- III. 1. d    2. a    3. d    4. c    5. b
- IV. 1. (T)    2. (F)    3. (F)    4. (T)    5. (T)
- V. 1. d    2. a    3. e    4. c    5. b

# Practical No. 8

## Muscular Tissue

X100

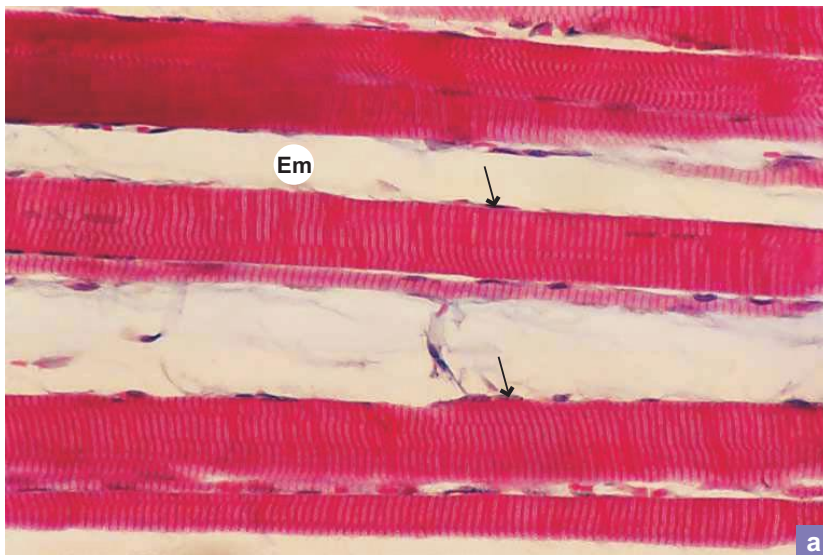


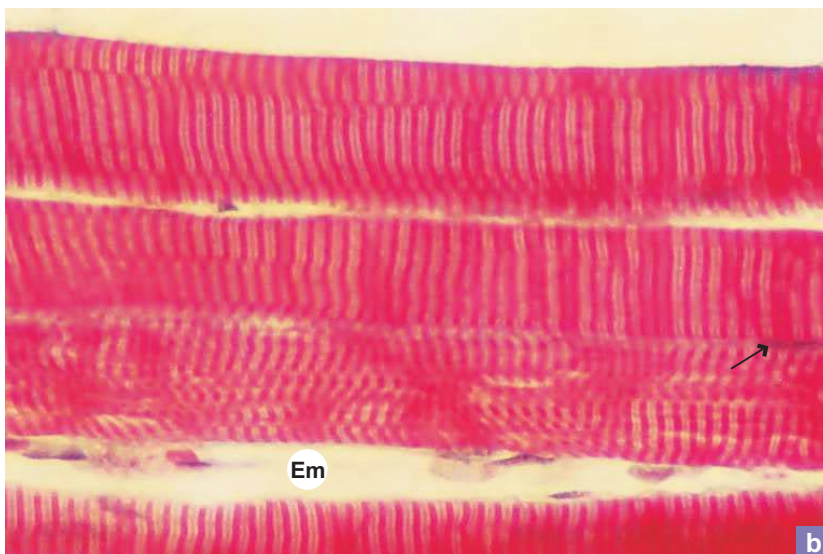
Plate 8:1  
a and b

L.S. of skeletal muscle.

Under low power (Plate 8:1a:), identify the following structures in a longitudinally sectioned skeletal muscle:

- Long cylindrical fibres with many nuclei (**arrow**) at the periphery.
- Endomysium (**Em**) separating the fibres.
- Cross striations of muscle fibres.

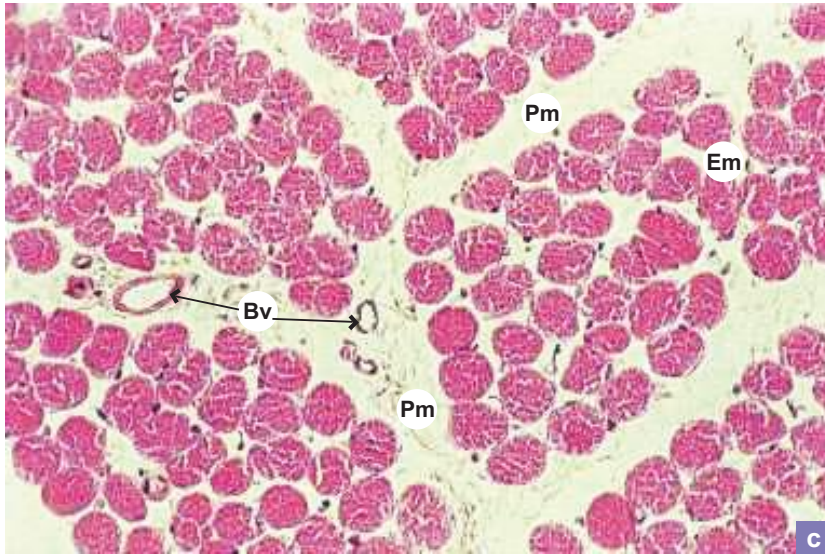
X200



Examine the same slide under high power (Plate 8:1b) and identify the following structures:

- Cross striations showing dark A bands and light I bands.
- Z discs may also be seen bisecting the light bands.
- Flat, peripheral nuclei (**arrow**).

X200

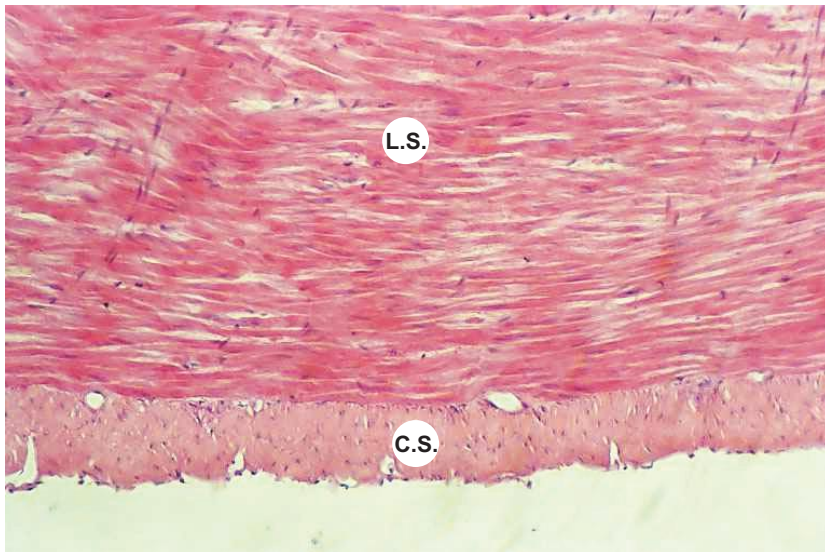
**Plate 8:1c C.S. of skeletal muscle.**

The general architecture of a muscle can be well appreciated in a cross section.

Note the connective tissue framework of the muscle:

- *Epimysium*—the connective tissue sheath of the muscle (not included in the section).
- *Perimysium (Pm)*—the connective tissue covering of the fascicle.
- *Endomysium (Em)*—the loose connective tissue supporting the muscle fibres.
- The muscle fibres are grouped into numerous *fascicles* separated by perimysium (**Pm**) containing blood vessels (**Bv**).
- At magnification  $\times 200$ , the sarcoplasm of each muscle fibre exhibits granular appearance due to cross section of myofibrils.
- Note the *peripheral nuclei*.

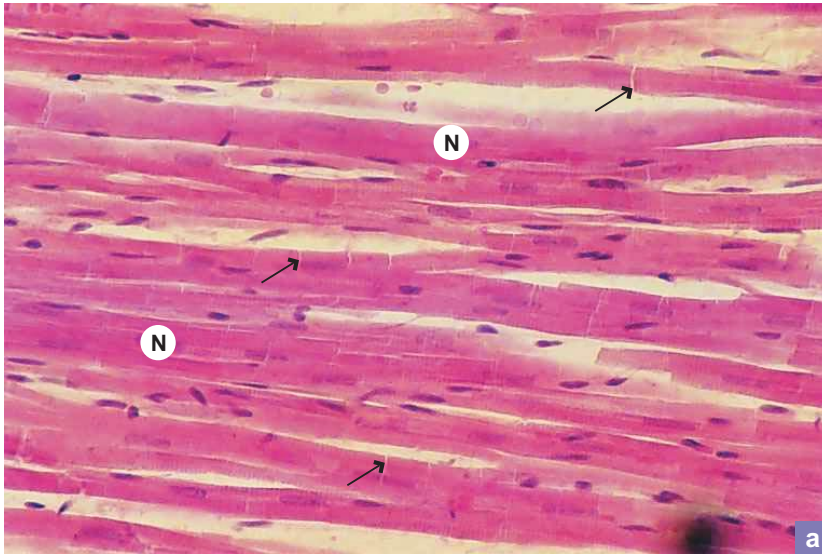
X100

**Plate 8:2 Smooth muscle (e.g. muscle coat of GIT).**

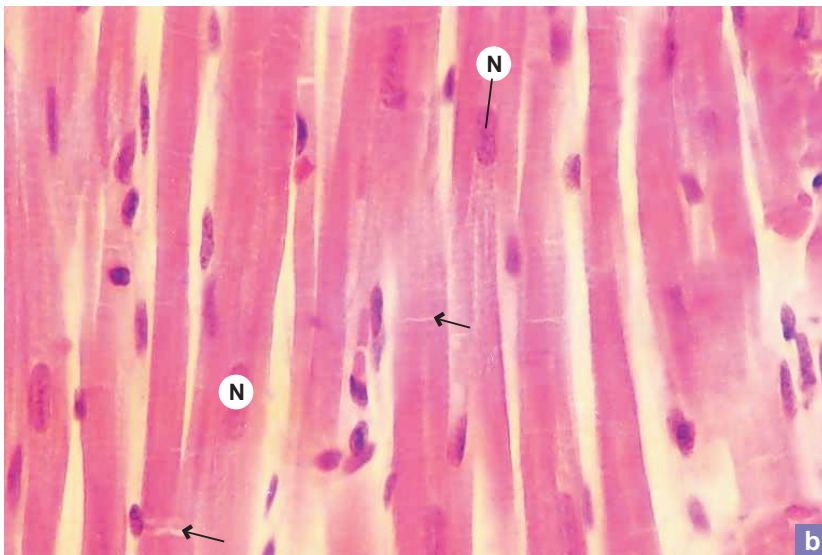
Examine a section of muscle coat of GIT or urinary bladder and note the following features:

- In longitudinal section (**LS**) the smooth muscle fibres are *spindle-shaped cells* with tapering ends.
- The nucleus is elongated and centrally placed.
- *No striations* are found.
- In cross section (**CS**) the spindle-shaped cells are cut at different places along the length resulting in various shapes and sizes of the cells. The nucleus will be seen in those cells which are cut through the centre. Others will not show nuclei.

X100



X200



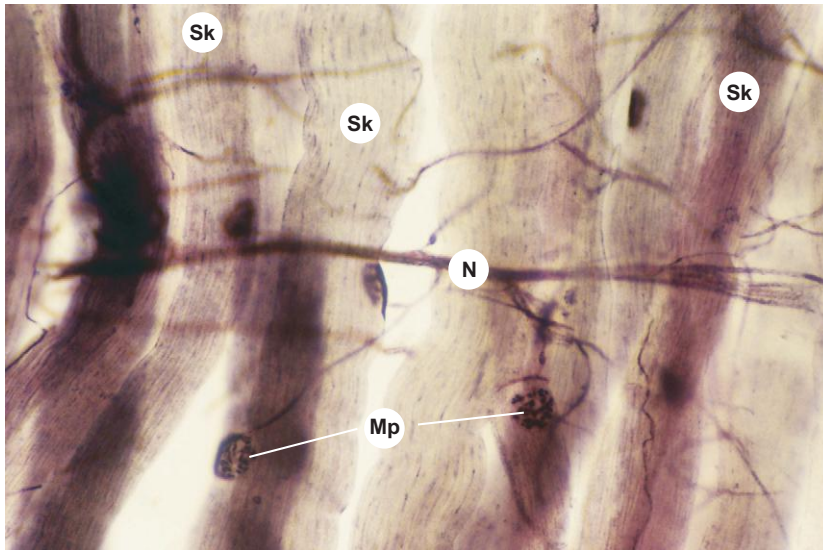
**Plate 8:3** L.S. of cardiac muscle.  
**a and b**

Appreciate the following features in a longitudinally sectioned cardiac muscle:

- *Branching* pattern of the cardiac muscle fibres.
- *Cross striations* are less prominent than in skeletal muscle.
- Presence of *intercalated discs* (**arrow**; junction between muscle fibres at their ends).
- *One (rarely two) oval nucleus (N)* central in position in each fibre.

## DEMONSTRATION OF SPECIAL SLIDES

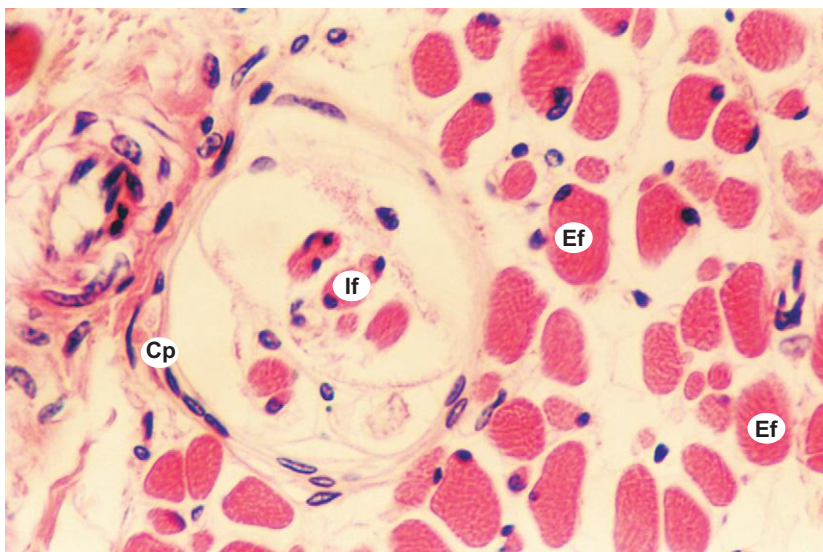
X100



## Plate 8:4 Motor end-plate.

- Motor end-plate can be demonstrated in teased skeletal muscle fibres stained specially with silver/gold impregnation techniques.
- Look for darkly stained string-like structures. They are *motor nerves* (N) and their terminal axons.
- Follow these axons; they will be endings on individual *skeletal muscle fibres* (Sk) at specialised junctions called *motor end-plates* (Mp) which resemble a flower spray (clusters of small bulbous swellings).

X400



## Plate 8:5 Muscle spindle.

- Muscle spindles can be easily demonstrated in a cross section of skeletal muscle at high magnification.
- Look for smaller diameter *intrafusal fibres* (If) enclosed in *connective tissue capsule* (Cp) among the larger diameter *extrafusal muscle fibres* (Ef; ordinary skeletal muscle fibres).
- The two types of intrafusal fibres, namely, nuclear bag fibres and nuclear chain fibres can be identified in a longitudinally sectioned skeletal muscle.

## Purkinje Fibres of Myocardium (Photograph not Available)

Look for these modified cardiac muscle fibres in the subendocardial tissue.

- They are larger than cardiac muscle fibres.
- Contain pale cytoplasm—a clear zone around the nucleus.
- Contain few myofibrils distributed at the periphery.
- Are rich in glycogen.

# 9

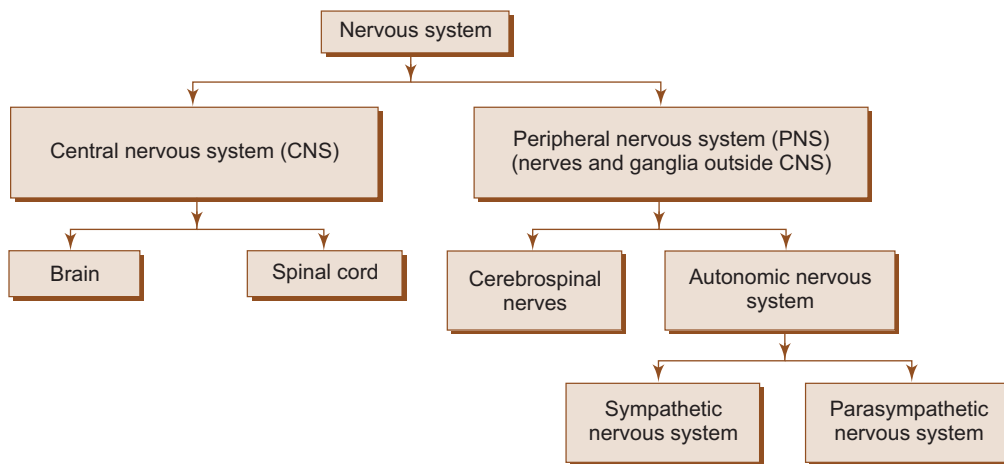
# NERVOUS TISSUE

## INTRODUCTION

The nervous tissue is composed of interconnecting network of specialised cells called *neurons* (nerve cells) supported by *neuroglial cells*. There are about 10 million neurons in human beings. The function of neurons is to receive stimuli and conduct them to a central site, the central nervous system (CNS), where they are analysed and integrated to produce a desired response in the effector organs.

## ANATOMICAL CLASSIFICATION OF NERVOUS SYSTEM

Nervous system can be classified into two categories, central nervous system and peripheral nervous system (Flowchart 9.1).

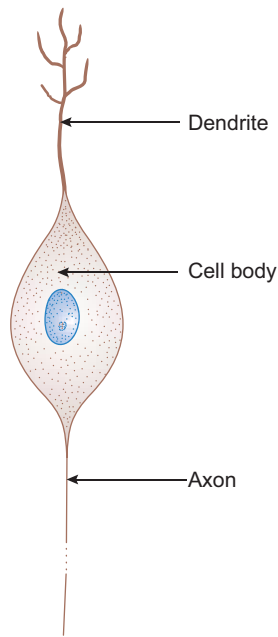


**Flowchart 9.1** Classification of nervous system.

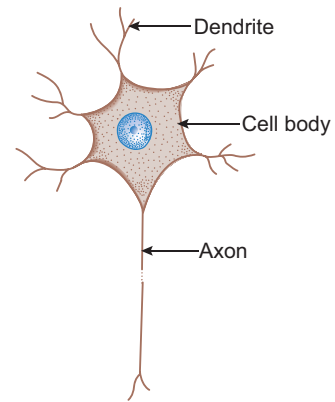
## CLASSIFICATION OF NEURONS

### A. Morphological (based on the number of processes)

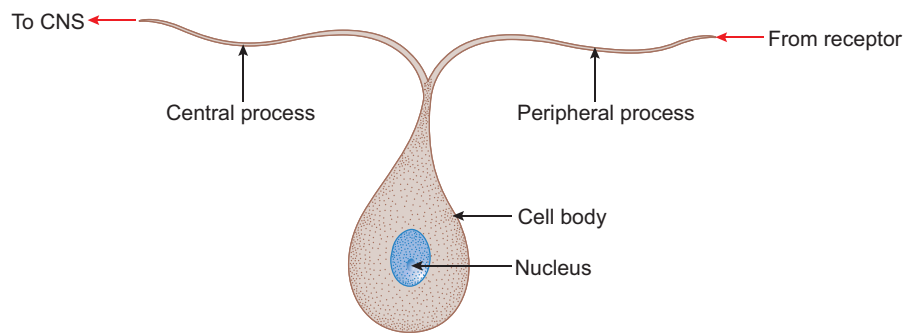
1. *Unipolar neuron*—has a single process (rare), e.g. *mesencephalic nucleus of V cranial nerve*.
2. *Bipolar neuron*—has two processes (an axon and a dendrite; Fig. 9.1), e.g. *spiral ganglion*, bipolar cells in *retina*, etc.
3. *Multipolar neuron*—has many processes (an axon and many dendrites; Fig. 9.2), e.g. *autonomic ganglia motor neurons*, etc.
4. *Pseudo-unipolar neuron*—has a single process that divides into an axon (central process) and a dendrite (peripheral process; Fig. 9.3), e.g. *cranial and spinal ganglia (sensory neurons)*.



**Fig. 9.1** Bipolar neuron.



**Fig. 9.2** Multipolar neuron.



**Fig. 9.3** Pseudo-unipolar neuron.

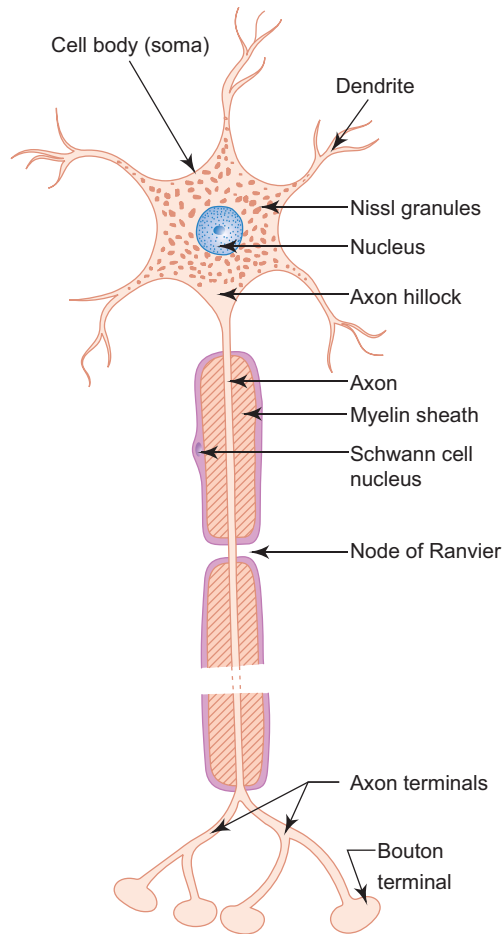
#### B. Functional (based on the function performed)

1. *Sensory neuron*—receives stimuli from receptors and conducts impulses to CNS, e.g. *sensory ganglia*.
2. *Motor neuron*—conducts impulses from CNS to effector organs (muscles), e.g. *ventral horn cells*.
3. *Interneuron*—connects sensory and motor neurons and completes the functional circuit.

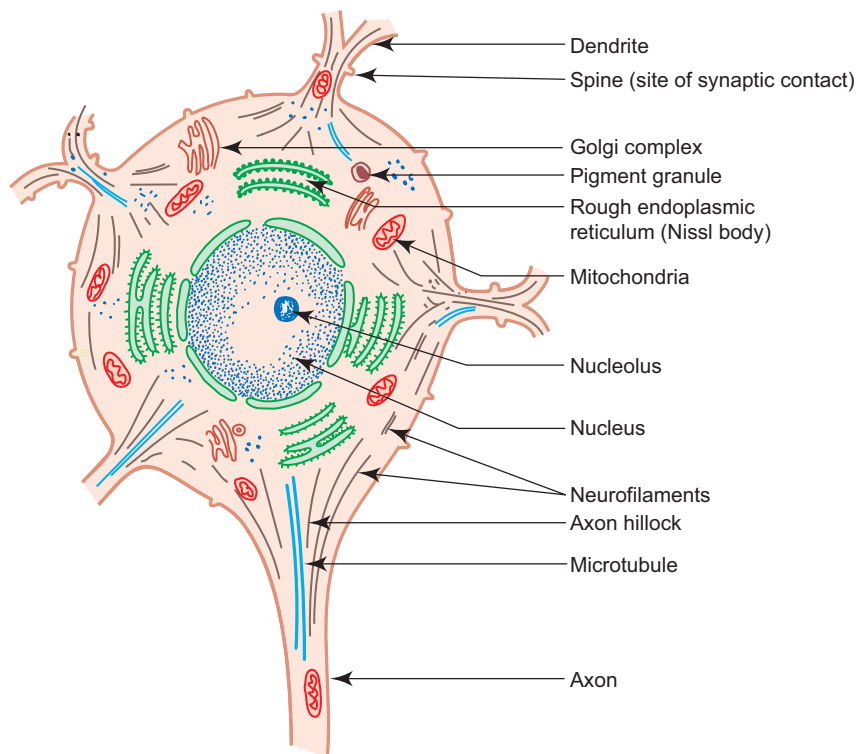
### STRUCTURE OF A NEURON (MULTIPOLAR)

#### Cell body/Soma/Perikaryon (5–150 $\mu\text{m}$ ):

- The cell bodies of all neurons are situated in the grey matter of the CNS and in the ganglia of PNS.
- The cell body of a neuron contains the nucleus and the following cytoplasmic organelles and inclusions (Figs 9.4 and 9.5):
  1. *Nucleus*—is large, euchromatic, spherical and centrally located.
  2. *Nissl bodies* or *Nissl substance*—are composed of large aggregations of rough endoplasmic reticulum
    - are observed as basophilic clumps by light microscopy
    - extend into dendrites but not into axon and axon hillock
    - disintegrate as a result of injury to axon (chromatolysis).
  3. *Golgi complex*—are found near the nucleus.



**Fig. 9.4** Structure of a multipolar neuron.



**Fig. 9.5** Ultrastructure of a neuron.



4. *Mitochondria*—are numerous and rod shaped.
5. *Neurofilaments* (10 nm dia) and microtubules (25 nm dia)—form neuronal cytoskeleton providing structural support and intracellular transport.
6. *Melanin pigments*—dark brown granules.
7. *Lipofuscin pigments*—residual bodies not digested by lysosomes (increase with age).

## Dendrites

- Are highly branched, tapering processes of a neuron. So their diameter is not uniform.
- Are covered by thorny spines (gemmules) which are sites of synaptic contact.
- Receive stimuli from sensory cells and other neurons and transmit them towards the soma. So they can be regarded as major sites of information input into neuron.

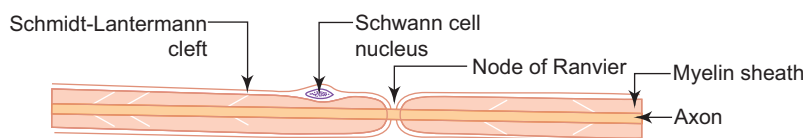
## Axon

- Single, long, cylindrical process of a neuron. So its diameter is uniform.
- Does not branch profusely; but may give rise to collaterals.
- Arises from a cone-shaped portion of the cell body called *axon hillock*, which is devoid of Nissl bodies, but contains bundles of microtubules.
- The cytoplasm of the axon is called *axoplasm* and the plasma membrane is called *axolemma*.
- Terminates by dividing into many small branches, *axon terminals*, ending in small swellings—*terminal boutons*.
- Conducts impulses away from the cell body to the axon terminals from which impulses are transmitted to another neuron or another target cell.
- Axons are commonly referred to as *nerve fibres*.
- Are often surrounded by *myelin sheath*, which is derived either from Schwann cells (PNS) or oligodendrocytes (CNS).
- When an axon is cut, peripheral part degenerates.
- Regeneration of the axon is possible only when the cell body of the neuron is intact.

*Neurons do not regenerate in the event of cell body death, i.e. they do not multiply.*

## Myelinated and Unmyelinated Axons

- In the PNS, all axons are enveloped by Schwann cells which provide both structural and metabolic support.
- Many axons with small diameter invaginate into one Schwann cell longitudinally and are simply surrounded by the cytoplasm of Schwann cells. They are called *unmyelinated* nerve fibres.
- Other axons, especially the ones with larger diameter, invaginate into the Schwann cell and are wrapped by concentric layers of the Schwann cell plasma membrane forming myelin sheath. These axons are called *myelinated* nerve fibres (Fig. 9.6).
- There are gaps (areas of axon not covered by myelin) along the length of myelin sheath at regular intervals called *nodes of Ranvier*.
- In large myelinated axons, the nerve impulse jumps from node to node resulting in faster conduction (saltatory conduction).
- The segment of myelin between two nodes of Ranvier is called *internode*.
- The myelin of one internode is formed by a single Schwann cell.



**Fig. 9.6** A myelinated peripheral nerve fibre.

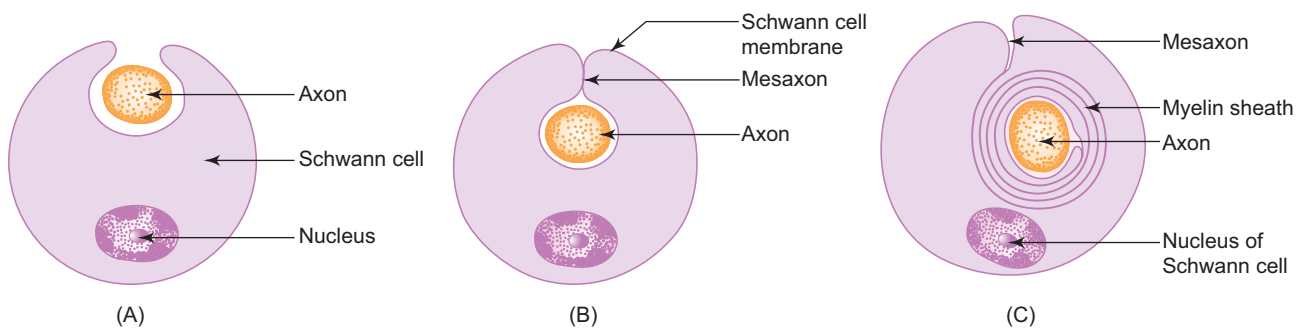
- The myelin sheath shows cone-shaped clefts called *Schmidt-Lantermann clefts*. They are areas of remnants of cytoplasm of Schwann cells present within the myelin sheath.

### Myelination

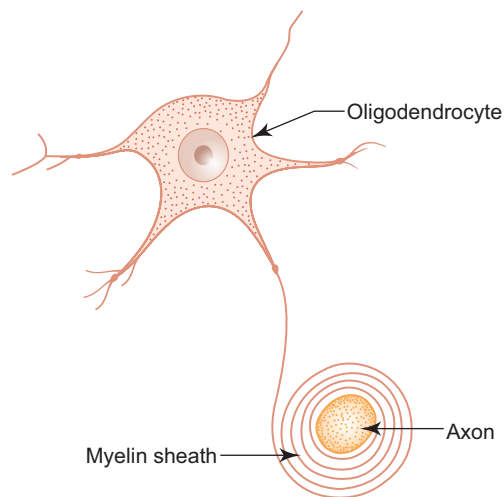
- In the PNS, the myelin sheath of an individual axon is provided by many *Schwann cells* lying along the length of the axon (Fig. 9.7A).
- Myelination begins with the invagination of the axon into the Schwann cell. The invaginated axon is suspended from the periphery of the cell by a fold of fused plasma membrane called *mesaxon* (Fig. 9.7B).
- As myelination proceeds the Schwann cell and mesaxon rotates itself around the axon several times resulting in enveloping the axon in concentric layers of Schwann cell cytoplasm and plasma membrane alternately (Fig. 9.7C).
- With further rotation cytoplasm between the concentric layers of plasma membrane is squeezed out and the opposing inner surfaces of the plasma membrane fuse with each other forming myelin sheath. Thus myelin sheath is actually composed of many layers of modified cell membrane of Schwann cell.
- In the CNS, the myelin sheath is formed by processes of oligodendrocytes (Fig. 9.8).

### Peripheral Nerve

- Each peripheral nerve (spinal or cranial) is made of bundles (fascicles) of nerve fibres (axons) which may be myelinated and/or unmyelinated.
- The bundles are held together by connective tissue which provides structural support as well as nutritional support by carrying blood vessels to nerve fibres.



**Fig. 9.7** Stages of myelin formation in PNS.



**Fig. 9.8** Myelin formation in CNS.

- The connective tissue framework is well appreciated in cross section of a nerve (Fig. 9.9; Box 9.1), where following structures can be observed:
  - *Epineurium*: Dense connective tissue sheath surrounding the entire nerve.
  - *Perineurium*: A sleeve of flattened specialised epithelial cells surrounding the bundles of nerve fibres.
  - *Endoneurium*: Loose connective tissue composed of reticular fibres supporting individual nerve fibres.
- In the case of optic nerve, it is surrounded by meninges of brain (Box 9.2).

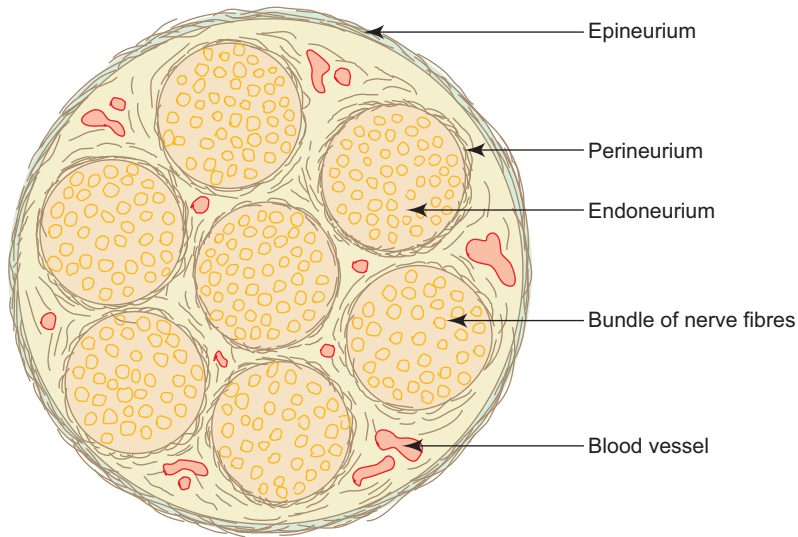
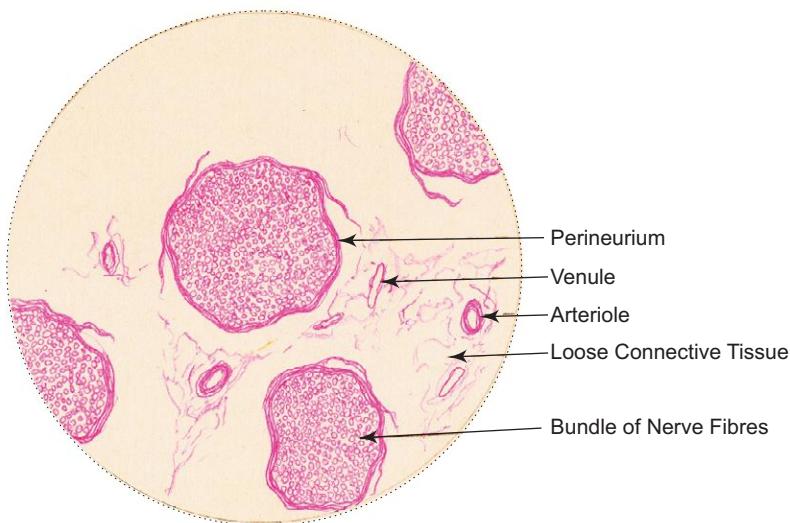


Fig. 9.9 Peripheral nerve (C.S.).

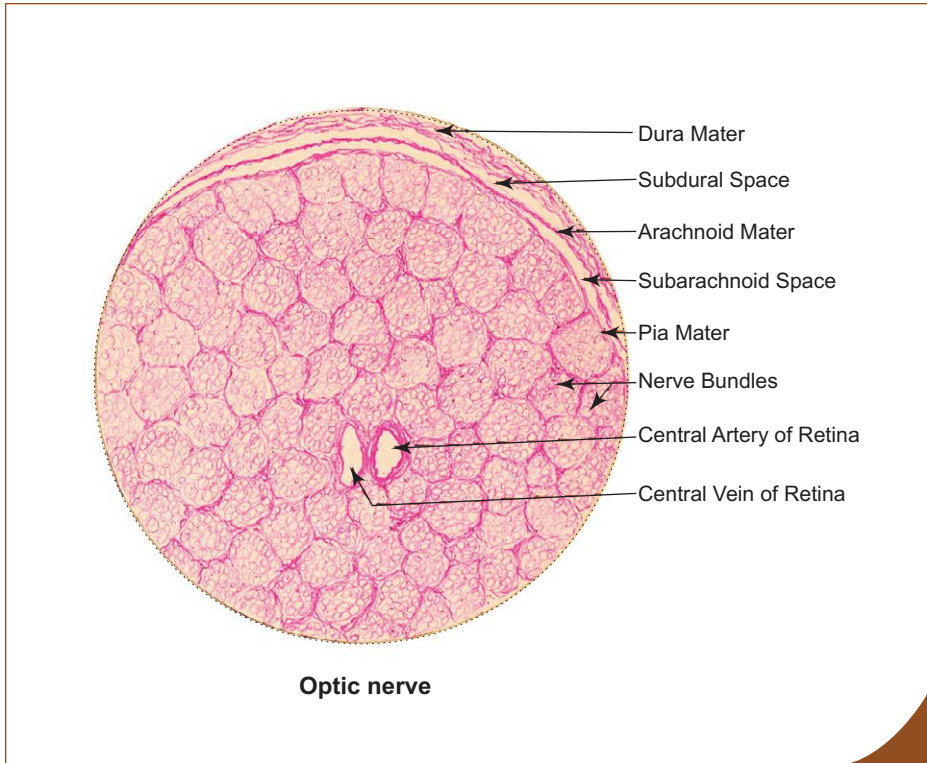
**Box 9.1** Peripheral nerve (C.S.).

Presence of

- (i) bundles of **nerve fibres**;
- (ii) **perineurium** around each bundle;
- (iii) darkly stained axon and lightly stained myelin.



Peripheral nerve (C.S.)



**Box 9.2** Optic Nerve.

Presence of

- (i) **central vessels** of retina;
- (ii) bundles of myelinated **nerve fibres**;
- (iii) **dura, arachnoid** and **pia maters** surrounding the nerve.

**GANGLIA**

Ganglia are oval bodies made of aggregation of cell bodies of neurons outside the CNS. They serve as relay centres in the neuronal pathway. They are usually covered by a dense connective tissue capsule known as epineurium. The cell bodies of the neurons are enveloped by a layer of cuboidal cells called satellite cells. Two types of ganglia can be distinguished on the basis of morphology and function; sensory and motor ganglia (Boxes 9.3 and 9.4). Their distinguishing features are enumerated in Table 9.1.

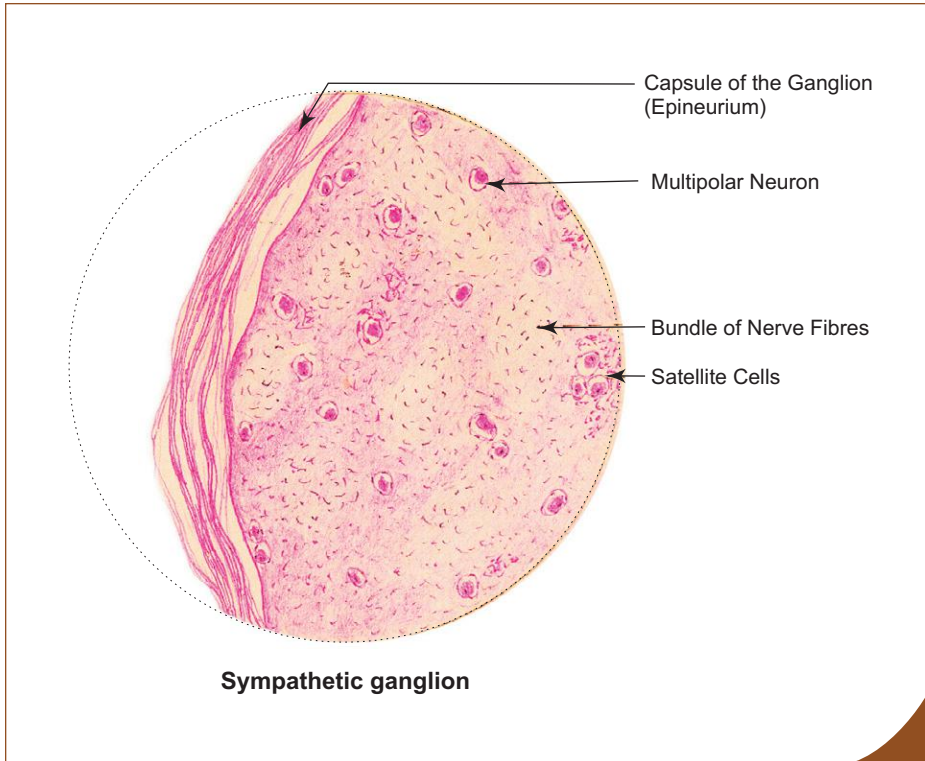
**Table 9.1** Differences between sensory and motor ganglia

Sensory ganglion (somatic), e.g. spinal ganglion	Motor ganglion (autonomic), e.g. sympathetic ganglion
<ol style="list-style-type: none"> <li>1. Pseudo-unipolar neurons                             <ul style="list-style-type: none"> <li>● Large, rounded and of varying size (in section)</li> <li>● Nucleus centrally placed</li> <li>● Found in groups</li> </ul> </li> <li>2. Well-defined satellite cells</li> </ol>	<ol style="list-style-type: none"> <li>1. Multipolar neurons                             <ul style="list-style-type: none"> <li>● Small, angular and of uniform size (in section)</li> <li>● Nucleus eccentrically placed</li> <li>● Found scattered</li> </ul> </li> <li>2. Poorly defined satellite cells</li> </ol>

**Box 9.3 Sympathetic Ganglion.**

*Presence of*

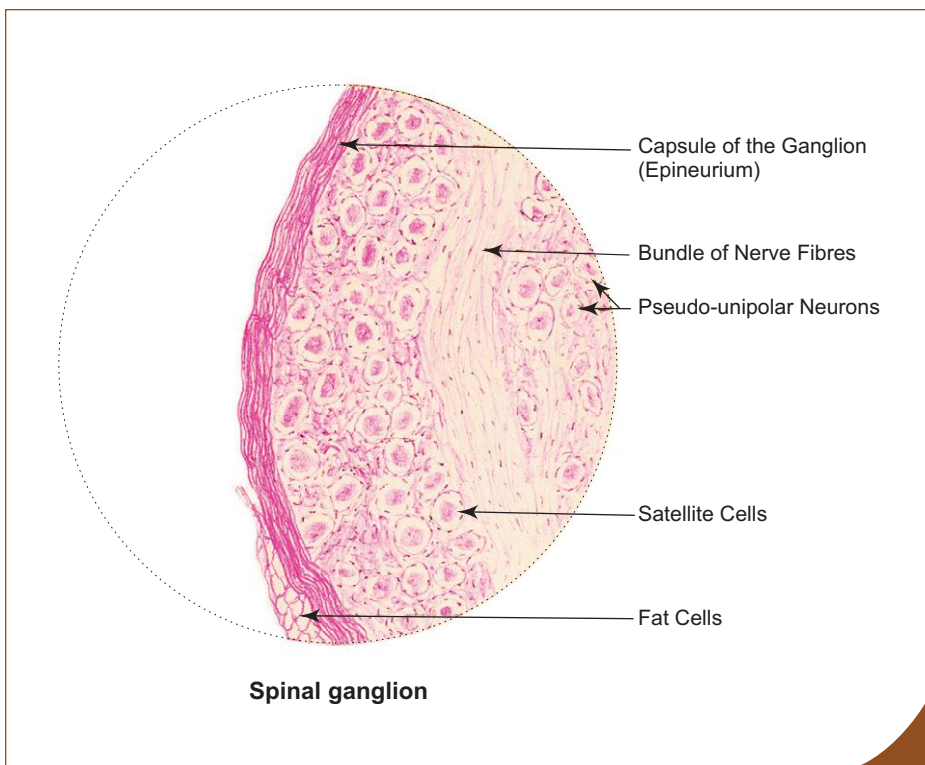
- (i) small **scattered, angular multipolar neurons** of uniform size;
- (ii) **poorly defined satellite cells;**
- (iii) **eccentrically placed nuclei** in the perikaryon.



**Box 9.4 Spinal Ganglion**

*Presence of*

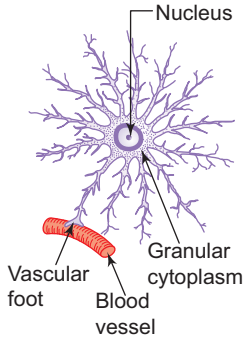
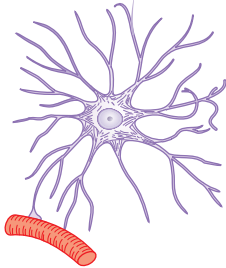
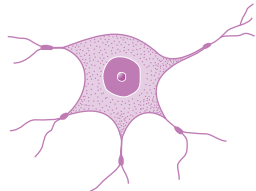
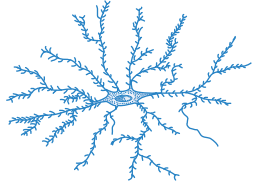
- (i) **groups of rounded pseudo-unipolar neurons** of varying size;
- (ii) **well defined satellite cells;**
- (iii) **centrally placed nuclei** in the perikaryon.



## NEUROGLIA (IN CNS)

Neuroglia are highly branched cells that support the neurons by occupying the spaces between them, providing both structural and metabolic support. There are four principal types of neuroglia in the CNS; namely astrocytes, oligodendrocytes, microglia and ependymal cells. Of the four types, ependymal cells form a specialised simple low columnar epithelium which lines the ventricles of brain and central canal of spinal cord. The epithelium lacks a basement membrane. The characteristic features and functions of the other three neuroglial cells are presented in Table 9.2.

**Table 9.2** Distinguishing features of astrocytes, oligodendrocytes and microglia

	Astrocytes		Oligodendrocytes	Microglia
	Protoplasmic	Fibrous		
Diagram				
Cell size	Large	Large	Medium	Small elongated
Shape of nucleus	Oval (lightly stained)	Oval (lightly stained)	Small spherical (darkly stained)	Small elongated (darkest)
Cytoplasmic processes	Many short thick processes	Many long slender processes	Few short beaded processes	Short thin processes with spines
Cytoplasm	Granular (organelles free)	Fibrillar (organelles free)	Organelles present	Organelles present
Occurrence (Predominant in)	Grey matter	White matter	White matter	Grey and white matters
Function	Supporting and nutritive, repair, barrier to diffusion of toxic substance		Myelination	Phagocytosis
Embryological origin	Neural ectoderm		Neural ectoderm	Mesoderm

## CEREBRAL CORTEX

### GENERAL FEATURES

- Cerebral cortex consists of grey matter that covers the cerebral hemisphere.
- The surface area of the cortex is increased due to the presence of many convolutions or gyri separated by sulci.
- The cortex is made of a mixture of nerve cells, fibres, neuroglia and blood vessels.

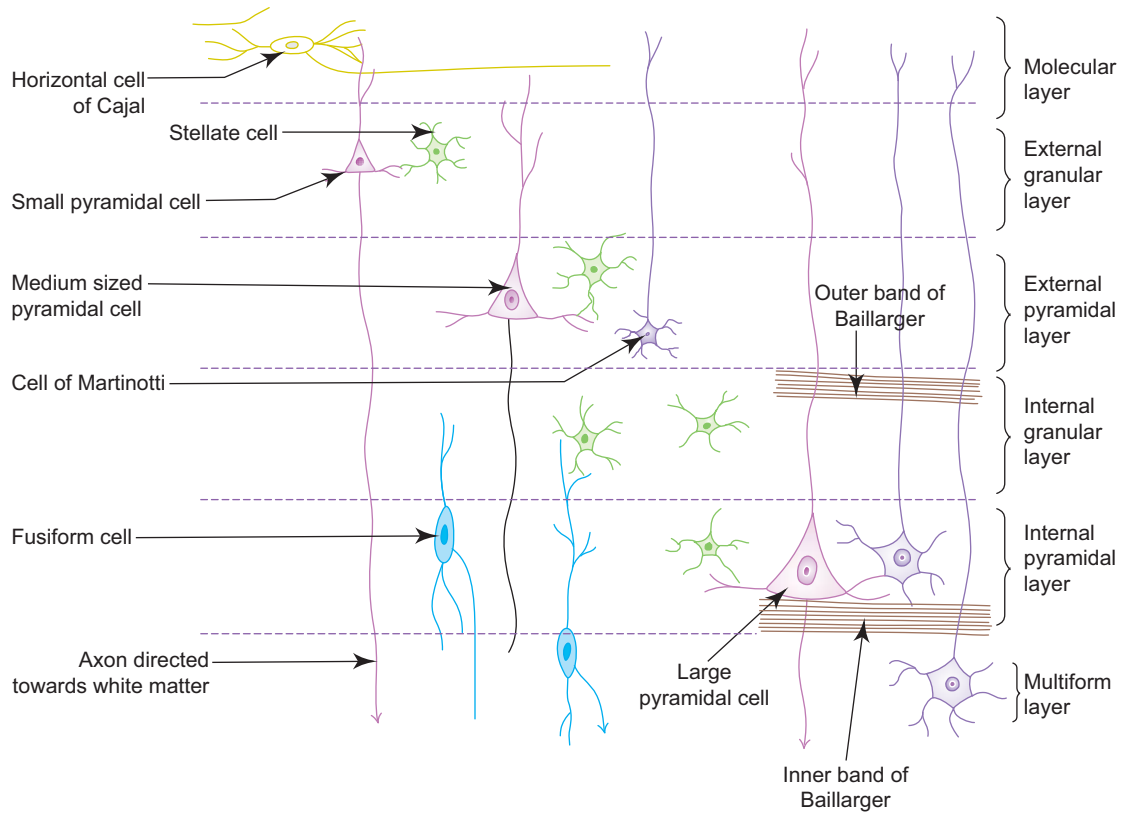
## Types of Nerve Cells

- The nerve cells in cerebral cortex are of five types (Fig. 9.10; Box 9.5). They are:
  1. **Pyramidal cells**
    - Are the most common type of neurons found in the cerebral cortex.
    - Are pyramidal in shape.
    - Their size ranges from 10  $\mu\text{m}$  to 120  $\mu\text{m}$ .
    - Giant pyramidal cells (120  $\mu\text{m}$ ) in the motor cortex are called *Betz cells*.
    - The apices of the neurons give rise to dendritic processes which are directed towards the surface of the cortex, whereas the bases give origin to axons which forms projection fibres of the white matter.
    - They are distributed in layers, 2–5, and progressively increase in size.
  2. **Stellate/Granule cells**
    - Small, star-shaped neurons of uniform diameter (8  $\mu\text{m}$ ).
    - Have short axons terminating in nearby neurons.
  3. **Fusiform cells**
    - Spindle-shaped cells placed at right angles to the surface in the deep layer.
    - Dendrites arise from each pole of the cell body and axon arises from the cell body just above the lower pole and enters the white matter.
  4. **Horizontal cells of Cajal**
    - They are also spindle-shaped cells but oriented horizontally, parallel to the surface in the superficial layer (molecular).
    - Dendrites arise from each pole and axon arises from the cell body and runs horizontally, parallel to the surface making contact with dendrites of pyramidal cells.
  5. **Cells of Martinotti**
    - Small multipolar cells found in layers 3–6.
    - The axons are directed towards the surface of the cortex and generally end in the molecular layer.

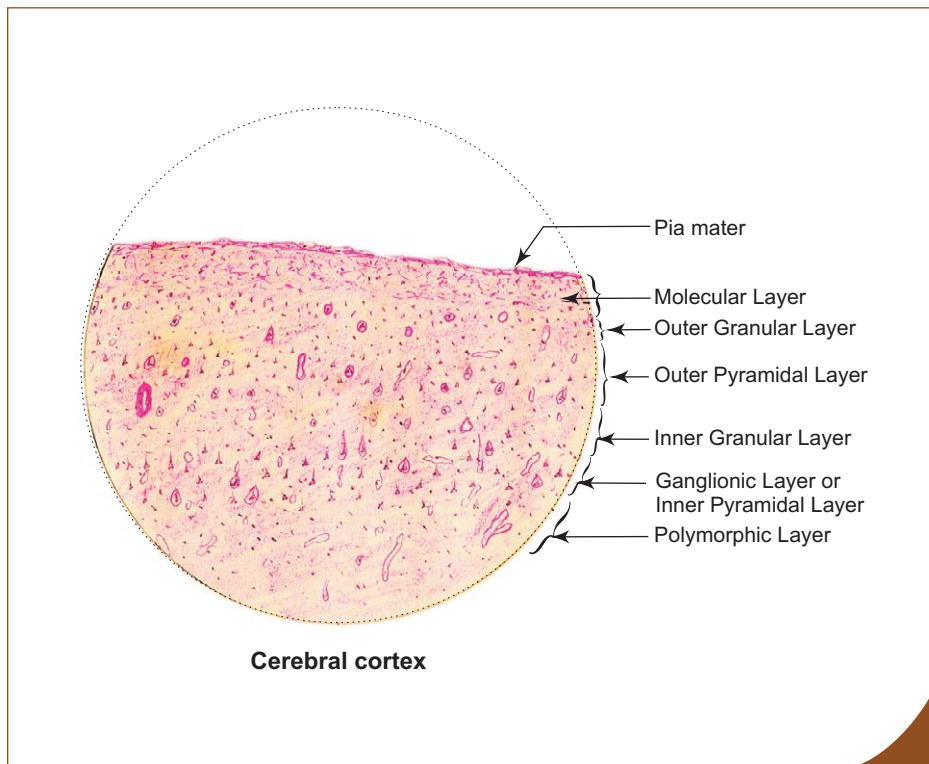
## STRUCTURE

- The nerve cells and associated fibres of cerebral cortex are so arranged as to form six layers, which are poorly distinguished. The layers are named according to the type and density of the cells:
  1. *Molecular layer* (plexiform layer)—is the most superficial, well defined layer. It consists mainly of nerve fibres and occasional *horizontal cells* of Cajal.
  2. *External granular layer*—contains large number of *stellate cells* and *small pyramidal cells*.
  3. *External pyramidal layer*—is mainly made of medium sized *pyramidal cells* and also contains few *stellate cells* and *cells of Martinotti*.
  4. *Internal granular layer*—is composed of closely packed *stellate cells* and horizontally oriented white fibre band called *outer band of Baillarger*.
  5. *Internal pyramidal layer* (ganglionic layer)—consists mainly of *large pyramidal cells* and few *stellate cells* and *cells of Martinotti*. This layer also contains horizontally arranged fibres that form the *inner band of Baillarger*.
  6. *Multiform layer* (layer of polymorphic cells)—is the deepest layer. It contains predominantly *fusiform cell* and also few *stellate cells* and *cells of Martinotti* intermixed with many nerve fibres entering or leaving the underlying white matter.

The structure of cerebral cortex shows considerable variation from region to region. In sensory areas the granular layers are well developed whereas the pyramidal layers are poorly developed and is termed as *granular cortex*. In motor areas it is the other way round, i.e. the pyramidal layers are well developed and the granular layers are poorly developed and is known as *agranular cortex*.



**Fig. 9.10** Distribution of cell types in layers of cerebral cortex.



**Box 9.5 Cerebral Cortex.**

*Presence of*

- (i) lightly stained superficial **molecular layer**;
- (ii) **pyramidal cells** and **granule cells** in deep layers.



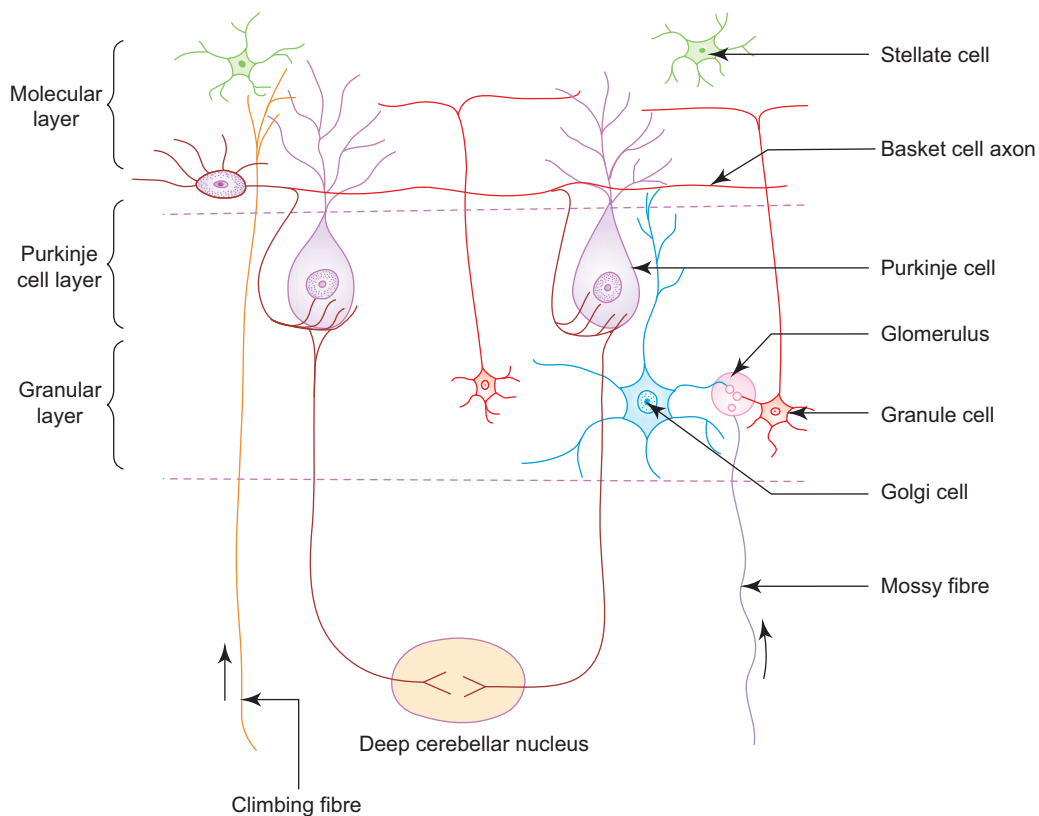
## CEREBELLAR CORTEX

### GENERAL FEATURES

- The cortex of cerebellum is highly folded. The folds or *folia* are separated by closely set parallel transverse fissures.
- Each folium contains a core of white matter covered superficially by grey matter or cortex.

### STRUCTURE

- The cerebellar cortex consists of three layers; an external molecular layer, a middle Purkinje cell layer and an internal granular layer (Fig. 9.11; Box 9.6):
  1. **Molecular layer**
    - Is the superficial thick layer and is usually lightly stained with eosin.
    - Mainly made of nerve fibres and few cells, namely, *stellate cells* in the superficial part and *basket cells* in the deeper part.
    - The axons of these cells run parallel to the long axis of the folia. The axons of basket cells form collaterals which arborize around the Purkinje cells in a 'basket-like' manner.
  2. **Purkinje cell layer**
    - *Purkinje cells* are large flask-shaped neurons (Golgi type I) and are arranged in a single row between molecular and granular layers.

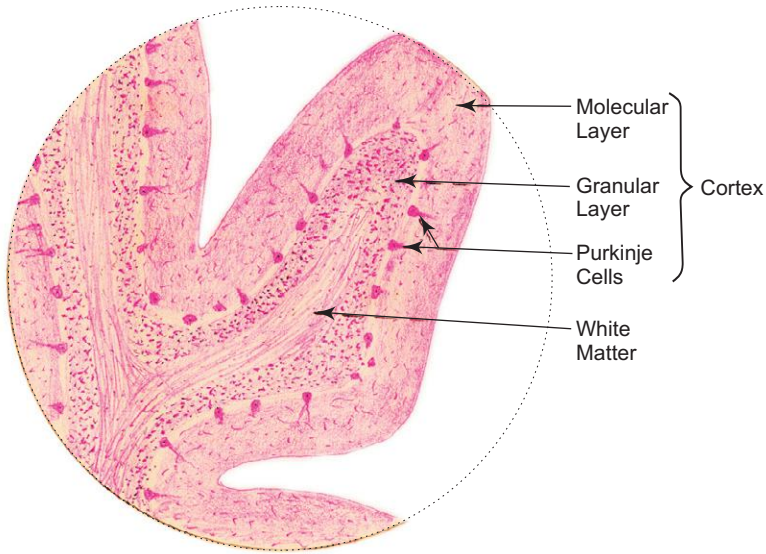


**Fig. 9.11** Distribution of cell types in layers of cerebellar cortex.

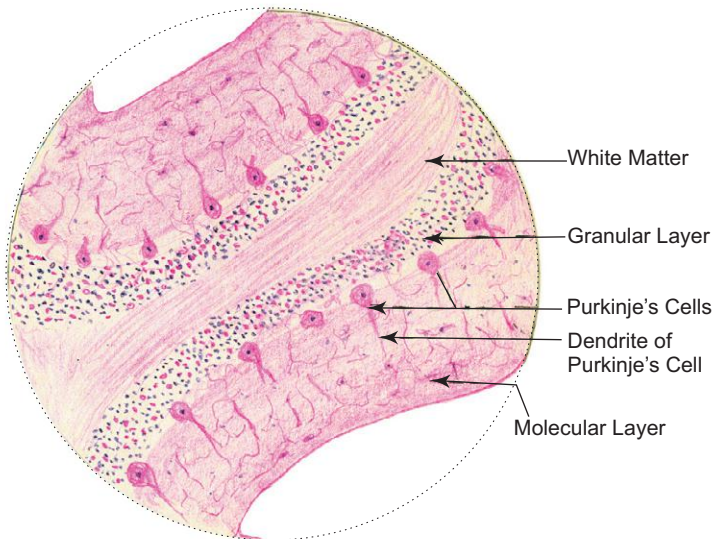
**Box 9.6 Cerebellum.**

*Presence of*

- (i) lightly stained superficial **molecular layer**;
- (ii) flask-shaped **Purkinje cells**;
- (iii) well defined **granular layer**.



**L/P**  
**Cerebellum**



**H/P**  
**Cerebellum**

- The dendrites of these cells pass into molecular layer and arborize profusely in a plane transverse to the folium. These dendrites synapse with axons of granular cells and *climbing fibres* that ascend to the molecular layer. (Climbing fibres are derived from olivary nuclei.)
- The axons of Purkinje cells pass through the granular layer to end in deeper nuclei of cerebellum, exerting an inhibitory influence on them.

### 3. Granular layer

- Is stained deeply with hematoxylin because it is densely packed with very *small granule neurons* (the smallest cell in the body). The axons of these granule cells pass into the molecular layer where they bifurcate in a T-shaped manner and run at right angles to the plane of dendritic processes of the Purkinje cells and synapse with them.
- Apart from granule cells, few *Golgi cells* (type II) are also present in the granular layer. They have vesicular nuclei, more cytoplasm and short neuronal processes.
- The granule cells receive impulses from afferent *Mossy fibres* which end as dilated terminals in the granular layer.
- The dendrites of granule cells and axons of Golgi cells synapse with terminals of Mossy fibres to form lightly stained areas called *glomeruli*.
- Mossy fibres synapse indirectly with thousands of Purkinje cells through granule cells causing a diffuse excitatory influence on many Purkinje cells, whereas the climbing fibres exert specific influence on only one Purkinje cell.

# Self-assessment Exercise

## I. Write short notes on:

- (a) Neuroglia
- (b) Types of neurons with examples
- (c) Structure of a multipolar neuron
- (d) Myelination
- (e) Differences between sensory and motor ganglia
- (f) Structure of cerebellar cortex
- (g) Structure of cerebral cortex

## II. Fill in the blanks:

1. Myelin sheath of the CNS is formed by \_\_\_\_\_
2. Myelin sheath of the PNS is formed by \_\_\_\_\_
3. The ventricle of brain and central canal of spinal cord are lined by \_\_\_\_\_
4. Axon arises from a cone-shaped portion of the cell body of the neuron called \_\_\_\_\_
5. The basophilic Nissl substance of a neuron is composed of \_\_\_\_\_

## III. Choose the best answer:

1. Pseudo-unipolar neurons are found in the following ganglion:
  - (a) Spinal
  - (b) Spiral
  - (c) Sympathetic
  - (d) Parasympathetic
2. The connective tissue sheath around a nerve is called
  - (a) endoneurium
  - (b) perineurium
  - (c) epineurium
  - (d) neurilemma
3. Section of sympathetic ganglion can be identified by the presence of
  - (a) large pseudo-unipolar neurons
  - (b) small multipolar neurons
  - (c) bipolar neurons
  - (d) well developed satellite cells
4. Betz cells are seen in
  - (a) cerebellar cortex
  - (b) cerebellar nuclei
  - (c) sensory cortex of cerebrum
  - (d) motor cortex of cerebrum

5. Climbing fibres of cerebellum are
- association fibres
  - axons of Purkinje cells
  - efferent fibres
  - afferent fibres

**IV. State whether the following statements are true (T) or false (F):**

- Neurons have mitotic potential ( )
- Degeneration of Nissl bodies is called chromatolysis ( )
- Interneurons connect sensory and motor neurons ( )
- Mossy fibres of cerebellum are involved in formation of glomeruli ( )
- Molecular layer of cerebellum is made of granule cells and Golgi cells ( )

**V. Match the items in Column 'A' with those of column 'B':**

A.	Column 'A'		Column 'B'
	<i>Neuroglia</i>		<i>Function</i>
1.	Ependyma	( )	(a) Myelination
2.	Astrocyte	( )	(b) Phagocytosis
3.	Oligodendrocyte	( )	(c) Secretion of cerebrospinal fluid
4.	Microglia	( )	(d) Support and nourishment
	<i>Neurons</i>		<i>Example</i>
1.	Bipolar	( )	(a) Mesencephalic nucleus of V cranial nerve
2.	Multipolar	( )	(b) Spiral ganglion
3.	Pseudo-unipolar	( )	(c) Sympathetic ganglion
4.	Unipolar	( )	(d) Dorsal root ganglion

**Answers**

- II.** 1. Oligodendrocytes    2. Schwann cells    3. Ependyma    4. Axon hillock  
5. Rough endoplasmic reticulum

- III.** 1. a    2. c    3. b    4. d    5. d

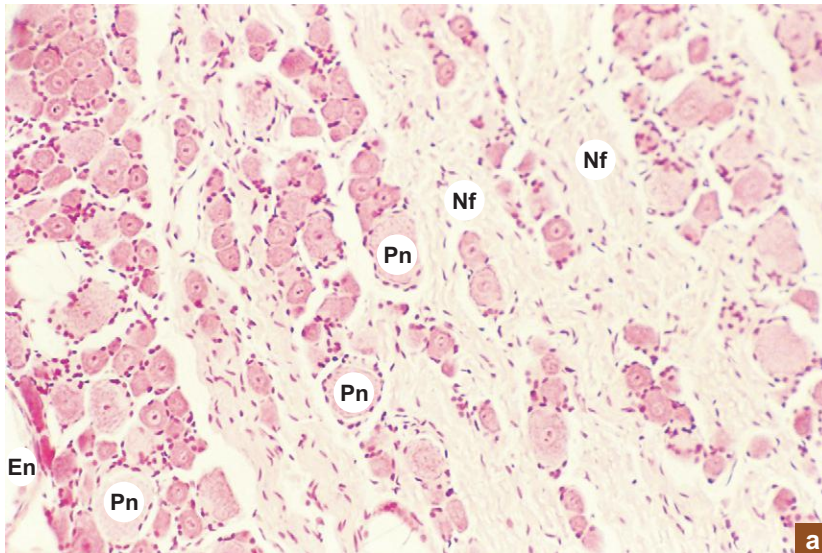
- IV.** 1. (F)    2. (T)    3. (T)    4. (T)    5. (F)

- V.** A. 1. c    2. d    3. a    4. b  
B. 1. b    2. c    3. d    4. a

# Practical No. 9

## Nervous Tissue

X100



**Plate 9:1**  
**a and b**      **Sensory ganglion (e.g. dorsal root ganglion).**

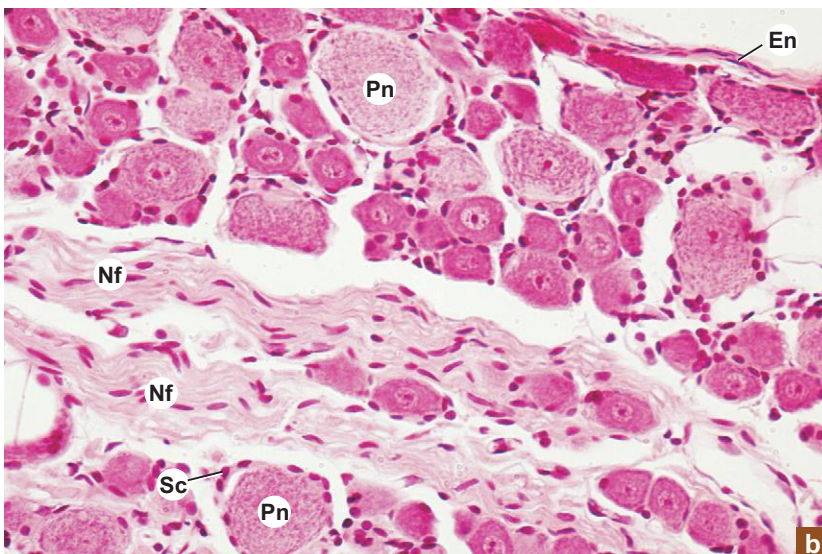
At low magnification (Plate 9:1a), identify the following structures in sensory ganglion:

- Epineurium (**En**) of dense connective tissue forming the capsule of the ganglion.
- Groups of round *pseudo-unipolar neurons* (**Pn**) of varying size found at the periphery separated by bundles of nerve fibres (**Nf**).

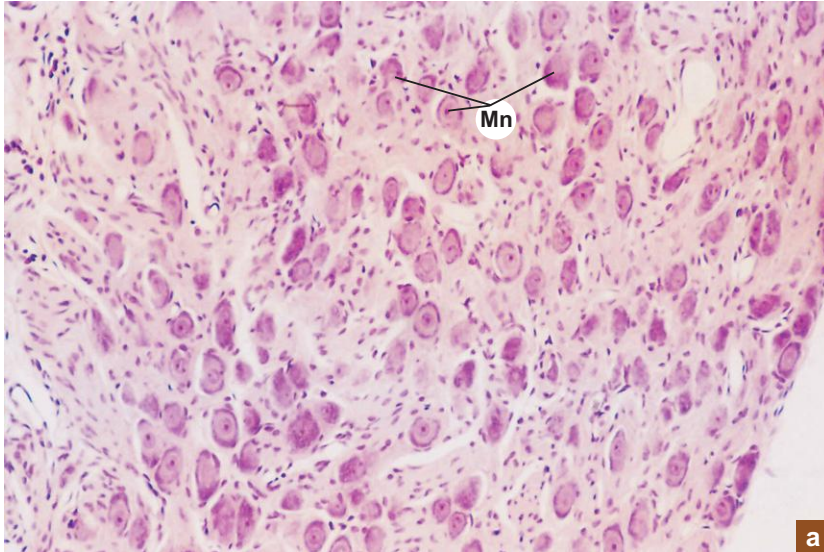
At high magnification (Plate 9:1b), identify the following structures:

- The large spherical centrally placed euchromatic (vesicular) nucleus with its prominent nucleolus can be identified in the neuronal cell body (**Pn**).
- Well defined cuboidal satellite cells (**Sc**) forming a cellular capsule around the cell body can also be identified. Their darkly stained round nuclei form a ring around the neurons. These cells play an important role in providing structural and metabolic support to the neurons.

X200



X100



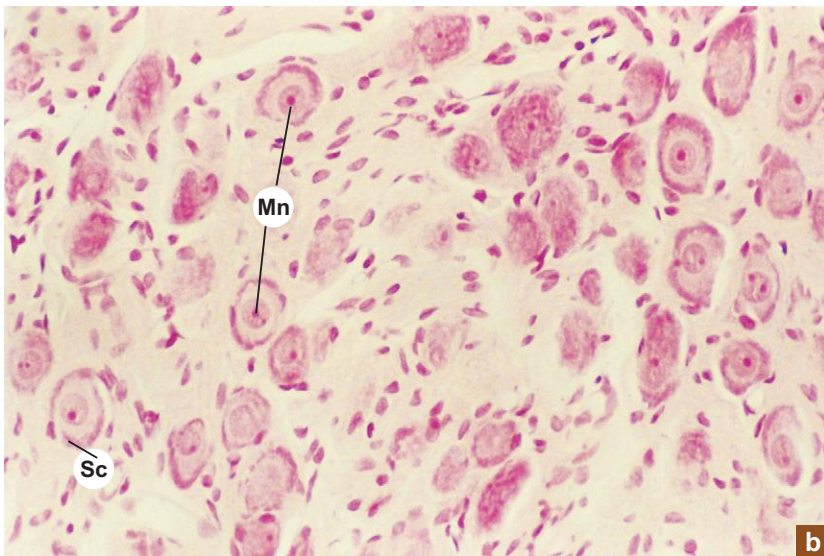
a

**Plate 9:2**    **Motor ganglion (e.g. sympathetic ganglion).**  
**a and b**

Examine the motor ganglion at low magnification (Plate 9:2a) and note the following features:

- The small, *angular, multipolar neurons (Mn)* of uniform size.
- Multipolar neurons are *scattered* among nerve fibres.

X200

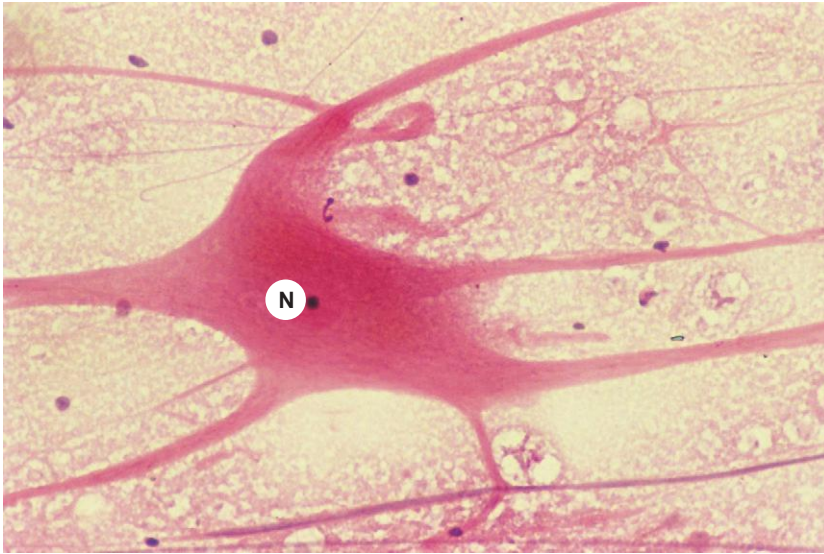

b

At high magnification (Plate 9:2b), note the following features:

- The eccentrically placed euchromatic nucleus with its prominent nucleolus.
- *Poorly defined satellite cells (Sc).*

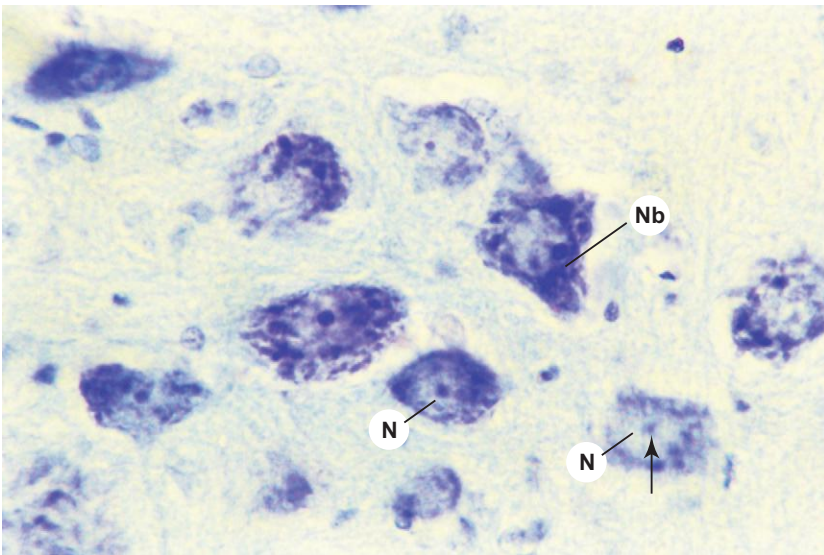
X200



**Plate 9:3** Multipolar neuron (teased).

Teased preparation of a multipolar neuron stained with H&E shows the neuronal processes radiating from the cell body. The cell body contains a nucleus (N) and a well developed nucleolus.

X200



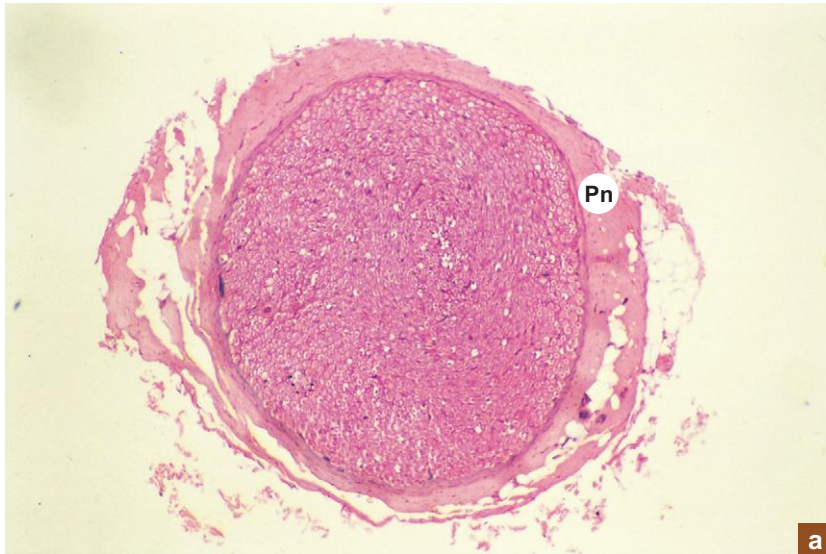
**Plate 9:4** Multipolar neuron (stained for Nissl substance; Toluidine blue).

Examine the ventral horn of the spinal cord or cranial nerve nuclei for large multipolar motor neurons. In these neurons, identify the following features:

- Lightly stained euchromatic nucleus (N) and darkly stained nucleolus (**arrow**).
- Nissl bodies in the cytoplasm.
- Dendritic processes (contain Nissl bodies; Nb).
- Axon hillock and axonal processes (devoid of Nissl bodies).

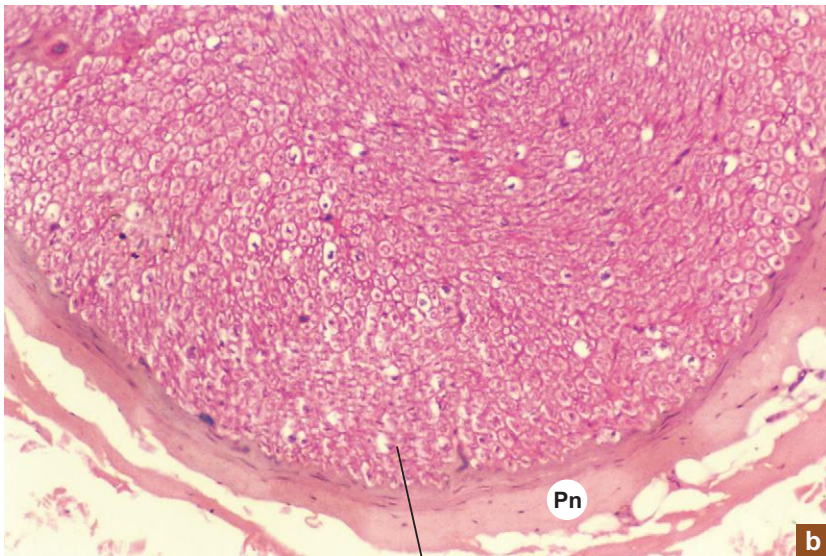


X40



a

X100



b

Ax

### Plate 9:5 C.S. of peripheral nerve. a and b

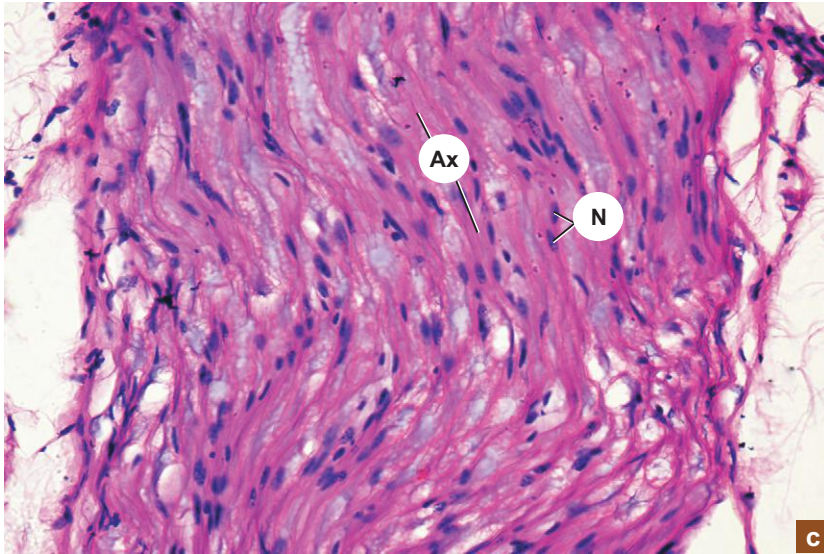
Examine the slide and observe the following features:

- The general architecture of a nerve can be well appreciated in cross section of a nerve at low magnification (Plate 9:5a).
- A nerve is made of many bundles of nerve fibres called *fascicles* supported by connective tissue.
- Note the organization of connective tissue components of a nerve.
- *Epineurium* (not seen) – connective tissue sheath around a nerve.
- *Perineurium* (Pn) – connective tissue sheath around a fascicle.
- *Endoneurium* – loose connective tissue supporting the nerve fibres.

At a still higher magnification (Plate 9:5b):

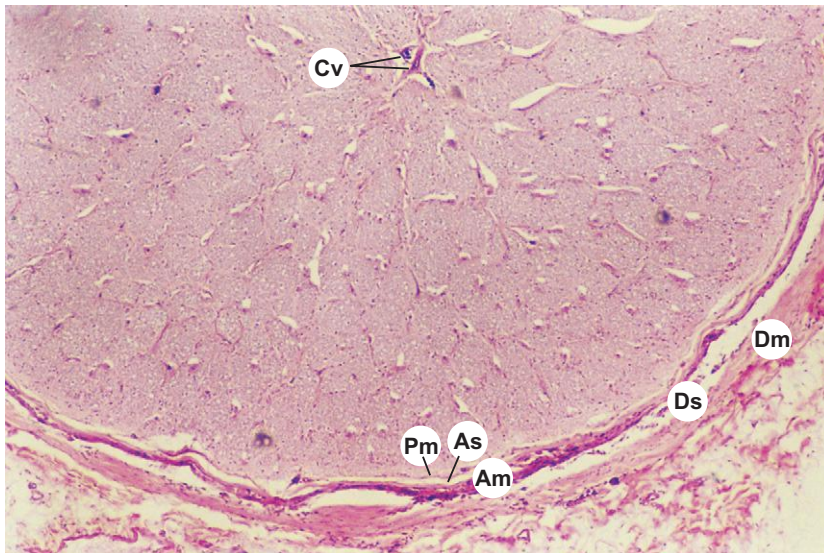
- each nerve fibre shows a darkly stained *axon* (Ax) surrounded by a lightly stained *myelin sheath* (the myelin sheath is paler due to the dissolution of lipid content during processing).

X400

**Plate 9:5c** L.S. of peripheral nerve.

- The characteristic feature of a peripheral nerve is the wavy course of its fibres which can be appreciated in a longitudinal section (Plate 9:5c). This zigzag course permits stretching of the nerve during movement.
- Note the thin lightly stained wavy strands of axons (Ax). They are surrounded by myelin sheath which appears foamy due to dissolution of lipid during preparation.
- Most of the nuclei (N) that are seen along the course of nerve fibres are the *Schwann cell* nuclei or fibroblast nuclei of the endoneurium.

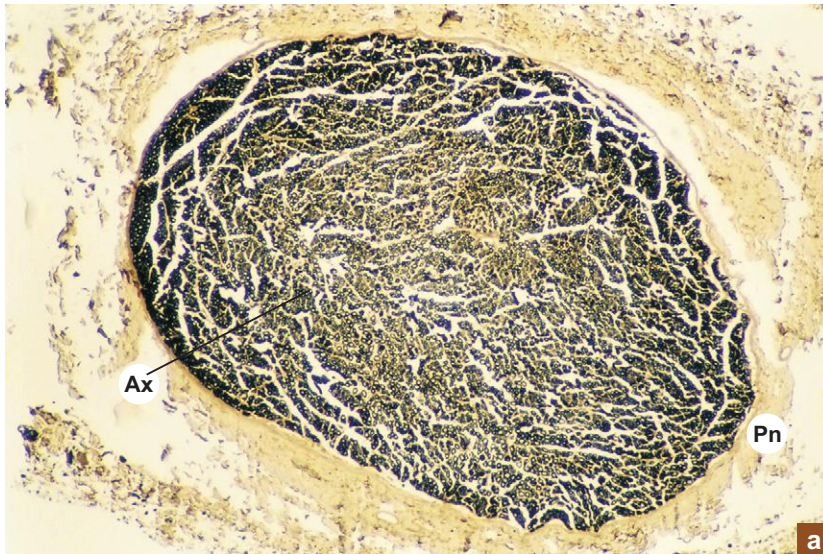
X100

**Plate 9:6** C.S. of optic nerve.

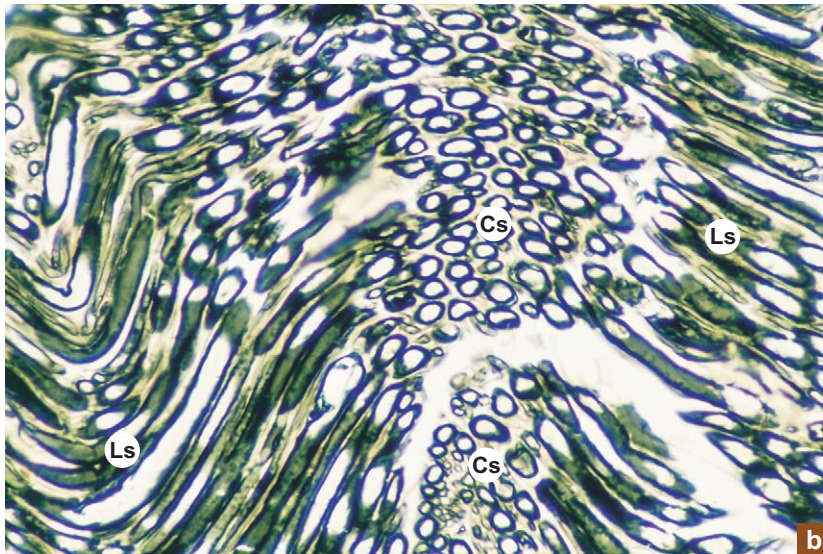
Note the following structures in the cross section of optic nerve:

- Dura mater (Dm).
- Arachnoid mater (Am) separated from dura mater by subdural space (Ds).
- Pia mater (Pm) separated from arachnoid by subarachnoid space (As).
- Central vessels (Cv) of retina in the centre.
- Bundles of optic nerve.

X40

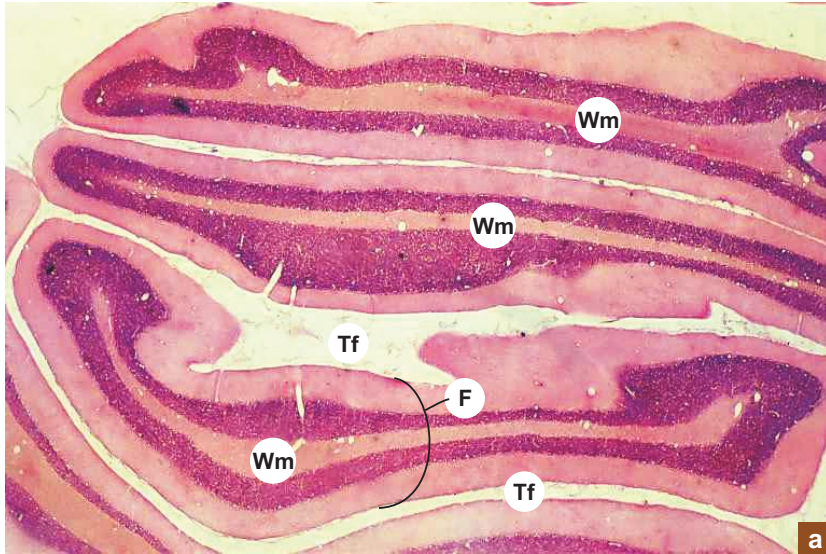


X200

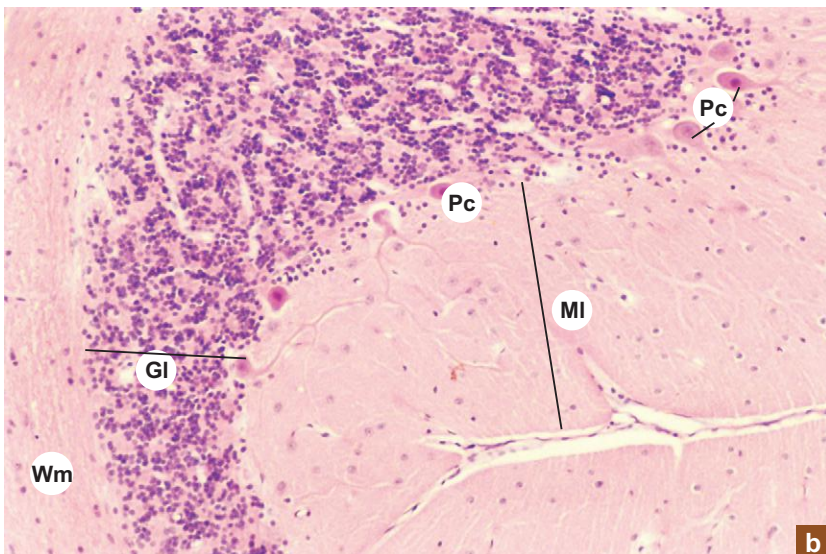

**Plate 9:7  
a and b**
**Peripheral nerve (osmic  
acid stained).**

- Myelin sheath can be demonstrated by fixing the nerve in osmic acid; it stains the myelin sheath black.
- In cross section (C.S.; Plate 9:7a), varying sizes of myelinated nerves can be seen as black rings (myelin sheath) around the pale unstained *axons*.
- In longitudinal section (L.S.; Plate 9:7b), the *myelin sheath* appears as elongated dark bands surrounding the pale unstained strands of axons.
- The dark myelin sheath is interrupted by the *nodes of Ranvier*. Some of the fibers are cut crosswise in the centre.  
Ax = axon; Pn = perineurium.

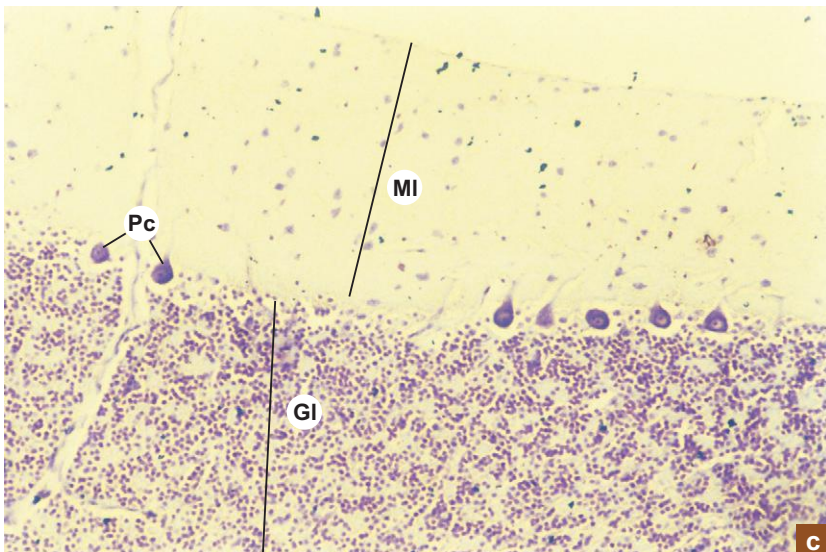
X10



X100



X100



**Plate 9:8a** Folia of cerebellum (panoramic view).

Under scanner, examine a section of cerebellum and note the following structures:

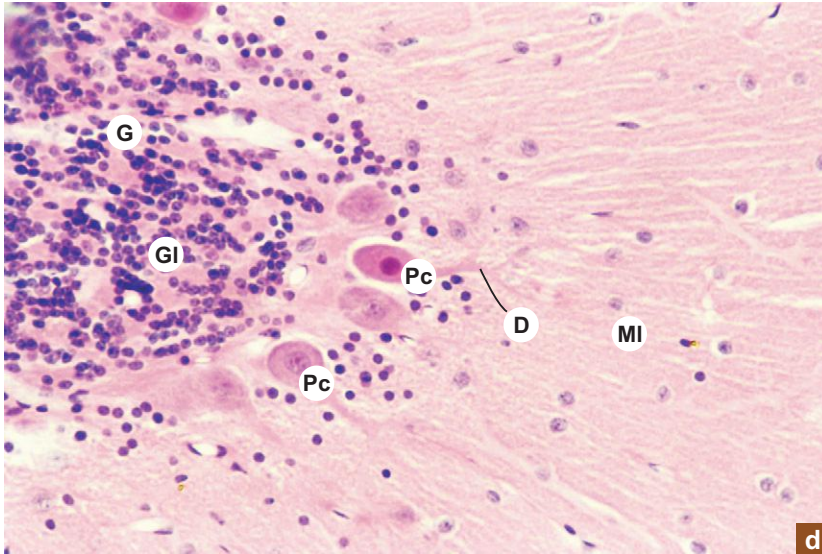
- Folia (F) separated by deep transverse fissure (Tf) containing pia mater.
- Branching white matter (Wm) in the centre of each folium.

**Plate 9:8 b and c** Cerebellar cortex; b. H&E staining and c. special stain.

At low magnifications identify the following three layers of cerebellar cortex:

- *Molecular layer (MI)*—contains few cells and more fibres, lightly stained.
- *Granular layer (Gl)*—contains densely packed small cells which are deeply stained.
- *Purkinje cell layer (Pc)*—made of large flask-shaped Purkinje cells (arrow) arranged in a single row between molecular and granular layers.

X200

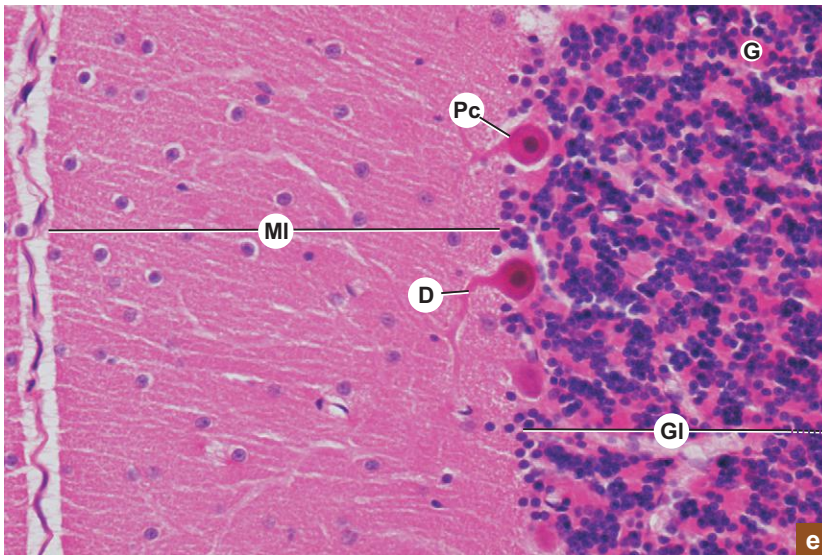


**Plate 9:8** Cerebellar cortex.  
**d and e**

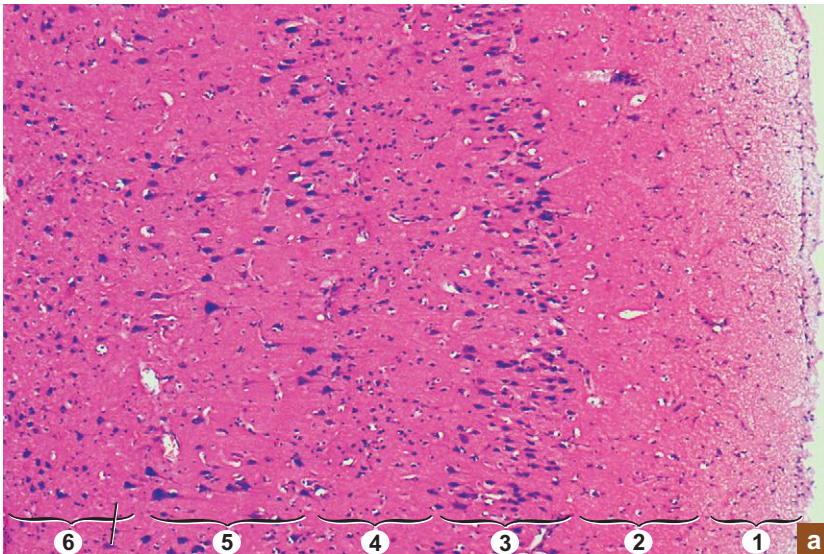
Under high power the size and shape of the cells present in the layers can be appreciated.

- Note the large flask-shaped Purkinje cells (Pc) giving off thick dendrites (D) into the molecular layer (MI).
- In the granular layer identify the predominant granule cells (dark nucleus), the scanty Golgi cells with vesicular nucleus and the lightly stained eosinophilic areas, glomeruli (G).

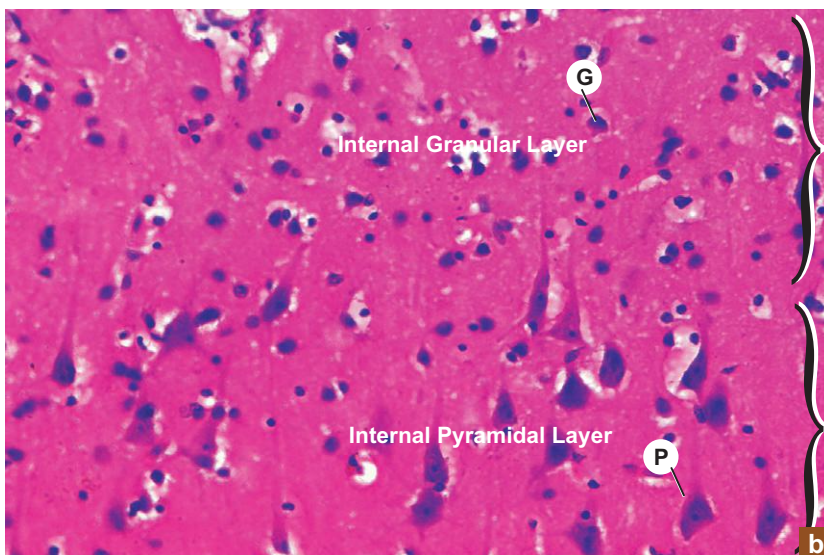
X400



X100

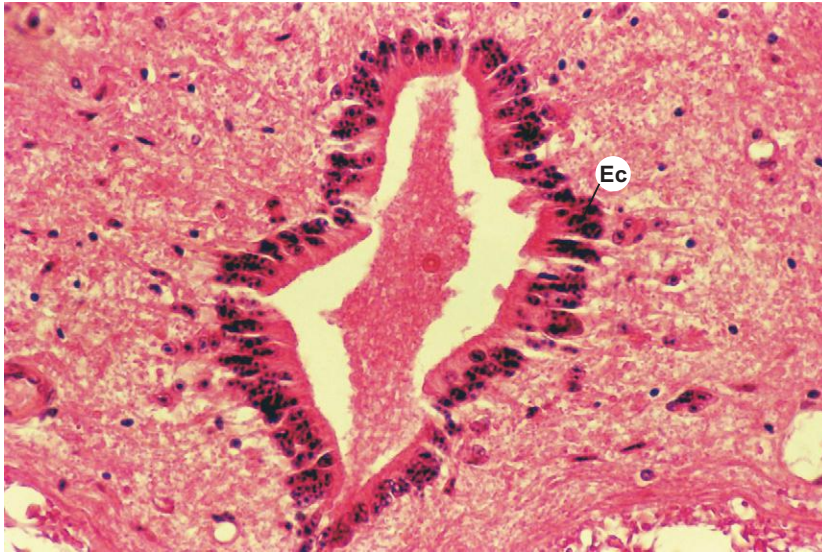


X400


**Plate 9:9** Cerebral cortex.  
**a and b**

- The most striking feature of cerebral cortex when examined under low power (Plate 9:9a) is the presence of pyramidal cells of varying size and granule or stellate cells of uniform size.
- Though six layers have been described, they cannot be identified clearly in a H&E section because the layers are not well demarcated by sharp boundaries. Only the superficial molecular layer deep to pia mater can be easily identified because it contains more of fibres and less of cells and is therefore lightly stained.
- The six layers that are described in the cerebral cortex are based on the presence of predominant cell types and fibre arrangements. The layers from superficial to deep are:
  1. Molecular layer
  2. External granular layer
  3. External pyramidal layer
  4. Internal granular layer
  5. Internal pyramidal or ganglionic layer (PL)
  6. Polymorphic or multiform layer.
- The shape and size of the pyramidal and granule cells can be appreciated at high magnification (Plate 9:9b).
- The size of pyramidal cells range from 10–120  $\mu\text{m}$ , whereas the granule cells are of uniform size (8  $\mu\text{m}$ ).  
 P = pyramidal cell; G = granule cell.

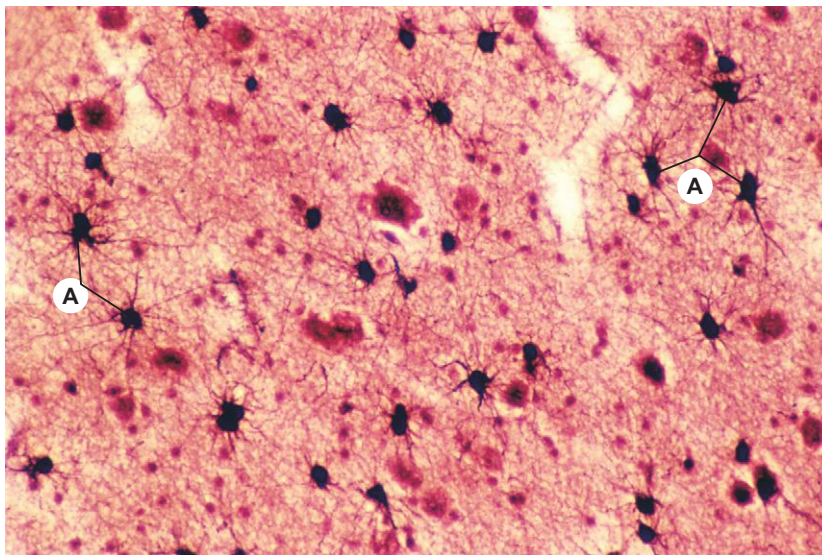
X200


**Plate 9:10 Ependyma (central canal of spinal cord).**

Examine the central canal of spinal cord at high magnification:

- It is lined by ependymal cells (Ec) which form a simple low columnar epithelium that lacks a basement membrane.
- The bases of the cells taper and ramify into the underlying tissue.
- The apical surface of some cells may show cilia.

X200


**Plate 9:11 Neuroglia (astrocyte).**

- Neuroglial cells can be demonstrated by staining with metallic stains like gold or silver impregnation technique. Note the astrocytes (A).
- The various types of cells can be identified based on their morphology given in Table 9.2.

# 10

# BLOOD VESSELS

## INTRODUCTION

Blood vessels deliver nutrients, oxygen and hormones to cells of the body and remove metabolic waste products and CO<sub>2</sub> from them through blood. Exchange of these substances takes place at the capillary level.

## TYPES OF BLOOD VESSELS

- Histologically there are five main types of blood vessels. They are:
  1. **Arteries**
    - (a) Large artery (elastic artery)
    - (b) Medium sized artery (muscular artery)
  2. **Arterioles**
  3. **Capillaries**
    - (a) Continuous capillary
    - (b) Fenestrated capillary
    - (c) Sinusoidal capillary
  4. **Venules**
  5. **Veins**
    - (a) Medium-sized vein
    - (b) Large vein

## STRUCTURE

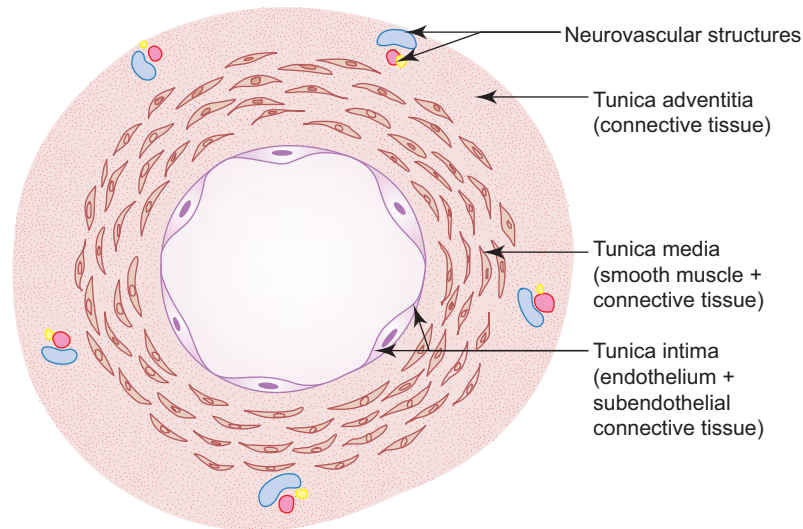
- All blood vessels have the same basic structure (Fig. 10.1). Each has three coats or tunics, namely,
  - (a) *Tunica intima*
    - It is composed of lining endothelium (simple squamous epithelium) and subendothelial connective tissue.
  - (b) *Tunica media*
    - This layer is made of smooth muscle and connective tissue.
  - (c) *Tunica adventitia*
    - It is constituted of fibroelastic connective tissue.

## ARTERIES

### GENERAL FEATURES

- Arteries are thick-walled blood vessels that carry blood from heart to capillaries.





**Fig. 10.1** General structure of a blood vessel.

- They divide repeatedly like a branch of a tree and gradually become smaller in size. However, their luminal surface is increased many times (800-fold) compared to that of a large artery (aorta). This causes a decrease in the rate of blood flow, facilitating exchange of substances through the capillaries.

## STRUCTURE

- The arteries are subdivided into the following types based on their structure and size:

### 1. Large/Elastic/Conducting artery (Box 10.1)

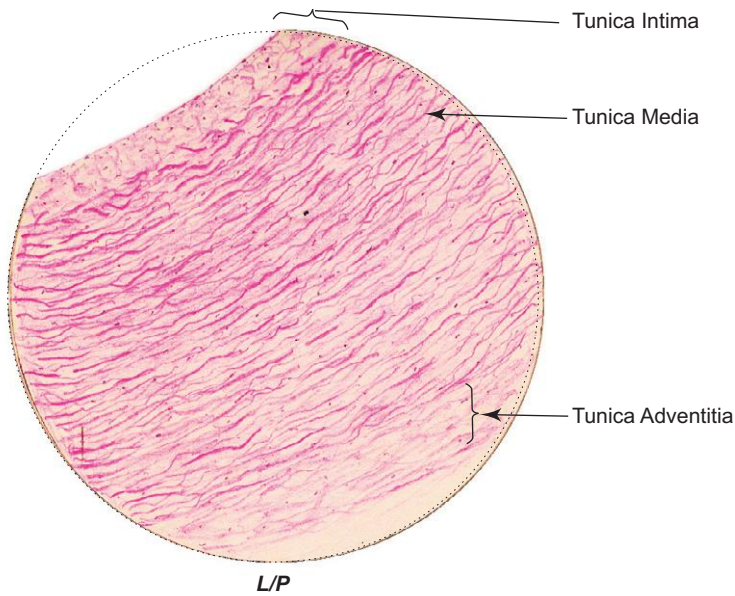
Example, aorta and its branches:

- It conducts blood from heart.
- Thickness of its wall is about one-tenth of the luminal diameter that varies.
- Presence of elastic fibres in the wall allows it to expand during contraction (systole) and to recoil during relaxation (diastole) of heart. This maintains necessary blood pressure, and thus permits the blood to flow more evenly through the other arterial channels.
- The following are the layers of large arteries:
  - (a) *Tunica intima* (100  $\mu\text{m}$  thick)
    - It includes endothelium and *subendothelial connective tissue*.
    - Subendothelial tissue contains fibrocytes, macrophages and smooth muscle-like cells called *myointimal cells*. The fibres (collagen and elastic) in it are longitudinally oriented.
    - Tunica intima is demarcated from tunica media by a poorly defined fenestrated internal elastic lamina.
  - (b) *Tunica media*
    - It is mainly made of about 40–70 layers of fenestrated *elastic laminae* arranged circularly. Hence the name elastic artery.
    - Between elastic laminae it contains smooth muscle cells and collagen fibres embedded in a basophilic matrix rich in chondroitin sulphate.
    - The outermost elastic lamina is thickened and called external elastic lamina.
  - (c) *Tunica adventitia*
    - It is composed of fibroelastic connective tissue carrying small blood vessels (*vasa vasorum*) and unmyelinated sympathetic fibres.

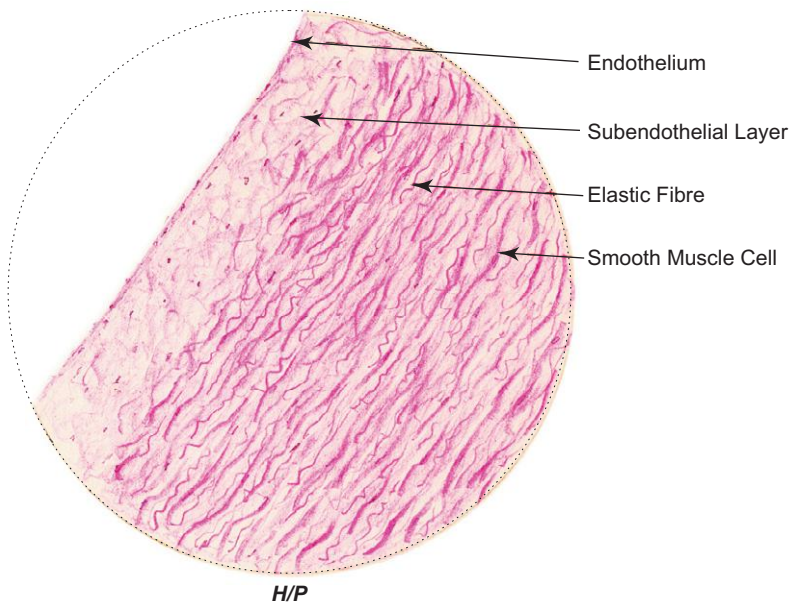
**Box 10.1** Large/Elastic Artery.

Presence of

- (i) thin tunica media with many **elastic laminae**;
- (ii) **vasa vasorum** in tunica adventitia;
- (iii) well developed subendothelial layer in tunica intima.



**Large/elastic artery**



**Large/elastic artery**

**Changes due to age in large artery:**

- Thickening of tunica intima due to migration and proliferation of smooth muscle cells from tunica media. (Tunica intima forms one-sixth of the total wall thickness.)
- Accumulation of lipid in the myointimal cells and macrophages.
- Formation of fibrofatty plaques in tunica intima (*atheroma*).
- Calcification of tunica media (*arteriosclerosis*).

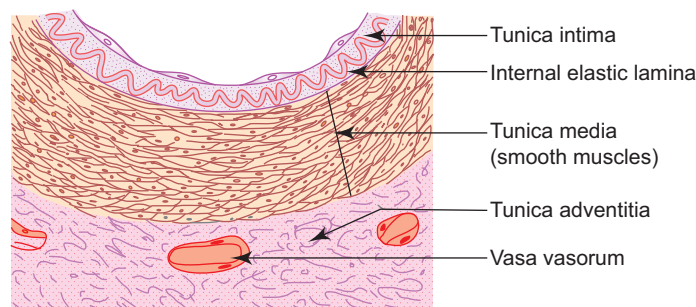
The aforementioned age-related changes in the artery are described as **atherosclerosis** (atheroma + arteriosclerosis) and they lead to gradual narrowing of the arterial lumen. Atherosclerosis is a killer disease more common in men. It not only affects the large artery but also the coronary and cerebral arteries causing arterial insufficiency leading to **infarction** or **stroke**.

Further, the tunica media may undergo atrophy resulting in loss of elasticity of the wall. The weakened wall may get stretched forming **aneurysm**. Rupture of aneurysm may cause death.

**2. Medium-sized/Muscular/Distributing artery (Box 10.2)**

Example: *branches of external carotid artery, radial and ulnar arteries:*

- It distributes blood to various parts of the body.
- Its wall thickness is about one-fourth of the luminal diameter.
- Presence of smooth muscle in its wall helps to control flow and pressure of blood through vasoconstriction or vasodilatation.
- The three layers of the wall (Fig. 10.2) are as follows:
  - (a) *Tunica intima*
    - It is made of endothelium and internal elastic lamina (no subendothelium).
    - The *internal elastic lamina* is a bright refractile membrane thrown into wavy folds due to contraction of smooth muscle in the media.
  - (b) *Tunica media*
    - It consists mainly of *smooth muscle* cells arranged circularly (about 40 layers). Hence the name muscular artery.
    - It also contains elastic and few collagen fibres intermixed with smooth muscle cells.
  - (c) *Tunica adventitia*
    - The inner part of tunica adventitia contains more elastic than collagen fibres and it includes the external elastic lamina.
    - The middle part contains collagen and elastic fibres running longitudinally.
    - The outer part is made of loose connective tissue, that merges with the surrounding areolar tissue and contains vasa vasorum and unmyelinated sympathetic nerve fibres.

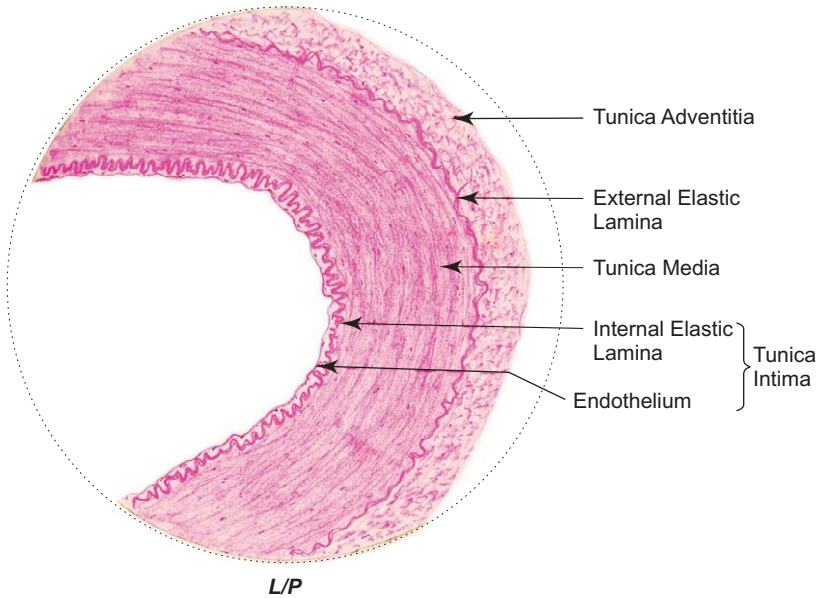


**Fig. 10.2** Muscular artery.

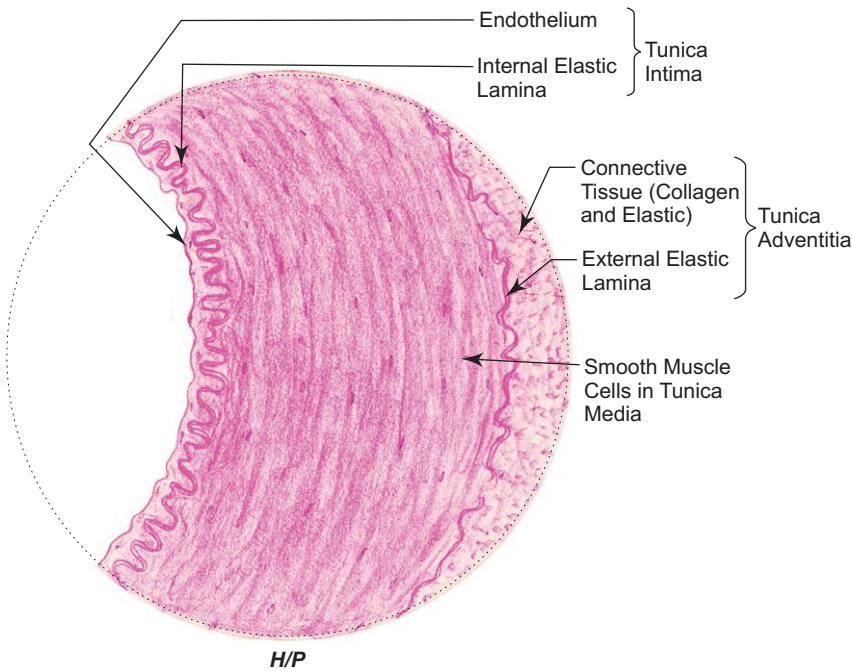
**Box 10.2** Medium-sized/  
Muscular Artery.

Presence of

- (i) thick tunica media with many **smooth muscle fibres**;
- (ii) well developed **internal elastic lamina** (thrown into wavy folds);
- (iii) elastic fibres in tunica adventitia.



**Medium-sized/muscular artery**



**Medium-sized/muscular artery**

## ARTERIOLE

### GENERAL FEATURES

- It is a small artery having a diameter less than 0.5 mm.
- It has a thick wall relative to the size of its small circular lumen.
- The terminal branches of arterioles are called *meta-arterioles*. They have smaller lumen and only few smooth muscle cells. This smooth muscle acts as precapillary sphincter regulating the flow of blood through capillary network depending on the metabolic need of the tissue.

### STRUCTURE

- An arteriole is composed of the following three layers:
  - (a) *Tunica intima*
    - It is thin having only endothelial lining.
    - It has neither subendothelial layer nor internal elastic lamina.
  - (b) *Tunica media*
    - It is made of 1–5 layers of circularly arranged smooth muscle cells.
  - (c) *Tunica adventitia*
    - This layer is thin and poorly developed.
    - It contains sympathetic vasomotor nerve fibres that bring about contraction of smooth muscle and thus control the size of the lumen.

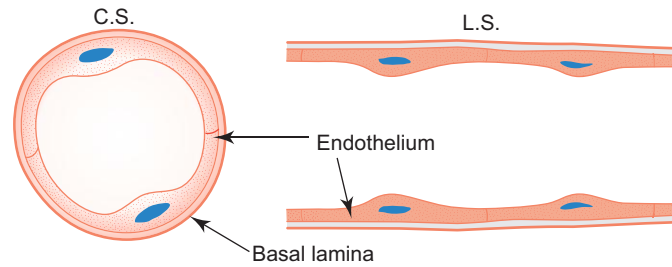
## CAPILLARIES

### GENERAL FEATURES

- Arterioles break up into small blood vessels called capillaries.
- Capillaries are often referred to as *exchange vessels*, because they are involved in exchange of gases, nutrients and metabolites between blood and tissue.
- Tissues with high metabolic rates have abundant capillary network (e.g. kidney, liver, cardiac muscle).

### STRUCTURE

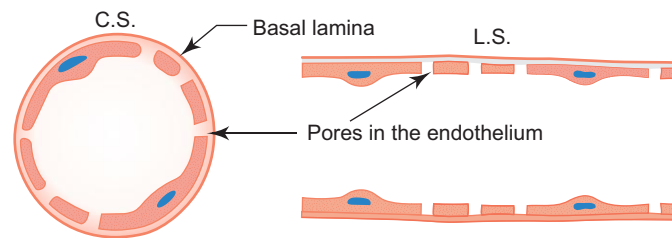
- The lumen of a typical capillary is about 7–9  $\mu\text{m}$  wide (equal to the diameter of an erythrocyte) and is lined by endothelial cells, which are two or three in number on cross section of vessel and form its **tunica intima**.
- The margin of endothelial cells are held together by tight and gap junctions. Numerous pinocytotic vesicles are seen in the cytoplasm. They are involved in transporting material across the endothelial lining in either direction.
- *Pericytes* or *adventitial cells* are occasionally seen within the basement membrane of the endothelium constituting the **tunica media**. These cells contain contractile filaments in the cytoplasm and can transform into other cells.
- A thin layer of collagen fibres that surround the capillaries form the **tunica adventitia**.
- Capillaries are divided into following three types depending on the nature of the endothelium:
  1. **Continuous or somatic capillary (Fig. 10.3)**
    - It is the commonest type of capillary present in connective tissue, muscle, brain, lung, etc.
    - The endothelial cells form a continuous lining of the capillary.



**Fig. 10.3** Continuous capillary.

**2. Fenestrated or visceral capillary (Fig. 10.4)**

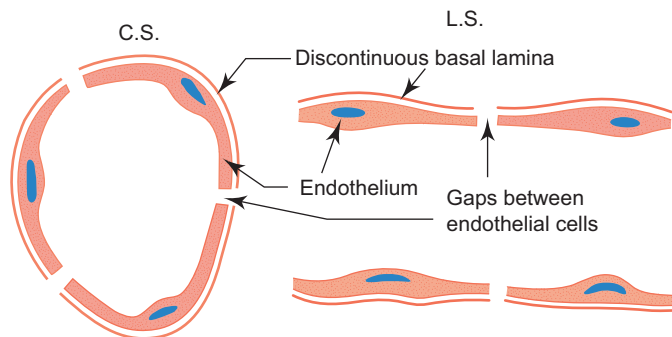
- This is characterised by the presence of tiny pores in the endothelial cells.
- These pores are often closed by a thin diaphragm (thinner than the cell membrane) and allows dissolved substances and macromolecules to pass through slowly.
- The permeability of fenestrated capillary is much greater than that of continuous capillary. So they are found in tissues in which rapid exchange of substances occur between tissues and blood, e.g. *kidney, intestinal villi, endocrine glands*, etc.



**Fig. 10.4** Fenestrated capillary.

**3. Sinusoidal capillary (Fig. 10.5)**

- It is found in liver and haemopoietic organs like red bone marrow and spleen.
- It is a thin walled tortuous blood vessel having a large irregular lumen (30–40  $\mu\text{m}$ ).
- Lumen is lined by discontinuous endothelium (the basal lamina is discontinuous). There are gaps between the endothelial cells that permit the passage of blood cells and macromolecules.
- Phagocytic cells may be seen in its wall (e.g. *Kupffer's cells in liver*).



**Fig. 10.5** Sinusoidal capillary.

## FUNCTIONS OF CAPILLARY ENDOTHELIUM

- **Permeability:**
  - Capillary endothelium allows exchange of water, oxygen,  $\text{CO}_2$  and metabolites between blood and tissue.

- It also allows migration of leucocytes from blood to tissue (diapedesis), which is increased during inflammation.
- It forms blood brain barrier – the tight junction between the endothelial cells and absence of pinocytotic vesicles in the cytoplasm suggest the presence of blood brain barrier.
- *Metabolic function:* Capillary endothelial cells can metabolise a wide variety of substances:
  - Activation – converts angiotensin I to angiotensin II.
  - Inactivation – converts some active substances (like bradykinin, serotonin, prostaglandin, norepinephrine, thrombin) into inactive/inert compounds.
  - Lipolysis – breaks down lipoprotein into triglycerides and cholesterol.
- *Nonthrombogenic function:* Platelets do not normally adhere to an intact endothelium. This is due to the ability of endothelial cells to release prostacyclin, which is a powerful inhibitor of platelet aggregation and thus prevent, clot formation.

## VENULE

### GENERAL FEATURES

- Venules receive blood from capillaries.
- They have a larger diameter (0.5–1 mm) than arterioles.
- Small venules (*postcapillary venules*) take part in exchange of metabolites between blood and tissue and permit leucocyte migration as do capillaries. The post capillary venules in mucosa associated lymphoid tissue (MALT) are lined by tall cuboidal endothelial cells and are called high endothelial venules (HEV). Venules are sensitive to inflammatory agents resulting in leakage of fluids and defensive cells).

### STRUCTURE

- The wall is thin with a large collapsed lumen.
- A venule is composed of the following three layers:
  - (a) *Tunica intima*
    - It is composed of endothelium.
  - (b) *Tunica media*
    - It is composed of one or two layers of smooth muscle fibres.
  - (c) *Tunica adventitia*
    - It is thick and composed of connective tissue rich in collagen fibres.

## VEINS

### GENERAL FEATURES

- Veins are thin-walled blood vessels that carry blood from capillaries to heart.
- Large veins are formed by union of smaller veins like tributaries of a river.
- They are often provided with valves which serve to prevent the reflux of the blood.

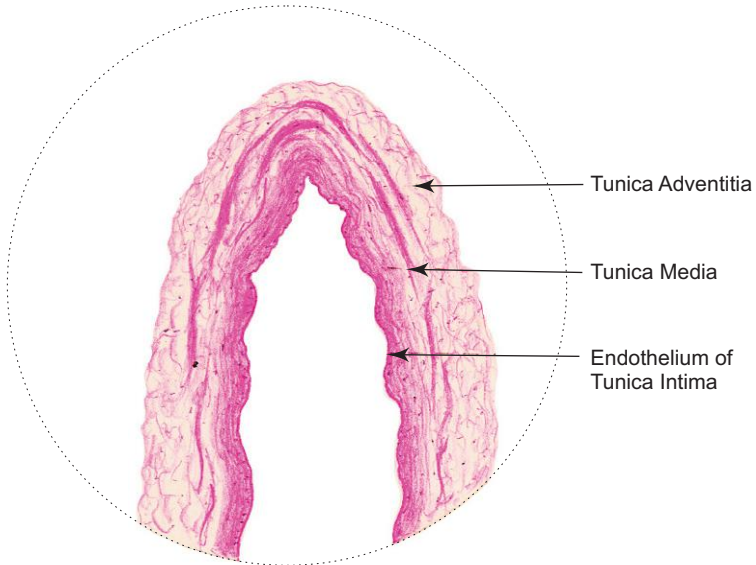
### STRUCTURE

- The veins are subdivided into the following types based on the size.
  1. **Medium-sized vein (Box 10.3)**

**Box 10.3** Medium-sized Vein.

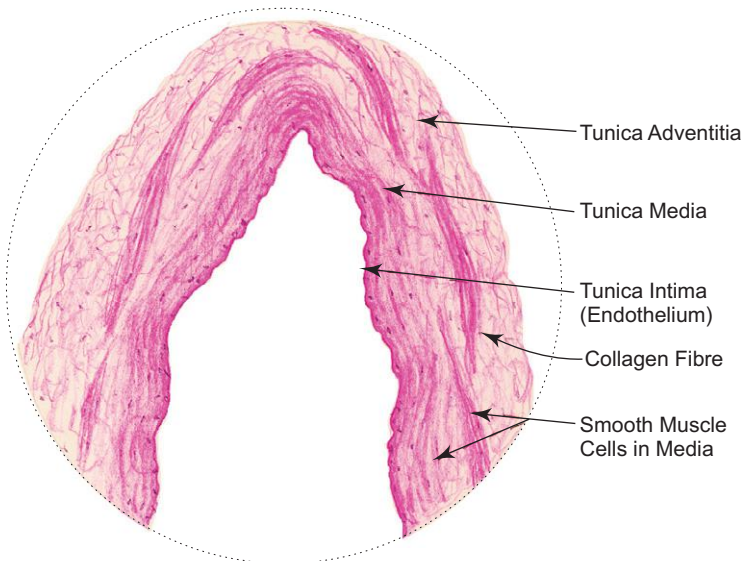
*Presence of*

- (i) thin tunica media with few smooth muscle fibres and less elastic fibres;
- (ii) large collapsed lumen.



*L/P*

**Medium-sized vein**



*H/P*

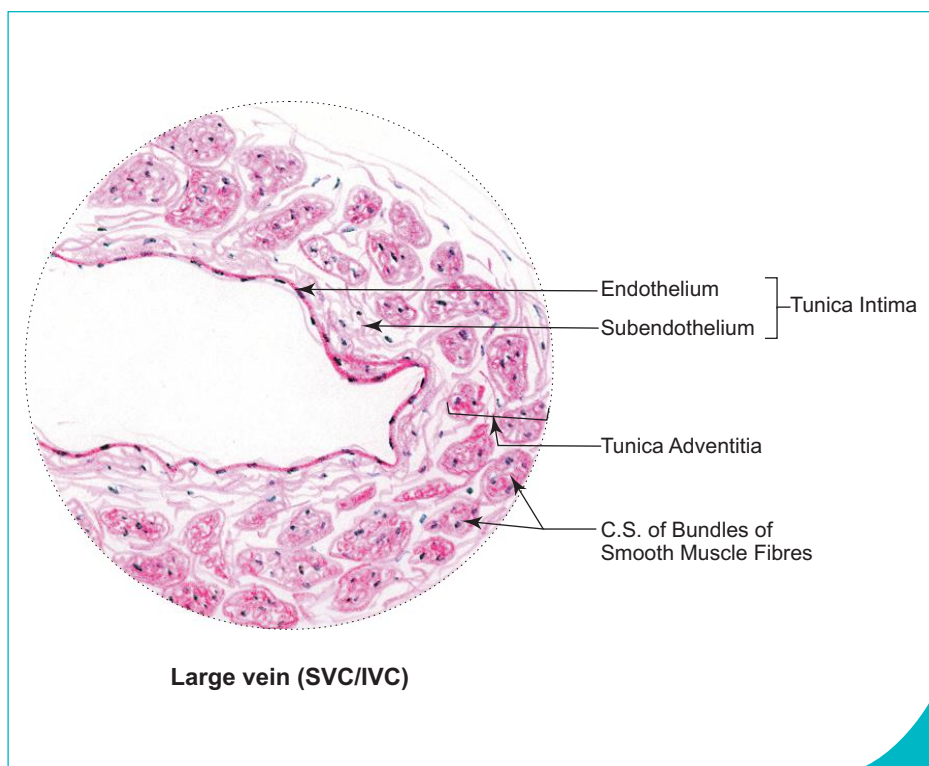
**Medium-sized vein**



- Medium-sized vein differs from medium-sized artery in having
  - a collapsed lumen,
  - thin wall with tunica media containing fewer smooth muscle and less elastic fibres,
  - no internal elastic lamina,
  - presence of valves to prevent back flow of blood.
- It is composed of the following three layers:
  - (a) *Tunica intima*
    - It is made of endothelium supported by a thin layer of subendothelium.
    - It does not have internal elastic lamina.
  - (b) *Tunica media*
    - It is composed of few circularly arranged smooth muscle fibres embedded in connective tissue predominantly made of collagen fibres. Elastic fibres are few.
  - (c) *Tunica adventitia*
    - This comprises loose fibroelastic connective tissue carrying vasa vasorum and nerve fibres.

## 2. Large vein, e.g. *superior vena cava (SVC)*, *inferior vena cava (IVC)*; Box 10.4

- It is made of the following three layers:
  - (a) *Tunica intima*
    - This layer is well developed.
    - It is formed by endothelium with subendothelial connective tissue.
  - (b) *Tunica media*
    - It is either thin or absent.
  - (c) *Tunica adventitia*
    - It is well developed and is the thickest coat.
    - It is made of many longitudinal bundles of smooth muscle fibres embedded in connective tissue.



### Box 10.4 Large Vein (SVC/IVC).

Presence of

- (i) thick tunica adventitia with longitudinally oriented **bundles of smooth muscle fibres**;
- (ii) poorly developed tunica media.

# Self-assessment Exercise

## I. Write short notes on:

- (a) Muscular artery
- (b) Elastic artery
- (c) Capillaries

## II. Fill in the blanks:

1. Blood vessels are lined with a specialised simple squamous epithelium called \_\_\_\_\_
2. Blood vessels supplying a blood vessel are called \_\_\_\_\_
3. The lumen of a typical capillary is about \_\_\_\_\_ wide.
4. The process by which leucocytes migrate from blood to tissue is called \_\_\_\_\_
5. Capillaries in endocrine glands are lined with \_\_\_\_\_ endothelium.

## III. Choose the best answer:

1. A large artery is characterised by the presence of
  - (a) a well developed internal elastic lamina
  - (b) elastic fibres in tunica media
  - (c) smooth muscle fibres in tunica adventitia
  - (d) mesothelial lining
2. Atherosclerosis in artery is due to
  - (a) thickening of tunica intima
  - (b) accumulation of lipid in myointimal cells
  - (c) calcification of tunica media
  - (d) all of the above
3. Medium-sized artery is characterised by the presence of
  - (a) a well developed internal elastic lamina
  - (b) a well developed subendothelial connective tissue
  - (c) elastic fibres in tunica media
  - (d) smooth muscle fibres in tunica adventitia
4. Pericytes are
  - (a) modified endothelial cells
  - (b) phagocytic cells
  - (c) pluripotent cells found in association with capillaries
  - (d) found in tunica media of arterioles
5. Capillary endothelial cells are involved in
  - (a) conversion of angiotensin I to angiotensin II
  - (b) exchange of metabolites
  - (c) diapedesis
  - (d) all of the above

**IV. State whether the following statements are true (T) or false (F):**

1. Precapillary sphincter is present in metarteriole. ( )
2. Internal elastic lamina is well developed in arterioles. ( )
3. Postcapillary venules take part in exchange of metabolites between blood and tissue. ( )
4. The diameter of the sinusoidal capillary is of uniform size. ( )
5. Tissues with high metabolic rate have abundant capillaries. ( )

**V. Match the items in column 'A' with those of column 'B':****Column 'A'***Blood vessel*

1. Large artery ( )
2. Medium-sized artery ( )
3. Arteriole ( )
4. Capillary ( )
5. Large vein ( )

**Column 'B'***Salient feature (presence of)*

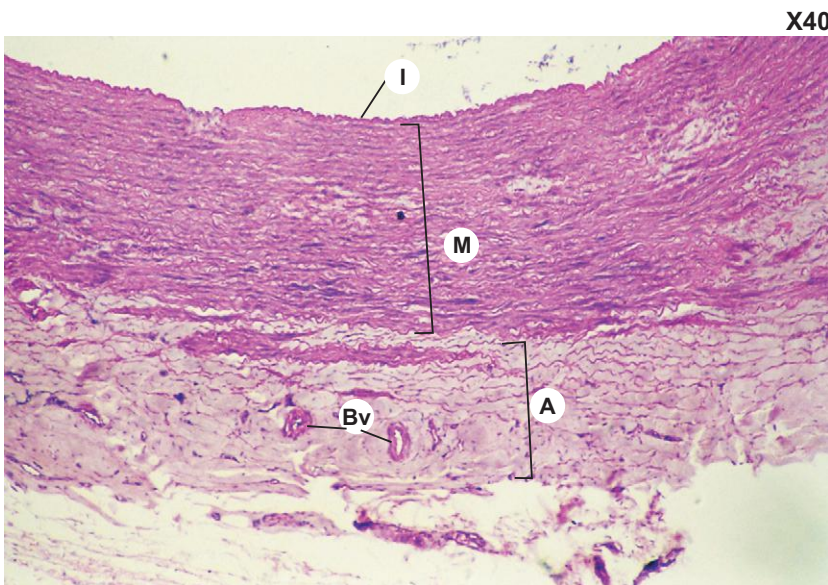
- (a) Thick muscular wall relative to the narrow circular lumen
- (b) Pinocytotic vesicles seen in the cytoplasm of endothelial cells
- (c) Well developed tunica adventitia with bundles of smooth muscle
- (d) Well developed tunica media containing elastic fibres
- (e) Well developed tunica media containing smooth muscle fibres

**Answers**

- II.** 1. Endothelium    2. Vasa vasorum    3. 7–9 mm    4. Diapedesis    5. Fenestrated
- III.** 1. b    2. d    3. a    4. c    5. d
- IV.** 1. (T)    2. (F)    3. (T)    4. (F)    5. (T)
- V.** 1. d    2. e    3. a    4. b    5. c

# Practical No. 10

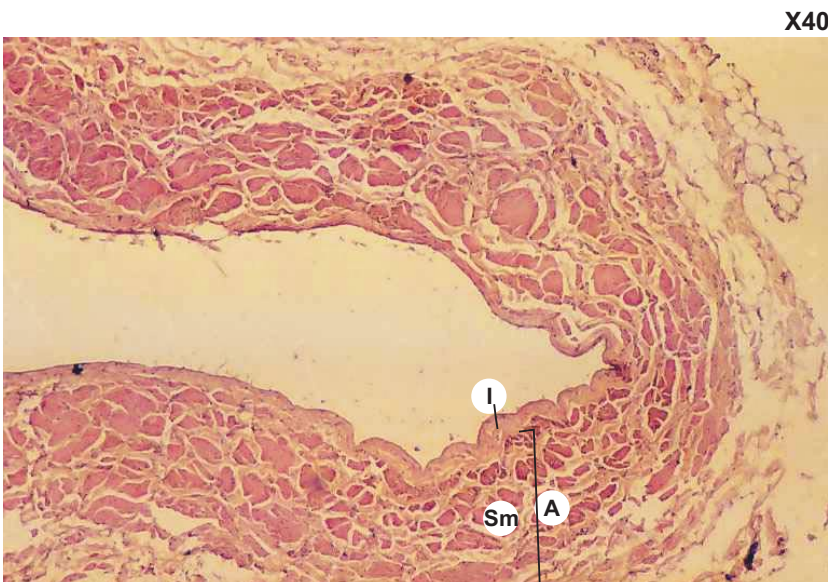## Blood Vessels



**Plate 10:1** Large artery (elastic artery).

Examine a section of large artery under low power. Identify the three tunics.

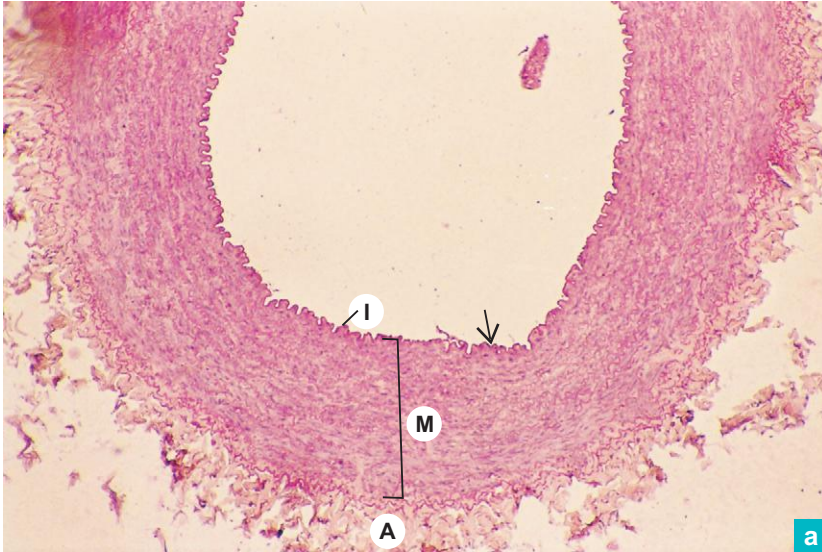- Tunica intima (I) – consists of endothelium and subendothelial connective tissue (not prominent in this section).
- Tunica media (M) – is thick and made primarily of concentric layers of *elastic laminae* (arrow) and few smooth muscle fibres between laminae.
- Tunica adventitia (A) – is composed of fibroelastic connective tissue carrying small blood vessels (Bv), *vasa vasorum* and vaso-motor nerve fibres.



**Plate 10:2** Large vein.

Large vein is characterized by the presence of a *thick tunica adventitia* (A) which contains bundles of smooth muscle fibres (Sm) running parallel to the long axis of the blood vessel. Note the thin tunica intima (I) and the very thin tunica media which may sometimes be absent.

X40



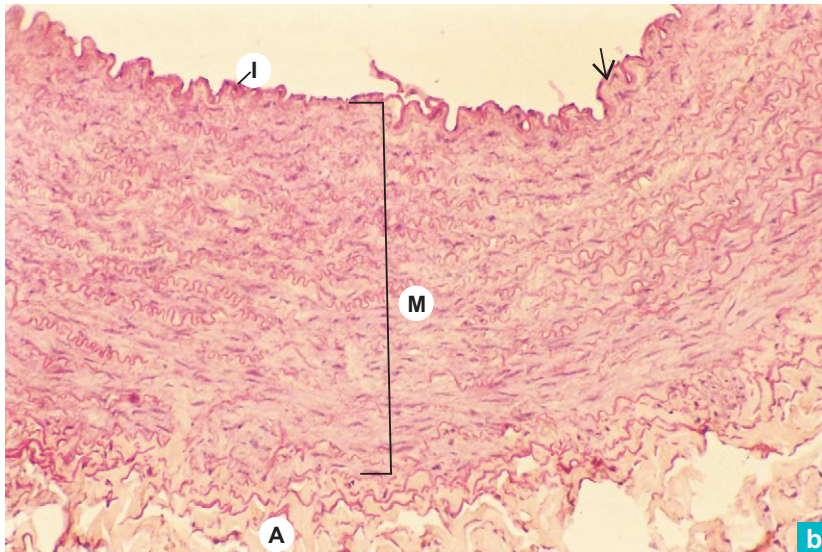
a

### Plate 10:3 Medium-sized or muscular artery. a and b

Identify the three coats at low magnifications (Plate 10:3a) and the salient features at higher magnitude (Plate 10:3b).

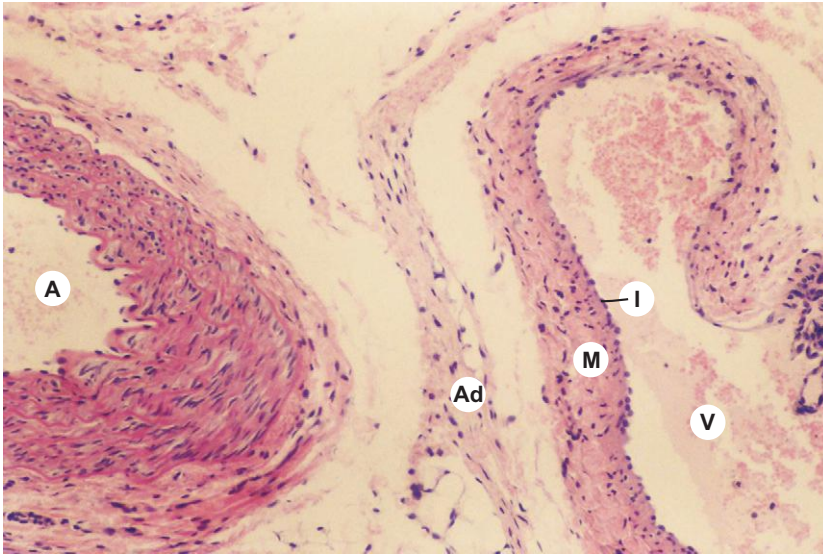
- Tunica intima (I) – is made of endothelium and internal elastic lamina. (There is no sub-endothelium.)
  - Note the *well-developed internal elastic lamina* (**arrow**) which is thrown into wavy folds due to contraction of smooth muscle in the media.
- Tunica media (M) – is composed mainly of *smooth muscle* fibres arranged circularly.
  - fine elastic fibres are seen interspersed among the smooth muscle fibres.
- Tunica adventitia (A) – contains elastic fibres in the inner part and collagen fibres in the outer part.

X100



b

X40



**Plate 10:4** Medium-sized artery and vein.

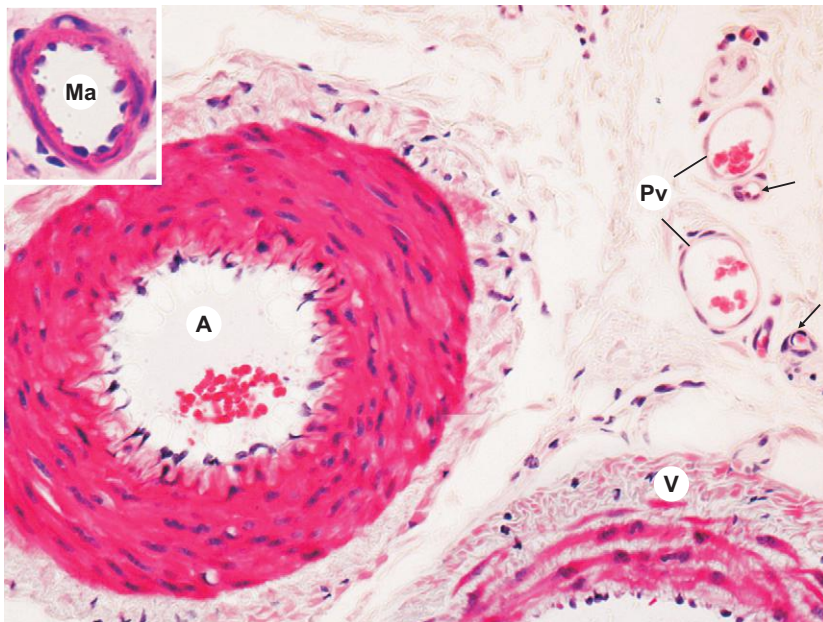
The photomicrograph shows a medium-sized artery (A) and a medium sized vein (V).

Identify the three tunics in medium-sized vein.

Note the thin tunica media (M) with few smooth muscle fibres embedded in collagenous connective tissue. There is no internal elastic lamina in tunica intima (I).

Ad = adventitia.

X400



**Plate 10:5** Group of small blood vessels.

The photomicrograph illustrates an arteriole (A), a venule (V) and a group of still smaller vessels.

Arteriole has a thick wall relative to its small circular lumen, whereas venule has a thin wall relative to the large lumen. Note the presence of more blood corpuscles in the lumen of the venule.

Ma = metarteriole; Pv = postcapillary venule; arrow = points out to a capillary.

"This page intentionally left blank"

# 11

# INTEGUMENTARY SYSTEM

## INTRODUCTION

Integumentary system includes skin and its appendages, namely, hair and nail. Skin covers the surface of the body and comes into direct contact with the external environment. It is the single heaviest organ of the body forming one-sixth of the total body weight, and its surface area is 18 sft. On close observation, the external surface of the skin shows many lines such as tension lines due to anchoring fibrils of dermis, flexure lines over joints and friction ridges (papillary ridges) over palm and sole. The papillary ridges and the intervening sulci on the palm and sole assume a unique configuration for each individual and is used for personal identification. The study of these configurations is called *dermatoglyphics* (finger print) which is an upcoming field and of considerable medical, anthropological and legal interest. The dry skin becomes continuous with the wet mucous membrane at various orifices seen on the surface of the body, *viz.*, mouth, nostril, anus, vulva, etc.

## FUNCTIONS OF SKIN

- *Protection:* Skin gives protection against mechanical trauma, invasion of microorganisms, evaporation (water loss) and ultraviolet rays (by melanin pigments).
- *Sensory perception:* Skin is the largest sense organ of the body. It contains many receptors for general sensation (pain, touch, temperature and pressure).
- *Thermoregulation:* It is mainly performed by glands (sweating) and also by blood vessels and adipose tissue.
- *Synthesis of vitamin D:* Epidermis of skin is involved in synthesis of vitamin D from 7-dehydrocholesterol by the action of UV light.
- *Excretion:* Skin acts as a minor excretory organ for certain catabolic nitrogenous waste products and water.
- *Blood pressure regulation:* This is done by specialized arteriovenous anastomosis called glomus found in the dermis of the skin.
- *Storage:* Skin acts as a storehouse for glycogen and cholesterol in the subcutaneous fat.
- *Absorption:* Skin also absorbs certain lipid soluble substances, drugs/chemicals which are of therapeutic value.

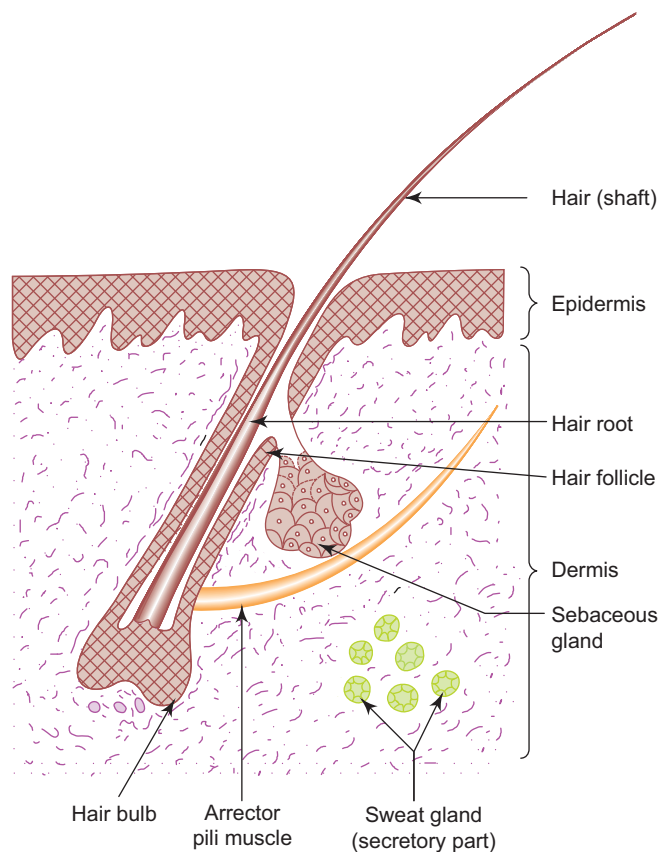
*Skin is useful in personal identification, especially in criminology—through dermatoglyphics (finger print).*

## TYPES OF SKIN

There are two types of skin:

1. **Thin skin or hairy skin (Fig. 11.1; Box 11.1)**
  - Epidermis is very thin.
  - Has hair.
  - Found in all other parts of the body except palm and sole.
2. **Thick skin or glabrous skin (Box 11.2)**
  - Epidermis is very thick with a thick layer of stratum corneum.
  - Has no hair.
  - Found in palm of hand and sole of foot.





**Fig. 11.1** Thin skin.

## STRUCTURE

- Skin is composed of two layers, epidermis and dermis. The epidermis is made of stratified squamous keratinized epithelium, whereas the dermis is made of connective tissue.
- The dermo-epidermal junction is not smooth, but uneven due the presence of two sets of ridges interlocking alternately with one another, *viz.*, epidermal ridges and dermal papillae. These ridges are numerous, tall and often branching in areas where mechanical demands are high, e.g. *palm, sole, nipple, penis*, etc.

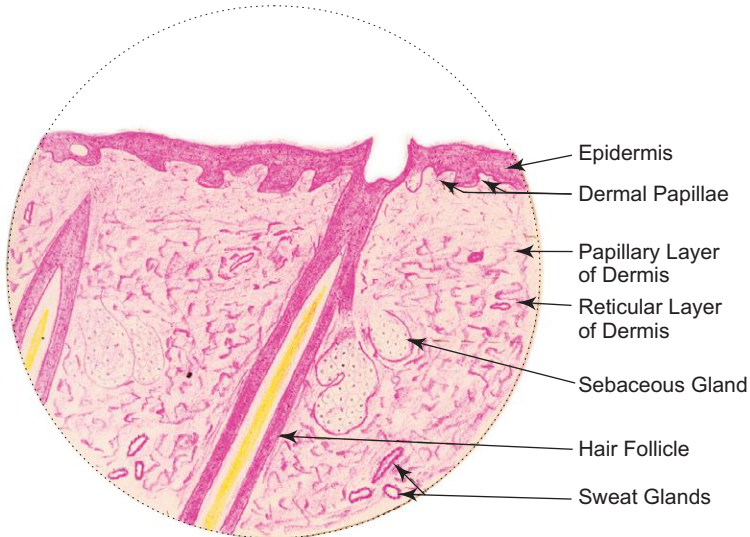
## EPIDERMIS

- Is dry epithelium made of stratified squamous keratinized epithelium.
- Projects into the dermis as epidermal ridges.
- Is ectodermal in origin.
- Its thickness varies from 0.1 mm to 1.4 mm.
- Is avascular and is nourished by diffusion.
- Free nerve endings are seen in its basal layer.
- Is mainly made of keratinocytes; other cells are melanocytes, Langerhans cells, Merkel's cells.
- Is renewed every 15–30 days depending on the region of the body, age and other factors.

**Box 11.1 Thin Skin (Hairy Skin).**

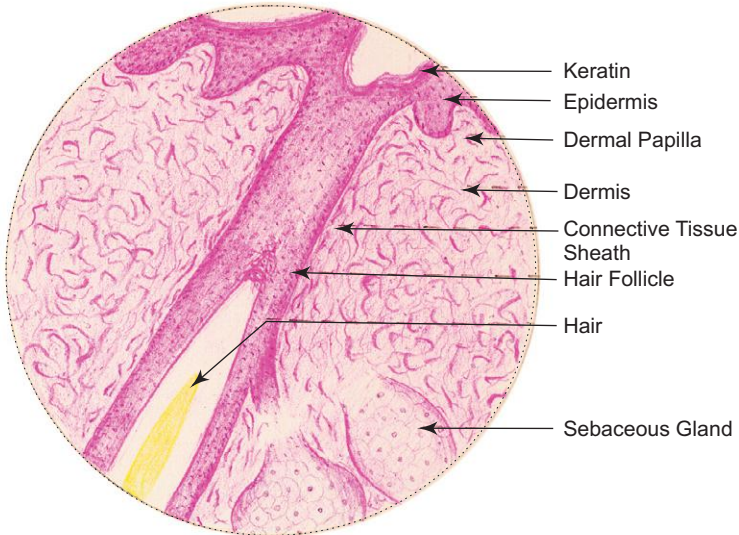
*Presence of*

- (i) **thin epidermis** made up of **keratinized stratified squamous epithelium** (stratum corneum is thin);
- (ii) **hair follicles** and **sebaceous glands**;
- (iii) **sweat glands** in the dermis.



*L/P*

**Thin skin (Hairy skin)**



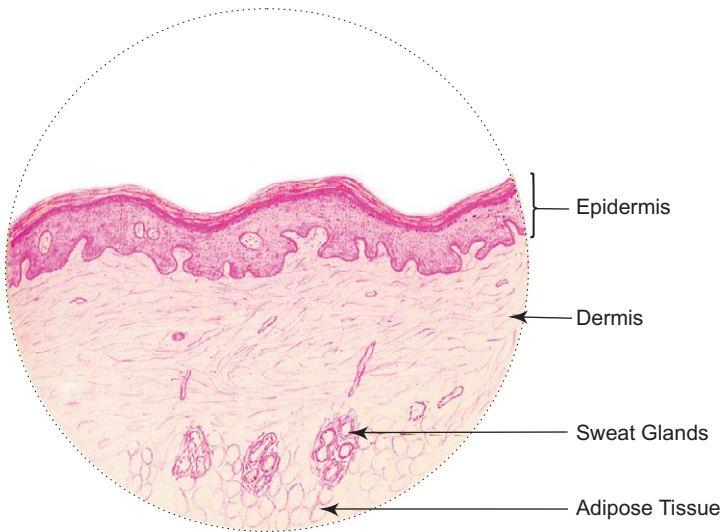
*H/P*

**Thin skin (Hairy skin)**

**Box 11.2** Thick/Glabrous Skin (Nonhairy Skin).

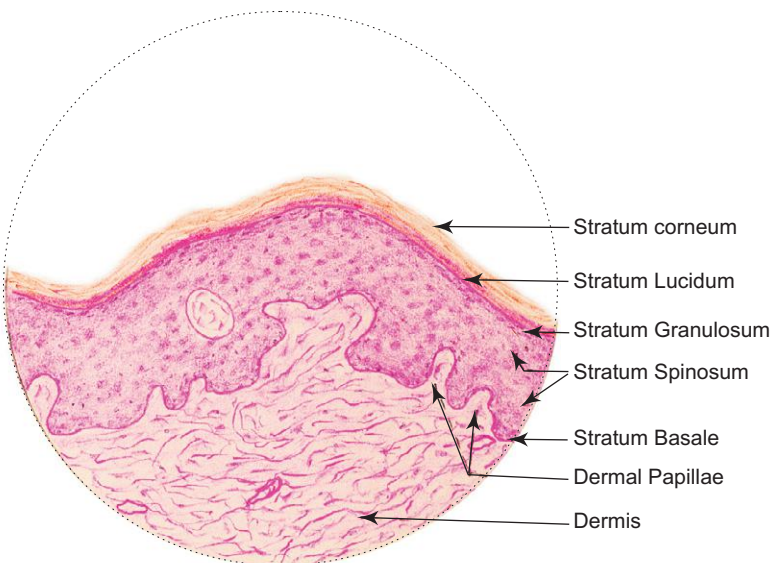
Presence of

- (i) **thick epidermis** made up of **keratinized stratified squamous epithelium** (stratum corneum is very thick);
- (ii) **absence of hair follicles and sebaceous glands;**
- (iii) presence of **sweat glands** in the dermise.



L/P

Thick/glabrous skin (Nonhairy skin)



H/P

Thick/glabrous skin (Nonhairy skin)

## Layers of Epidermis (Fig. 11.2)

Five layers can be distinguished in the epidermis from its deep to superficial surface.

### 1. Stratum basale

- It is the deepest layer of epidermis.
- It consists of a single layer of cuboidal/low columnar cells lying on the basement membrane.
- Cells of this layer show mitotic figures and the newly formed cells move towards the superficial layer.

### 2. Stratum spinosum

- It consists of several layers of polyhedral cells which are held together by desmosomes at the spine-like projections of the plasma membrane, hence the name.
- Cells of this layer contain bundles of tonofilaments which are seen under light microscope as tonofibrils.
- This layer is well developed in areas of skin subjected to continuous friction and pressure.

### 3. Stratum granulosum

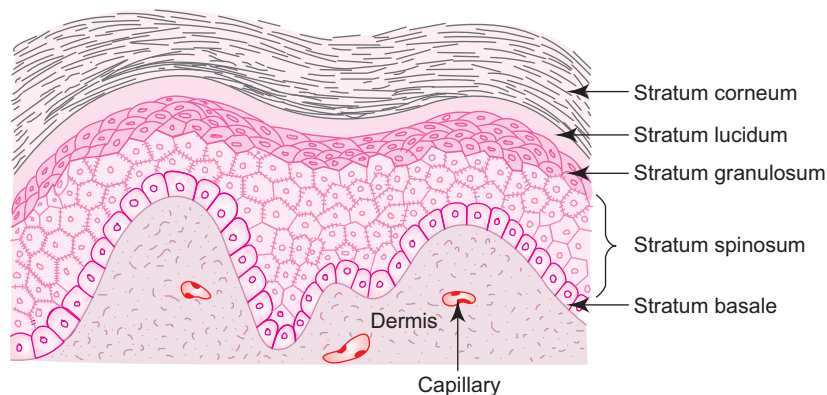
- It is made of 3–5 layers of flattened fusiform cells. They are filled with basophilic keratohyalin granules (precursor of keratin) and membrane-coating granules. These membrane-coating granules discharge their contents into the intercellular space of the granular layer providing the epidermis a 'sealing effect' against foreign materials.

### 4. Stratum lucidum

- It is made of flattened eosinophilic dead cells forming a homogeneous glassy layer. The organelles and the nuclei are no longer evident in these cells. The cytoplasm is filled with a tough scleroprotein, called keratin, derived from keratohyalin granules and tonofibrils.

### 5. Stratum corneum

- It is the most superficial layer of epidermis.
- It contains flattened non-nucleated dead scaly keratinized cells whose plasma membrane is thickened and cytoplasm filled with keratin.
- The cells of this layer are continuously shed from the superficial surface.



**Fig. 11.2** Layers of epidermis.

## Cells of Epidermis

Epidermis is made of the following four cell types:

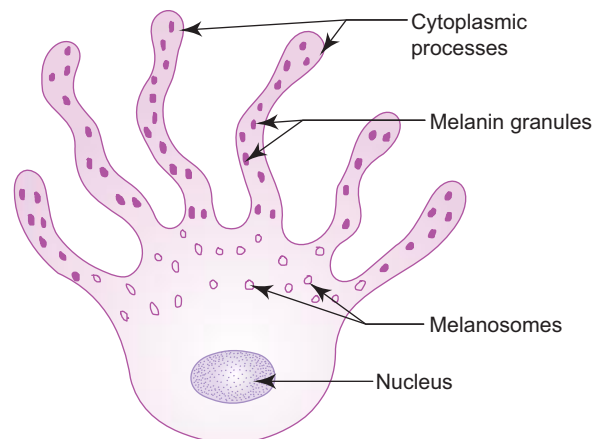
### 1. Keratinocytes

- They are the most abundant cell type (more than 90% of population) that undergo keratinization and form the above mentioned five layers.

- Their main function is to produce a tough complex scleroprotein known as keratin, which is composed of a mixture of amorphous protein (from keratohyalin granules) and fibrillar protein (from tonofibrils) that provides protection to the skin.
- As the keratinocytes migrate from the stratum basale toward surface they begin to undergo keratinization.
- In the process of keratinization the following events take place in keratinocytes:
  - loss of mitotic potential,
  - keratin synthesis,
  - thickening of the plasma membrane,
  - disintegration of nuclei and organelles, and
  - cornification and desquamation of the cells.
- The dead, cornified keratinocytes are shed periodically from the surface (life span 15–30 days).

## 2. Melanocytes (Fig. 11.3)

- They are the second most commonly seen cells and are derived from neural crest cells.
- They are found in the basal layer of epidermis and appear as clear cells in H&E stained section.
- They are round in shape with many cytoplasmic processes that run between keratinocytes in stratum spinosum.
- They can be stained histochemically for 3,4 dihydroxyphenylalanine (DOPA) reaction.
- They produce melanin pigment (dark brown pigment), which is mainly responsible for the colour of the skin.
- They transfer (inject) melanin pigments into the keratinocytes by a process called 'cytocrine secretion'.
- Under E/M, melanocyte reveals lack of tonofilaments and desmosomes.
- Tyrosinase-filled vesicles called melanosomes, which play an important role in melanin synthesis, are also found in the cytoplasm.
- In the process of melanin synthesis tyrosine is first transformed to DOPA by the action of tyrosinase present in melanosomes and then to dopaquinone which is converted after a series of transformations into melanin.
- Absence of tyrosinase activity leads to a condition known as *albinism*.



**Fig. 11.3** Melanocyte.

## 3. Langerhans cells

- They are the third most common cells of the epidermal cell population.
- They are found mainly in the stratum spinosum (they are also found in oral mucosa, vagina and in thymus).
- They can be stained with gold chloride.
- Like melanocytes, they also appear as clear cells with many cytoplasmic processes that run between keratinocytes.
- Under E/M, they show presence of specific tennis-racket shaped granules (Birbeck granules) in the cytoplasm and absence of tonofilaments and desmosomes.
- They are antigen-presenting cells, which process and present cutaneous antigens to lymphoid cells in the dermis.
- They are mesodermal in origin and included in mononuclear phagocytic system.

#### 4. Merkel's cells

- They are sensory cells present in the stratum basale and are associated with expanded terminal discs of nerve endings forming special receptors concerned with touch sensation (vide infra).

**Psoriasis** is a common skin disease where the cells in the stratum basale proliferate very rapidly and undergo keratinization within 7 days (normally keratinization takes 40–60 days). This results in increase in thickness of epidermis with immature keratinocytes producing raised red patches under white scale. These cells are desquamated prematurely before the keratin is fully formed.

**Vitiligo** is another common skin disease in which the melanocytes are destroyed due to an autoimmune reaction. This results in bilateral depigmentation of skin.

**Moles** or **Nevi** are benign accumulation of melanocytes in the dermis, epidermis or both.

Chronic exposure to excessive UV light leads to various skin cancers such as, **basal cell carcinoma** affecting basal cells of stratum basale, **squamous cell carcinoma** affecting squamous cells of stratum spinosum and **malignant melanoma** affecting melanocytes. Malignant melanoma is a dangerous invasive tumour of melanocytes. This may penetrate into dermis and invade the blood and lymph vessels to gain wider ramification.

## Dermis

- Dermis is made of vascular connective tissue derived from mesoderm.
- It corresponds to lamina propria of mucous membrane.
- The thickness of dermis varies from 0.3 mm to 4.0 mm (thinner in the eyelid and thicker in the trunk).
- Dermis from animal skin is tanned commercially and is known as 'leather'.
- For descriptive purpose dermis is divided into *papillary* and *reticular layers*:

### 1. Papillary layer

- This forms the superficial layer of dermis and is composed of loose connective tissue containing fibroblasts, macrophages, mast cells and leukocytes and sometimes pigmented connective tissue cells called chromatophores in heavily pigmented areas like areola, circumanal region, etc. True melanocytes can be seen in Mongolian spot in the sacral region of infants (up to 5th month).
- The connective tissue of papillary layer projects into the epidermis as dermal papillae which interlock alternately with epidermal ridges making the dermo-epidermal junction more uneven, especially in thick skin. The dermal papilla contains either blood capillaries or Meissner's corpuscles (tactile corpuscles).
- This layer also contains perpendicularly running collagen fibrils called '*anchoring fibrils*' which bind the epidermis with dermis and are responsible for the tension lines seen on the surface.

### 2. Reticular layer

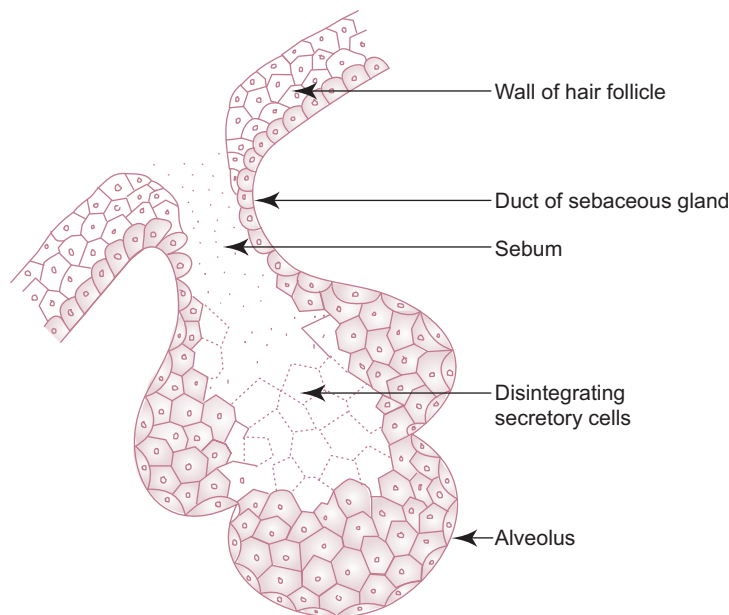
- Reticular layer is the deep layer of dermis and is mainly composed of irregular collagenous connective tissue (Type I collagen). Though the fibres are irregularly arranged, in general, they are longitudinally oriented in limbs and transversely in trunk and neck—'*Cleavage line*'.
- It also contains a network of elastic fibres which become thinner in the papillary layer. This network is responsible for the elasticity and firmness of the skin.
- Also found in the dermis are the sweat and sebaceous glands, hair follicles and arrector pili muscles. In some areas the dermis contains smooth muscle (in penis, scrotum and nipple) and skeletal muscle (in face and neck).
- The dermis has a rich network of blood and lymph vessels. The arteries and lymphatic vessels form two plexuses. The one located between papillary and reticular layer is called *papillary plexus* and the other between the dermis and hypodermis is called *cutaneous plexus*. Similarly, veins form three plexuses, two are found in the same plane as arterial plexuses and the third one is disposed in the middle of the dermis.
- In certain areas of skin, especially in thick skin, specialised arteriovenous anastomoses called *glomera* are present, where blood can pass directly from arteries to veins. Glomera play an important role in temperature and blood pressure regulation.
- Besides these components, the dermis also contains various cutaneous receptors like free nerve endings, peritrichial nerve endings, Meissner's and Pacinian corpuscles.

## GLANDS OF SKIN

- The glands of skin are the sebaceous and sweat glands.
- The oily secretion of sebaceous gland keeps the skin smooth to prevent it from drying and the watery secretion of sweat gland keeps the skin surface cool, thereby helps in maintaining body temperature.

### Sebaceous Gland

- Sebaceous gland is found in the dermis of the skin and is a simple acinar gland whose duct usually opens into the hair follicle (Fig. 11.4). But in certain regions like glans penis, clitoris and lip, it opens directly onto the epidermal surface.



**Fig. 11.4** Sebaceous gland.

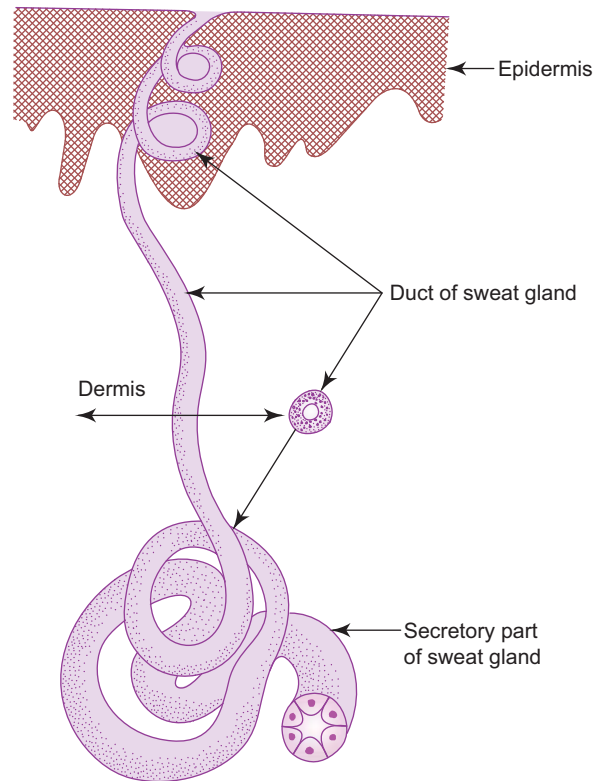
- Based on the mode of secretion, this gland is classified as holocrine gland.
- The secretory acinus of the gland consists of a basal layer of undifferentiated flattened epithelial cells resting on a basement membrane and centrally placed rounded cells (sebocytes) filled with fat droplets. These rounded cells eventually become bigger and burst outpouring the secretion, *sebum* with remnants of nuclei and organelles.
- Sebum is an oily secretion having antibacterial and antifungal properties. It contains lipids and cholesterol and its esters.
- The secretion of the gland is primarily controlled by testosterone in males and ovarian and adrenal androgens in females.

Any disturbance in the flow of sebum may lead to formation of **acne** (pimple), which is caused by inflammation of sebaceous gland due to bacterial infection. Acne may contain pus and are usually confined to face in teenagers.

### Sweat Gland or Sudoriferous Gland

- Sweat gland is found in the deeper part of dermis and is widely distributed. But it is absent in glans penis, inner surface of prepuce and margin of lip.
- It is a simple coiled, tubular gland whose duct usually opens on the epidermal surface (Fig. 11.5). The part of the duct present in the dermis is straight and is lined by stratified cuboidal epithelium, whereas the part that passes, through the epidermis is coiled and is limited by epidermal cells. (It has no lining of its own and is called acrosyngium.)

- The secretory tubules are lined by simple cuboidal epithelium and are bigger in size on cross section and lightly stained, whereas the ducts are smaller in size and darkly stained (Plate 11:6).
- There are two types of sweat glands present in human beings, namely, eccrine (merocrine) and apocrine. Their histological features are presented in Table 11.1.



**Fig. 11.5** Sweat gland.

**Table 11.1** Characteristics of sweat glands

	<b>Eccrine (merocrine) gland</b>	<b>Apocrine gland</b>
<i>Distribution</i>	Wide	Limited (axilla, areola, anus, external genitalia)
<i>Location</i>	Dermis	Hypodermis
<i>Size</i>	Small	Large
<i>Secretion</i>	Thin watery secretion	Thick viscous secretion
<i>Secretory tubule</i>	Simple cuboidal epithelium made of two types of cells (i) Dark cell—secretory cell (ii) Light cell—ion transporting cell + associated myoepithelial cells	Simple cuboidal epithelium made of only one type of cell + associated myoepithelial cells
<i>Duct (site of termination)</i>	Open on epidermal surface	Open into hair follicle above the duct of sebaceous gland.
<i>Innervation</i>	Cholinergic but sympathetic	Adrenergic (sympathetic)
<i>Control</i>	Neuronal	Neuronal and hormonal (sex hormones)
<i>Function</i>	Temperature control and excretion	Apart from temperature control and excretion, it has sexual function



## Other Modified Glands of Skin

1. Mammary gland	}	Modified apocrine sweat gland
2. Ceruminous gland in external acoustic meatus		
3. Glands of Moll in eyelid		
4. Glands of Zeis in eyelid	}	Modified sebaceous gland
5. Tarsal or Meibomian gland in eyelid		

## APPENDAGES OF SKIN

- Appendages of skin include the hair and nails which are made of dead scaly keratinized cells derived from epidermis.

### Hair

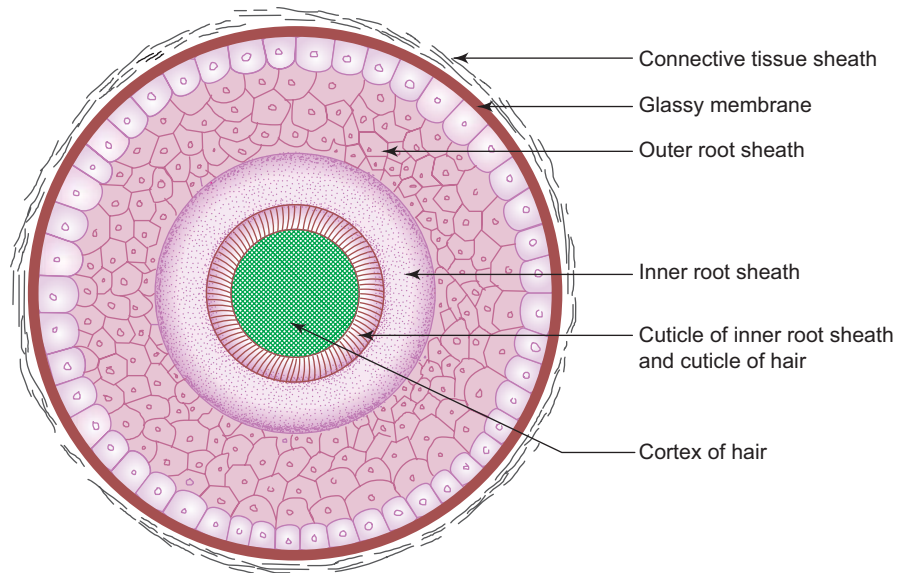
- Presence of hair in the skin is the characteristic feature of mammals.
- It is made of fused dead keratinized cells.
- Hair is found in all parts of the skin except palm, sole, lip, umbilicus, glans penis, clitoris, labia minora and distal phalanx.
- Skin of foetus is covered by fine hair called *lanugo* (primary hair) which is shed at birth and is replaced by pale downy hair called *vellus* (secondary hair). Vellus is retained in most of the regions of the body except scalp, face, eyebrow, axilla and pubis, where it is replaced by coarse dark hair called *terminal hair* (influenced by sex hormone).
- Hair is not placed at right angles to the surface but is set obliquely. The visible projecting part of the hair is called *shaft* (scapus) and the invisible part embedded in the dermis, is called *root* (radix). The root of the hair is surrounded by a tubular invagination of the epidermis called *hair follicle* from which hair arises.

### Structure of Hair

- Hair consists of cuticle, cortex and medulla.
- *Cuticle* is the outer layer and is made of single layer of flat scale-like cells that overlap one another from below.
- *Cortex* lies deep to the cuticle and is composed of several layers of elongated cells. Cortex forms the main bulk of the hair.
- *Medulla* is found in the centre and is made of large vacuolated cells which are often separated by air spaces.
- All the cells of the above layers of hair contain hard keratin and melanin pigment granules.

### Structure of Hair Follicle

- Hair follicle is the tubular invagination of the epidermis that surrounds the root of the hair.
- The deep expanded part of the follicle is called *hair bulb* which is made of pluripotent polyhedral matrix cells. Hair grows by differentiation and keratinization of cells of hair bulb.
- Melanocytes are also present in the hair bulb which transfer melanin granules into the cells of hair and are responsible for pigmentation of hair.
- The hair bulb is indented by vascular connective tissue of the dermis and is known as *hair papilla*.
- The hair follicle receives the duct of the sebaceous gland.
- It also gives attachment to a band of smooth muscle, called *arrector pili* muscle, below the level of sebaceous gland. Contraction of the muscle causes erection of hair resulting in *goose skin*, as occurs on exposure to cold or during emotions. Contraction also causes compression of sebaceous gland expressing sebum.
- The wall of the follicle has two coats, namely, *connective tissue sheath* derived from dermis and *epithelial or epidermal sheath* derived from epidermis.
- The epithelial sheath consists of the following layers from outer to inner (Fig. 11.6):
  1. *Glassy membrane*—thickened basement membrane separating connective tissue sheath from epithelial sheath.



**Fig. 11.6** C.S. of hair follicle.

2. *Outer epithelial root sheath*—corresponds to and is continuous with stratum basale and stratum spinosum of epidermis.
3. *Inner epithelial root sheath*—corresponds to superficial layers of the epidermis and is present only below the level of sebaceous glands
  - made of three layers, namely, from outer to inner, Henle’s layer, Huxley’s layer and cuticle.
  - the cells of the cuticle of inner root sheath interlock with the cells of cuticle of hair. This arrangement helps to anchor the hair within the follicle.

### Some Interesting Facts about Hair

- Straight hair are stronger than curly hair.
- Hair do not grow continuously but have a growth cycle [they have period of growth (anagen phase) followed by a period of rest (telogen phase)].
- Hair growth is not affected by frequency of cutting or shaving.
- Growth rate of hair is approximately 1.5–2.2 mm per week.
- Hair grow faster between ages 26 and 46 years.
- Life span of hair varies from region to region; in scalp as long as 4 years, in axilla as short as 4 months.
- Greying or whitening of hair is caused by either failure of melanocytes to form pigment granules (congenital) or appearance of small air bubbles among the cells of the cortex and medulla of hair. The reflection of light in the air bubbles is responsible for the glistening or silvery appearance of white hair.
- Baldness is caused by
  - progressive atrophy of hair follicle with age
  - genetic factor
  - presence of androgenic hormone.

### Nail

- Nail is a cornified plate of stratum corneum found on the dorsal surface of the terminal part of fingers and toes.
- The inferior surface of nail rests on nail bed which corresponds to stratum basale and stratum spinosum of the epidermis.

- The proximal part of nail is called nail root and is buried under a fold of skin called *eponychium*. The skin beneath the distal free end of the nail is known as *hyponychium*.
- The nail grows distally by proliferation and differentiation of matrix cells of the nail bed found near the root.

## SKIN RECEPTORS

- Numerous nonencapsulated and encapsulated receptors are found in the skin and they respond to stimuli for temperature, touch, pain and pressure. Thus, skin is the largest sense organ of the body.

### Nonencapsulated Receptors

- Nonencapsulated receptors are sensory nerve endings whose terminations are not covered by capsule.
  1. **Free nerve endings**
    - They are found in epidermis and dermis.
    - Free nerve endings in epidermis reach up to stratum granulosum and are concerned with touch and pain sensation.
  2. **Merkel's corpuscle/disc**
    - It is found in stratum basale of the epidermis.
    - Each corpuscle is composed of a free nerve ending that terminates as a disc-shaped expansion in relation to the Merkel's cell of the epidermis and is sensitive to touch.

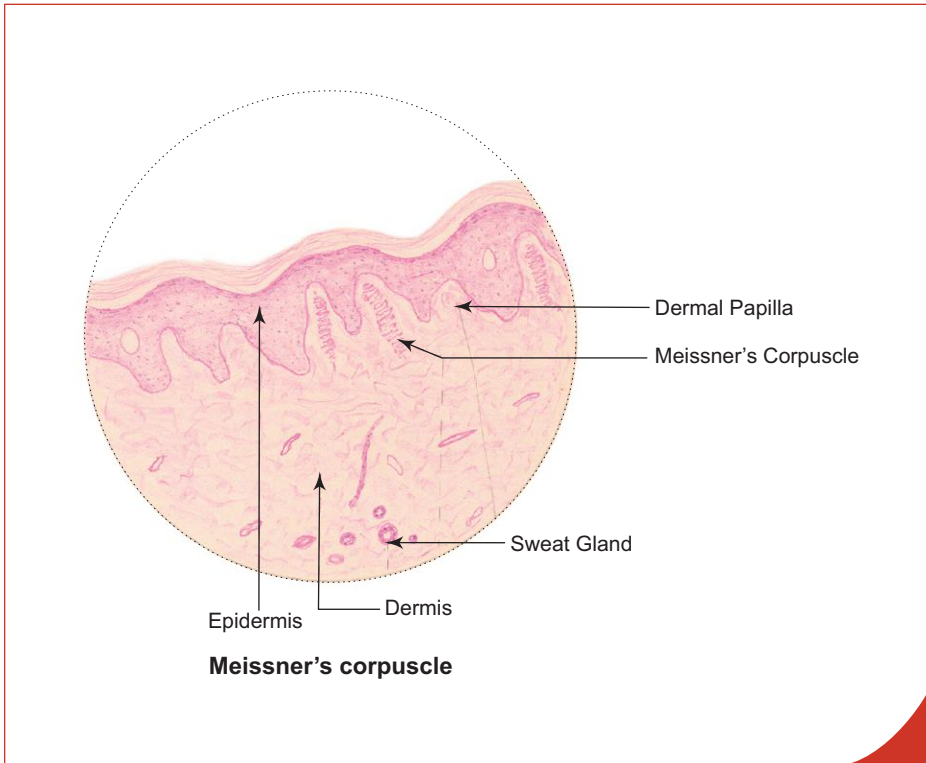
### Encapsulated Receptors

- In encapsulated receptors the termination of the nerve is covered by a capsule, not derived from nervous tissue.
  1. **Meissner's corpuscle (Box 11.3)**
    - It is found in the dermal papillae of skin, especially in thick skin.
    - It is cylindrical in shape, oriented perpendicular to the surface of the skin.
    - Each corpuscle is composed of a stack of flattened wedge-shaped modified Schwann cells (tactile cells) enclosed in a capsule with associated nonmyelinated nerve fibres which ramify among the stacked cells.
    - It is extremely sensitive to touch and enables an individual to distinguish between two points when they are placed close together on the skin (two point tactile discrimination).
  2. **Pacinian corpuscle (Box 11.4)**
    - It is found in the dermis (also present in ligaments, joint capsule, pleura, peritoneum, nipple and external genitalia).
    - It is oval in shape and resembles a sliced onion in a section.
    - It consists of a central cylindrical core containing a naked axon surrounded by many concentric lamellae of flattened epithelioid fibroblasts.
    - It is sensitive to pressure and vibration.
  3. **Ruffini's corpuscle**
    - It is fusiform in shape and is found in the dermis of the skin and joints.
    - It consists of bundles of elongated collagen fibres and fluid enclosed in a capsule with associated nerve fibres which ramify among the collagen fibres.
    - It is sensitive to stretch.

**Box 11.3 Meissner's Corpuscle.**

*Presence of*

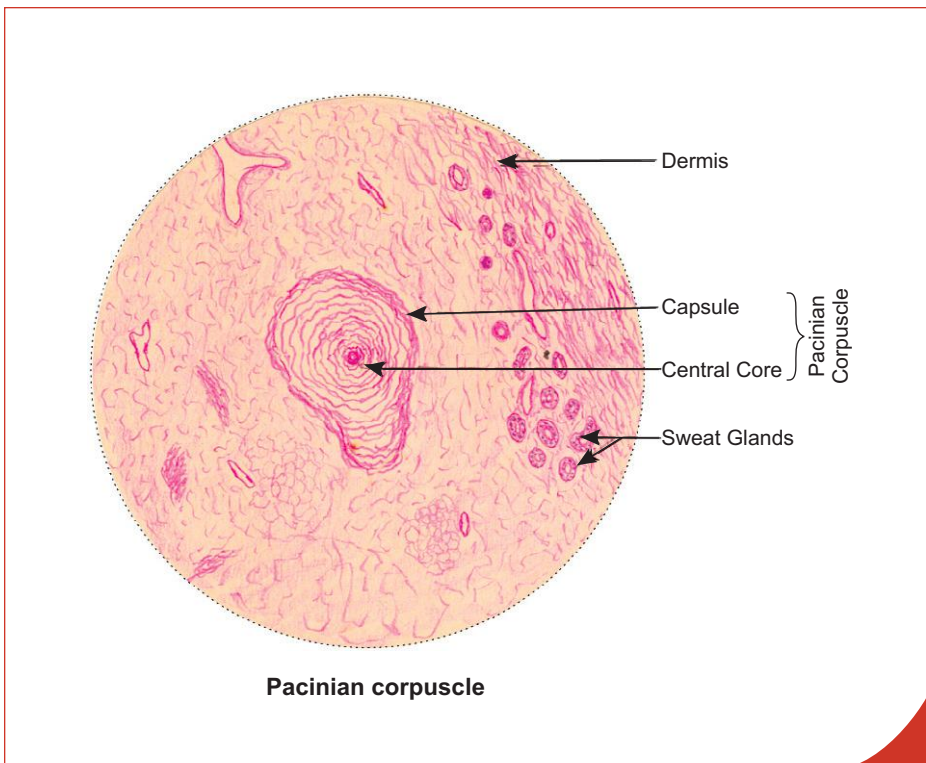
- (i) cylindrical encapsulated body in the **dermal papilla**;
- (ii) **zigzag course of the axon** among stacked cells forming the corpuscle.



**Box 11.4 Pacinian Corpuscle.**

*Presence of*

- (i) **concentric lamellae** of flattened fibroblasts giving a sliced onion appearance;
- (ii) central core containing a nerve fibre.



# Self-assessment Exercise

## I. Present detailed account of:

- (a) Structure of skin
- (b) Epidermal derivatives of skin

## II. Write short notes on:

- (a) Layers of epidermis
- (b) Melanocytes
- (c) Hair and hair follicle
- (d) Glands of skin
- (e) Cutaneous receptors
- (f) Differences between eccrine and apocrine sweat glands

## III. Fill in the blanks:

1. The specialised arteriovenous anastomosis in the skin is called \_\_\_\_\_
2. Melanocytes are derived from \_\_\_\_\_
3. The enzyme that plays an important role in melanin synthesis is \_\_\_\_\_
4. Absence of the tyrosinase activity leads to a condition called \_\_\_\_\_
5. Inflammation of sebaceous glands leads to formation of \_\_\_\_\_
6. Skin of foetus is covered by fine hair called \_\_\_\_\_
7. The receptor involved in two point tactile discrimination is \_\_\_\_\_
8. The appendages of skin consist of \_\_\_\_\_ and \_\_\_\_\_
9. The study of the configuration of ridges and sulci on the palm and sole is known as \_\_\_\_\_

## IV. Choose the best answer:

1. Thick skin is characterised by the presence of
  - (a) thick dermis
  - (b) long interlocking epidermal ridges with dermal papillae
  - (c) thick basement membrane
  - (d) all of the above
2. Thin skin is characterised by the presence of
  - (a) thin epidermis
  - (b) hair follicle
  - (c) sebaceous gland
  - (d) all of the above
3. Which of the following cells of epidermis is part of the immune system?
  - (a) Keratinocyte
  - (b) Melanocyte
  - (c) Langerhans cell
  - (d) Merkel's cell

4. The cutaneous receptor concerned with pressure is
  - (a) Pacinian corpuscle
  - (b) Meissner's corpuscle
  - (c) free nerve ending
  - (d) peritrichial nerve ending
5. The secretory tubules of sweat gland can be differentiated from the duct part by
  - (a) simple cuboidal epithelial lining
  - (b) stratified cuboidal epithelial lining
  - (c) smaller diameter of the tubule
  - (e) darker staining reaction with routine stains

**V. State whether the following statements are true (T) or false (F):**

1. Epidermis of skin is involved in synthesis of vitamin E ( )
2. Skin is the largest and heaviest sense organ ( )
3. Keratinocytes contain tonofilaments in their cytoplasm ( )
4. Stratum lucidum of epidermis is well developed in thick skin ( )
5. Sebaceous gland is a compound acinar gland ( )
6. Mammary gland is a modified apocrine sweat gland ( )
7. Hair do not grow continuously ( )
8. The main constituent of the hair is formed by the cells of the medulla ( )
9. Eccrine sweat glands are innervated by cholinergic sympathetic nerve fibres ( )
10. Sweat glands are absent in red margin of lip ( )

**VI. Match the items of column 'A' with those of column 'B':**

Column 'A'		Column 'B'
1. Glomera	( )	a. Modified sebaceous gland
2. Sweat gland	( )	b. Modified apocrine sweat gland
3. Sebaceous gland	( )	c. Thermoregulation
4. Ceruminous gland	( )	d. Hair follicle
5. Meibomian gland	( )	e. Blood pressure regulation

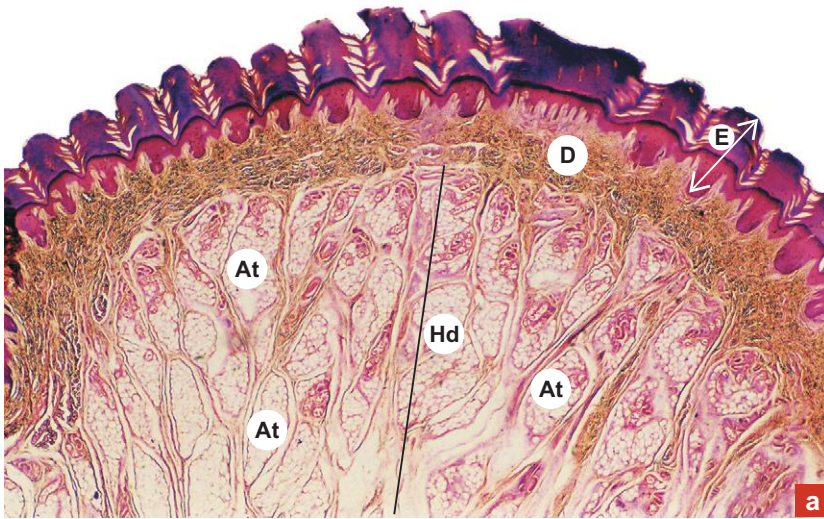
**Answers**

- III.** 1. Glomus    2. Neural crest cells    3. Tyrosinase    4. Albinism    5. Acne    6. Lanugo or primary hair  
 7. Meissner's corpuscle    8. Hair and nail    9. Dermatoglyphics
- IV.** 1. b    2. d    3. c    4. a    5. a
- V.** 1. (F)    2. (T)    3. (T)    4. (T)    5. (F)    6. (T)    7. (T)    8. (F)    9. (T)    10. (T)
- VI.** 1. e    2. c    3. d    4. b    5. a

# Practical No. 11

## Skin

X10



**Plate 11:1**  
**a and b**

**Thick skin or**  
**glabrous skin.**

**a. Panoramic view.**

Examine the thick skin under scanner (Plate 11:1a) and identify the following features:

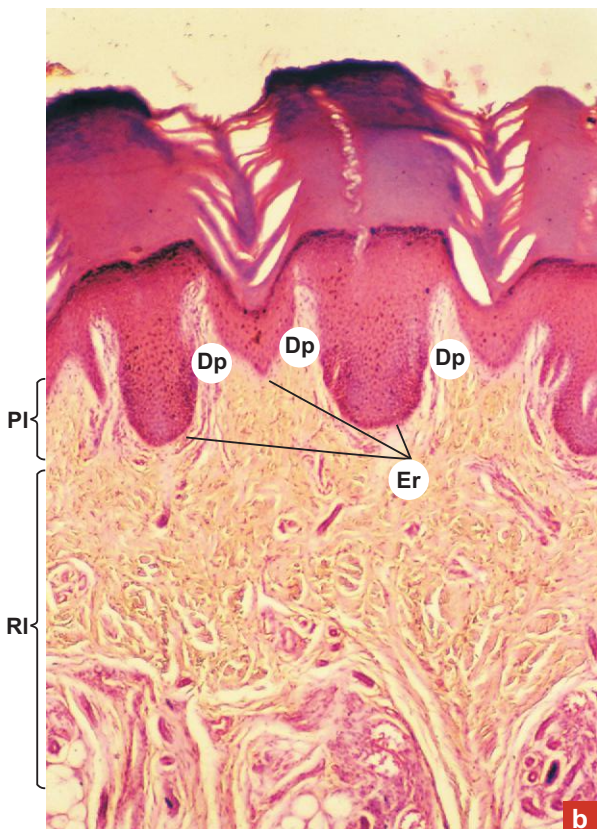
- The thick epidermis (E) made of stratified squamous keratinized epithelium.
- The dermis (D) made of connective tissue.
- The sweat gland (Sg) in the deeper part of dermis.
- The hypodermis (Hd) infiltrated with adipose tissue (At).

Examine the thick skin at low magnification (Plate 11:1b) and note the following features:

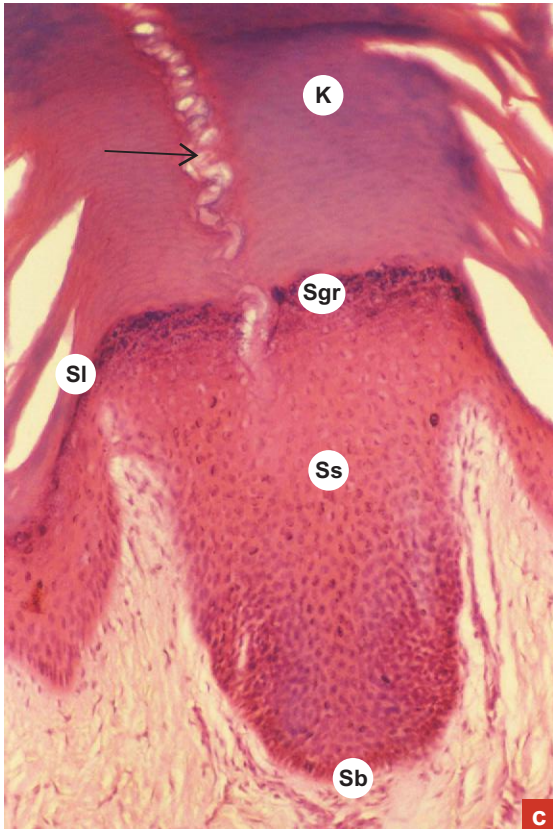
Uneven dermo-epidermal junction due to the presence of interlocking long epidermal ridges (Er) with dermal papillae (Dp).

In the dermis, note the superficial papillary layer (PI), made of loose connective tissue and the deep reticular layer (RI), made of dense connective tissue.

X40



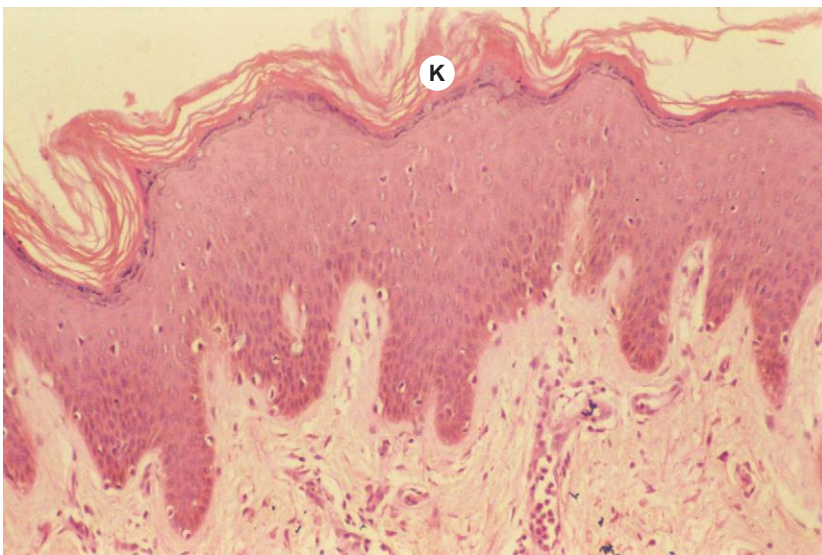
X100

**Plate 11:1c** Thick skin (epidermis).

At a still higher magnification (Plate 11:1c) identify the various layers of the epidermis, from superficial to deep:

- *Stratum corneum* (**K**)—is very thick, made of dead scaly eosinophilic cells.
- A row of empty spaces (**arrow**) may be seen in this layer. They are sections of cork screw-like duct of sweat gland.
- *Stratum lucidum* (**Sl**)—is well developed and appears as a homogeneous transparent layer.
- *Stratum granulosum* (**Sgr**)—made of fusiform cells with keratohyalin granules.
- *Stratum spinosum* (**Ss**)—made of polyhedral cells with spine-like processes at the periphery.
- *Stratum basale* (**Sb**)—made of columnar cells showing mitotic activity, lying on the basement membrane.

X100

**Plate 11:2** Thin skin (epidermis).

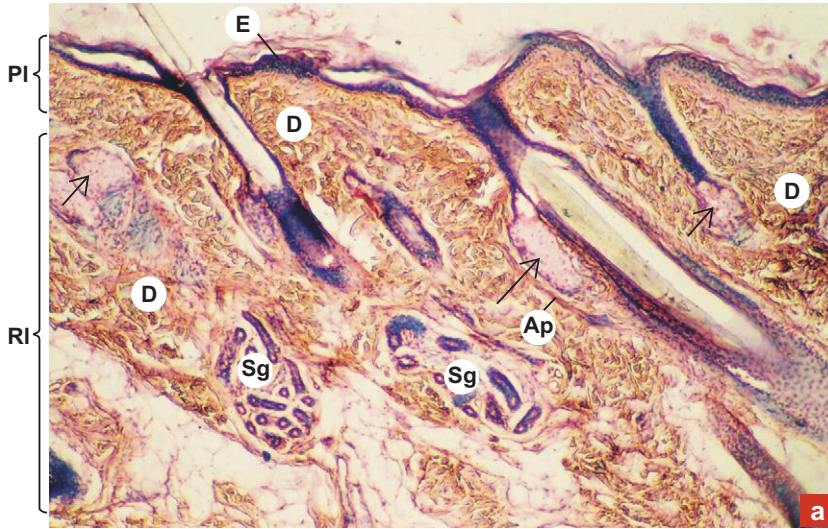Examine the epidermis of thin skin (Plate 11:2) and compare it with that of thick skin (Plate 11:1c).

Note the thin stratum corneum (**K**) and absence of stratum lucidum.

The other layers are also relatively thin.



X40



**Plate 11:3** Thin skin.  
**a and b**

Examine the sections of thin skin under low power (Plate 11:3a and b) and identify the following features:

- Epidermis (E), which is thin and is made of stratified squamous keratinized epithelium. Note the thin layer of stratum corneum.

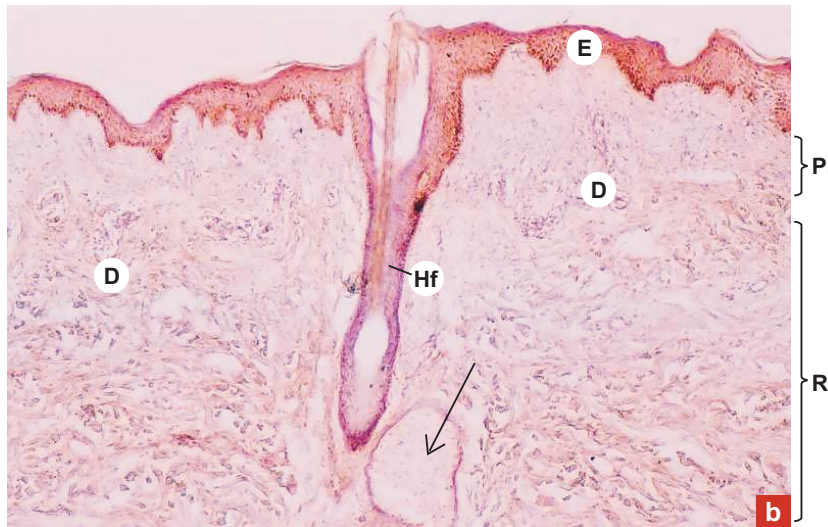
Identify the following structures in dermis (D):

1. Hair follicle (Hf) cut at different planes enclosing the root of hair (**yellow colour**).
2. Sebaceous gland (**arrow**) made of clusters of clear cells connected to a duct that opens into hair follicle.
3. Arrector pili muscle (Ap); a band of smooth muscle extending obliquely from the hair follicle to the papillary layer of the dermis.
4. Sweat gland (Sg) in the deeper part of the dermis.

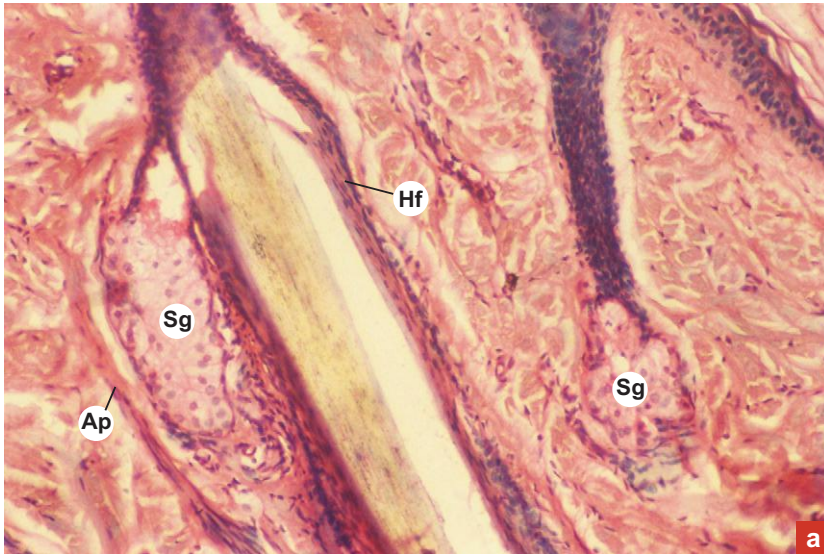
Identify the two layers of dermis:

PI = papillary layer; RI = reticular layer.

X40



X100


**Plate 11:4** L.S. of hair follicle and associated structures.  
**a and b**

Examine a longitudinal section of hair follicle and associated pilosebaceous unit (Plate 11:4a) in the thin skin.

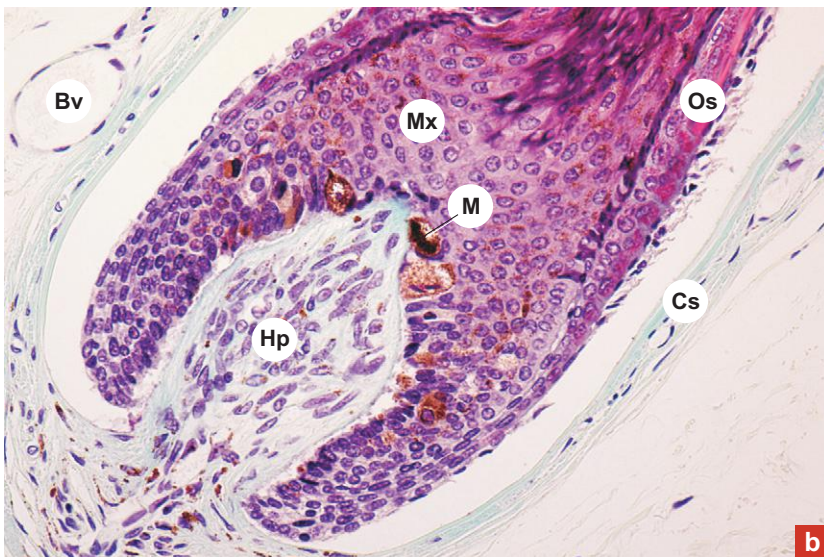
Try to identify the components of pilosebaceous unit:

- Hair follicle (Hf).
- Sebaceous gland (Sg).
- Arrector pili muscle (Ap).

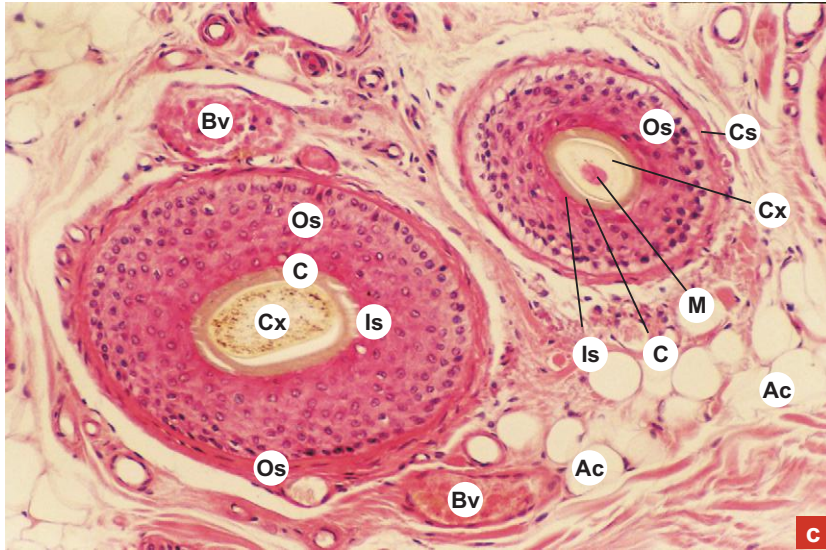
Examine the deeper part of LS of hair follicle under high power (Plate 11:4b) and note the following features:

- Expanded hair bulb made of pluripotent matrix cells (Mx) and melanocytes (M).
- Connective tissue hair papilla (Hp) indenting hair bulb.
- Also note the connecting tissue sheath (Cs) and outer root sheath (Os).

X400



X100



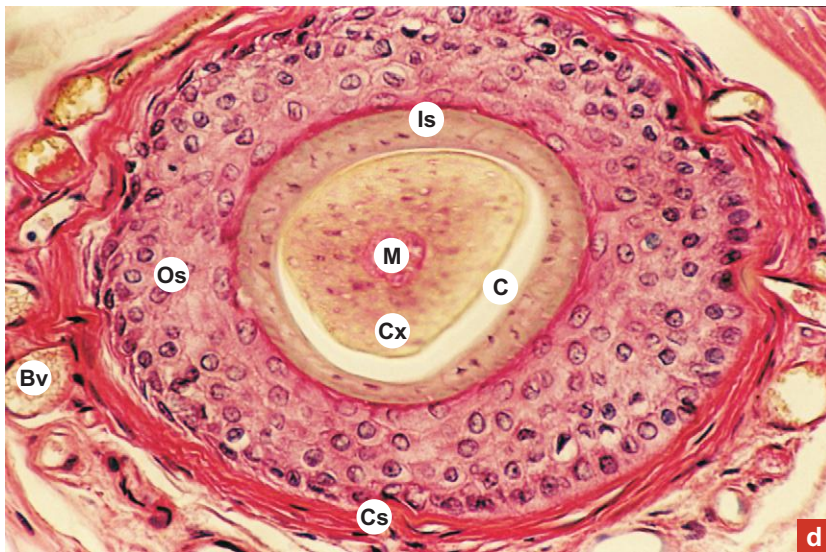
c

**Plate 11:4**  
**c and d**
**C.S. of hair follicle.**

Examine a cross section of hair follicle at low and high magnifications (Plate 11:4c) and (Plate 11:4d) try to identify its layers surrounding the medulla (M), cortex (Cx) and cuticle (c) of hair:

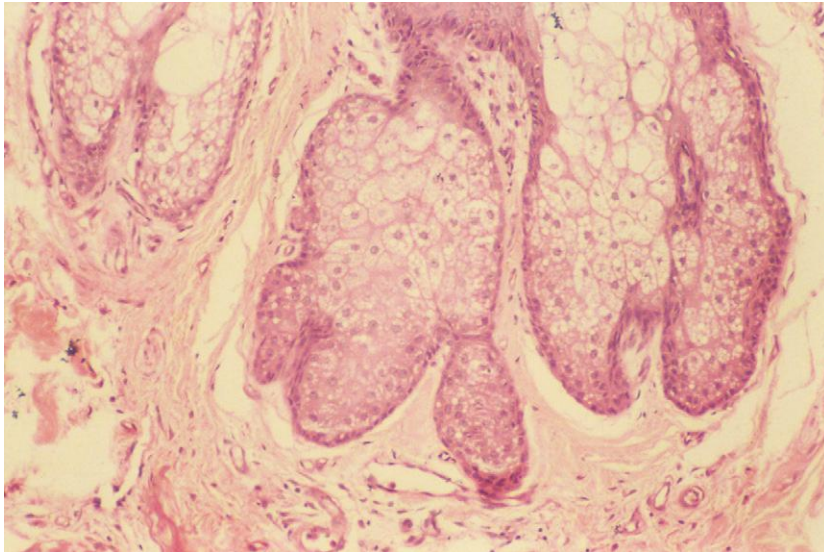
- Connective tissue sheath (Cs).
  - Glassy membrane separating the epithelial sheath from the connective tissue sheath.
  - Outer epithelial sheath (Os).
  - Inner epithelial sheath (Is).
- Bv = blood vessels; Ac = adipocytes.

X200



d

X100

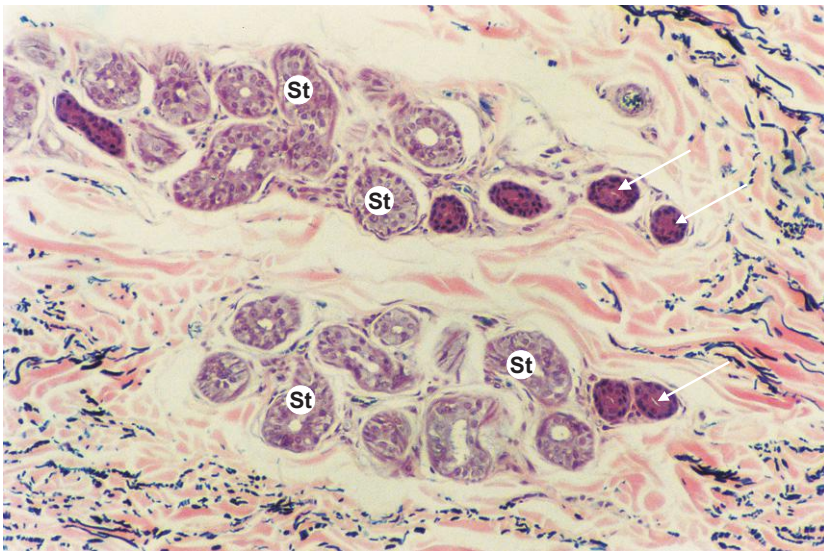


**Plate 11:5** Sebaceous gland.

Examine the sebaceous gland (Plate 11.5).

It is a simple branched acinar gland and also a holocrine gland. Each acinus is composed of a cluster of large vacuolated cells called sebocytes. Note that the cells in the centre are undergoing disintegration.

X100



**Plate 11:6** Sweat gland.

Examine the sweat gland at high/low magnification (Plate 11:6). Its secretory tubules (St) and ducts (arrow) can be differentially identified based on the size, staining intensity and lining epithelium.

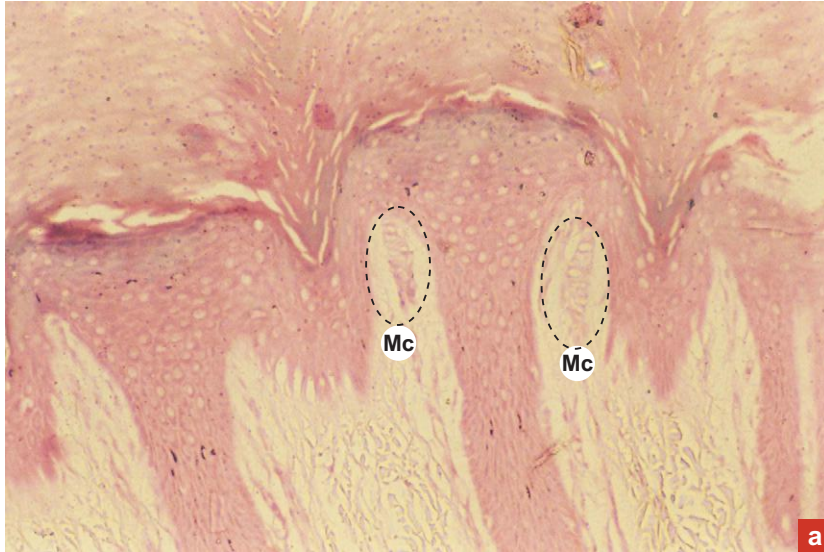**Secretory tubule of sweat gland**

*Larger in diameter  
Lightly stained  
Simple cuboidal epithelial lining*

**Duct of sweat gland**

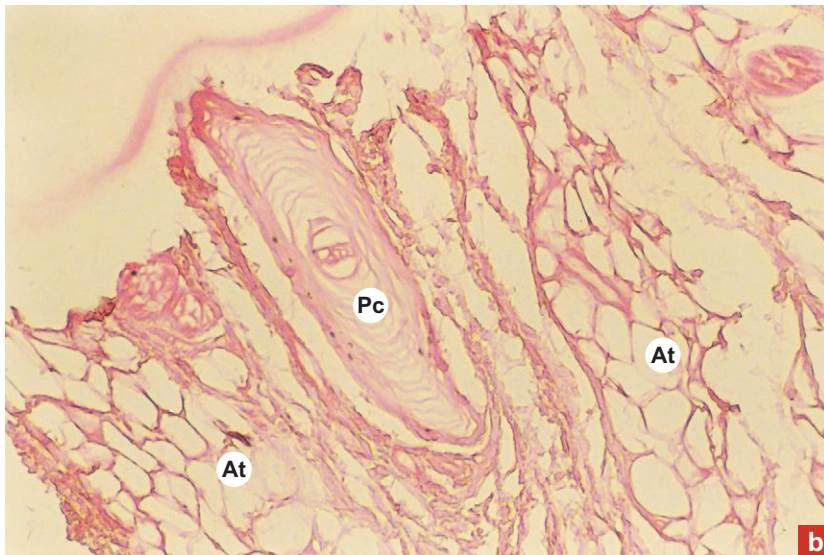
*Smaller in diameter  
Darkly stained  
Stratified cuboidal epithelial lining*

X100

**Plate 11:7a** Meissner's corpuscle.

- Look for Meissner's corpuscle (Mc) in the dermal papilla of thick skin (Plate 11:7a) under high power. This corpuscle is an encapsulated receptor, cylindrical in shape and vertically placed. It is made of stack of flat modified Schwann cells.

X100

**Plate 11:7b** Pacinian corpuscle.

- In the deeper part of dermis, look for Pacinian corpuscle (Pc), (Plate 11:7b). This corpuscle is also an encapsulated receptor, appears like a sliced onion. Note the adipose tissue (At) around it.

# 12

# DIGESTIVE SYSTEM

## INTRODUCTION

The digestive system consists of oral cavity and a hollow tubular gastrointestinal tract (GIT) plus digestive glands associated with it. The main function of the digestive system is to digest the ingested food and absorb the nutrients.

## ORAL CAVITY

### GENERAL FEATURES

- The oral cavity is the first part of the digestive system where the food is broken into small pieces by teeth, moistened and lubricated by saliva. Saliva is secreted by three pairs of major salivary glands and minor salivary glands present in the oral mucosa. The digestive enzyme, amylase, present in the saliva initiates carbohydrate digestion in the oral cavity. The saliva has got bactericidal action also.
- The oral cavity consists of two parts, namely, the *vestibule* and the *oral cavity proper*. The vestibule is a slit like space bounded by lips and cheeks externally and gingivae (gums) and teeth internally. The oral cavity proper is the large space limited anteriorly and laterally by the dental arches and superiorly by the palate. It contains the tongue which arises from the floor.
- The oral cavity is lined by moist oral mucous membrane or *oral mucosa* which is continuous with the dry skin at the mucocutaneous junction of the lips.

### STRUCTURE OF ORAL MUCOSA

- The oral mucosa is made of covering epithelium (stratified squamous epithelium) and the underlying connective tissue (lamina propria). It has no muscularis mucosa.
- The deeper part of the lamina propria that contains major blood vessels, adipose and glandular tissues is often referred to as submucosa.
- This submucosa contains minor salivary glands which are named according to the region they are found in, e.g. *labial glands* in the lip, *buccal glands* in the cheek, *palatine glands* in the palate and *lingual glands* in the tongue.
- Sebaceous glands are occasionally seen in the lamina propria of oral mucosa. They appear as pale yellow spots called *Fordyce's spots*. Presence of sebaceous glands in the oral mucosa may be due to retention of parts of skin ectoderm when oral ectoderm invaginates to form the lining of oral cavity.
- The oral mucosa shows considerable structural variation in different regions of the oral cavity. Based on the function, it can be divided into three main types, namely, masticatory mucosa, lining mucosa and specialized mucosa.

### *Masticatory Mucosa*

- Masticatory mucosa covers those areas of oral cavity that are subjected to mechanical trauma during mastication of food, e.g. gingiva and mucosa over hard palate.
- It is firm and immobile and attached to the periosteum of the underlying bone forming *mucoperiosteum*.
- The stratified squamous epithelium of masticatory mucosa is moderately thick and frequently *parakeratinized* (parakeratinization is otherwise called incomplete keratinization, where the superficial partly keratinized cells retain their shrunken

pyknotic nuclei and other remnants of organelles, refer to Plate 2.II:1b). Its basal surface is indented by deep connective tissue papillae.

- The firmness of masticatory mucosa ensures that it does not gape after surgical incisions and rarely requires suturing. For the same reason, injection of local anaesthetics into these areas are difficult, often painful as is any swelling arising from inflammation.

### Lining Mucosa

- Lining mucosa is soft and pliable. It covers the inner surface of lips, cheeks, soft palate, floor of the mouth and ventral surface of tongue.
- The epithelium of lining mucosa is thicker than that of masticatory mucosa and is nonkeratinized. Its basal surface is largely smooth and occasionally indented with slender connective tissue papillae.
- The lamina propria is thick, made up of irregularly arranged collagen and elastic fibres. The submucosa is also thick containing glandular tissue. The elastic fibres in the lamina propria tend to restore the mucosa to its resting position after being stretched, except over the undersurface of the tongue where the mucosa is firmly bound to the underlying muscle.
- Since the mucosa is soft and flexible, surgical incisions gape and frequently require sutures for closure. Injection into this region is easy because dispersion of fluid occurs readily in the loose connective tissue; similarly infection also spreads rapidly.

### Specialized Mucosa

- Specialized mucosa is found on the dorsum of the tongue. Though it is functionally a masticatory mucosa, it has been classified as specialized mucosa because of the presence of taste buds in it. The detailed description of this mucosa is described under 'tongue' (*vide infra*).  
The main structures present in the oral cavity are the lips, gingiva, teeth and tongue.

## LIPS

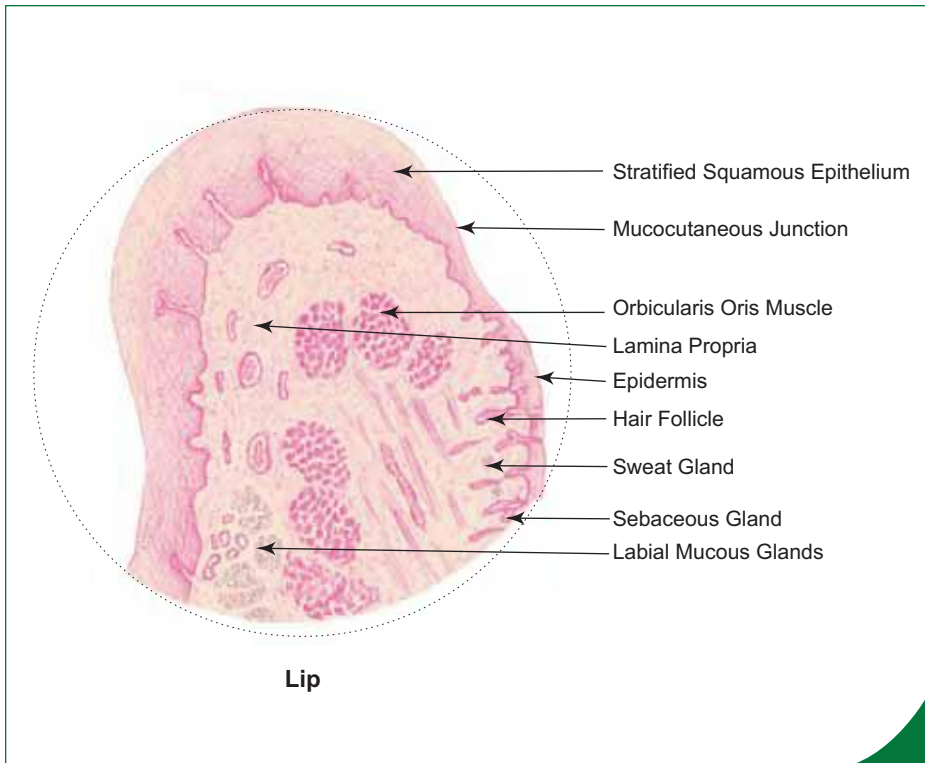
- The upper and lower lips are fleshy mucocutaneous flaps forming the boundaries of the oral fissure.
- Each lip is covered externally by dry hairy skin and internally by wet mucous membrane, enclosing in the middle, circularly arranged skeletal muscle, orbicularis oris.
- Oral orifice is one of the regions of the *mucocutaneous junctions* of the body where the skin becomes continuous with the mucous membrane. This junction shows a transition of keratinized epidermis of skin to nonkeratinized epithelium of labial mucosa. This transitory zone is called *red line* or *vermilion border* of the lip.
- The labial epithelium is very thick and indented by deep vascular papillae of lamina propria.
- The submucosa (deeper part of lamina propria) contains large labial glands (predominantly mucous) (Box 12.1).

## GINGIVA

- Gingiva is formed of masticatory oral mucosa located around the neck of the tooth and is commonly called gum. It is paler than the alveolar mucosa.
- The gingiva may be divided into two parts, namely, *free gingiva* that forms a cuff around the neck of the tooth and *attached gingiva* which attaches it with the underlying alveolar bone.
- Between the free gingiva and the enamel of neck of tooth, there is a potential space called *gingival sulcus* or gingival crevice. Its depth varies from 0.5–3.0 mm with an average of 1.8 mm. The floor of the sulcus is usually found attached to the enamel of the crown and with age it may be shifted to the cemento-enamel junction or to the cementum.
- The oral aspect of the gingiva is lined by a thick stratified squamous *oral gingival epithelium*, which becomes continuous with *sulcular epithelium* at the free gingival margin (*gingival crest*).
- The sulcular epithelium is thin and it lacks epithelial ridges and so forms a smooth interface with lamina propria.

**Box 12.1 Lip.***Presence of*

- (i) C.S. of skeletal muscle (orbicularis oris) in the centre;
- (ii) thick stratified squamous nonkeratinized epithelium on the internal surface;
- (iii) thin skin on the external surface.



- The sulcular epithelium is easily breached by pathogenic organisms and so the underlying lamina propria is frequently infiltrated by lymphocytes and plasma cells.
- At the bottom of the sulcus, the sulcular epithelium is continuous with the *junctional epithelium*, which is attached to the enamel of the tooth by an extracellular attaching substance (*internal basal lamina*) secreted by it (Fig. 12.1).

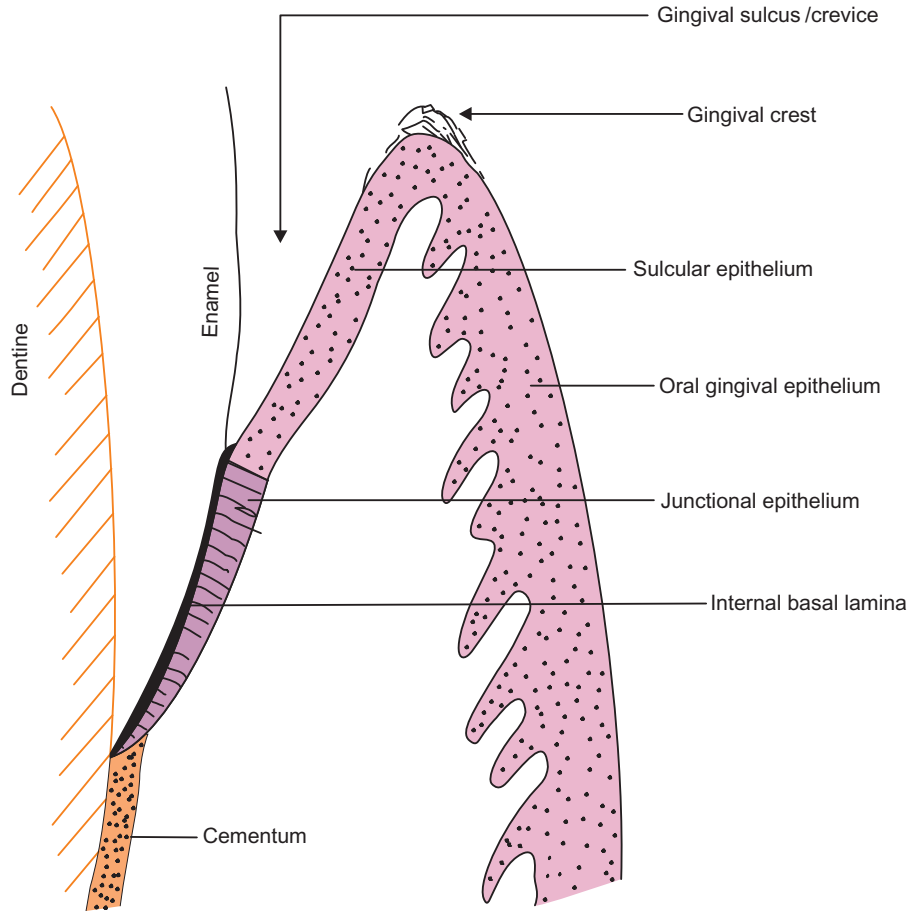
**TEETH**

- The ingested food is masticated (chewed) by the teeth, which are anchored to the sockets of the alveolar processes of maxilla and mandible. The alveolar processes are covered by gingiva or gum, which is firmly bound to their periosteum.
- In human beings there are two sets of teeth, namely,
  1. The deciduous or milk teeth (10 in each jaw)—later replaced by permanent teeth.
  2. The permanent teeth (16 in each jaw).
- Teeth of both sets have similar histological structure.

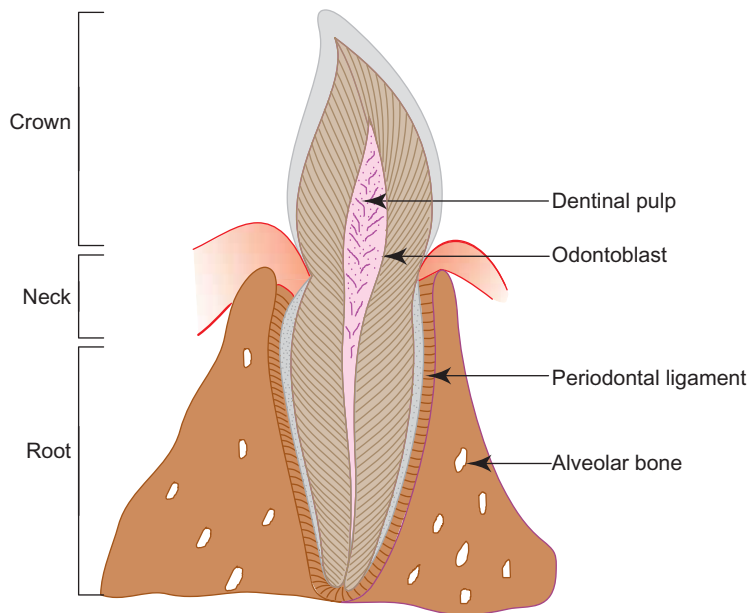
**HISTOLOGICAL STRUCTURE OF A TOOTH**

- The parts of a typical tooth (Fig. 12.2) are:
  1. *Crown*—the visible part of tooth above the gum.
  2. *Root*—the concealed part of tooth anchored to socket by periodontal ligament. It has an apical foramen at the tip.
  3. *Neck*—the constricted part at the junction of the crown and root near the gum line.
  4. *Pulp cavity* and *root canal*—found in the interior filled with dentinal pulp.
- The tooth is made of the following types of tissues:
  1. *Hard tissues*—which include dentine, enamel and cementum.
  2. *Soft tissues*—which include dentinal pulp and periodontal ligament.





**Fig. 12.1** Dentogingival junction.

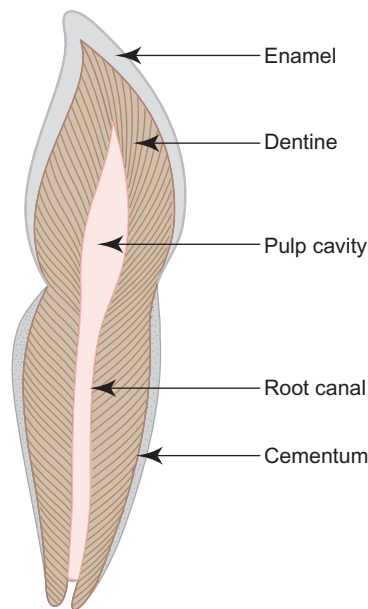


**Fig. 12.2** L.S. of tooth in situ.

## Hard Tissues (Box 12.2; Fig. 12.3)

### Dentine

- This tissue forms the main bulk of the tooth surrounding the pulp cavity and the root canal, in the crown and root respectively.
- It is composed of organic (20%) and inorganic (80%) components similar to bone.
- Dentine is formed by *odontoblasts* that line the pulp cavity. (Formation of dentine is a continuous but slow process occurring throughout life.) These cells are mesodermal in origin (Box 12.3).
- It is characterised by the presence of dentinal tubules radiating from the pulp cavity containing the processes of odontoblasts in the living.



**Fig. 12.3** L.S. of tooth.

### Enamel

- It is the hardest substance in the body.
- It is composed of 99.5% inorganic salts.
- Enamel covers the dentine of crown.
- It is formed by *ameloblasts* that disappear after the tooth has erupted (so no capacity for regeneration). These cells are ectodermal in origin (Box 12.3).
- This tissue is characterised by the presence of enamel rods or prisms that radiate from dentino-enamel junction towards the surface.

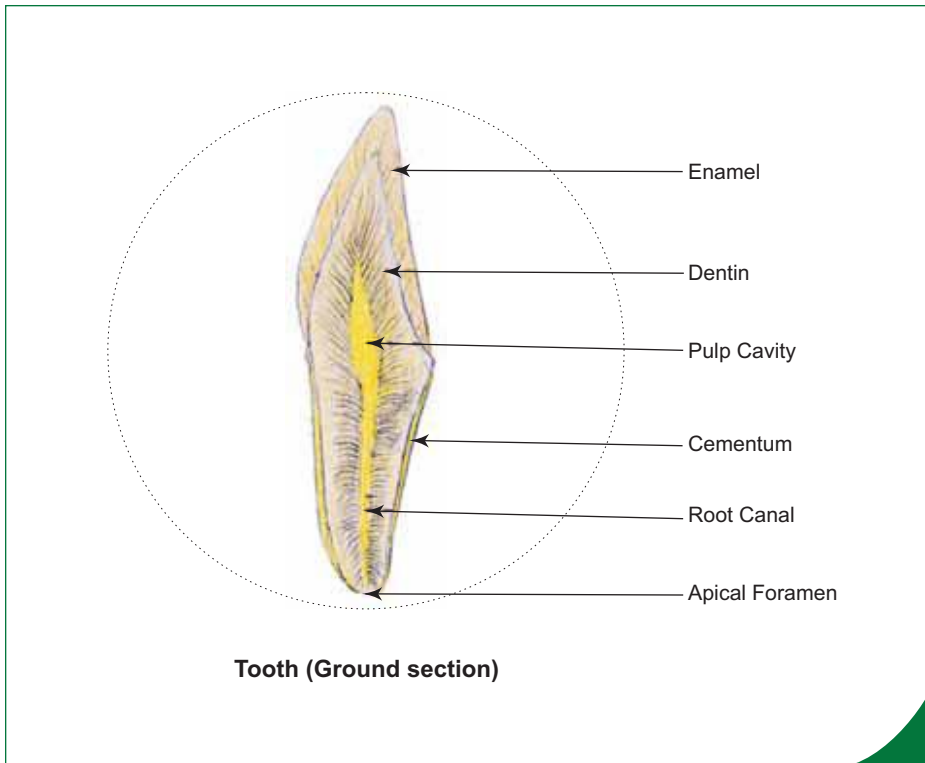
### Cementum

- It covers the dentine of the root.
- Structurally cementum is similar to the bone.
- It is secreted by *cementoblasts* which later become cementocytes once cementoblasts are surrounded by their own secretion and found in lacunae.
- Cementum is laid continuously throughout life.

**Box 12.2** Tooth (Ground Section).

Presence of

- (i) **pulp cavity** surrounded by dentin;
- (ii) **enamel** over the crown and **cementum** over the root.

**Soft Tissues (Figs 12.2 and 12.3)****Dentinal Pulp**

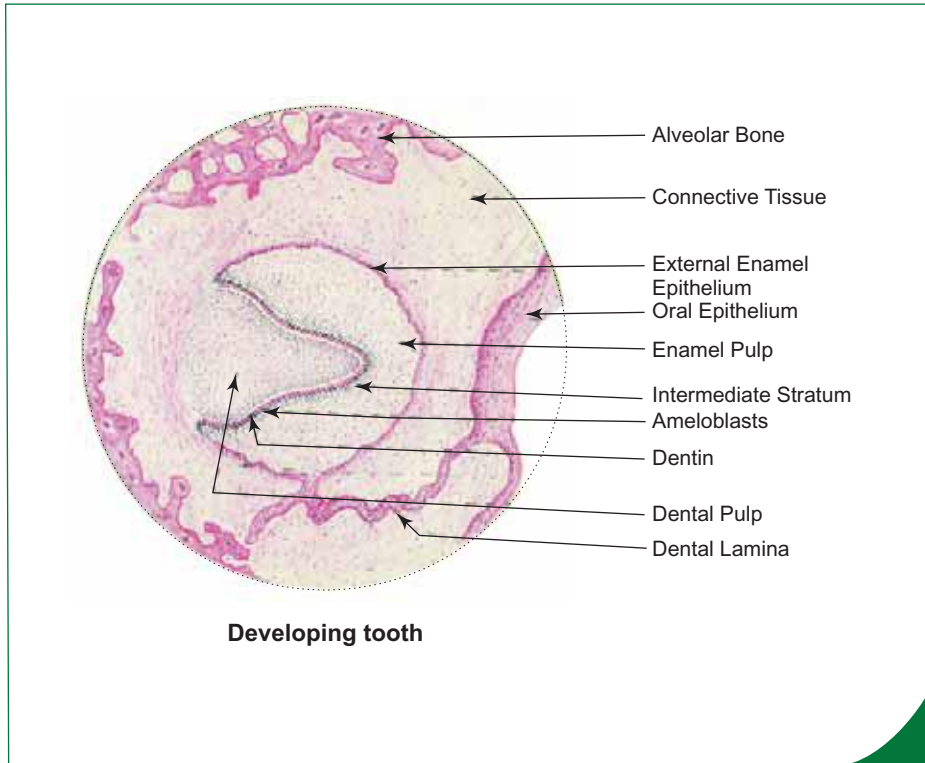
- It is present in the pulp cavity and root canal.
- The pulp is made of loose areolar connective tissue containing neurovascular structures which enter the pulp cavity through the *apical foramen* present at the tip of the root.
- It is covered externally by a layer of odontoblasts which are responsible for the deposition and maintenance of dentine.

**Periodontal Ligament**

- The ligament fixes the root of tooth to alveolar socket.
- It is composed of dense fibrous connective tissue whose fibres are arranged in such a way as to avoid transmission of pressure directly to the bone during mastication.

**TONGUE**

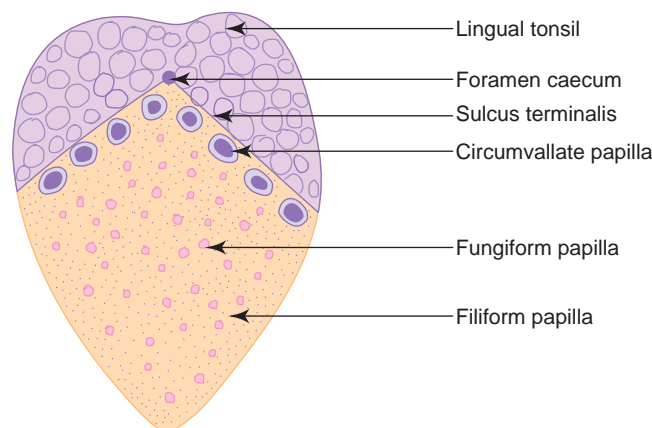
- Tongue is a muscular organ made of skeletal muscle (intrinsic and extrinsic muscles of tongue) covered by mucous membrane.
- The mucous membrane consists of stratified squamous epithelial lining which may show keratinization at places (especially at the tips of filiform papillae) and the underlying lamina propria.
- The lamina propria contains lingual glands which are of three types, namely,
  1. Anterior lingual glands (mixed seromucous)—at the tip.
  2. von Ebner's glands (serous)—related to vallate and foliate papillae.
  3. Posterior lingual glands (mucous)—related to lingual tonsil, ducts open in central crypt, so chance of tonsillitis is nil.


**Box 12.3** Developing Tooth.

Presence of

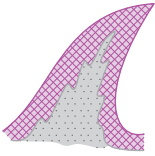
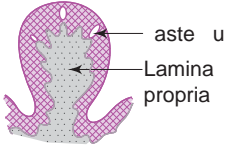
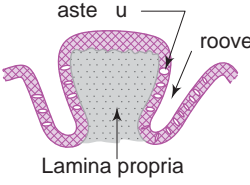
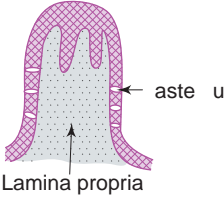
- (i) enamel organ having an outer enamel epithelium and an inner enamel epithelium (**ameloblasts**);
- (ii) **odontoblasts** differentiated from cells of dental pulp;
- (iii) **enamel** and **dentin** formation.

- Mucous membrane over the dorsal surface of tongue is rough due to the presence of lingual papillae and lingual tonsils; whereas the ventral surface is smooth and slippery.
- The dorsal surface is divided into two parts by a 'V' shaped sulcus terminalis. The anterior two-third is the oral part and the posterior one-third is the pharyngeal part of tongue (Fig. 12.4).
- The oral part of tongue is provided with lingual papillae (projection of mucous membrane), whereas the pharyngeal part shows many rounded elevations called lingual tonsils due to the presence of lymphatic nodules in lamina propria.
- The lingual papillae are of four types (based on shape; Table 12.1; Box 12.4 a–c):
  1. Filiform
  2. Fungiform
  3. Circumvallate
  4. Foliate (rudimentary in human beings)



**Fig. 12.4** Tongue: dorsal surface.

**Table 12.1** Characteristic features of the different types of lingual papillae

	Filiform	Fungiform	Circumvallate	Foliate
Diagram				
Distribution	Anterior two-thirds (numerous at the tip)	Anterior two-thirds (among filiform)	In front of and parallel to the sulcus terminalis	Posterior part of lateral margin (rudimentary in man but well developed in rodents)
Shape	Conical (with tip pointing towards pharynx)	Knob-like with rounded top (like a mushroom)	Inverted truncated cone with a flat top (surrounded by a circular sulcus)	Cylindrical
Secondary connective tissue papillae	On all surfaces	On all surfaces	Only on the top	Mainly on the top
Taste buds	Absent	Few on the top	Many on the lateral surface	Many on the lateral surface
Glandular association	Absent	Present (serous)	Present (serous – von Ebner's gland)	Present (serous)

## TASTE BUDS

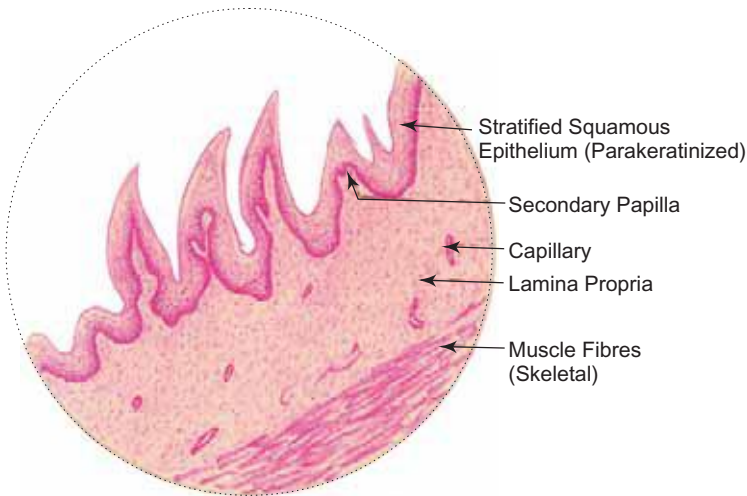
- These buds are present in the epithelium of fungiform, circumvallate and foliate papillae of tongue. They are also present in the epiglottis, soft palate and oropharynx.
- In section, taste buds appear as oval pale staining bodies embedded within the full thickness of the stratified squamous epithelium of the papillae extending from basement membrane to surface.
- They are mainly made of elongated spindle-shaped cells arranged perpendicular to the surface of the epithelium.
- The apical free ends of these cells converge on a small opening on the surface of the epithelium called *taste pore*. The free ends bear microvilli (*taste hairs*) that protrude through the taste pore (Fig. 12.5; Box 12.5).
- There are three types of cells present in the taste bud, *viz.*,
  1. **Taste or gustatory cells (Type II cells)**
    - Lightly stained elongated cells having microvilli at the apical ends.
    - Unmyelinated nerve fibres are associated with these cells.
  2. **Sustentacular or supportive cells (Type I cells)**
    - Darkly stained elongated cells having microvilli at the apical ends.
    - Also associated with unmyelinated nerve fibres.
    - Support the taste cells and also secrete a dense amorphous substance.
  3. **Basal cells or stem cells**
    - Small pyramidal cells lying close to the basement membrane.
    - Do not reach the taste pore.
    - Give rise to taste and sustentacular cells.

The four basic taste sensations are acid, bitter, sweet and saline. Each of them can be perceived maximum at certain regions of the tongue. For example, sweet at the tip, saline at the margin, sour over the dorsum and bitter over the posterior part of the tongue. However, there is no structural differences in the taste buds for various sensations.

**Box 12.4a–b** Tongue:  
(a) Filiform Papilla,  
and (b) Fungiform Papilla.

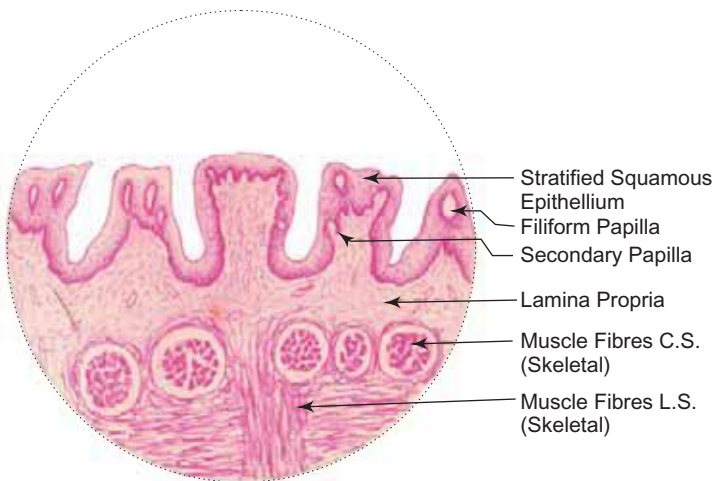
Presence of

- (i) conical **filiform papillae** (no taste buds) and;
- (ii) mushroom shaped **fungiform papillae** covered with;
- (iii) **stratified squamous epithelium**;
- (iv) **skeletal muscle** running in different directions.



(a)

**Tongue: Filiform papillae**



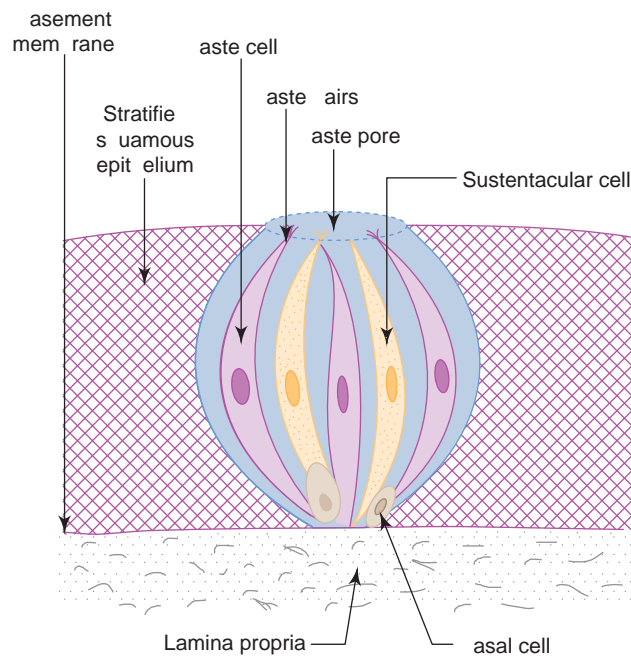
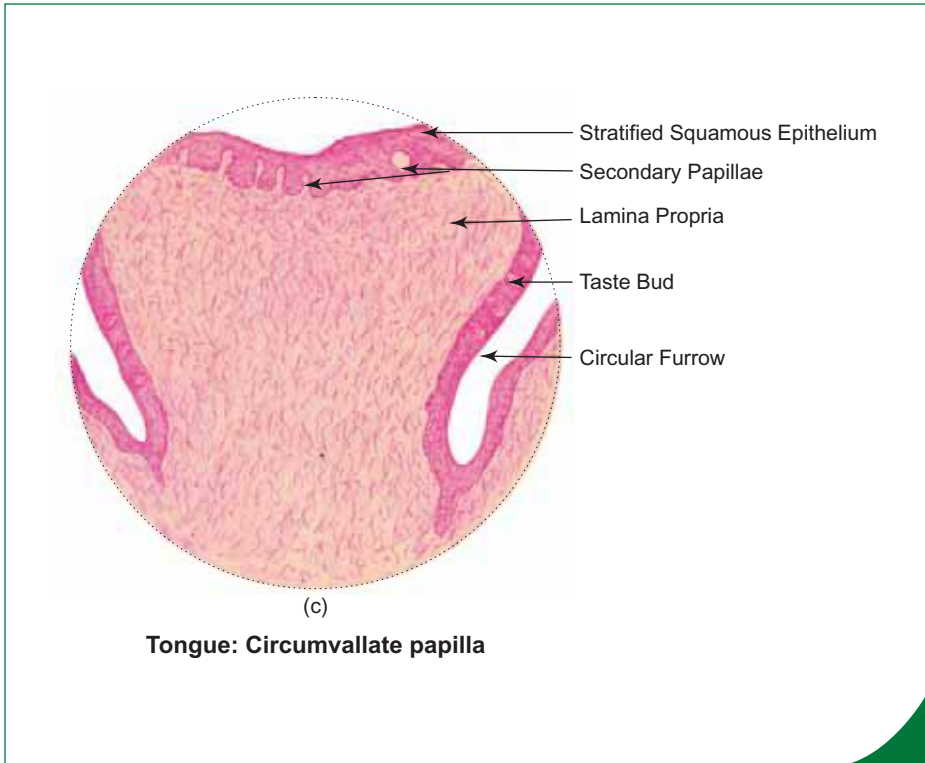
(b)

**Tongue: Fungiform papillae**

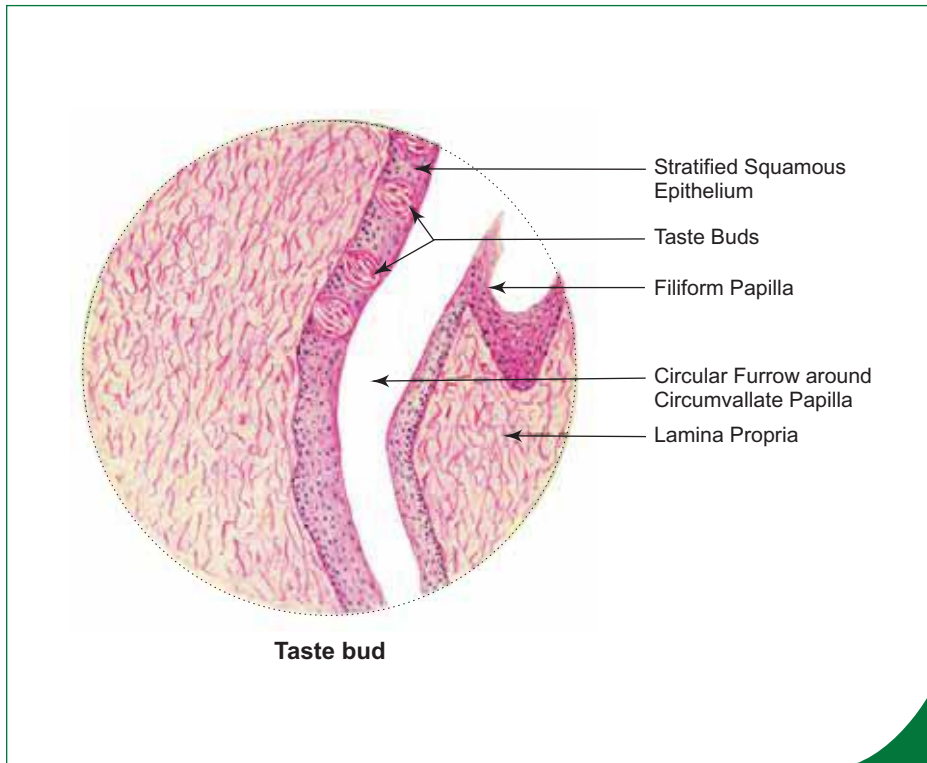
**Box 12.4c** Tongue: Circumvallate Papilla.

Presence of

- (i) sunken inverted cone shaped papilla with a flat top lined by;
- (ii) **stratified squamous epithelium**;
- (iii) numerous **taste buds** on the lateral wall of the papilla;
- (iv) **deep trench** around the papilla;
- (v) **von Ebner's glands** (serous);
- (vi) **skeletal muscle** running in different directions.



**Fig. 12.5** Schematic diagram of taste bud.

**Box 12.5 Taste Bud.**

Presence of

- (i) lightly stained oval bodies (taste buds) embedded in **stratified squamous epithelium**;
- (ii) spindle shaped **gustatory** and **sustentacular cells**;
- (iii) **taste pores**.

## GASTROINTESTINAL TRACT (GIT)

### GENERAL PLAN OF GASTROINTESTINAL TRACT

- The general structure of gastrointestinal tract (GIT) starting from oesophagus to anal canal is more or less same except for regional variations in the mucosal coat.
- The GIT shows four distinct coats, from inner to outer (Fig. 12.6). They are:

#### 1. Mucosa

- It is composed of the following three layers:
  - (a) *Epithelium*.
  - (b) *Lamina propria* – made of connective tissue containing glands and lymphoid accumulations.
  - (c) *Muscularis mucosa* – made of smooth muscle fibres; arranged in two layers, the inner circular and the outer longitudinal. This layer is responsible for movement and folding of mucosa.

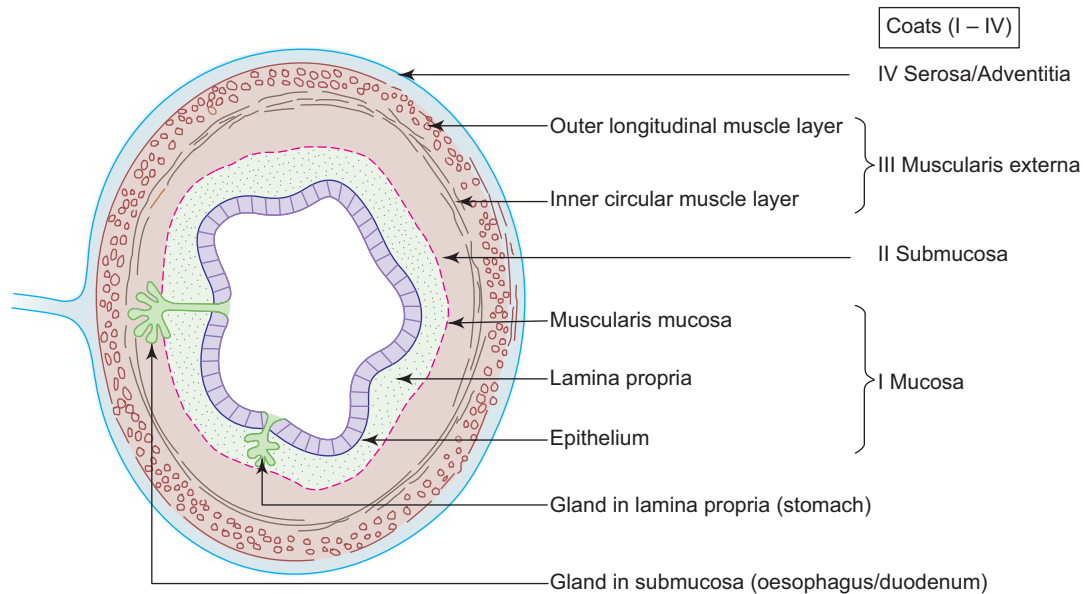
#### 2. Submucosa

- Consists of fibroelastic connective tissue.
- Contains Meissner's nerve plexus.
- May contain glands (oesophagus and duodenum).

#### 3. Muscularis externa

- Composed of two layers of smooth muscle, the inner circular and the outer longitudinal. Muscularis externa is responsible for peristaltic contractions. In the oesophagus skeletal muscle is present in the upper part.
- Contains Auerbach's nerve plexus (myenteric) and parasympathetic ganglia between the two layers of muscle.





**Fig. 12.6** General plan of gastrointestinal tract (GIT).

#### 4. Adventitia/Serosa

- Adventitia consists of only loose connective tissue without peritoneum.
- Serosa consists of peritoneum (mesothelial lining) over a layer of loose connective tissue.

## OESOPHAGUS

### GENERAL FEATURES

- Oesophagus is a long (25 cm) muscular tube extending from pharynx to stomach.
- It conducts chewed food (bolus) and liquids to stomach.

### STRUCTURE (BOX 12.6)

- Oesophagus is composed of four basic coats. From inner to outer they are:

#### 1. Mucosa

- It is composed of the following three layers:
  - (a) *Epithelium* – stratified squamous nonkeratinized.
  - (b) *Lamina propria* – contains oesophageal cardiac glands in the lower part of oesophagus.
  - (c) *Muscularis mucosa* – is made of single longitudinal layer of smooth muscle. (No circular layer.)

#### 2. Submucosa

- It contains oesophageal glands (mucous).

#### 3. Muscularis externa

- It is made of muscles of following types; arranged into inner circular and outer longitudinal layers:
  - Upper one-third of oesophagus – only skeletal muscle.
  - Middle one-third of oesophagus – both skeletal and smooth muscle.
  - Lower one-third of oesophagus – only smooth muscle.

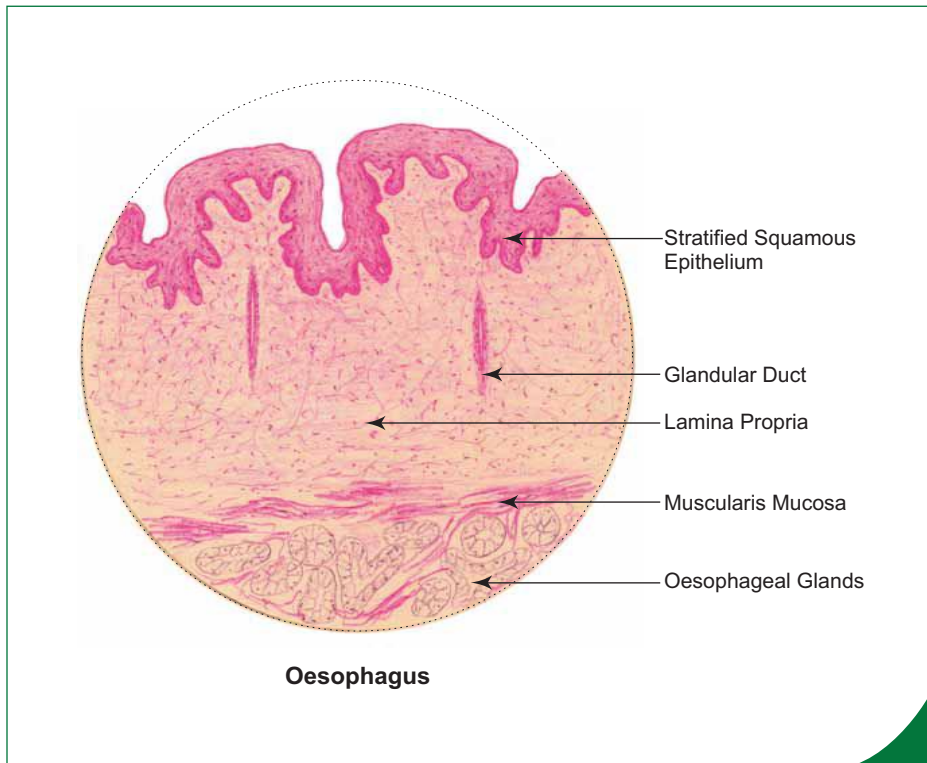
#### 4. Adventitia

- It is same as the general plan of GIT.

**Box 12.6 Oesophagus.**

Presence of

- (i) **stratified squamous epithelium;**
- (ii) **oesophageal glands** (mucous) in the submucosa;
- (iii) thick muscularis mucosa;
- (iv) muscularis externa
  - skeletal muscle in upper one-third;
  - skeletal and smooth muscles in middle one-third;
  - smooth muscle in lower one-third.



## STOMACH

### GENERAL FEATURES

- Stomach is a muscular bag that receives food bolus from oesophagus.
- It acidifies and converts the ingested food into a thick viscous pulp called *chyme*.
- It also absorbs water, salts, alcohol and certain drugs.
- Mucosa shows longitudinal folds called *rugae* which disappear when stomach is expanded.
- Mucosa also shows tiny grooves which appear as invaginations called *gastric pits* or *foveolae gastricae*.
- All the glands of the stomach open into the bottom of the gastric pits.
- Anatomically, stomach is divided into four parts, namely, cardia, fundus, body and pylorus (Fig. 12.7). However, histologically it is divided into three parts only because the fundus and body share common histological features.

### STRUCTURE

- Stomach has from inner to outer, the following four layers:

#### 1. Mucosa (Fig. 12.8)

- It is made of the following three layers:
  - (a) *Epithelium* – simple tall columnar epithelium, which secretes mucus that lubricates and protects the epithelial surface from the acid content of chyme. The epithelium shows invaginations called gastric pits. The epithelial cells are renewed about every three days.
  - (b) *Lamina propria* – contains gastric glands (cardiac/fundic/pyloric glands; Box 12.7).
  - (c) *Muscularis mucosa* – made of two layers of smooth muscle as in the general plan of GIT. Smooth muscle fibres extend into lamina propria between gastric glands.

#### 2. Submucosa

- It is same as the general plan of GIT.

3. Muscularis externa

- It is composed of three layers of smooth muscle, viz.,
  - Inner oblique
  - Middle circular
  - Outer longitudinal

4. Serosa

- It is same as general plan of GIT.

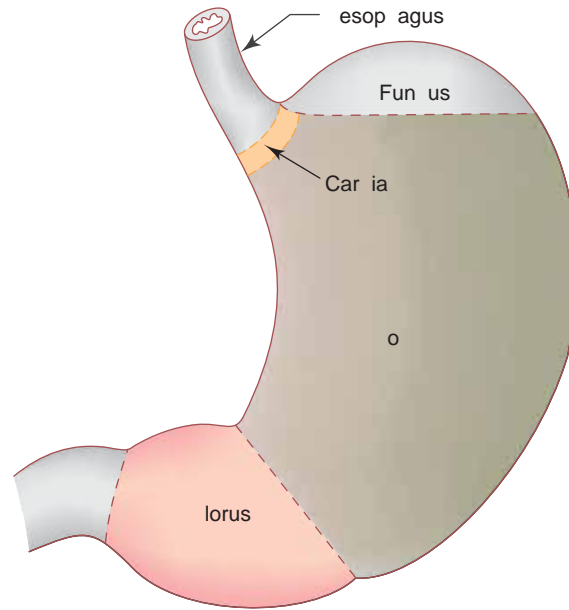


Fig. 12.7 Parts of stomach.

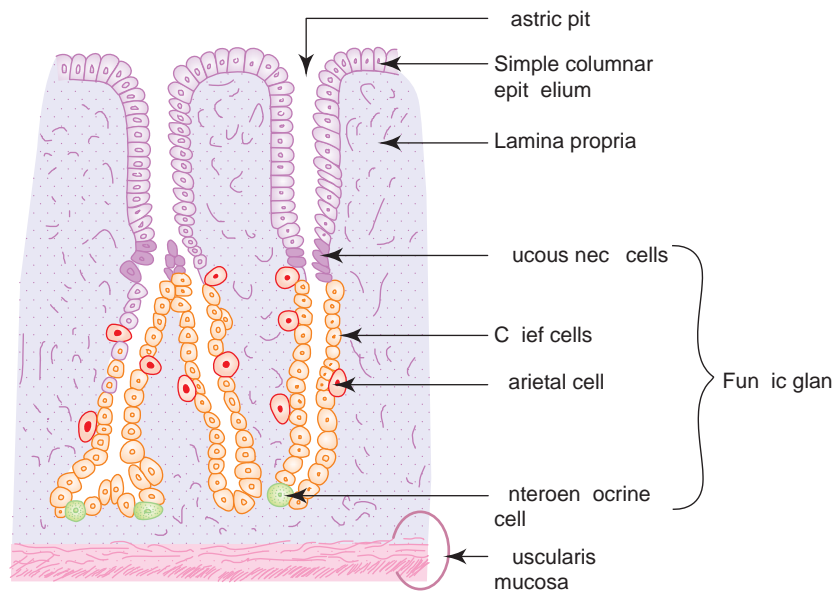
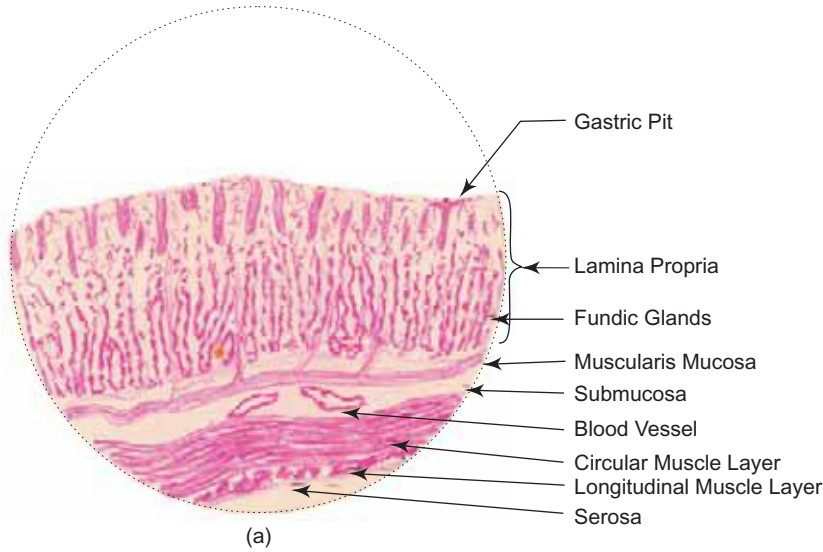
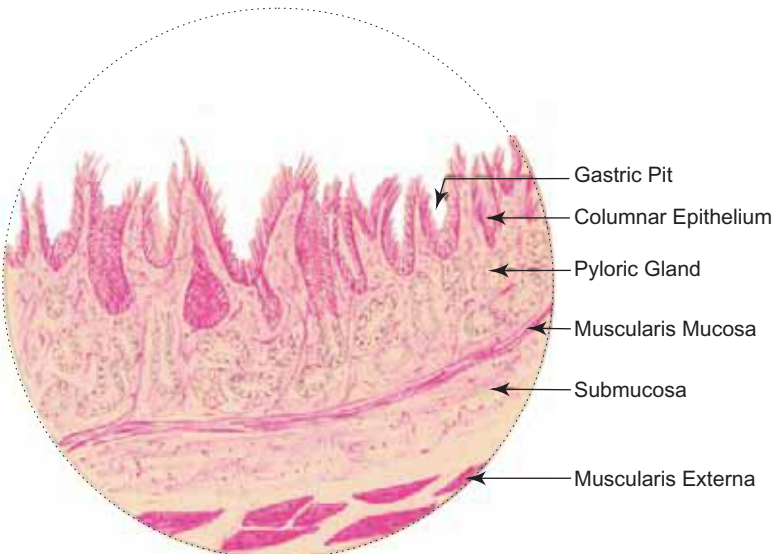


Fig. 12.8 Mucous membrane of stomach (fundus and body).

**Box 12.7** Stomach: (a) Fundus, and (b) Pylorus.



(a)  
**Stomach: Fundus**



(b)  
**Stomach: Pylorus**

(a) Fundus: *Presence of*

- (i) **shallow gastric pits** lined by **simple columnar epithelium**;
- (ii) long tubular **fundic glands** in the lamina propria;
- (iii) **chief** and **parietal cells** in the fundic gland;
- (iv) muscularis externa showing 3 layers of smooth muscle (inner oblique, middle circular, outer longitudinal).

(b) Pylorus: *Presence of*

- (i) **deep gastric pits** lined by **simple columnar epithelium**;
- (ii) **pyloric glands** (mucous) in the lamina propria;
- (iii) pyloric sphincter (thickened middle circular layer of smooth muscle).

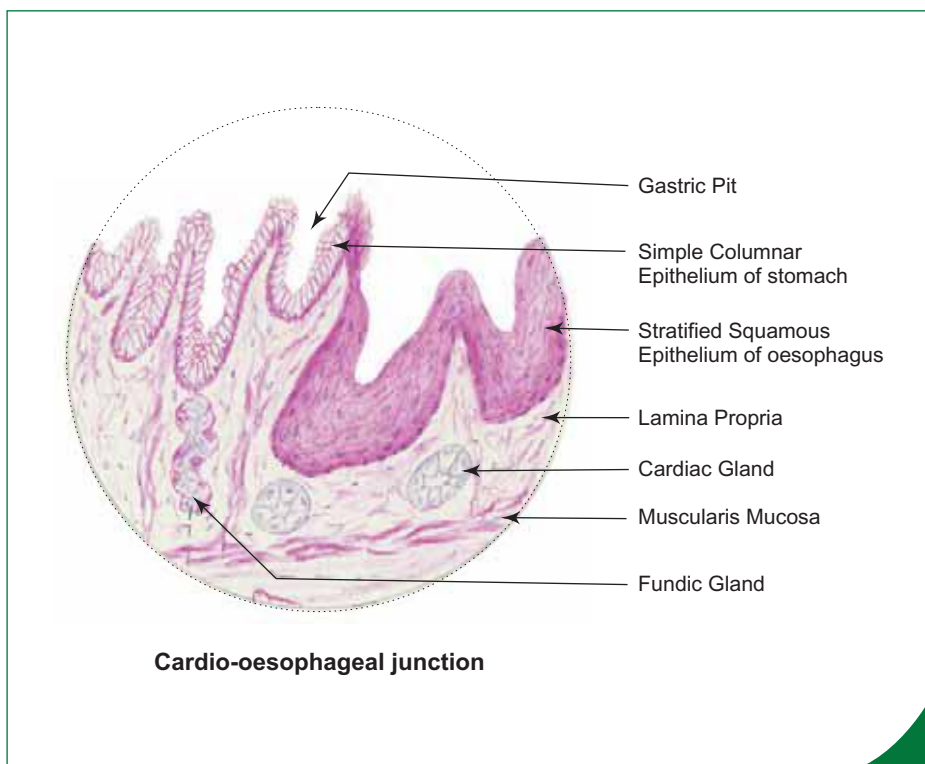
## SALIENT FEATURES OF EACH REGION OF STOMACH

### Cardia

- A change of epithelium from stratified squamous in the oesophagus to simple columnar epithelium in stomach (Box 12.8).
- Presence of *cardiac glands* (mucous) in the lamina propria.
- Presence of shallow gastric pits.

### Fundus and Body (Fig. 12.8)

- Presence of *shallow gastric pits* lined by simple columnar epithelium. The pits form one-fourth of the thickness of mucosa.
- Presence of simple branched tubular *fundic glands* in the lamina propria.
- The fundic glands contain the following cell types:
  1. **Mucous neck cells**
    - Low columnar cells in the neck region of the gland secreting *acid mucus*.
  2. **Parietal or oxyntic cells**
    - Large pyramidal cells found in the upper half of the gland.
    - They can be easily identified by the presence of acidophilic cytoplasm and are attached to the periphery of the gland.
    - These cells secrete *hydrochloric acid* and a *gastric intrinsic factor* necessary for absorption of vitamin B<sub>12</sub> in the ileum which is essential for erythropoiesis.
  3. **Chief or zymogenic cells**
    - Small cuboidal cells bordering the glandular lumen, found mainly in the deeper part of the gland.
    - They can be identified by the presence of basophilic cytoplasm.
    - These cells secrete *pepsinogen* which is converted into active pepsin in an acid environment and also secrete *lipase* and *amylase*.



### Box 12.8 Cardio-oesophageal Junction.

Presence of

- change of **stratified squamous epithelium** (oesophagus) into **simple columnar epithelium** (cardia of stomach);
- oesophageal** and **cardiac glands** in the lamina propria;
- gastric pits**.

#### 4. Enteroendocrine cells

- These cells are unicellular endocrine cells found in the basal part of the gland and need special stains to visualize.
- They are characterised by the presence of secretory granules in the basal part of the cytoplasm.
- They are grouped under the amine precursor uptake and decarboxylation (APUD) cell series.
- They secrete *enteroglucagon* and *amines*.

### Pylorus

- It is marked by the presence of *deep gastric pits* lined by simple columnar epithelium. The pits form one-half of the thickness of mucosa.
- It has *pyloric glands* (mucous) in the lamina propria.
- Middle circular muscle layer thickens to form *pyloric sphincter*.

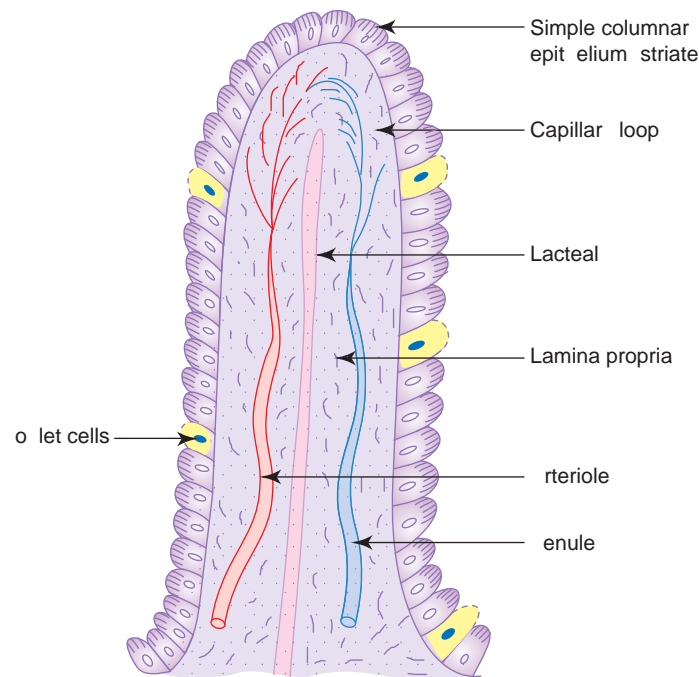
Gastric irritants (alcohol, aspirin, etc.) hyperosmolarity of meals, *Helicobacter pylori* infection and emotional stress—can disrupt the epithelial lining of stomach and lead to **ulceration** of mucosa. The initial ulceration may heal, but may aggravate if the mucosa is repeatedly damaged by the irritants.

In human beings, parietal cells are the main source of production of gastric intrinsic factor that helps in absorption of vitamin B<sub>12</sub> from ileum. Lack of intrinsic factor in **atrophic gastritis** (in which parietal and chief cells are less numerous) can lead to vitamin B<sub>12</sub> deficiency, which in turn disrupts erythropoiesis causing **pernicious anaemia**.

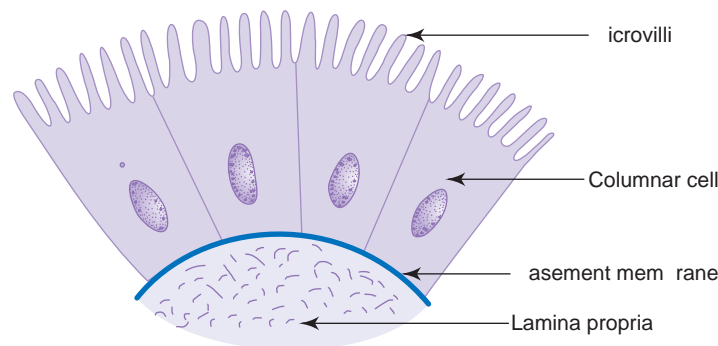
## SMALL INTESTINE

### GENERAL FEATURES

- It is about 6 m long.
- Is divided into 3 parts, *viz.*, duodenum, jejunum and ileum.
- Is the principal site for absorption of products of digestion. It also secretes some hormones through enteroendocrine cells.
- Digestion is completed in small intestine.
- To facilitate absorption, the luminal surface area is increased 400–600-fold by the presence of the following structures:
  1. **Plicae circulares (valves of Kerckring)**
    - Permanent circular folds of mucosa and submucosa—which increase the surface area 2–3-fold.
  2. **Intestinal villi (Fig. 12.9)**
    - Minute finger-like projections of mucosa containing a central core of lamina propria with a single lacteal (blind ended lymphatic vessel), capillary loops and smooth muscle cells derived from muscularis mucosa.
    - These increase the surface area 10-fold.
  3. **Microvilli (Fig. 12.10)**
    - Very minute finger-like projections of plasma membrane of absorptive columnar epithelial cells (under EM up to 300 per cell).
    - These give a striated border to the epithelium under LM.
    - Increase the surface area 20-fold.
    - The basic components of food—proteins, carbohydrates and lipids—are transformed into smaller molecules namely, amino acids, monosaccharides and monoglycerides, respectively and then absorbed by the intestinal villi. Amino acids and monosaccharides enter the intestinal capillaries and pass via the portal vein to the liver, whereas the free fatty acids and monoglycerides enter the lacteal and from there to the thoracic duct bypassing the liver. While being absorbed, the monoglycerides are converted to triglycerides and coated with protein and phospholipids to form fine globules called chylomicrons which are transported via lymphatics.



**Fig. 12.9** Intestinal villus.



**Fig. 12.10** Microvilli of columnar cells.

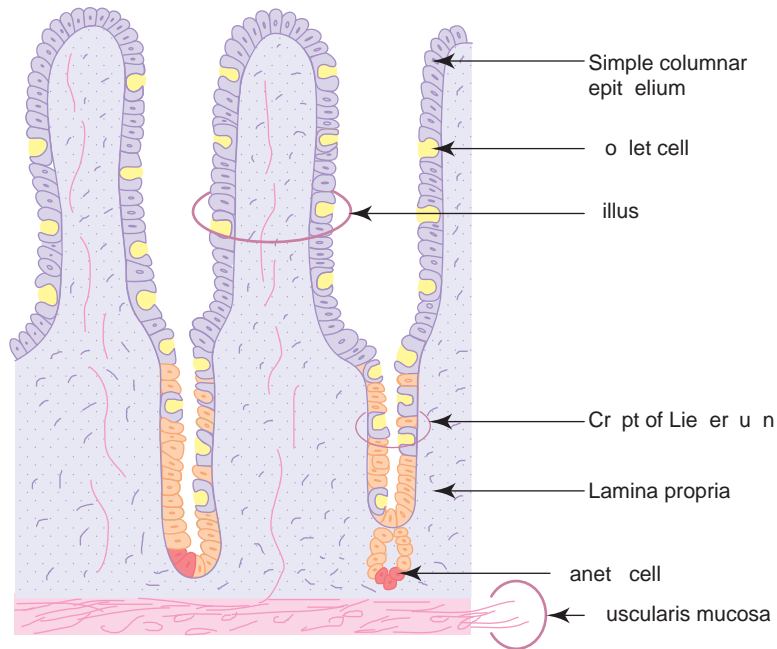
## STRUCTURE

- Small intestine is composed of the following four layers:

### 1. Mucosa (Fig. 12.11)

#### (a) Epithelium

- It is made of simple columnar absorptive epithelium with goblet cells.
- The epithelium and the underlying lamina propria shows finger-like evaginations called *intestinal villi*.
- A thick glycocalyx overlies the epithelium which serves as the site for adsorption of pancreatic enzymes and gives protection against autodigestion.
- Epithelium also shows tubular invagination from the base of the villi into the lamina propria known as *crypts of Lieberkuhn* (intestinal glands). These crypts are lined by columnar and goblet cells. Apart from these cells Paneth cells are found at the base, which secrete lysozyme, an antibacterial enzyme controlling the intestinal flora. The crypts open at the base of the villus in the intervillous space.
- Epithelium is renewed every 3–5 days.



**Fig. 12.11** Mucous membrane of small intestine.

**(b) Lamina propria**

- It is the connective tissue that contains fibroblasts, mast cells, plasma cells, lymphocytes + crypts of Lieberkuhn + lacteals + capillary loops.

**(c) Muscularis mucosa**

- Same as the general plan of GIT.

**2. Submucosa**

- It shows regional variations, e.g.
  - Presence of *Brunner's gland* in *duodenum*
  - *Peyer's patches* in *ileum*
  - *None of the above* in *jejunum*

**3. Muscularis externa**

- Same as the general plan of GIT.

**4. Serosa**

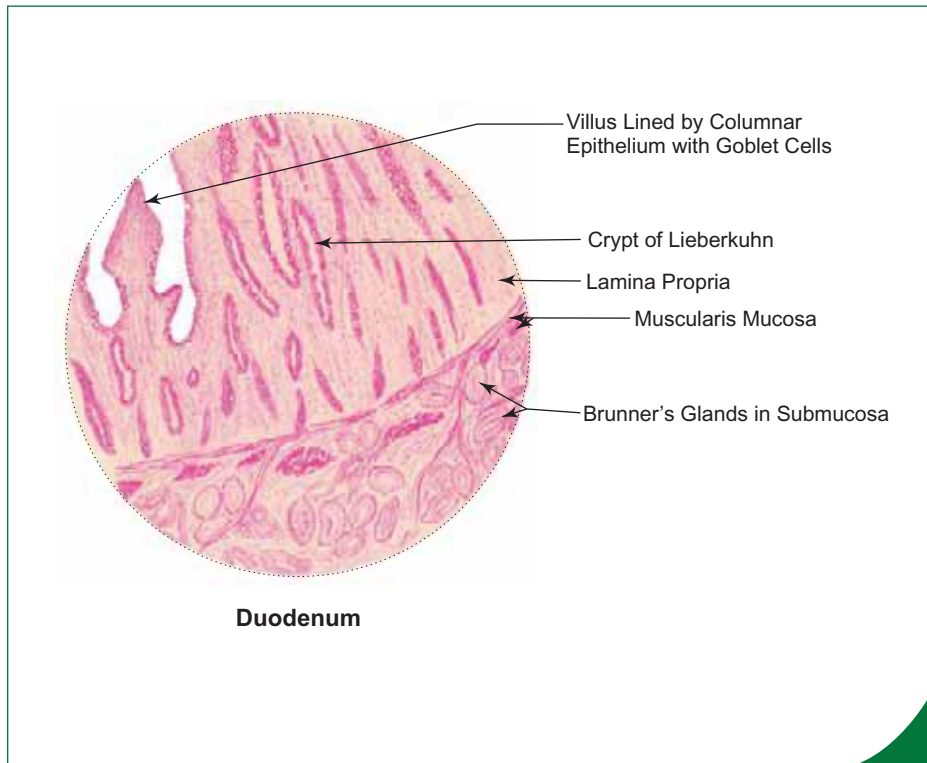
- Same as the general plan of GIT.

## SALIENT MICROSCOPIC FEATURES OF EACH REGION OF SMALL INTESTINE

### Duodenum (Box 12.9)

- The villi are leaf-like.
- Muscularis mucosa is disrupted.
- Presence of *Brunner's glands* (mucous) in the submucosa.
- These glands are branched coiled tubular structures opening into the bottom of the crypts.
- The glands secrete thin alkaline mucus to neutralize acid chyme and to protect the duodenal mucosa from autodigestion.
- The enteroendocrine cells present in the mucosa secrete hormone like, *urogastrone* that inhibits HCl secretion in the stomach and *secretin* and *cholecystinin* that regulate pancreatic secretion.



**Box 12.9 Duodenum.**

Presence of

- (i) short leaf-like **intestinal villi** lined by **simple columnar epithelium** with goblet cells;
- (ii) **Brunner's glands** (mucous) in the submucosa;
- (iii) crypts of Lieberkuhn.

**Jejunum (Box 12.10)**

- The villi are finger-like.
- The submucosa *lacks glands* and *Peyer's patches*.

**Ileum (Box 12.11)**

- The villi are thin and slender.
- The submucosa contains *Peyer's patches* (aggregated lymphoid follicles).
- M cells (antigen-presenting cells) are found overlying the lymphoid follicles.

**LARGE INTESTINE****GENERAL FEATURES**

- It consists of the caecum, appendix, colon, rectum and anal canal.
- It harbours some nonpathogenic bacteria that produce vitamin B<sub>12</sub> and vitamin K. The former is necessary for haemopoiesis and the latter for coagulation.
- Large intestine is involved in absorption of electrolytes and water from the indigestible remnants, converting these into faeces.
- It produces plenty of mucus that lubricates its lining and facilitates easy passage of faeces.
- It lacks intestinal villi.

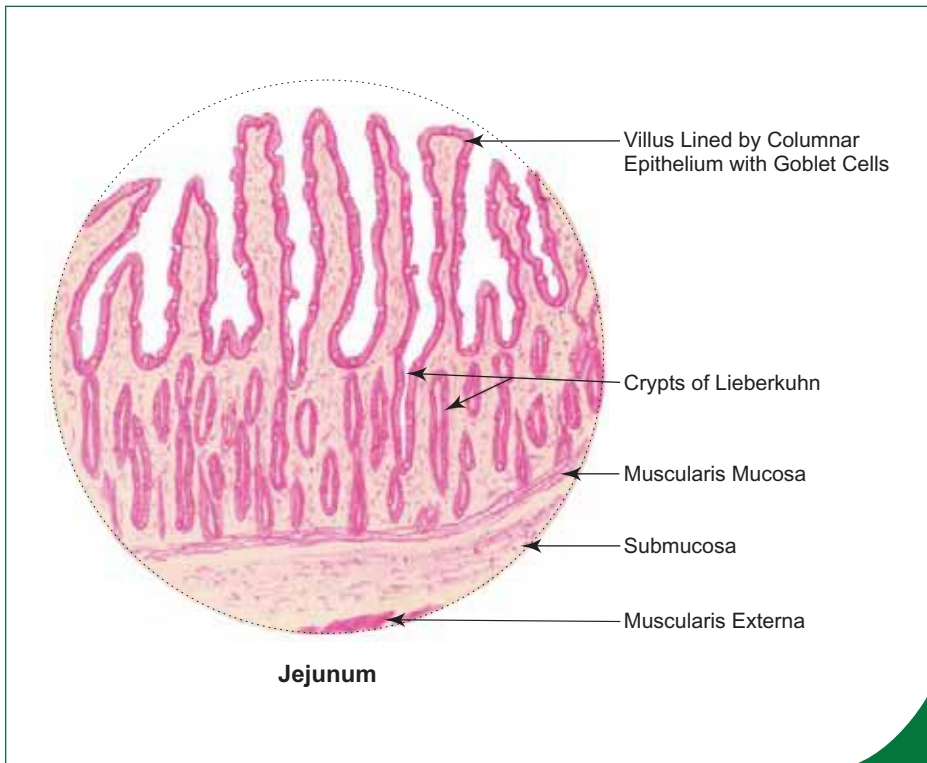
**STRUCTURE**

- The structure of large intestine follows the general plan of small intestine, except for the following salient features.

**Box 12.10 Jejunum.**

*Presence of*

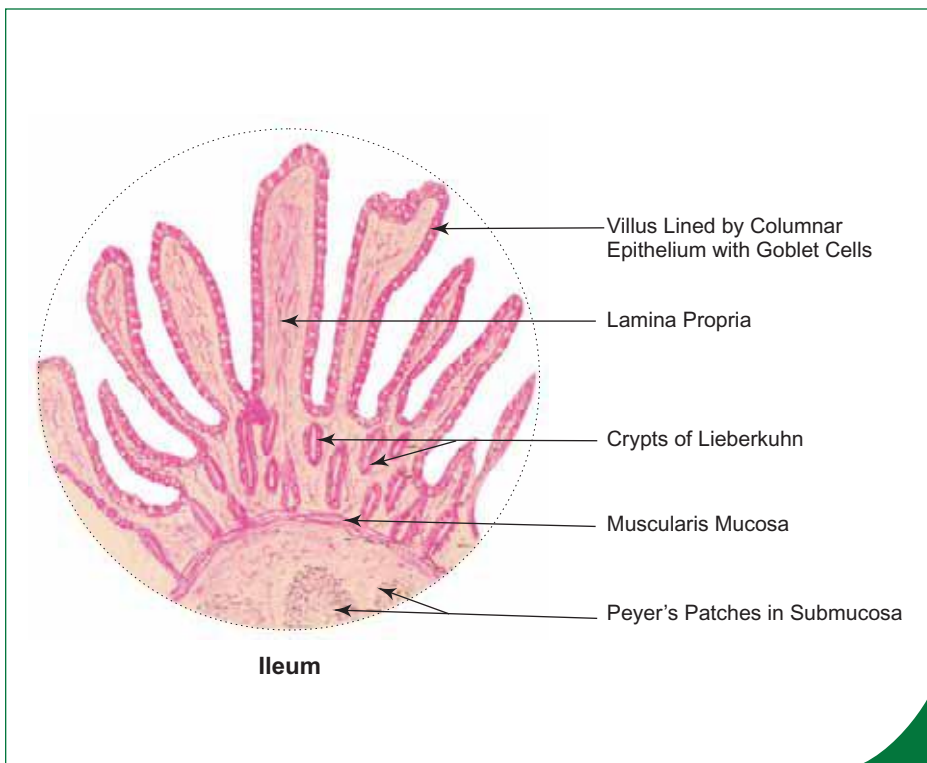
- (i) long club-shaped **intestinal villi** lined by **simple columnar** epithelium with goblet cells;
- (ii) **absence of Brunner's glands**;
- (iii) absence of Peyer's patches.



**Box 12.11 Ileum.**

*Presence of*

- (i) short slender finger-like **intestinal villi** lined by **simple columnar** epithelium with goblet cells;
- (ii) **Peyer's patches** (lymphoid aggregations) in the submucoa.



## SALIENT FEATURES OF EACH REGION OF LARGE INTESTINE

### Vermiform Appendix (Box 12.12)

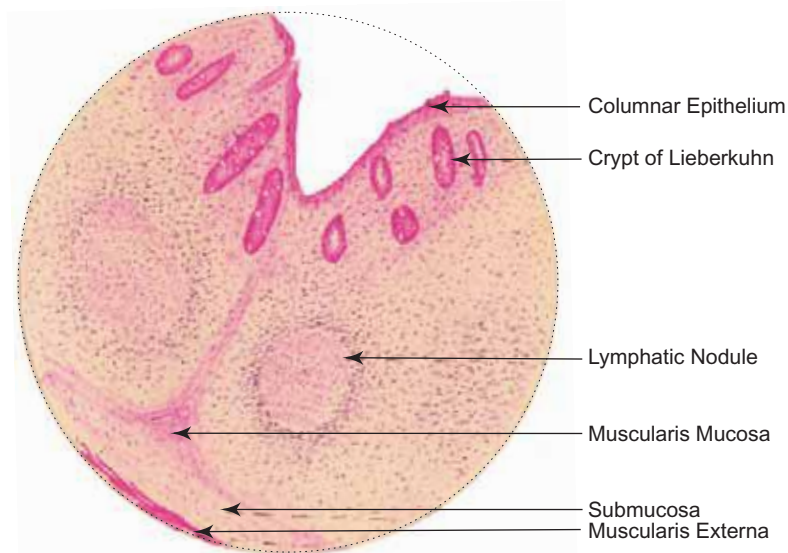
- Small angular lumen compared to the thick wall.
- No villi.
- Few short crypts.
- Ring of *lymphoid follicles* with germinal centres in the lamina propria around the lumen.
- Disrupted muscularis mucosa.

### Caecum and Colon (Box 12.13)

- No villi.
- Crypts are well developed and lined by plenty of goblet cells.
- Paneth cells are absent in the crypts.
- Outer longitudinal layer of muscularis externa shows thickening to form ribbon-like bands (3 in number) called *taenia coli*.
- Serosa shows fat-filled peritoneal pockets called *appendices epiploicae*.

### Rectum

- Long crypts of Lieberkuhn (intestinal glands).
- Lymphoid tissue is less abundant in the lamina propria.



Vermiform appendix

#### Box 12.12 Vermiform Appendix.

Presence of

- few crypts** of Lieberkuhn lined by simple columnar epithelium with goblet cells;
- lymphatic nodules** in the lamina propria;
- small angular lumen** compared to the thick wall.

**Absence of intestinal villi.**

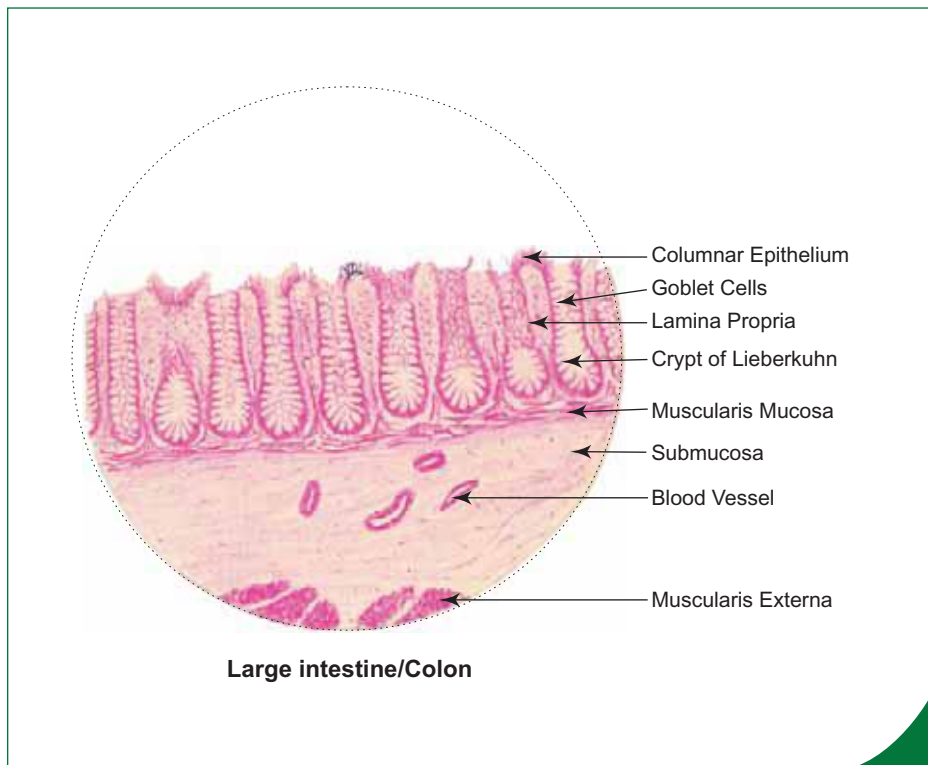
- The muscle coat lacks taenia coli.
- Serosa is replaced by adventitia in the lower part.

### Anal Canal

- Epithelium of the anal canal shows changes at different levels:
  - Above the anal valves—stratified cuboidal.
  - At the anal valves—stratified squamous.
  - At the anal orifice—becomes epidermis of skin (mucocutaneous junction).
- No crypts of Lieberkuhn.
- No muscularis mucosa.
- Deeper part of lamina propria becomes submucosa containing rich vascular plexus.
- Inner circular layer of smooth muscle thickens to form *internal anal sphincter*.
- Externally, at the orifice, skeletal muscle forms *external anal sphincter*.

## GLANDS ASSOCIATED WITH DIGESTIVE SYSTEM

- The major glands associated with digestive system are the salivary glands, liver and pancreas. This chapter also deals with gall bladder, which stores and concentrates bile secreted by the liver.



### Box 12.13 Large Intestine/Colon.

*It is characterised by*

- absence of **intestinal villi**;
- presence of **more crypts** of Lieberkuhn with large number of goblet cells;
- presence of well defined muscularis mucosa;
- presence of **taenia coli**.

In **Hirschsprung's disease** (congenital megacolon), the intrinsic nerve plexuses (Meissner's and myenteric plexuses) are not well developed. This leads to disturbances of digestive tract motility with dilatation proximal to the affected region, especially seen in sigmoid colon.

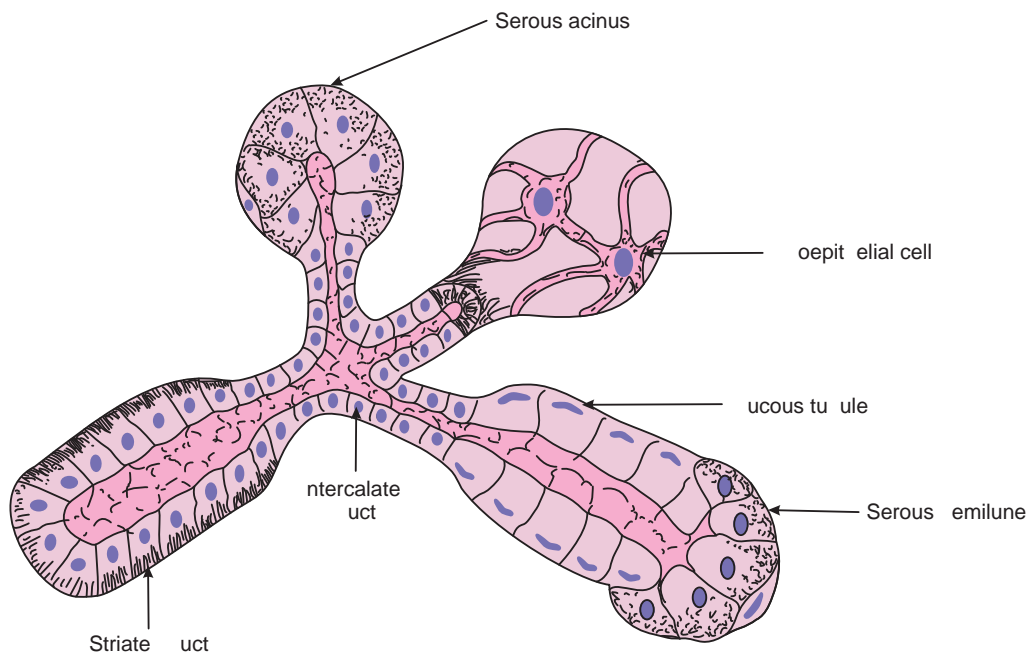
## SALIVARY GLANDS

### GENERAL FEATURES

- There are three pairs of major salivary glands in human beings, viz. *parotid*, *submandibular* and *sublingual glands*. They secrete saliva (600–1500 ml/day) which is conveyed to the oral cavity through ducts.
- Apart from major salivary glands there are minor salivary glands present in the oral mucosa and these are named according to the place where they are situated (*labial glands* in the lip, *lingual glands* in the tongue, *buccal glands* in the cheek and *palatine glands* in the palate).
- The percentage of saliva secreted by each of these glands varies: parotid 20%, submandibular 70%, sublingual 5% and minor glands 5%.
- The main functions of saliva are to lubricate the oral cavity, to initiate digestion of carbohydrates and to cleanse the teeth.

### STRUCTURE

- One of the characteristic features of salivary gland is the presence of *striated ducts* (Fig. 12.12). These ducts are intralobular in position and are lined by low columnar epithelium stained deeply with eosin.
- Under an electron microscope, the cells lining these ducts show characteristic features of ion transporting cells. They have basal infoldings of plasma membrane and longitudinal orientation of mitochondria between the infoldings, which give a striated appearance to the basal part of epithelium under a light microscope giving the name striated duct. These ducts change the ionic composition of primary saliva from isotonic to hypotonic by secreting potassium and absorbing sodium ions.
- Striated ducts are formed by the union of small *intercalated ducts* which arise from acini. The striated ducts drain into large *excretory ducts* which are interlobular in position and lined by stratified columnar epithelium.
- The main duct of each salivary gland empties into the oral cavity and is lined by stratified squamous epithelium.



**Fig. 12.12** Parenchyma of salivary glands, ducts and secretory end pieces.

### Parotid Salivary Gland (Box 12.14)

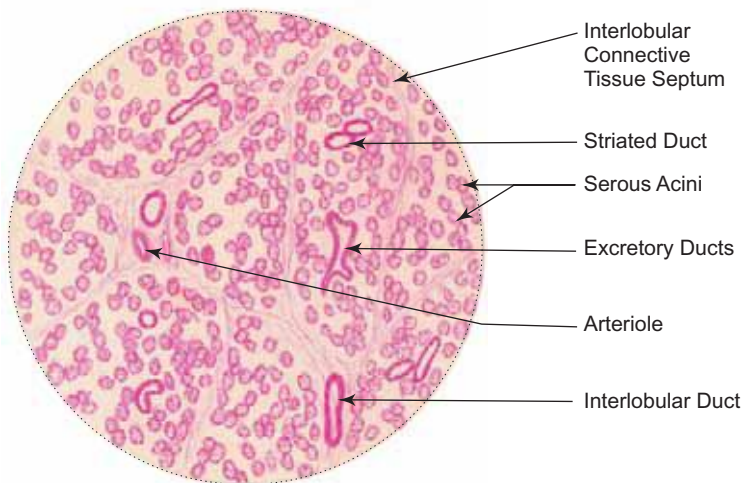
- Parotid is a compound acinar gland, whose secretory end pieces are made purely of *serous acini*. (The histological structure of a serous acinus is described in chapter 3.)
- Parotid gland is characterised by the presence of many ducts of varying calibre and the gland is often infiltrated with adipocytes.
- The plasma cells found in the connective tissue component of the gland are responsible for the production of IgA present in the saliva.
- The main parotid duct (*Stenson's duct*) opens into the vestibule of the mouth opposite the upper second molar tooth.

### Submandibular Salivary Gland (Box 12.15)

- Submandibular is a compound tubuloacinar gland of *mixed* variety. Its secretory end pieces are formed predominantly by serous and few mucous acini. Some of the mucous acini are associated with serous demilunes.
- The serous and mucous acini are differentiated by their histological features (refer to chapter 3).
- The submandibular duct (*Wharton's duct*) opens on the top of the sublingual papilla in the floor of the mouth cavity on either side of frenulum linguae.

### Sublingual Salivary Gland (Box 12.16)

- Sublingual is also a compound tubuloacinar gland like submandibular gland. Its secretory end pieces are formed predominantly by *mucous acini*. However, some serous cells form demilunes on mucous acini.
- The gland is drained by many ducts (*ducts of Rivinus*) which open directly on the surface of the sublingual fold in the floor of mouth cavity. Some ducts may join Wharton's duct.



Parotid salivary gland

#### Box 12.14 Parotid Salivary Gland.

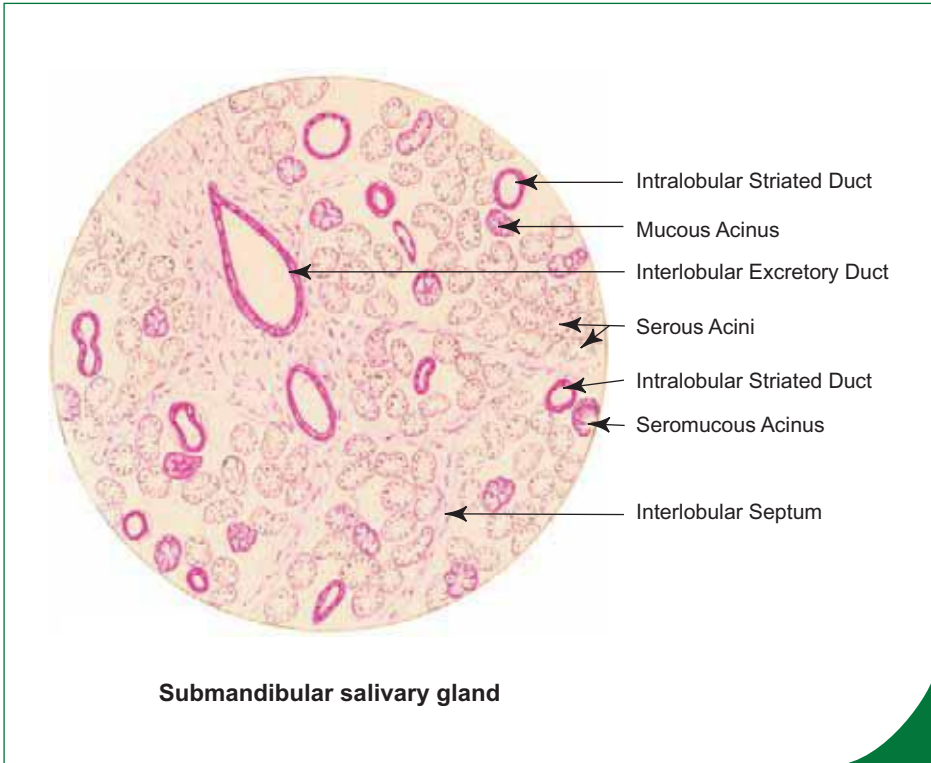
Presence of

- (i) **serous acini;**
- (ii) large number of ducts including **striated ducts;**
- (iii) infiltration of **adipocytes.**

**Box 12.15 Submandibular Salivary Gland.**

Presence of

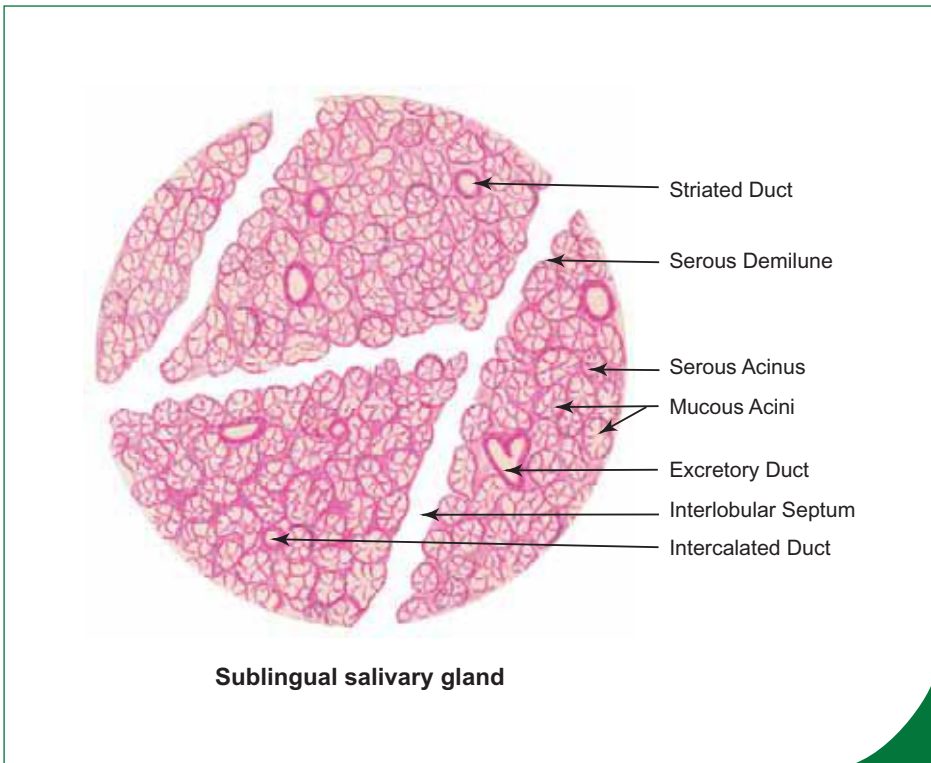
- (i) **many serous acini** and **few mucous acini**;
- (ii) **many striated ducts**;
- (iii) **serous demilunes**.



**Box 12.16 Sublingual Salivary Gland.**

Presence of

- (i) **many mucous acini** and tubules;
- (ii) **few striated ducts**;
- (iii) **few serous demilunes**.



## LIVER

### GENERAL FEATURES

- Liver is 2% of body weight and is the second heaviest organ in the body (first being skin) situated mainly in the right hypochondrium, below the right dome of diaphragm in the abdomen.
- It is irrigated by two types of blood vessels, namely, portal vein (70%) and hepatic artery (30%).
- Liver is an important organ because it performs the following exocrine and endocrine functions and is involved in:
  - *synthesis and secretion of bile* (exocrine function) for emulsification of fat for easy digestion,
  - *excretion of bilirubin* into the bile, which is a toxic chemical formed in the body during degradation of worn out erythrocytes by the phagocytic cells (Kupffer's cells) of liver,
  - *synthesis and secretion of plasma proteins* like albumin, prothrombin and fibrinogen (endocrine function),
  - *storage of glucose as glycogen*,
  - *detoxification* of various drugs and harmful substances like alcohol,
  - *haemopoiesis in foetuses*,
  - *clearing the blood* of cellular debris and particulate material by the phagocytic function of the Kupffer's cells.

### STRUCTURE

- Liver is completely invested by a fibrous capsule called *Glisson's capsule* that lies deep to the peritoneal covering (mesothelium).
- The Glisson's capsule is thickened at the porta hepatis and sends trabeculae into the interior dividing the parenchyma into incomplete *lobules*.
- These trabeculae carry branches of hepatic artery, portal vein, hepatic duct and lymphatics and are called *portal tract* or portal space or portal canal.

### Liver Lobule (Box 12.17 and Fig. 12.14)

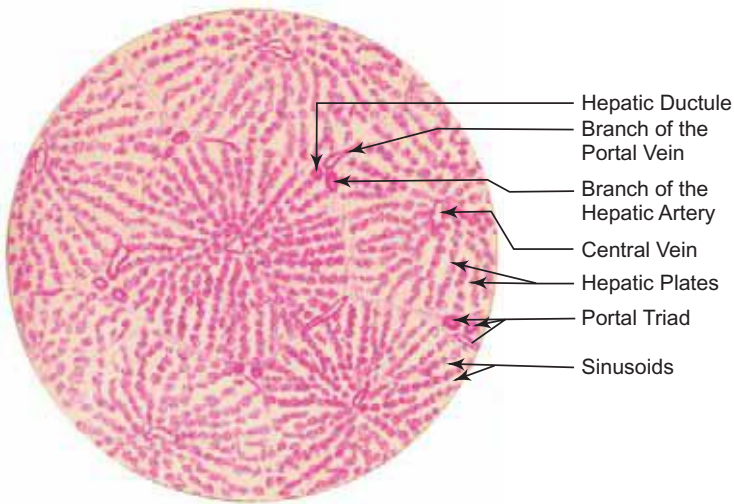
- A classical liver lobule is hexagonal (polygonal) in shape and forms the structural unit of liver.
- It has a vein at the centre, the *central vein*.
- Unlike the liver of pig, human liver lobules are not completely demarcated by connective tissue septae. So, it is very difficult to precisely identify the limit of the lobule.
- However, hexagonal shape of the lobule can be defined by drawing imaginary lines connecting the portal tracts that are present at the periphery (corners) of the lobule.
- The portal tract contains connective tissue derived from Glisson's capsule, containing three structures, namely, a portal venule, hepatic arteriole and a small hepatic ductule. As these three structures are always found in the portal tract, the portal tracts are often referred to as **portal triad** (Fig. 12.13).
- The main structural and functional components of the liver are the hepatocytes, which are arranged in one cell thick plates radiating from the central vein towards the periphery of the lobule. (The hepatic plates are two cells thick in children until about seven years of age.) These *hepatic plates* branch and anastomose freely forming a complex labyrinthine and spongy structure.
- The irregular spaces between the hepatic plates are occupied by liver *sinusoids* which are lined by discontinuous fenestrated endothelial cells.
- Some of the endothelial cells are modified to become phagocytic cells called *Kupffer's cells* which phagocytose worn out RBCs. These cells form a part of the mononuclear phagocytic system (Fig. 12.14).
- There are also cells called hepatic stellate/Ito cells (perisinusoidal lipocytes) present within the hepatic plates. They become activated in certain pathological condition.



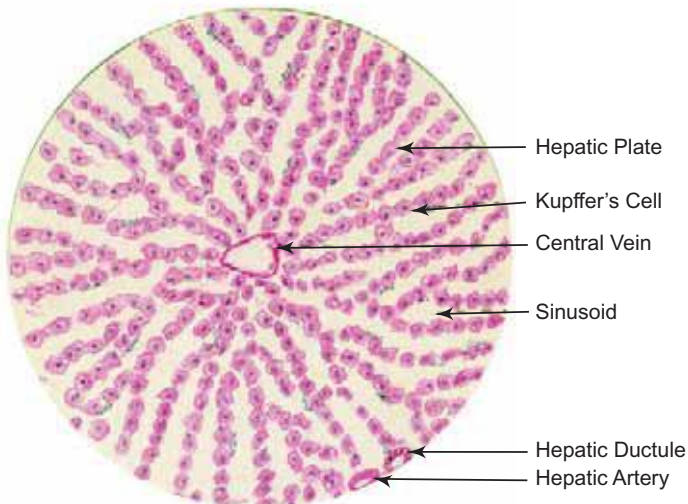
**Box 12.17** Liver.

*Presence of*

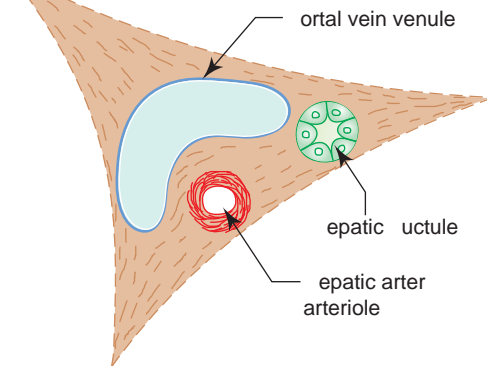
- (i) polygonal **hepatic lobules**;
- (ii) **portal triad** (containing branches hepatic artery, portal vein and hepatic duct);
- (iii) **central vein** in the centre of the lobule;
- (iv) radiating **hepatic cords** and **sinusoids** from central vein.



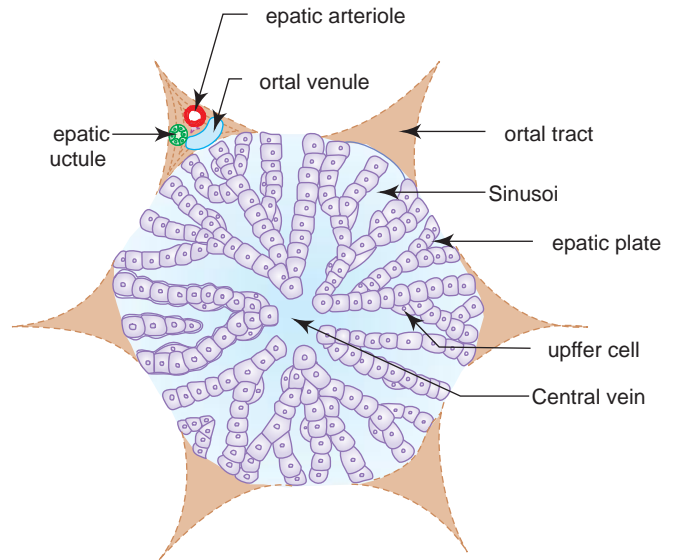
**L/P**  
**Liver**



**H/P**  
**Liver**

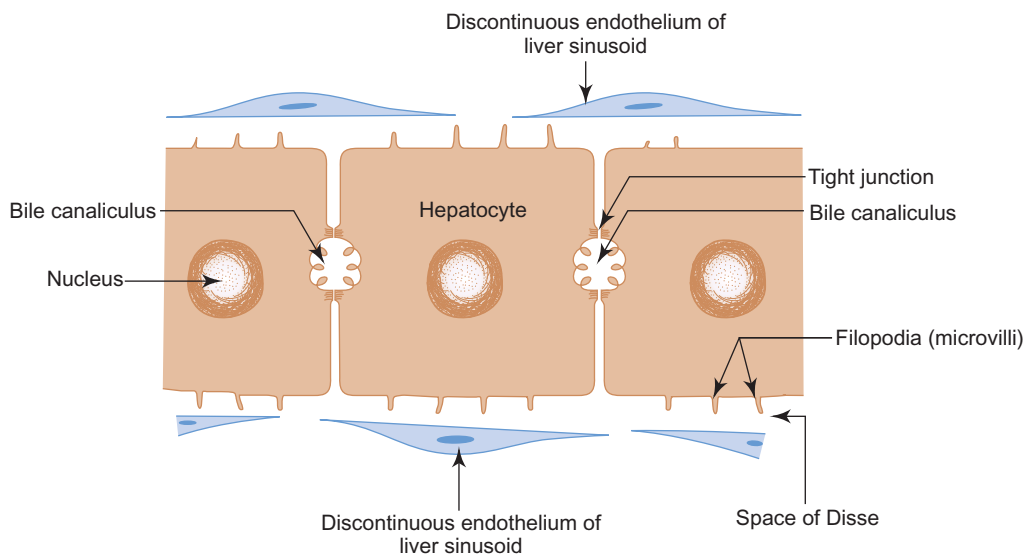


**Fig. 12.13** Portal tract (portal triad).



**Fig. 12.14** A classic liver lobule.

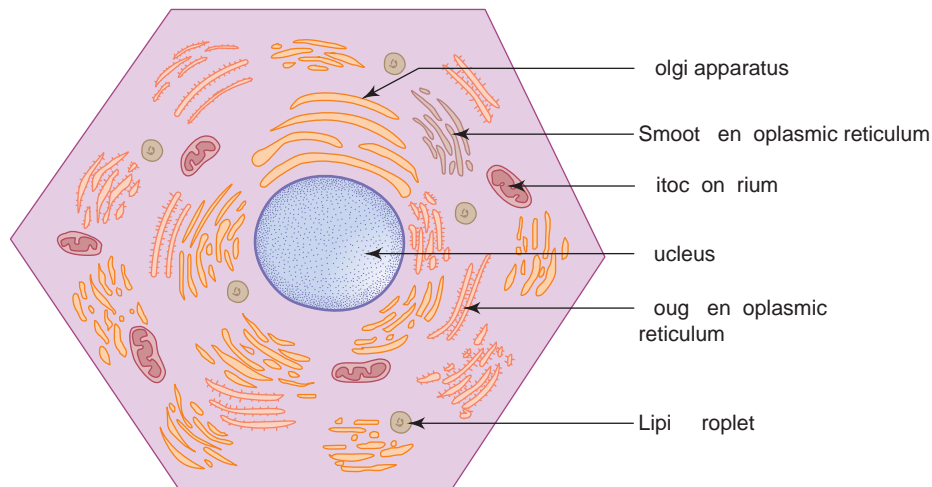
- The sinusoids are separated from the underlying plates of hepatocytes by a perisinusoidal *space of Disse* (Fig. 12.15).
- The sinusoids are irrigated by the mixed arterial blood from hepatic artery and venous blood from portal vein through distributing vessels from the periphery of the lobule. The blood then flows towards the central vein, which in turn, drains into sublobular vein and then to the hepatic vein.
- The absorbed nutritive materials and  $O_2$  present in the mixed blood percolates through the discontinuous endothelial wall of these sinusoids and comes into direct contact with the hepatocytes through the space of Disse. This allows exchange of material between blood and hepatocytes in an efficient manner.



**Fig. 12.15** Space of Disse and bile canaliculus.

## Hepatocytes (Fig 12.16)

- Hepatocytes are polyhedral cells having one or two spherical nuclei with well developed nucleoli. The nuclei of hepatocytes often show polyploidy.
- The cytoplasm is eosinophilic and contains abundant mitochondria.
- As the cell is metabolically very active, organelles like rER, sER and Golgi complex are also well developed reflecting the multiple potential functions of the hepatocytes.
- Out of the six or more surfaces of the hepatocyte, at least two surfaces of each hepatocyte are in contact with the wall of the sinusoids through space of Disse, facilitating exchange of materials between blood and hepatocytes.
- The other surfaces which are in contact with the adjacent hepatocytes delimit a tubular intercellular space known as *bile canaliculus* and is bounded only by the plasma membranes of two hepatocytes (Fig. 12.15). The plasma membranes near the canaliculus are firmly bound by tight junctions.
- Thus within each plate of hepatocytes, the canaliculi form a regular hexagonal network in the plane of the plate, each mesh enclosing a single hepatocyte.
- These bile canaliculi which have no lining of their own, are the first part of the *bile duct* system and terminate in the hepatic ductule in the portal triad through canal of Hering. These ductules unite to form large hepatic duct.
- Thus, the bile synthesised in the liver cells flows through the duct system in a direction opposite to that of blood, i.e. from the centre of the lobule to its periphery.



**Fig. 12.16** Electron microscopic structure of a hepatocyte.

## Portal Lobule

- To study certain pathological conditions it is useful to divide the liver into functional units called portal lobule.
- It can be defined as that part of the liver parenchyma that drains bile into the hepatic ductule present at the portal triad.
- The portal lobule is triangular in shape and can be visualised by drawing imaginary lines connecting the central veins of three adjacent liver lobules with the portal triad at the centre (Fig. 12.17).

## Hepatic Acinus

- Hepatic acinus is another functional unit of the liver which is irrigated by the terminal distributing branches of portal vein and hepatic artery.
- It is diamond-shaped containing adjacent areas of two classical liver lobules between the central veins. The corners of the diamond are formed by central veins and portal triads with the distributing vessels in the centre (Fig 12.17).
- In relation to their proximity to the distributing vessels, cells in the hepatic acinus can be subdivided into many zones. Cells close to the vessels (zone I) would be the first to be affected by or to alter the incoming blood and vice versa.

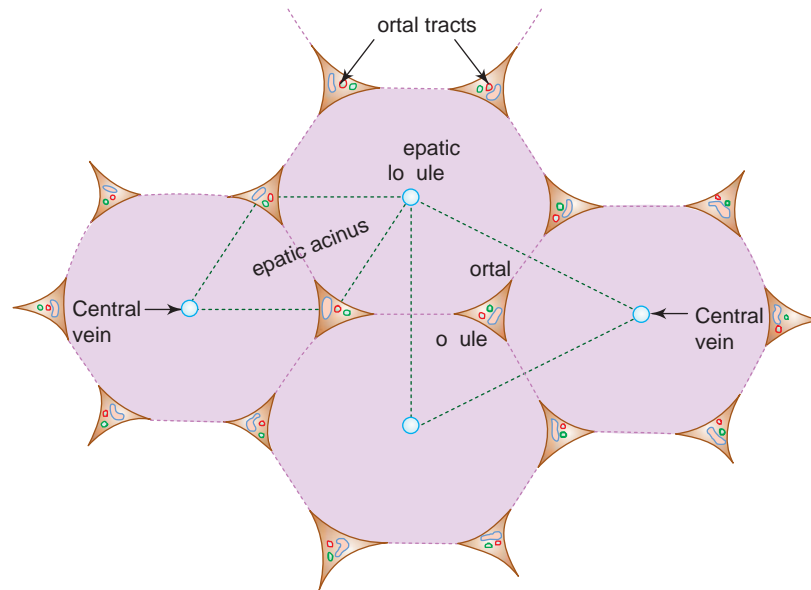


Fig. 12.17 Structural and functional subdivisions of liver parenchyma.

## REGENERATION OF LIVER

- The regenerative capacity of liver is very good. Loss of hepatic tissue by surgical removal or by toxic reaction triggers a mechanism by which hepatocytes begin to divide and the process continues till the original mass of tissue is restored. This regenerative capacity of liver helps the surgeon to go for transplantation of a part of liver.

In spite of liver having a remarkable regeneration capacity, it reacts differently when there is a continuous or repeated damage to hepatocytes induced by alcohol. In such conditions, hepatocytes proliferate in a disorganized manner forming nodular masses with increased amount of connective tissue, a condition called **cirrhosis** of liver.

## PANCREAS

### GENERAL FEATURES

- Pancreas is an *exocrine* digestive gland as well as an *endocrine* gland.
- It extends from the concavity of the duodenum on the right to the spleen on the left in the posterior abdominal wall retroperitoneally.

### STRUCTURE

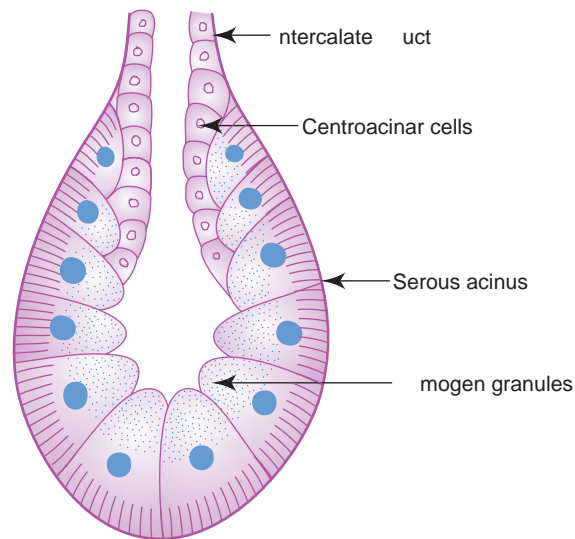
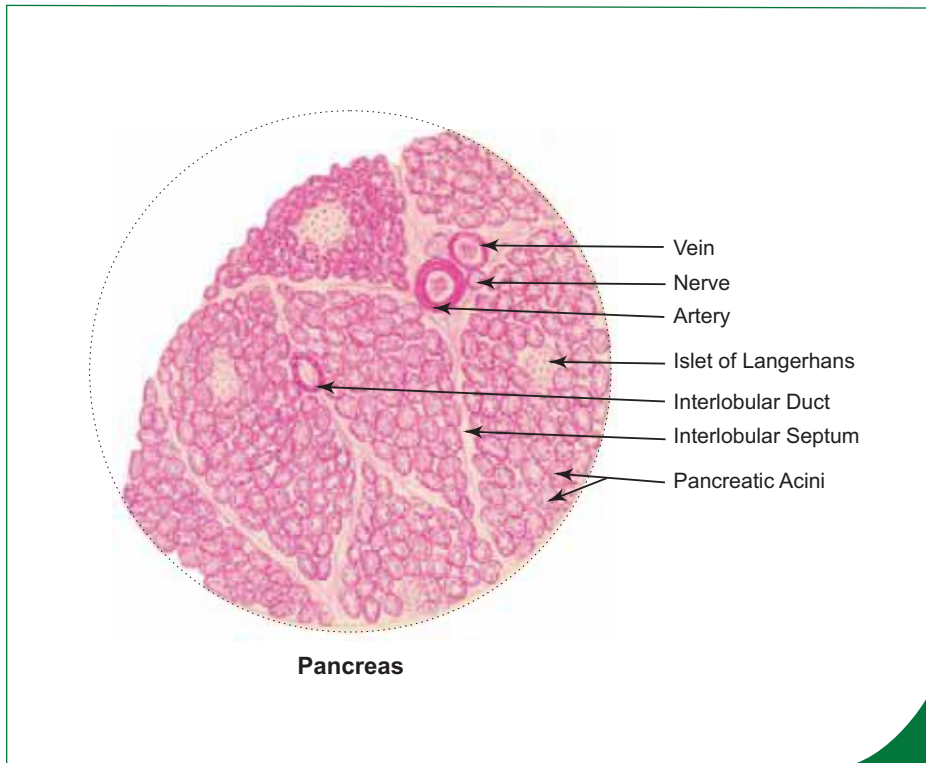
#### Exocrine Pancreas (Box 12.18)

- The exocrine part of pancreas is formed by *serous acini* arranged into many lobules.
- The lobules are separated by interlobular septae of connective tissue which carry neurovascular structures and ducts.
- Each serous acinus is made of pyramidal serous cells surrounding a small lumen. These cells are darkly stained at the base and lightly at the apex and contain zymogen granules (Fig. 12.18). There are no myoepithelial cells. Instead, there are myofibroblast like cells called pancreatic stellate cells found encircling the base of the acinus in the periacinar connective tissue.
- Some of the acini exhibit pale staining *centroacinar cells* within the lumen. They are cuboidal in shape and represent the intra-acinar part of the intercalated duct, which instead of arising from the periphery of the acinus, has invaginated into the acinus and starts from inside it (Fig. 12.18).

**Box 12.18 Pancreas.**

It is characterised by

- (i) presence of darkly stained **serous acini**;
- (ii) presence of lightly stained islets of **Langerhans**;
- (iii) presence of **centroacinar cells**;
- (iv) **absence of striated duct**.



**Fig. 12.18** Pancreatic serous acinus.

- The intercalated ducts drain into intralobular ducts which in turn drain into interlobular ducts and are lined by simple to stratified cuboidal epithelium. The interlobular ducts empty into the main pancreatic duct.
- The exocrine part of pancreas secretes pancreatic juice (alkaline in nature), rich in digestive enzymes into the duodenum. This alkaline pancreatic secretion neutralizes the acidic chyme that comes to the duodenum from the stomach.
- These digestive enzymes (protease, amylase, lipase) break down protein, carbohydrate and fat into smaller molecules facilitating absorption.
- The pancreatic secretion is regulated by hormones like *secretin* and *cholecystokinin* (pancreozymin) produced by the enteroendocrine cells of duodenal mucosa and by vagal stimulation.
- Presence of acidic chyme in the duodenum stimulates secretion of secretin which in turn stimulates the pancreatic acini (especially centroacinar cells) to secrete large amount of watery fluid rich in bicarbonate ions. This bicarbonate rich fluid neutralizes the acidic chyme, facilitating digestion by other pancreatic enzymes.

- Cholecystokinin stimulates the acinar cells to secrete large amount of digestive enzymes and also causes contraction of gall bladder.
- The digestive enzymes which are in inactive form initially are activated in the duodenum by the hormone *enterokinase* secreted by the intestinal mucosa.

### Endocrine Pancreas (Box 12.18)

- The endocrine part of pancreas is formed by *islets of Langerhans*, which appear as pale staining spherical bodies among the serous acini (Fig. 12.19).
- They are more in the tail region of pancreas.
- There are about 1 to 2 million islets in the pancreas.
- They are made of branching cords of endocrine cells of the following types, supported by reticular fibres.
- A rich network of capillaries can be seen among the cords of cells:
  1. **Alpha ( $\alpha$ ) cells**
    - Form 20% of the total population
    - Are large cells with eosinophilic granules
    - Are found mainly at the periphery of islet
    - Secrete *glucagon*, that increases glucose level in the blood.
  2. **Beta ( $\beta$ ) cells**
    - Form 70% of the population
    - Are small cells with basophilic granules
    - Are found mostly in the centre
    - Secrete *insulin* which decrease glucose level in the blood.
  3. **Delta ( $\delta$ ) cells**
    - Form 5% of the population
    - Secrete *somatostatin*, which inhibits secretion of GH, glucagon and insulin. They also decrease pancreatic exocrine secretion and bile secretion.
  4. **F cells/PP Cells**
    - Secrete *pancreatic polypeptides* which inhibit pancreatic secretion.

In **diabetes mellitus**, the beta cells of islet of Langerhans are unable to produce the required amount of insulin, resulting in increased blood sugar level. If the disease remains untreated, it may lead to degenerative changes of other organs like kidney, retina, etc.

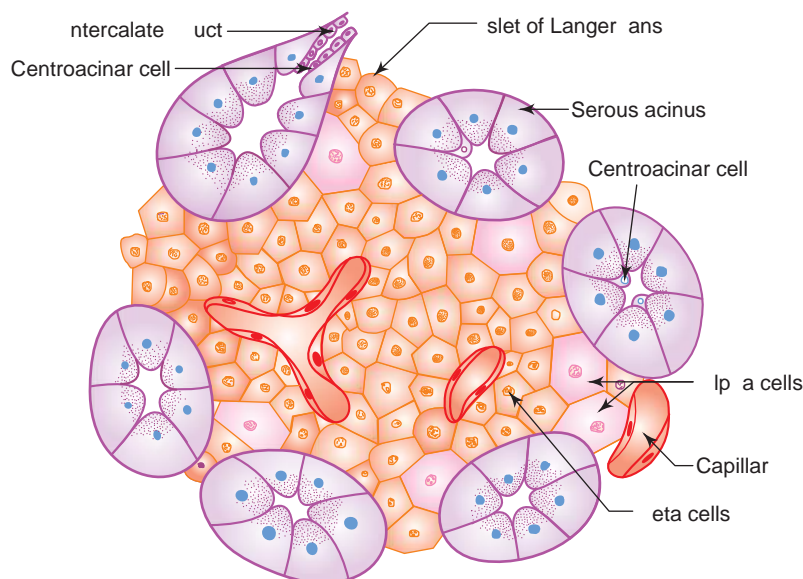


Fig. 12.19 Islet of Langerhans.

## GALL BLADDER

### GENERAL FEATURES

- Gall bladder is a muscular sac situated on the visceral surface of liver in the fossa for gall bladder.
- It concentrates bile by absorbing water and stores the same.
- It has a capacity of about 50–100 ml.
- Presence of fatty content in the small intestine stimulates the production of cholecystokinin (CCK) by the enteroendocrine cells present in the duodenal mucosa. This causes contraction of gall bladder discharging bile into the common bile duct. Bile salts emulsify lipids facilitating absorption.

### STRUCTURE (BOX 12.19)

Gall bladder has from inner to outer, the following coats:

#### 1. Mucosa

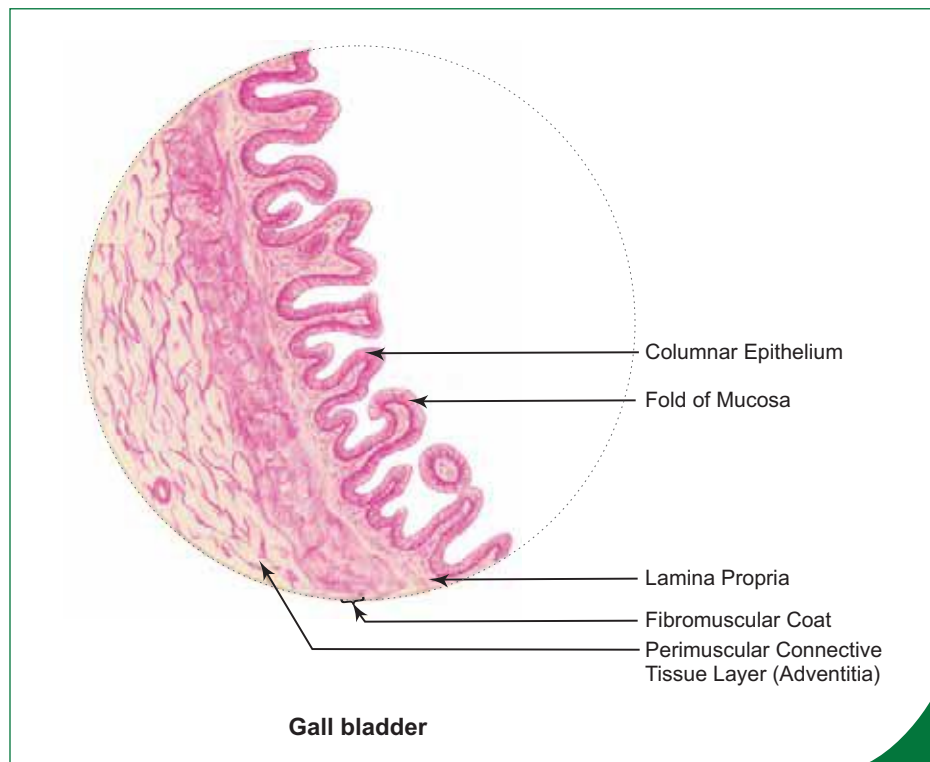
- It includes the lining epithelium of simple columnar variety and the supporting lamina propria rich in elastic fibres and blood vessels.
- As this epithelium is involved in absorption of water, it is provided with microvilli which give a brush border appearance to the epithelium under light microscope.
- Mucosa is thrown into small folds when the bladder is empty.
- Muscularis mucosa and submucosa are absent. (Muscularis mucosa and muscularis externa fuse.)

#### 2. Fibromuscular layer

- This layer is composed of circularly arranged smooth muscle fibres intermixed with connective tissue.

#### 3. Serosa/Adventitia

- The fundus and lower surface of body of gall bladder is covered by peritoneum (serosa), whereas the upper surface is attached to the fossa for gall bladder by means of connective tissue (adventitia). So depending on the area selected for sectioning, the outer coat is made of either serosa or adventitia.



#### Box 12.19 Gall Bladder.

*It is characterised by*

- (i) presence of mucosal folds lined by **simple tall columnar epithelium**;
- (ii) presence of **fibromuscular layer**;
- (iii) absence of muscularis mucosa and submucosa.

# Self-assessment Exercise

## I. Write short notes on:

- (a) Histology of tooth
- (b) Lingual papillae
- (c) Structure of oesophagus
- (d) Gastric glands
- (e) Structure of fundus of stomach
- (f) Structure of duodenum
- (g) Structure of ileum
- (h) Structure of vermiform appendix
- (i) Structure of liver
- (j) A classic hepatic lobule
- (k) Portal lobule
- (l) Structure of pancreas
- (m) Islet of Langerhans

## II. Fill in the blanks:

1. Digestion of carbohydrate is initiated by the enzyme \_\_\_\_\_ present in the saliva
2. Gastric intrinsic factor secreted by parietal cells helps in absorption of \_\_\_\_\_
3. The blind-ended lymphatic vessel present in the intestinal villus is called \_\_\_\_\_
4. The fibrous capsule that surrounds the liver is called \_\_\_\_\_
5. The phagocytic cells present in liver sinusoids are called \_\_\_\_\_
6. Insulin deficiency leads to a clinical condition called \_\_\_\_\_
7. Mucosa of gall bladder is lined by \_\_\_\_\_
8. The space around the sinusoid in the liver is called \_\_\_\_\_
9. The cells responsible for the formation of enamel in tooth are called \_\_\_\_\_
10. Submucosa of duodenum contains \_\_\_\_\_ glands.

## III. Choose the best answer:

1. Dentine of the tooth is formed by
  - (a) ameloblast
  - (b) odontoblast
  - (c) cementoblast
  - (d) fibroblast
2. Circumvallate papilla is characterised by the presence of the following, *except*
  - (a) circular furrow
  - (b) taste buds on the lateral wall
  - (c) simple columnar epithelium
  - (d) von Ebner's glands



3. Meissner's plexus is present in which layer of GIT?
  - (a) lamina propria
  - (b) submucosa
  - (c) muscularis externa
  - (d) serosa
4. Which of the following structures is *not* lined by stratified squamous epithelium?
  - (a) Oral cavity
  - (b) Oesophagus
  - (c) Stomach
  - (d) Anal canal
5. To facilitate absorption, the luminal surface area of small intestine is increased manifold due to the presence of
  - (a) plica circulares
  - (b) intestinal villi
  - (c) microvilli
  - (d) all of the above
6. Paneth cells are present in
  - (a) rectum
  - (b) colon
  - (c) small intestine
  - (d) stomach
7. The percentage of saliva secreted by submandibular gland is
  - (a) 70
  - (b) 30
  - (c) 20
  - (d) 10
8. Which of the following statements is *not true* about the striated ducts of salivary glands? They
  - (a) are involved in ion transport
  - (b) show basal infoldings of plasma membrane
  - (c) bear microvilli on their free surface
  - (d) are intralobular in position
9. Bile canaliculus is lined by
  - (a) endothelium
  - (b) plasma membrane of adjacent hepatocytes
  - (c) cuboidal epithelium
  - (d) none of the above
10. Which of the following cell is responsible for secretion of glucagon in the islet of Langerhans?
  - (a) Alpha
  - (b) Beta
  - (c) Delta
  - (d) F

**IV. State whether the following statements are true (T) or false (F):**

1. Enamel of the tooth is the hardest substance in the body ( )
2. Ameloblasts are mesodermal in origin ( )
3. Filiform papilla contains taste buds ( )
4. Sweet sensation (taste) is best perceived at the tip of the tongue ( )
5. Muscularis externa of upper one-third of oesophagus is made only of skeletal muscle ( )
6. In Hirschsprung's disease, the Auerbach's plexus is not well developed ( )
7. The flow of blood in a classic liver lobule is from centre to periphery ( )
8. Presence of fatty substance in the lumen of small intestine stimulates the production of cholecystokinin ( )
9. The immunoglobulin, IgA present in the saliva is derived from parotid salivary gland ( )
10. Oesophageal glands are present in the lamina propria ( )

**V. Match the items in Column 'A' with those of Column 'B':**

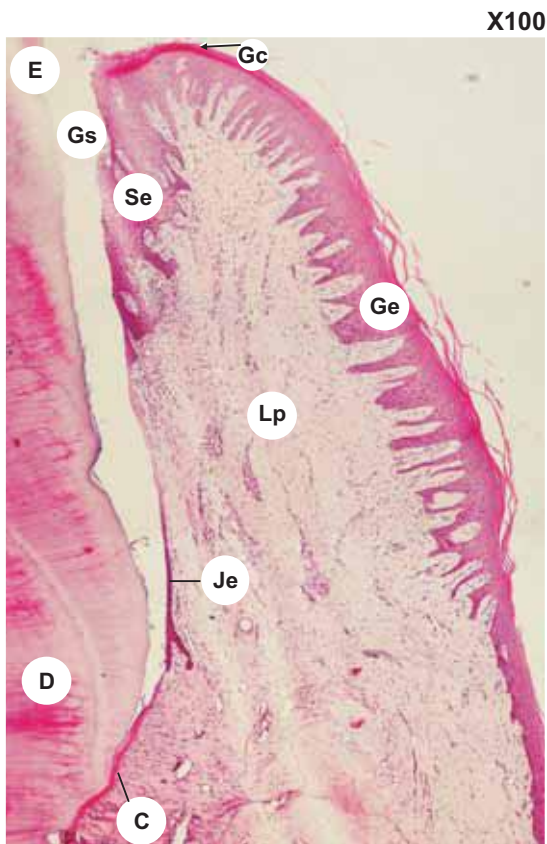
Column 'A'	Column 'B'
A. <i>Organ/Structure</i>	<i>Lining epithelium</i>
1. Intestine ( )	(a) Simple columnar
2. Tongue ( )	(b) Simple columnar with goblet cells
3. Gall bladder ( )	(c) Simple cuboidal
4. Bile duct ( )	(d) Stratified squamous
B. <i>Cells of fundic glands</i>	<i>Secretion</i>
1. Mucous neck cells ( )	(a) Enteroglucagon
2. Oxyntic cells ( )	(b) Pepsinogen
3. Zymogenic cells ( )	(c) Hydrochloric acid
4. Enteroendocrine cells ( )	(d) Acid mucus

**Answers**

- II.** 1. Amylase      2. Vitamin B<sub>12</sub>      3. Lacteal      4. Glisson's capsule      5. Kupffer's cells  
 6. Diabetes mellitus      7. Simple columnar epithelium with microvilli      8. Space of Disse  
 9. Ameloblasts      10. Brunner's gland
- III.** 1. b    2. c    3. b    4. c    5. d    6. c    7. a    8. c    9. b    10. a
- IV.** 1. (T)    2. (F)    3. (F)    4. (T)    5. (T)    6 (T)    7. (F)    8. (T)    9. (T)    10. (F)
- V.** A. 1. b    2. d    3. a    4. c  
 B. 1. d    2. c    3. b    4. a

# Practical No. 12.I

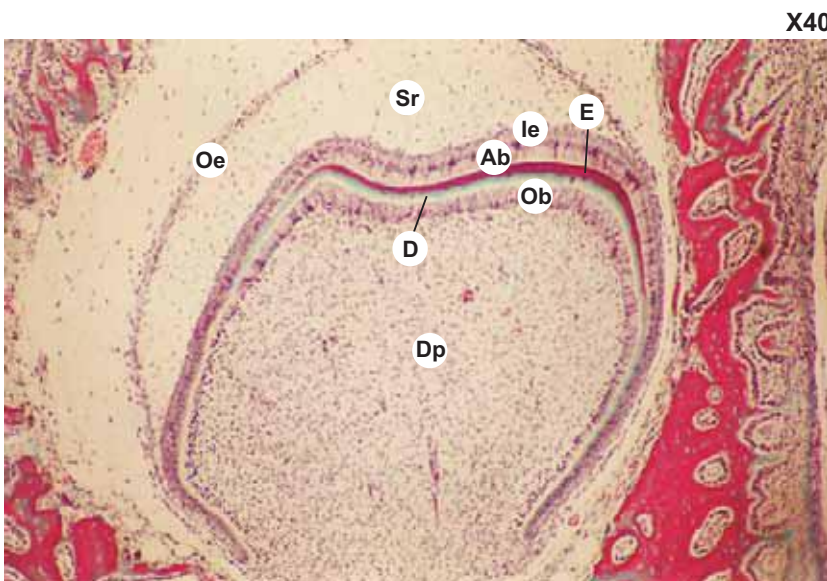
## Digestive System: Oral Cavity



### Plate 12.I:1 Dentogingival junction.

Examine a section of gingiva at the dentogingival junction (Plate 12.I:1) and identify the following features:

- Thick gingival epithelium (**Ge**) of stratified squamous variety on the oral surface of gingiva.
- Note the basal surface of the epithelium is deeply indented by the underlying lamina propria (**Lp**).
- When this epithelium is traced distally it becomes continuous with sulcular epithelium (**Se**) at the free gingival margin called gingival crest (**Gc**).
- Sulcular epithelium is separated from the enamel of tooth by gingival sulcus (**Gs**).
- The sulcular epithelium is less thick and the connective tissue papillae are shallower when compared to gingival epithelium.
- Note that the sulcular epithelium becomes junctional epithelium (**Je**) as it approach the cementum (**C**). It is thin and firmly attached to the tooth. (In this section it is detached from the tooth: an artifact.)



### Plate 12.I:2 Developing tooth.

Examine a section of developing tooth (Plate 12.I:2) under low power and identify the following features in the bell-shaped enamel organ.

- Outer enamel epithelium (**Oe**) of simple cuboidal variety.
- Stellate reticulum (**Sr**).
- Intermediate enamel epithelium (**Ie**) of flattened cells (2 or 3 layers).
- Inner enamel epithelium of columnar ameloblastic cells (**Ab**).
- Enamel (**E**) produced by ameloblasts.

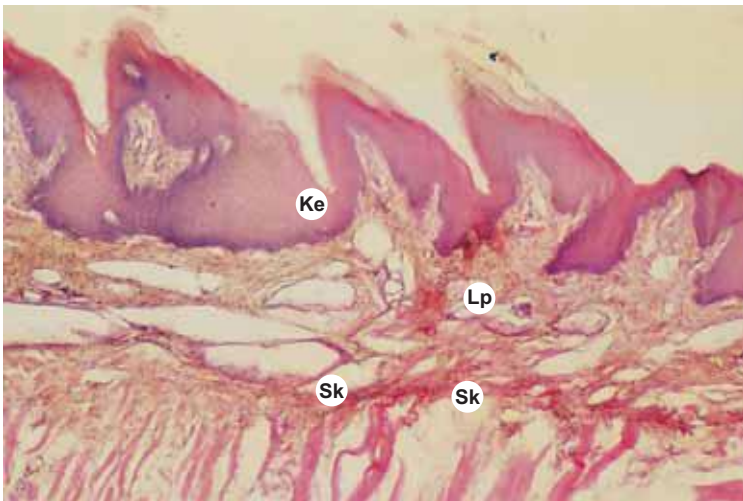
Note the condensed mesenchyme, the dental papilla (**Dp**) deep to the enamel organ and the columnar odontoblastic cells (**Ob**) differentiated from the dental papilla. These odontoblasts are responsible for the production of dentin (**D**).

**Plate 12.1:3 Lip.**

Examine a section of lip under low magnification (see Box 12.1) and note the following features:

- The external surface is covered by thin hairy skin with stratified squamous keratinized epithelium of the epidermis.
- The internal surface is lined by thick nonkeratinized stratified squamous epithelium indented by deep vascular connective tissue papillae.
- The intermediate transition zone (*vermilion border*) is lined by partially keratinized epidermis and the dermis containing no skin glands.
- The central core is made of skeletal muscle (*orbicularis oris*) cut cross-wise.
- Labial gland (*mixed* – predominantly mucous) are seen in the submucosa.

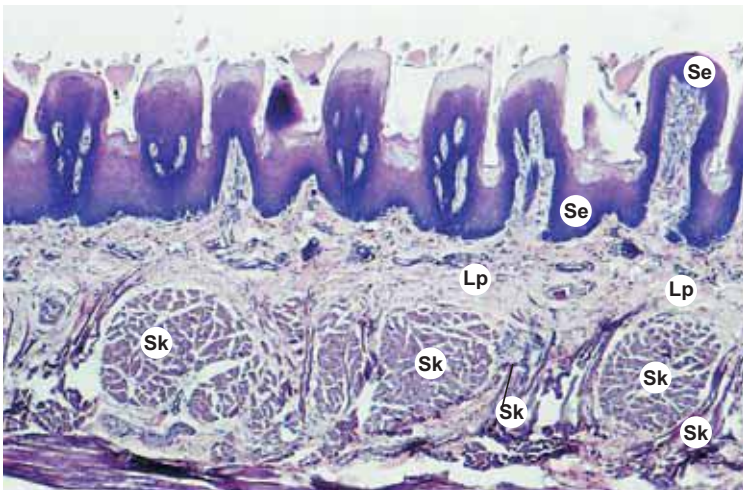
X40


**Plate 12.1:4 Tongue: Filiform papillae.**

Examine a section of tongue showing filiform papillae (Plate 12.1:4) under low power and appreciate the following salient features:

- Note the conical shape of the papillae lined by partly keratinized stratified squamous epithelium (**Ke**).
- No taste buds are found in them.
- Below the lamina propria (**Lp**) skeletal muscles (**Sk**) can be seen.

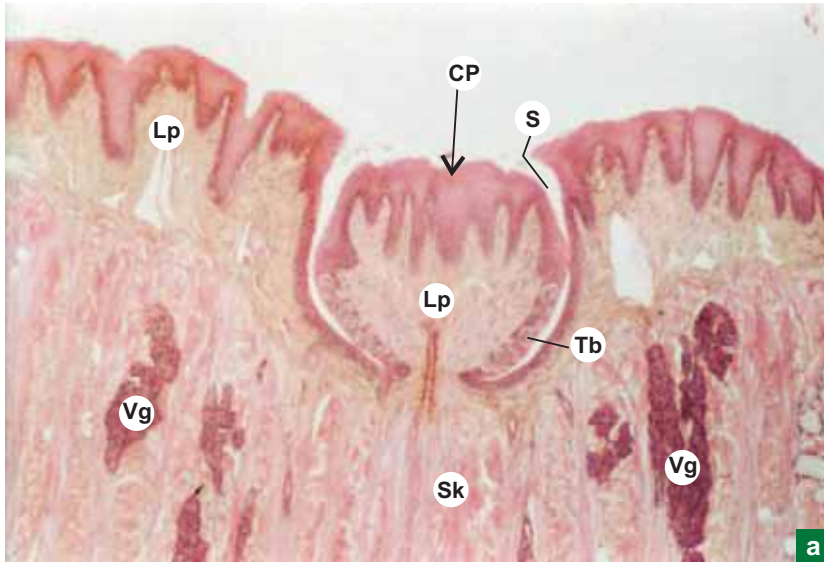
X40


**Plate 12.1:5 Tongue: Fungiform papillae.**

Examine a section of tongue showing fungiform papillae (Plate 12.1:5) under low power and appreciate the following salient features:

- Note the round mushroom shape of the papillae lined by stratified squamous epithelium (**Se**).
- Secondary connective tissue papillae are seen on all sides.
- Taste buds may be seen on the top surface.
- Below the lamina propria (**Lp**) skeletal muscles (**Sk**) can be seen cut at different planes.

X10



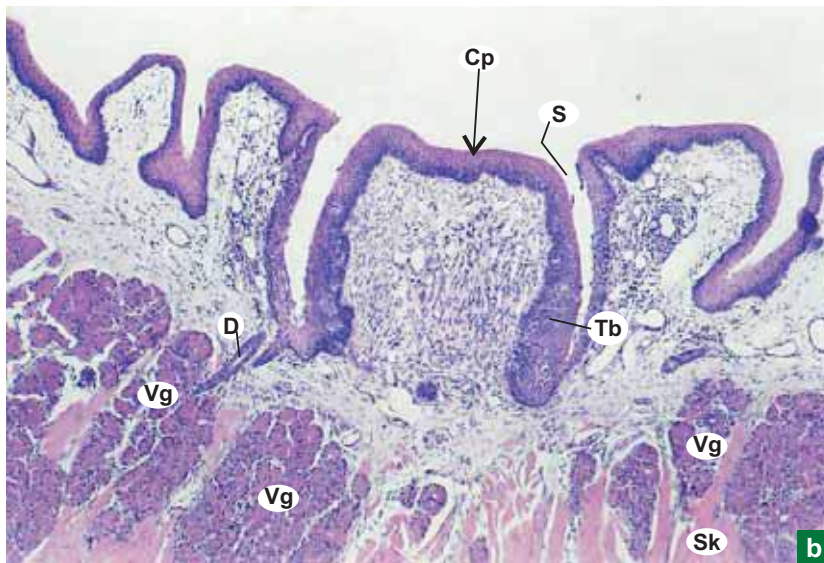
a

**Plate 12.1:6 Tongue: Circumvallate papillae a and b**

Examine a section of Tongue showing circumvallate papilla (Plate 12.1:6a and b) under low power and note the following salient features:

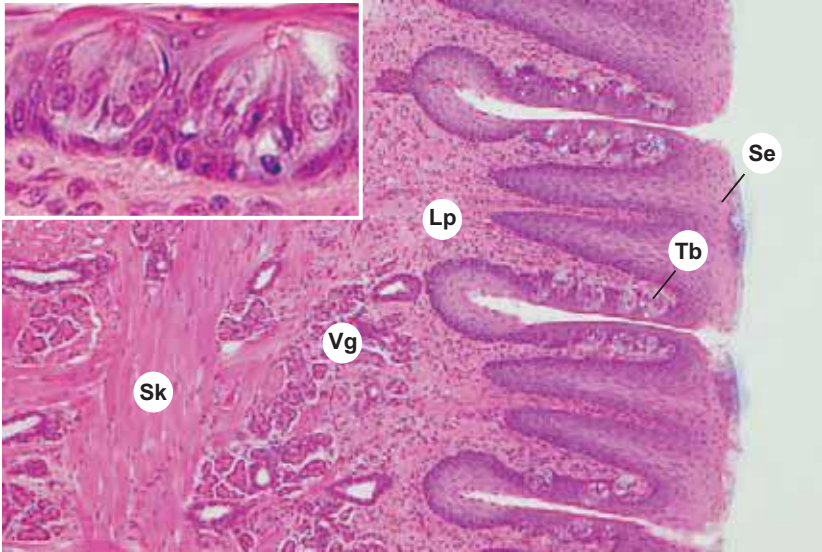
- Inverted cone-shaped sunken papillae (**arrow**) (Cp).
- Deep sulcus (S) or *furrow* around the papilla.
- Oval lightly stained *taste buds* (Tb) are seen on the lateral wall.
- *von Ebner's glands* (Vg; serous) are seen among the skeletal muscle fibres (Sk) cut at different planes. The duct of the gland (D) may be seen opening into the sulcus.

X40



b

X100


**Plate 12.I:7 Tongue: Foliate papillae (Inset: Taste bud).**

Examine a section of tongue showing foliate papillae (Plate 12.I:7) and note the following features:

- Cylindrical shape of the papillae, lined by stratified squamous epithelium (Se).
- Taste buds on the lateral wall.
- Serous glands (Vg) among the selected muscle fibres (Sk) cut at different planes.

Examine a taste bud (inset) under high power either in the circumvallate papilla, or in the foliate papilla which appears as a lightly stained oval body embedded in the stratified squamous epithelium (Se) forming the lateral wall.

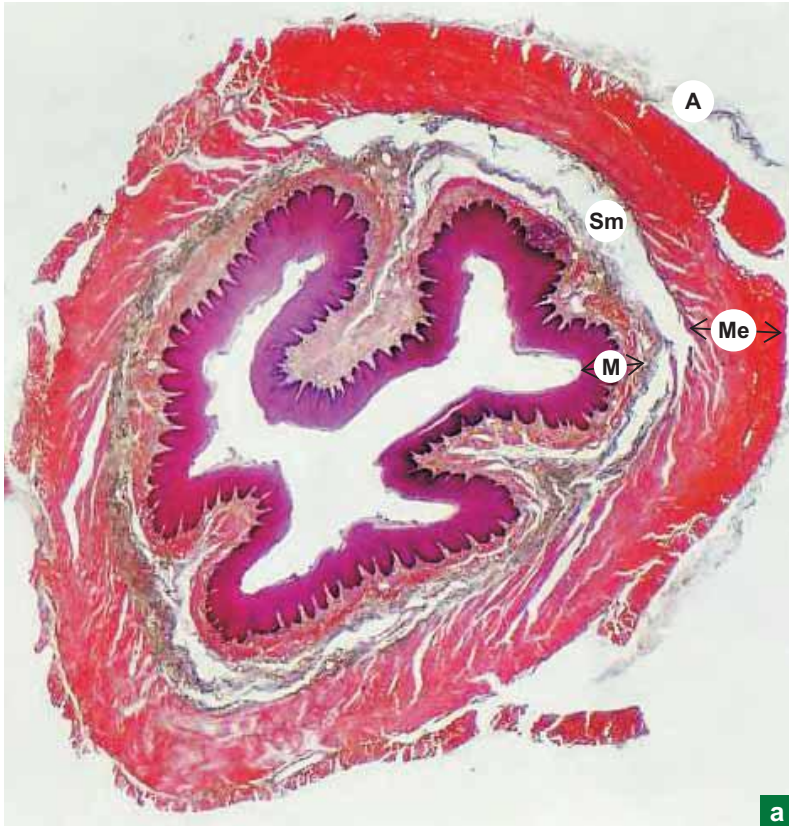
At high magnification (inset), identify the taste pore and the following cell types in the taste bud:

- Spindle-shaped dark cells – sustentacular cells.
- Spindle-shaped light cells – gustatory (taste) cells.
- Conical-shaped basal cells – stem cells.

# Practical No. 12.II

## Digestive System: Oesophagus and Stomach

X10



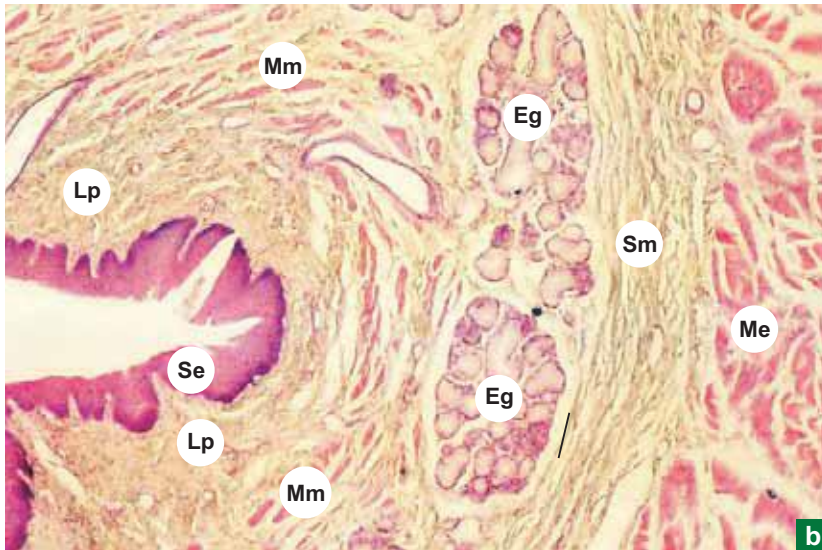
### Plate 12.II:1a Oesophagus (panoramic view).

Under scanner (Plate 12.II:1a) identify the four basic coats of the digestive tract by moving the slide.

From inner to outer these are:

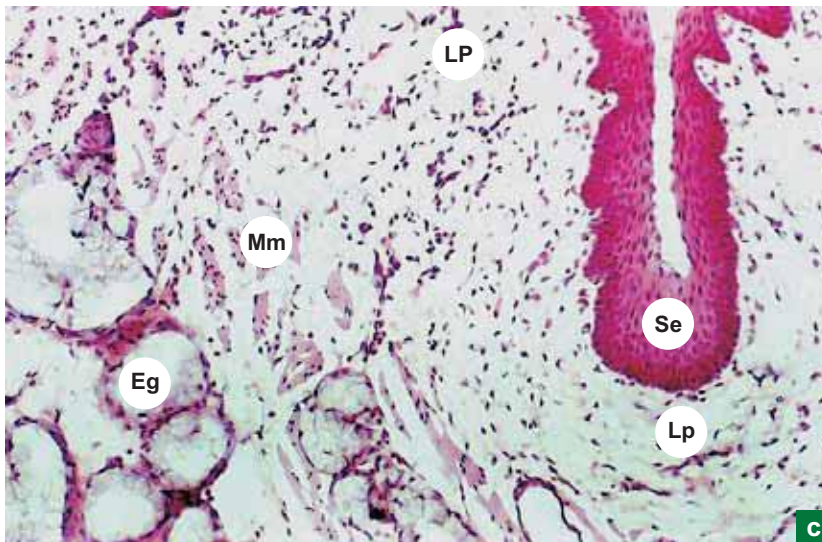
- Mucosa (M).
- Submucosa (Sm).
- Muscularis externa (Me).
- Adventitia (A).

X40



b

X200



c

**Plate 12.II:1  
b and c**
**Oesophagus.**

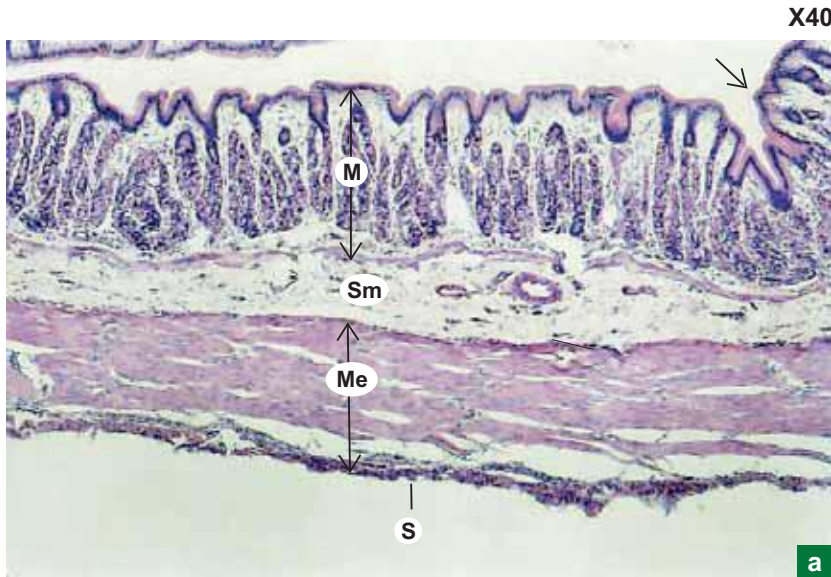
Note the following salient features of oesophagus at low and high magnifications (Plate 12.II:1b and c):

- *Stratified squamous epithelial lining (Se)*, supported by lamina propria (**Lp**).
- Well defined muscularis mucosa (**Mm**) (single layer of smooth muscle longitudinally oriented).
- *Oesophageal glands (Eg)* (mucous) in the submucosa (**Sm**).

Observe the type of muscle present in the muscularis externa (**Me**). Depending upon the region of oesophagus sectioned, it will be

- Skeletal muscle – in upper one-third part.
- Skeletal and smooth muscles – in middle one-third part.
- Smooth muscle – in lower one-third part.





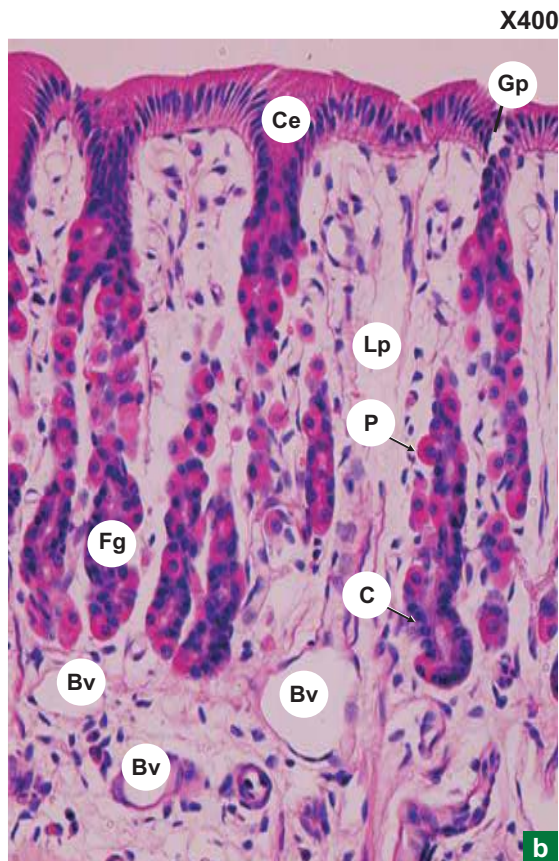
### Plate 12.II:2a Stomach: Fundus

At low magnification (Plate 12.II:2a), identify the four coats:

- Mucosa (M).
- Submucosa (Sm).
- Muscularis externa (Me).
- Serosa (S).

Note the folds of mucosa (rugae) (arrow) involving submucosa.

In muscularis externa, three layers of smooth muscle (inner oblique, middle circular, outer longitudinal) can be identified.



### Plate 12.II:2b Stomach: Mucosa of fundus.

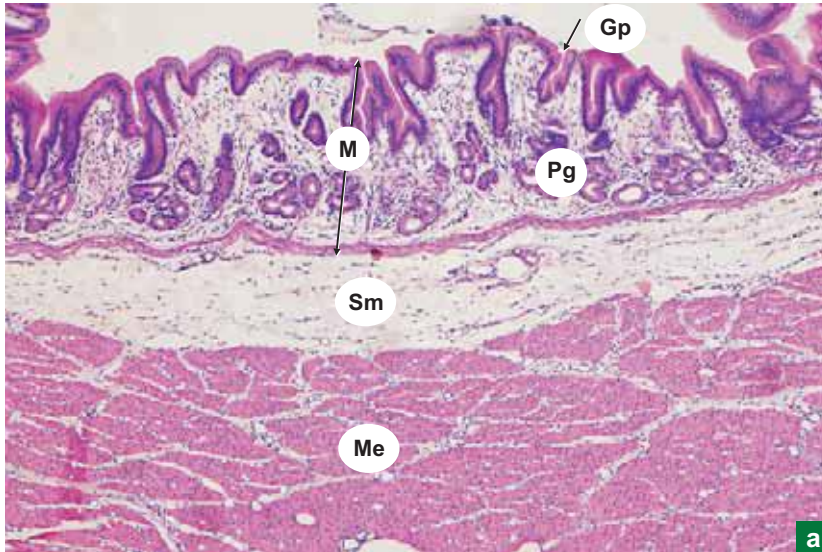
Note the following salient features in the mucosa of fundus at high magnification (Plate 12.II:2b):

- Shallow gastric pits (Gp) lined by simple columnar epithelium (Ce) (mucus secreting in nature).
- Tubular fundic glands (Fg) in the lamina propria (Lp) arranged perpendicular to the surface.

In the fundic gland, identify the following cell types:

- Mucous neck cells – lightly stained cells in the neck of the gland.
- Parietal (oxyntic) cells – large eosinophilic cells (P).
- Chief (zymogenic) cells – small basophilic cells (C).
- Enteroendocrine cells – not visible as they require special staining.

X40


**Plate 12.II:3  
a and b**
**Stomach.  
a. Pylorus.  
b. Mucosa of pylorus.**

At magnification x40 (Plate 12.II:3a) identify the four coats:

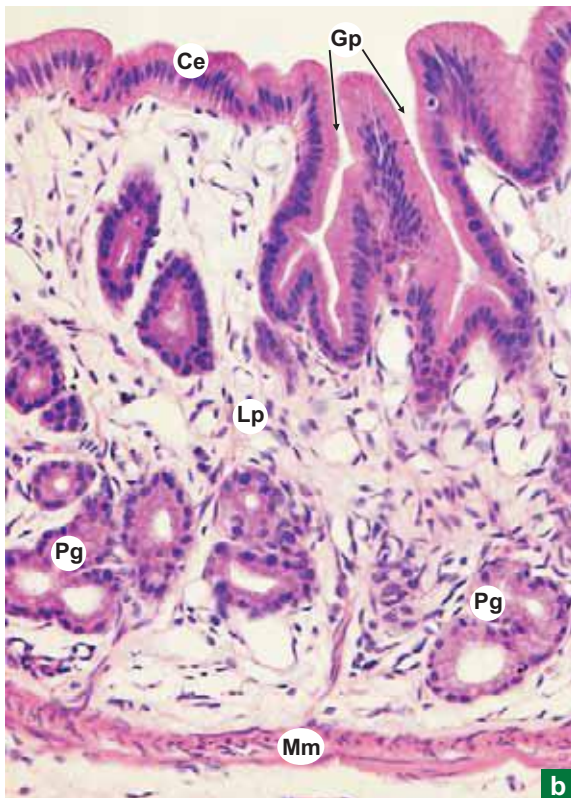
- Mucosa (M).
- Submucosa (Sm).
- Muscularis externa (Me).
- Serosa (S).

Identify the thickening of the circular layer of muscularis externa to form pyloric sphincter (Ps).

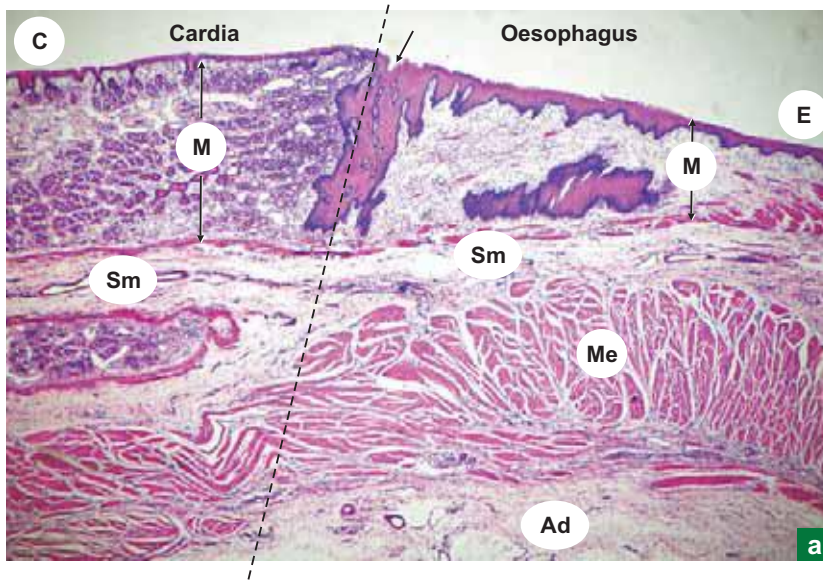
Note the following salient features in the mucosa of pylorus at higher magnification (Plate 12.II:3b):

- *Deep gastric pits (Gp)* lined by simple columnar epithelium (Ce).
  - Branched tubular *pyloric glands (Pg)* in the lamina propria (Lp); they are mucous secreting in nature.
- Mm = muscularis mucosa.

X200



X10

**Plate 12.II:4  
a and b**

**a. Cardio-oesophageal junction (panoramic view).**  
**b. Mucosa at the cardio-oesophageal junction.**

Scan the entire slide from one end to the other (Plate 12.II:4a) and identify the various coats:

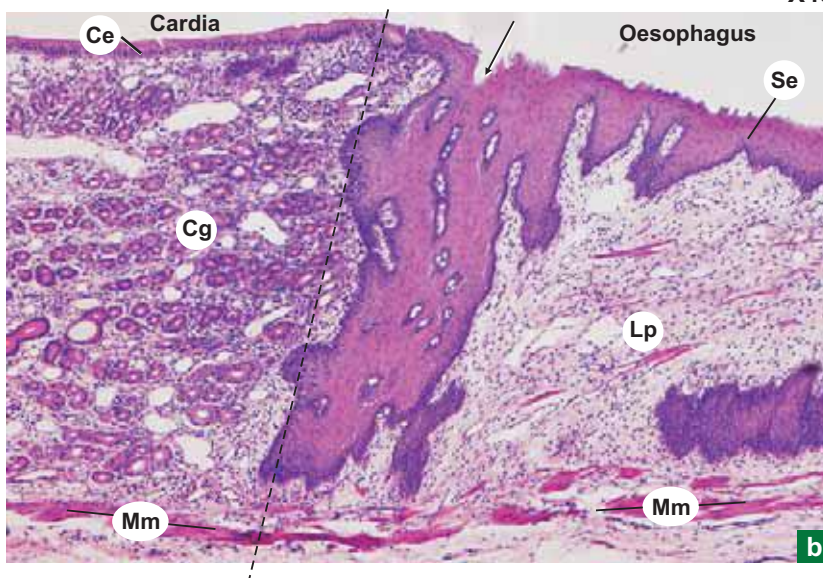
- Mucosa (M).
- Submucosa (Sm).
- Muscularis externa (Me).
- Adventitia (Ad).

Examine the oesophageal end (E) of the slide and appreciate its salient features. Slowly move the slide towards the cardiac part (C) of the stomach and identify the cardio-oesophageal junction (arrow).

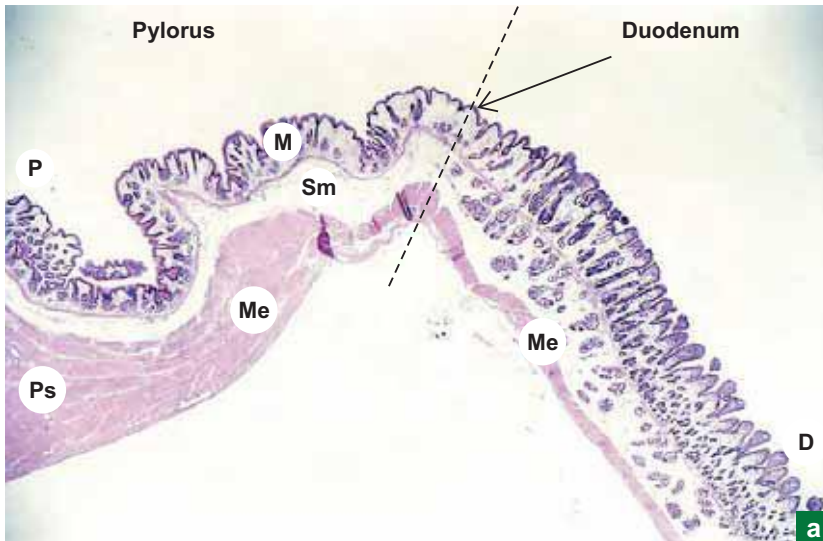
Examine the mucosa at the junction (arrow) and appreciate the following changes (Plate 12.II:4b):

- Stratified squamous epithelium (Se) of oesophagus abruptly changes into tall columnar epithelium (Ce) lining the gastric pits (Gp) of stomach.
- Appearance of oesophageal cardiac glands (not seen) in the lamina propria (Lp) of oesophagus.
- Appearance of cardiac glands (Cg) in the lamina propria (Lp) of stomach.
- Muscularis mucosa (Mm) becomes double layer of smooth muscle in the stomach.

X40



X10


**Plate 12.II:5  
a and b**

**a. Pyloroduodenal junction (panoramic view).**  
**b. Pyloroduodenal junction.**

Scan the entire slide from one end to the other (Plate 12.II:5a) and identify the various coats:

- Mucosa (M).
- Submucosa (Sm).
- Muscularis externa (Me).

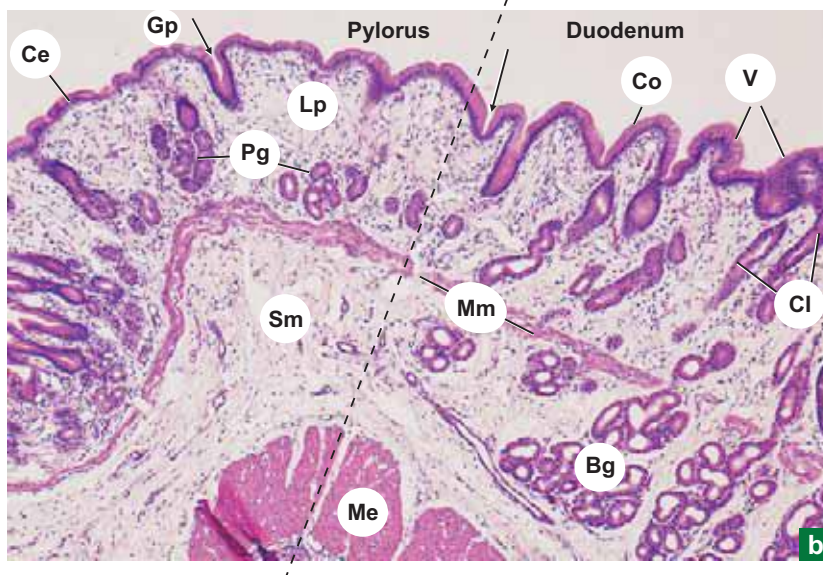
Examine the pyloric part (P) of the slide and appreciate its salient features especially the thickening of muscularis externa (Me) to form pyloric sphincter (Ps).

Slowly move the slide towards the duodenal part (D) of the slide and identify the pyloroduodenal junction (arrow).

Examine the mucosa and submucosa at the junction (arrow) and appreciate the following changes (Plate 12.II:5b).

- Simple tall columnar secretory epithelium (Ce) lining the gastric pits (Gp) of stomach changes into absorptive columnar epithelium (Co) of intestine with goblet cells.
- Appearance of leaf-like villi (V) makes the luminal surface uneven.
- Appearance of crypts of Lieberkuhn (Cl) in the lamina propria (Lp).
- Disruption of muscularis mucosa (Mm).
- Appearance of Brunner's gland (Bg) in the submucosa (Sm) of duodenum.

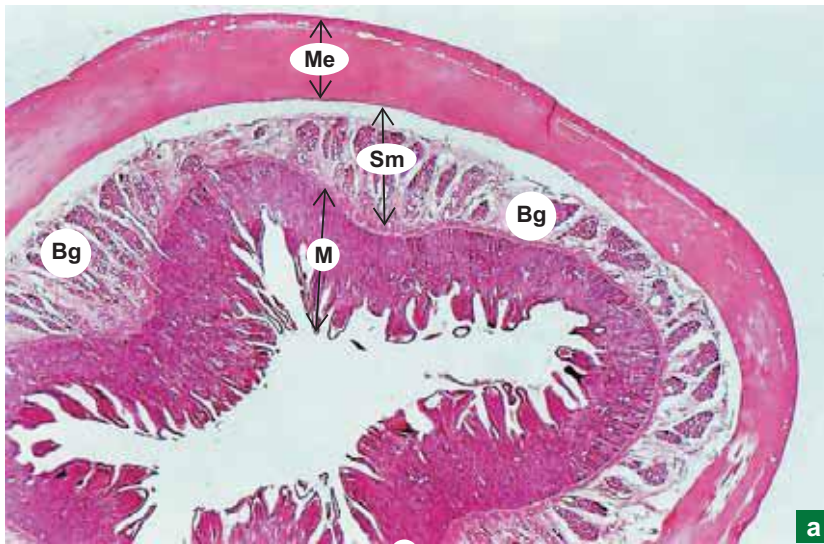
X40



# Practical No. 12.III

## Digestive System: Intestine

X10



a

**Plate 12.III:1**  
**a and b**

**Duodenum.**

**a. Panoramic view.**  
**b. Mucosa and sub-**  
**mucosa).**

Under the scanner examine the entire section and identify the four basic coats (Plate 12.III:1a):

- Mucosa (M).
- Submucosa (Sm).
- Muscularis externa (Me).
- Serosa (S) or adventitia.

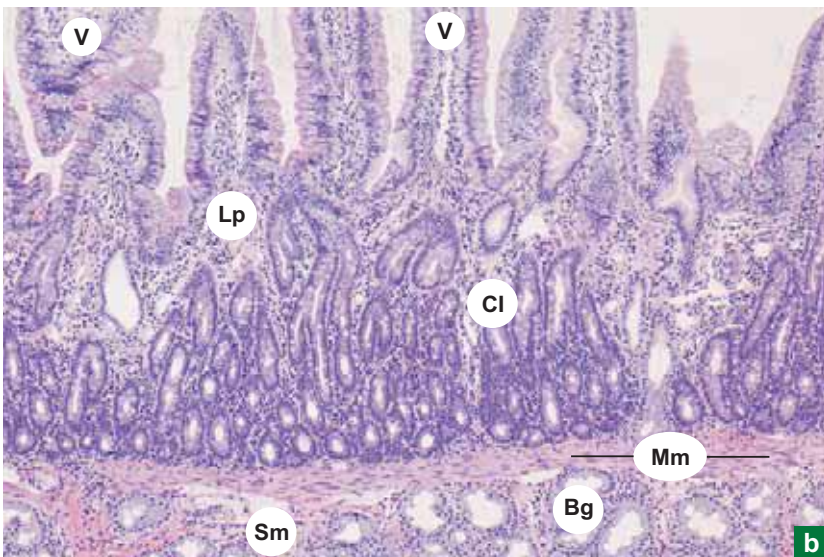
Note the groups of Brunner's glands (Bg) in the submucosa (Sm) (Plate 12.III:1a).

Now examine the mucosa (Plate 12.III:1b) which is characterised by the presence of following features:

- Numerous leaf-like projections called *villi* (V).
- Tubular intestinal glands called crypts of *Lieberkuhn* (Cl) in the lamina propria (Lp) reaching the muscularis mucosa (Mm).
- Simple *columnar absorptive type of epithelium* with striated border (due to microvilli) lining the villus.
- Goblet cells are interspersed among the columnar cells.
- The central core of the villus is filled with lamina propria containing blood capillaries, lymphatic vessels (lacteal) and occasional smooth muscle cells derived from muscularis mucosa.

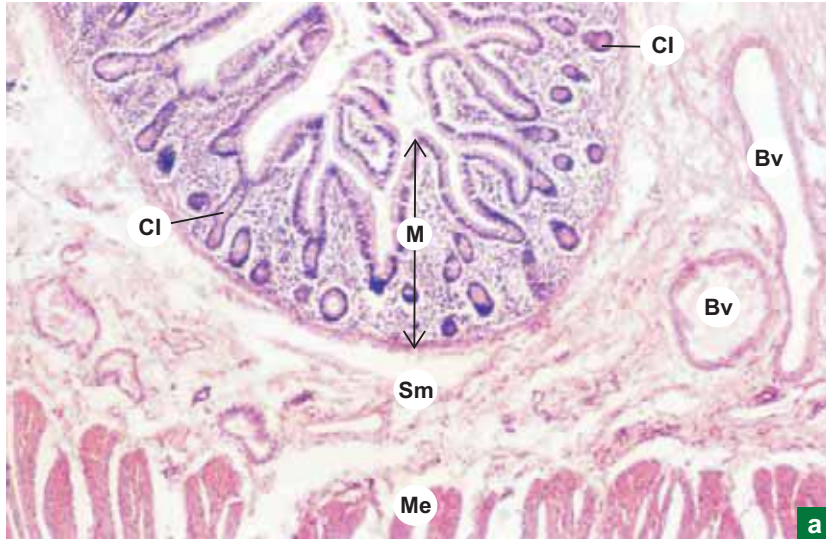
The submucosa (Sm) contains *Brunner's glands* (Bg), which is a unique feature of duodenum and are absent in the rest of the small and large intestines.

X100



b

X40

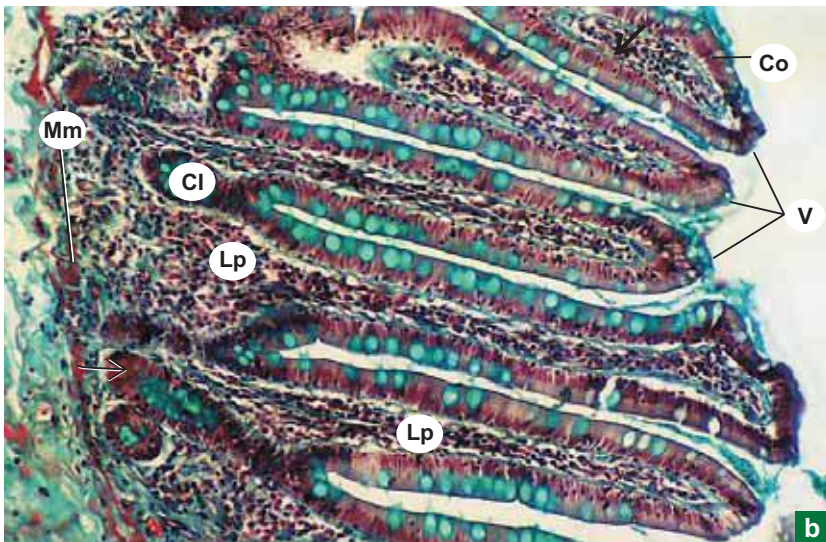

**Plate 12.III:2** a. Jejunum.  
 a and b b. Mucosa of jejunum.

Examine the slide at low magnification (Plate 12.III:2a) and identify the four basic coats, namely:

- Mucosa (M).
- Submucosa (Sm).
- Muscularis externa (Me).
- Serosa.

The submucosa (Sm) is devoid of glands and Peyer's patches. It contains loose areolar connective tissue and blood vessels (Bv).

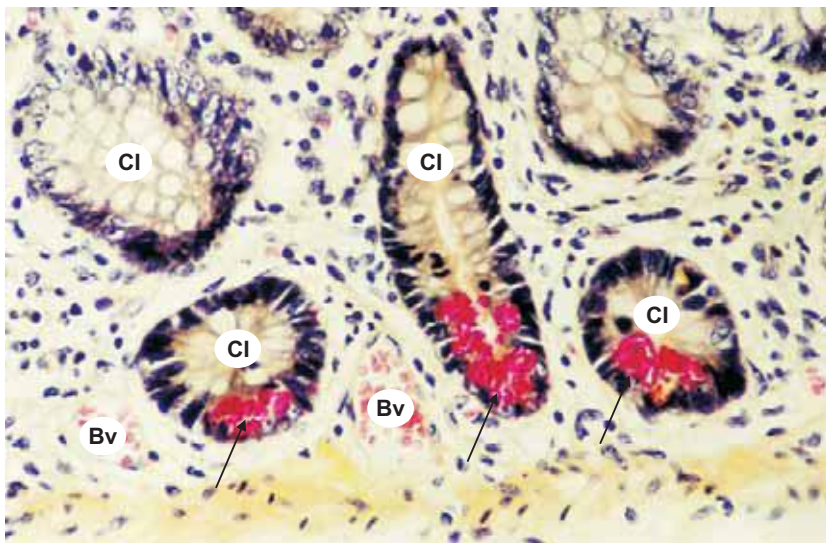
X100



Examine the mucosa under higher power (Plate 12.III:2b) which exhibits the typical features of small intestine:

- Long finger-like villi (V) lined by simple columnar epithelium (Co) with striated border and goblet cells (green).
- Lamina propria (Lp) containing crypts of Lieberkuhn (Cl).
- At the base of the crypt close to the muscularis mucosa (Mm), identify the Paneth cells (arrow) which are large pyramidal cells with acidophilic granules in the cytoplasm.

X200

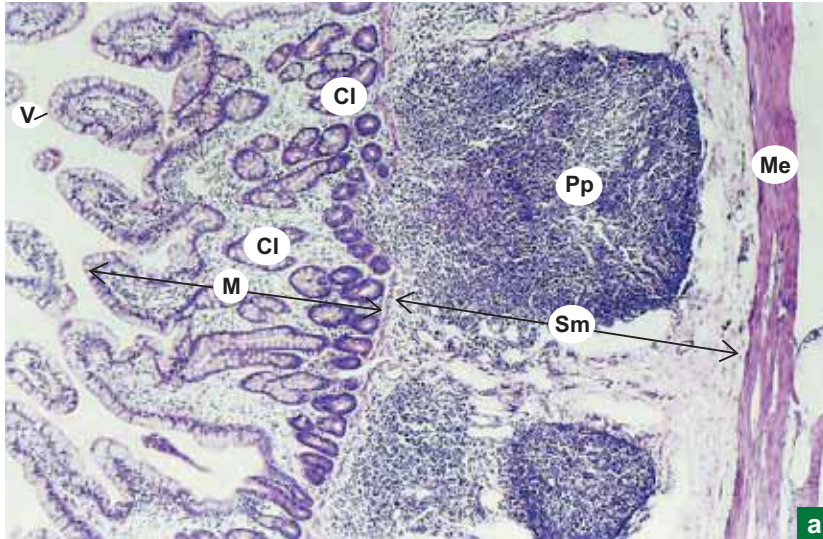

**Plate 12.III:3** Paneth cells.

Examine the crypts of Lieberkuhn (Cl) of jejunum at high magnification (Plate 12.III:3).

At the bases of crypts note the large pyramidal-shaped Paneth cells (arrow) with acidophilic secretory granules. These granules contain antimicrobial substances like defensins and lysozyme.

Bv = blood vessels.

X40



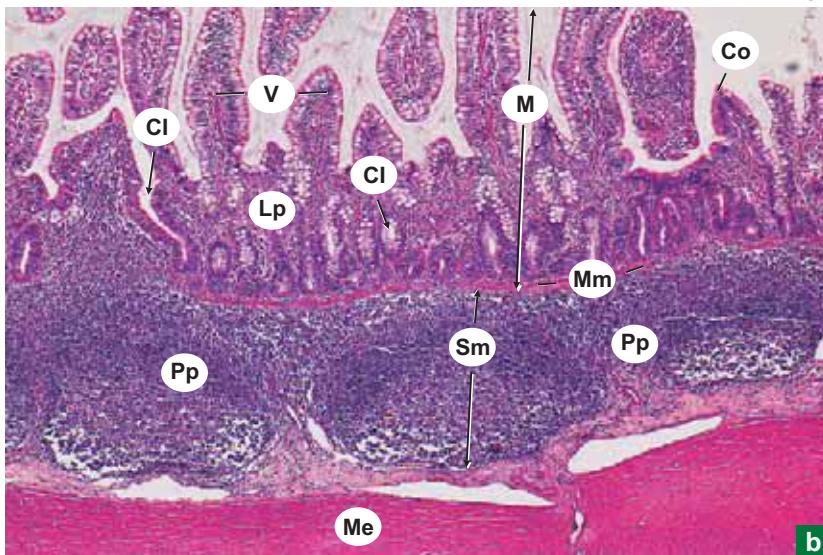
a

**Plate 12.III:4 ileum.  
a and b**

Scan a section of ileum at low and high magnifications (Plate 12.III:4a, b and c) and identify the four basic coats, namely:

- Mucosa (M).
- Submucosa (Sm).
- Muscularis externa (Me).
- Serosa.

X100

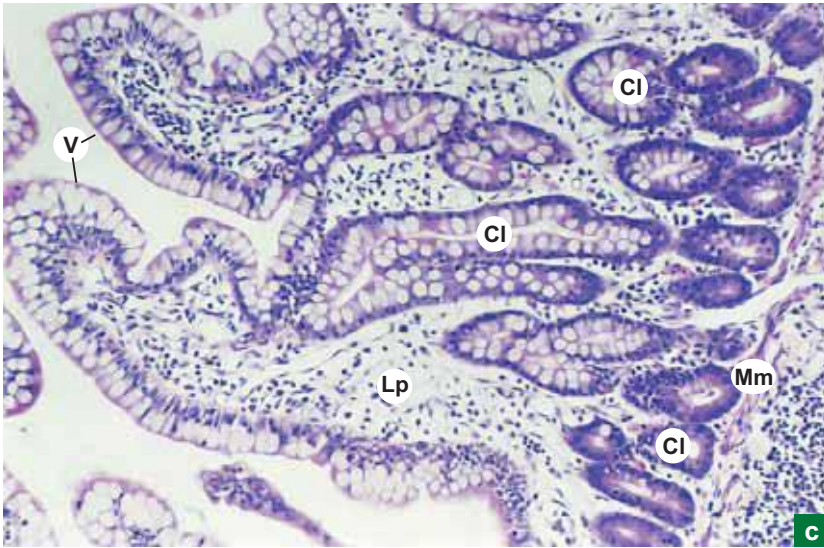


b

The submucosa (Sm) contains aggregation of lymphoid follicles called *Peyer's patches* (Pp) which is a unique feature of ileum.

The muscularis mucosa (Mm) is often disrupted due to the penetration of Peyer's patches into the lamina propria, where crypts of Lieberkuhn (Cl) are seen.

X100



**Plate 12.III:4  
c and d**

**c. Mucosa of ileum.  
d(i) and (ii) Intestinal  
villus.**

Examine the mucosa of ileum (Plate 12.III:4c) and note the following features:

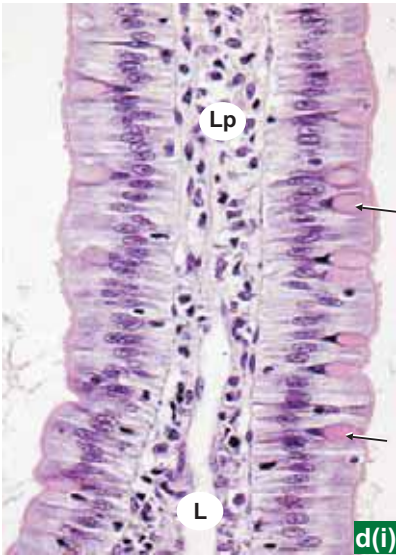
- Short villi.
- Crypts of *Lieberkuhn* (Cl) cut at different planes.
- Muscularis mucosa (Mm).

Examine the L.S. and C.S. of intestinal villi at high magnification (Plate 12.III:4d).

The villi (V) are lined by simple columnar epithelium with goblet cells (arrows) interspersed among the columnar cells. The lamina propria (Lp) contains lacteal (L) and blood capillaries.

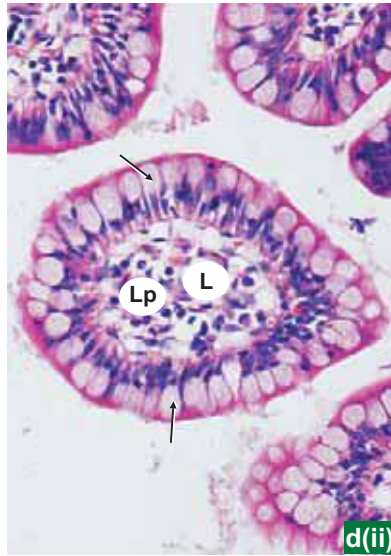
Note the increase in the number of goblet cells as compared to jejunum and duodenum.

L.S.



C.S.

X400

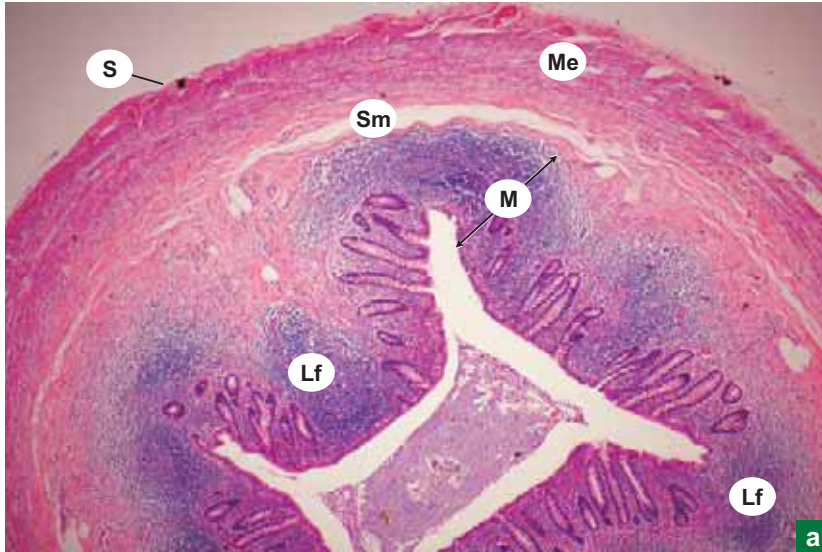


d(i)

d(ii)



X40



**Plate 12.III:5** a. Vermiform appendix (panoramic view).  
b. Vermiform appendix.

Scan the entire section and identify the four basic coats as in Plate 12.III:5a:

- Mucosa (M).
- Submucosa (Sm).
- Muscularis externa (Me).
- Serosa (S).

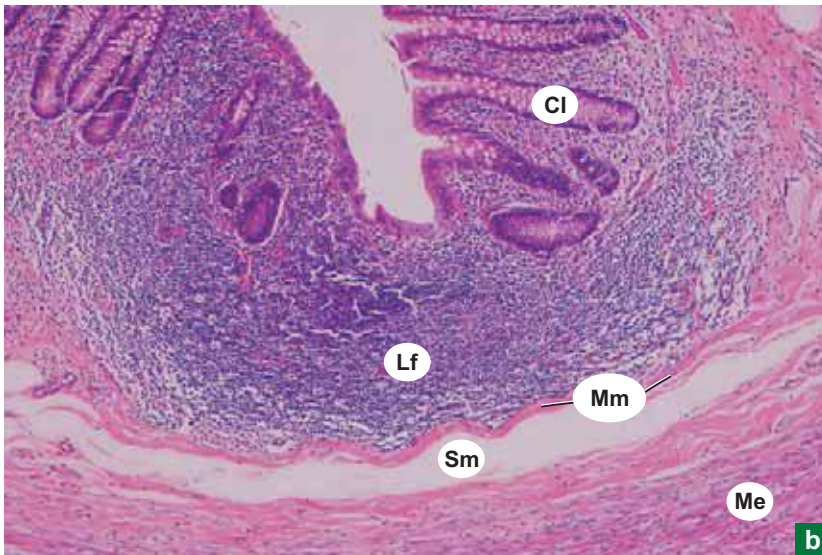Appreciate the following salient features:

- *Small angular lumen* compared to the thick wall.
- *Ring of lymphoid follicles (Lf)* around the lumen in the lamina propria.

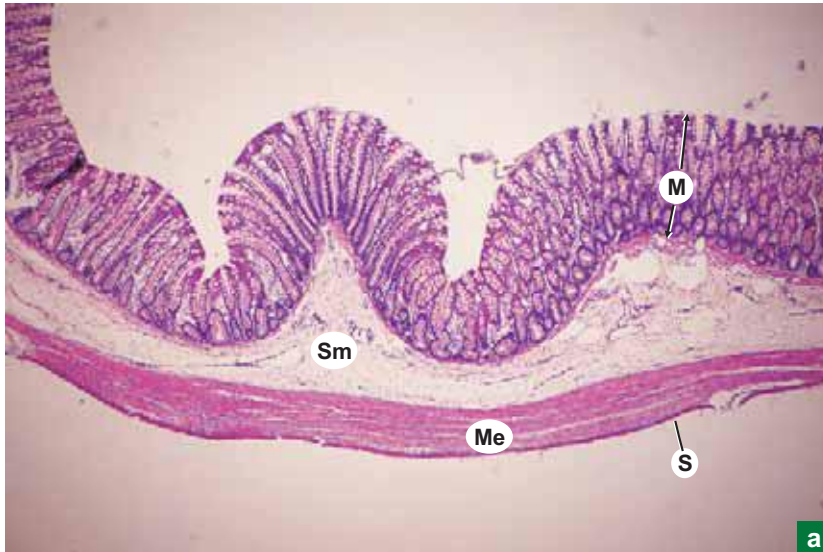
Identify the following structures at low magnification (Plate 12.III:5b):

- Few crypts of *Lieberkuhn (Cl)*.
- *Lymphoid follicle (Lf)* with germinal centre.
- *Absence of villi*.
- *Disrupted muscularis mucosa (Mm)*.

X100



X40



a

**Plate 12.III:6  
a and b**
**a. Colon.  
b. Mucosa of colon.**

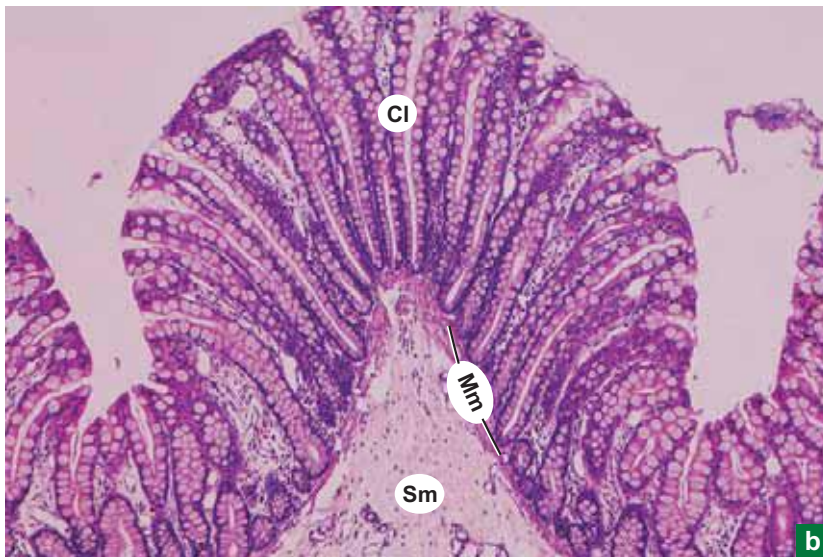
The wall of the large intestine (colon) contains the same four coats (Plate 12.III:6a), namely:

- Mucosa (M).
- Submucosa (Sm).
- Muscularis externa (Me).
- Serosa (S) or adventitia.

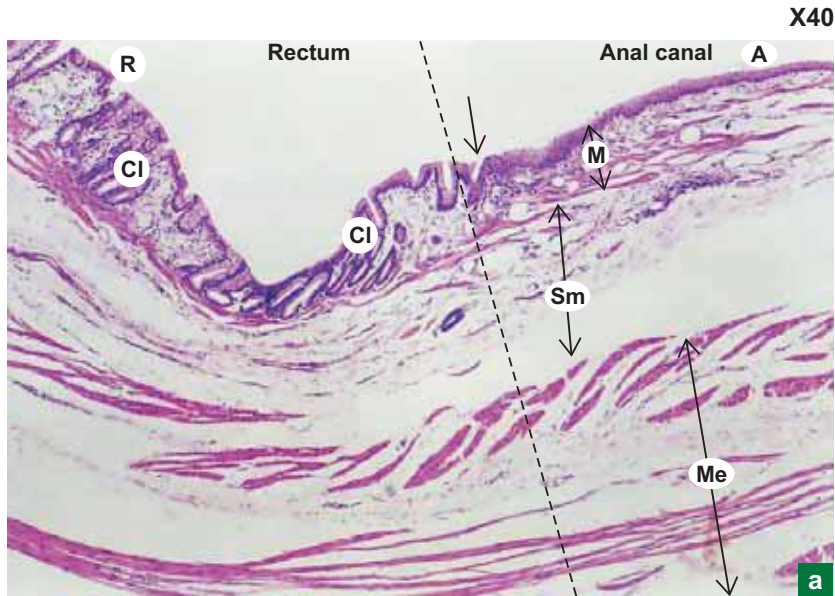
Appreciate the following salient features in the mucosa of colon (Plate 12.III:6b):

- Long uniform regularly arranged *crypts of Lieberkuhn* (Cl), in the entire thickness of mucosa.
  - *Absence of villi.*
  - Absence of Paneth cells in the crypt.
  - Well defined muscularis mucosa (Mm).
- Submucosa (Sm) consists of loose areolar connective tissue.

X100



b



**Plate 12.III:7**  
**a and b**  
**a. Recto-anal junction.**  
**b. Recto-anal junction (mucosa).**

Scan the entire slide from one end to the other (Plate 12.III:7a) and identify the various coats, namely:

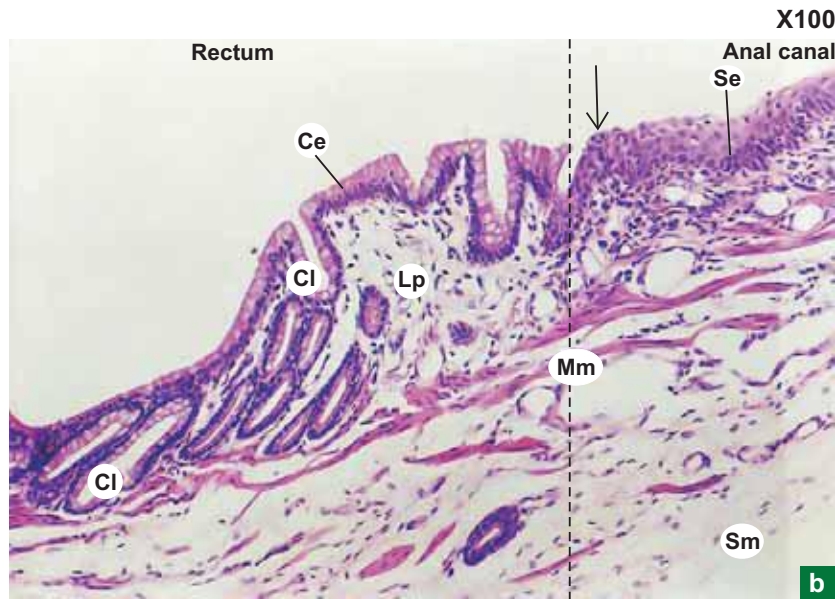
- Mucosa (M).
- Submucosa (Sm).
- Muscularis externa (Me).

Examine the mucosa (Plate 12.III:7b) at the rectal end (R) of the slide and appreciate its salient features. Slowly move the slide towards the anal end (A) and identify the recto-anal junction (arrow).

At this junction, the simple columnar epithelium (Ce) lining the rectum abruptly changes into stratified squamous epithelium (Se) lining the anal canal.

Note that the crypts of Lieberkuhn (Cl) present in the lamina propria (Lp) of rectum and are absent in the anal canal.

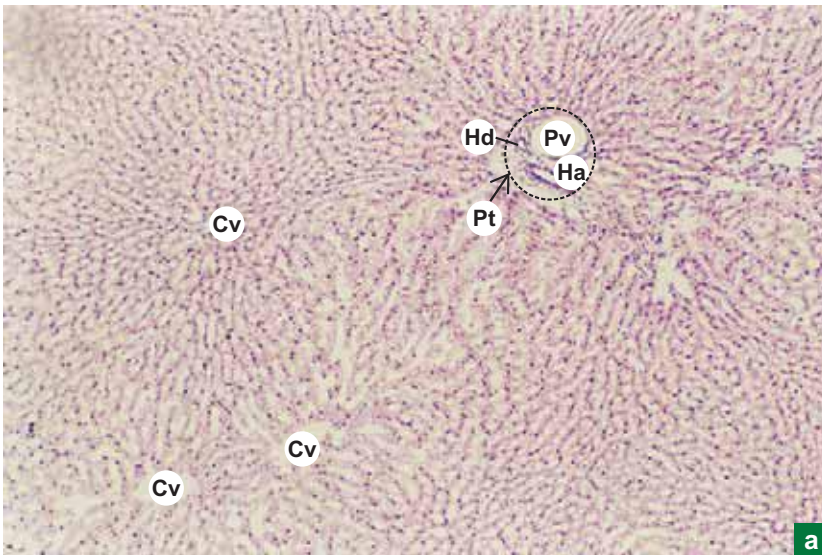
Mm = muscular mucosa.



# Practical No. 12.IV

## Digestive System: Glands

X40

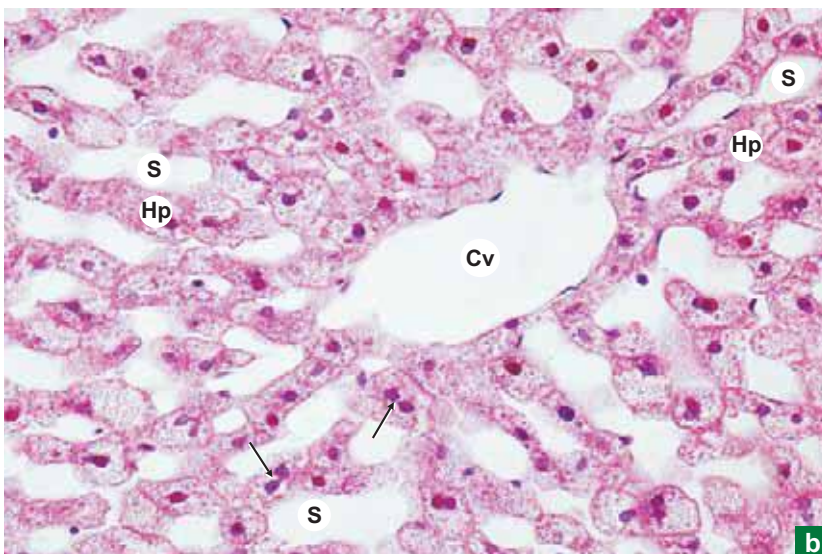


a

**Plate 12.IV:1** Liver.  
**a and b**

- At low magnifications (Plate. 12.IV:1a and c) identify the liver lobules which are roughly hexagonal in shape. Though the lobules are not delineated by interlobular connective tissue septae, the shape can be defined by drawing imaginary lines connecting the portal tracts (Pt) present at the angles of the lobules.
- Each portal tract contains three structures (Portal triad) namely branches of portal vein (Pv), hepatic artery (Ha) and hepatic ductule (Hd) supported by connective tissue.
- Identify the central vein (Cv) in the centre of the lobule and radiating plates of hepatocytes (Hp); darkly stained separated by sinusoids (S); lightly stained.
- At high magnification (Plate 12.IV:1b) identify the endothelium lined central vein (Cv) into which the sinusoids (S) drain. The sinusoids are also lined by discontinuous endothelium.

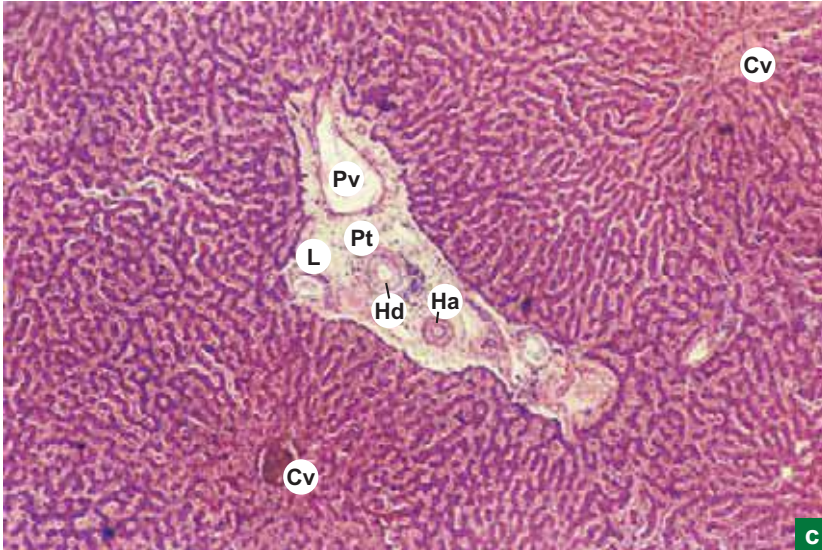
X400



b

(Contd.)

X40



**Plate 12.IV:1**  
c and d

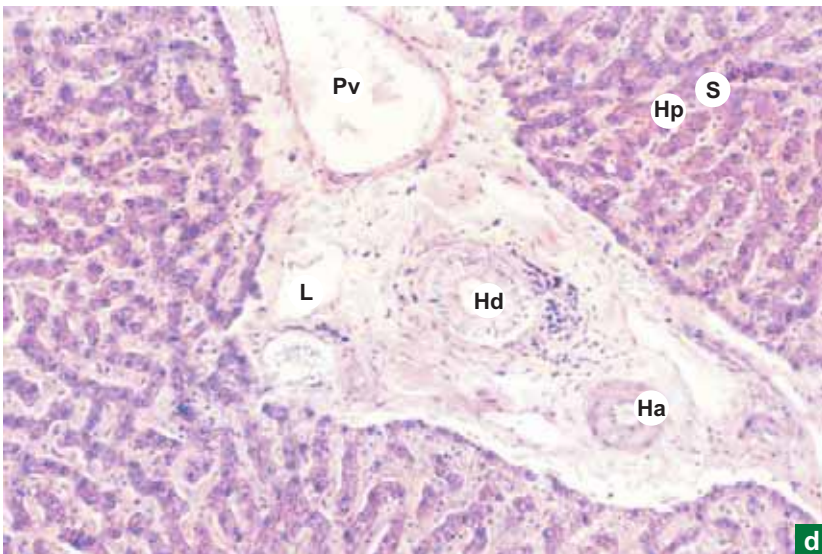
c. Liver.  
d. Liver (Portal tract).

(Contd.)

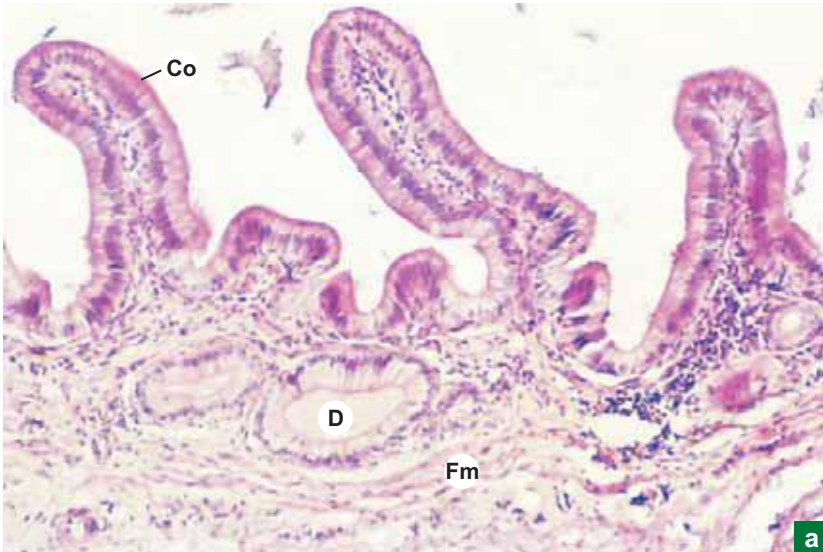
- Note the radiating cords of hepatocytes (**Hp**) from the central vein. Arrows indicate binucleated hepatocytes.
- Plate 12.IV:1d shows an enlarged view of the portal tract. Identify the three structures of portal triad separately. The hepatic ductule (**Hd**) can be identified by the lining epithelium which is cuboidal to low columnar epithelium, whereas the blood vessels (portal venule and hepatic arteriole) are lined by endothelium. Further, the portal venule (**Pv**) has got a thin wall and large collapsed lumen, and the hepatic arteriole (**Ha**) has a thick wall compared to small circular lumen.

L = lymph vessel.

X100



X100



a

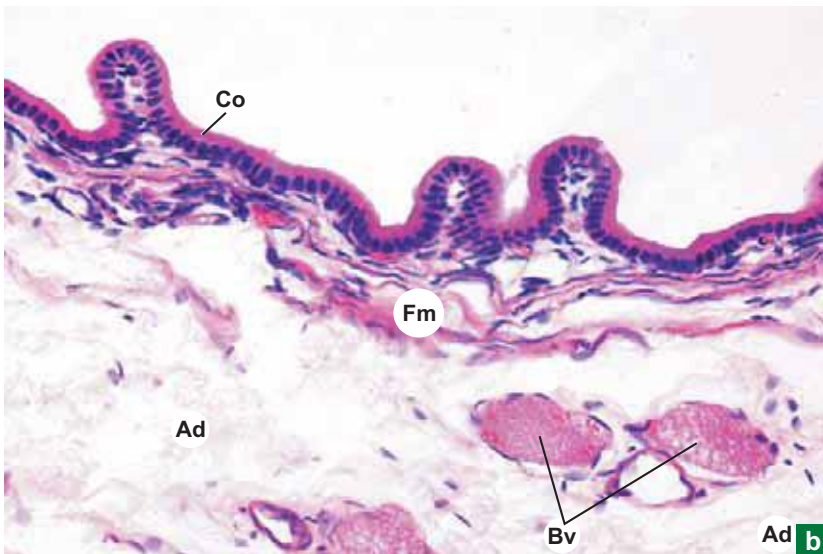
**Plate 12.IV:2 Gall bladder.  
a and b**

Note the following features in the sections of gall bladder (Plate 12.IV:2a and b):

- Mucosa is thrown into folds, which include the lining.
  - *Simple columnar epithelium* (Co).
  - Lamina propria, rich in elastic fibres and occasionally diverticulum (D) of the epithelium.
- Middle *fibromuscular layer* (Fm).
- Adventitia (Ad) forming the outer coat.

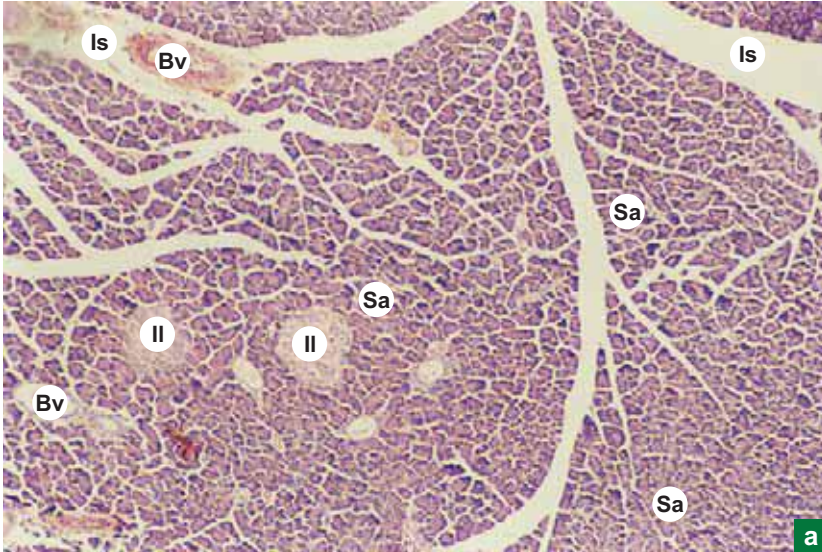
Bv = blood vessel.

X200



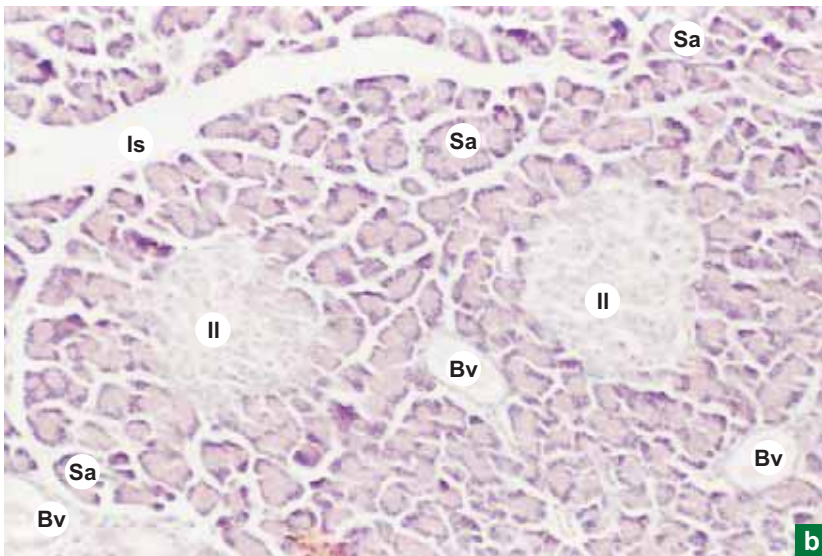
Ad b

X40



a

X100



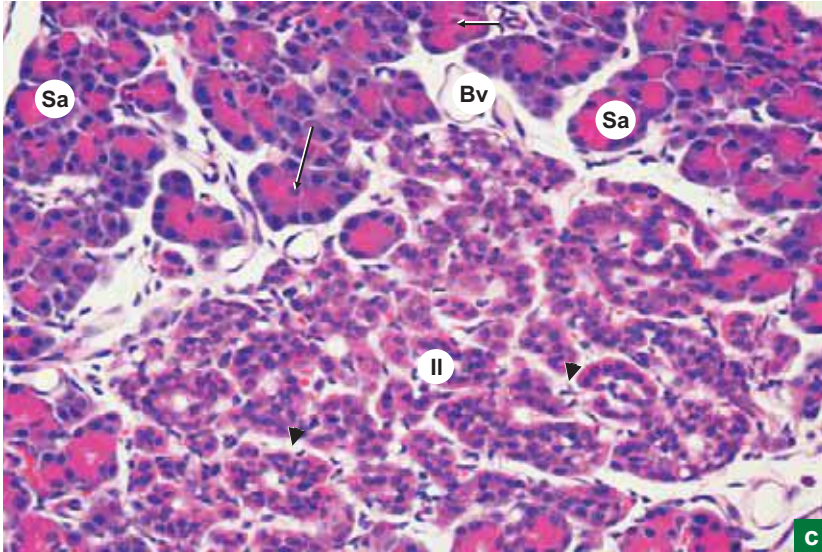
b

### Plate 12.IV:3a, Pancreas. b

Examine the section of pancreas under the scanner (Plate 12.IV:3a) and under low power (Plate 12.IV:3b) and identify the following features:

- Lobules separated by interlobular connective tissue septae (Is) containing blood vessel (Bv).
- Interlobular ducts (not seen).
- Darkly stained *serous acini* (Sa).
- Lightly stained *islet of Langerhans* (Il).

X400

**Plate 12.IV:3c** Pancreas.

Turn to high magnification (Plate 12.IV:3c) and examine a serous acinous (Sa) and an islet of Langerhans (Il). Look for following features:

- *Centroacinar cells* (**arrow**) in the lumen of serous acinus.
- Small basophilic cells in the centre of islet (Beta cells).
- Large acidophilic cells at the periphery (Alpha cells).
- Other cells of the islet may not be visible as they need special staining.

**Arrowheads** – capillaries; **Bv** – Blood vessel.

Compare the slide of pancreas with that of parotid salivary gland (Plate 3:2a and b) and note the differences. The pancreas differs from the parotid gland in the following features:

- Absence of striated (secretory) duct.
- Presence of islets of Langerhans.
- Presence of centroacinar cells.
- Absence of myoepithelial cells.



"This page intentionally left blank"

# 13

## URINARY SYSTEM

### INTRODUCTION

Urinary system consists of a pair of kidneys, a pair of ureters, urinary bladder and urethra. Kidneys are involved in the production of urine which is conveyed by the ureters to the urinary bladder, where it is stored for a short period and is voided through urethra during micturition.

### KIDNEY

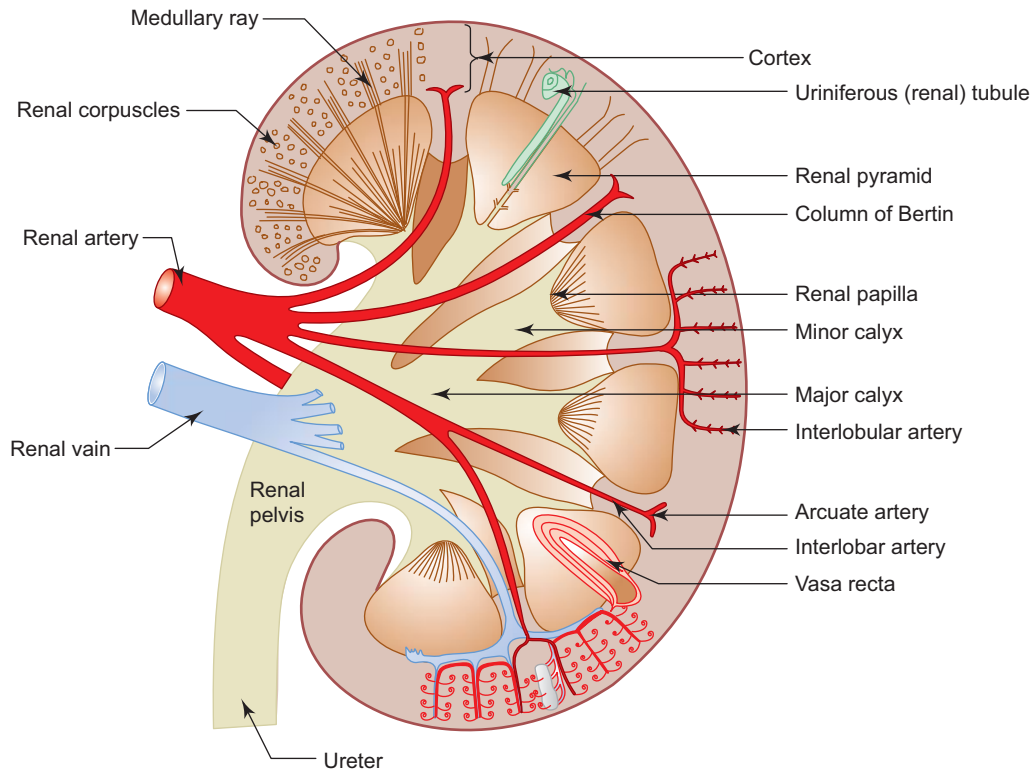
#### GENERAL FEATURES

- Each kidney is a large bean-shaped organ situated in the posterior abdominal wall behind the peritoneum.
- It measures 7.5 cm in length, 5 cm in breadth and 2.5 cm in thickness.
- Its medial concave border has hilum through which renal vessels and nerves pass.
- The chemical composition of urine reflects the important functions performed by the kidney. It
  - controls water and electrolyte balance in the body.
  - maintains acid base balance.
  - excretes many toxic metabolic waste products (nitrogen, urea and creatinine).
  - maintains blood pressure by *renin-angiotensin-aldosterone mechanism*.
  - stimulates RBC production in bone marrow through *erythropoietin*.
- Coverings:
  - Kidney is surrounded by a thin *fibrous capsule* which is adherent to the substance of the kidney.
  - External to it there is condensation of fatty tissue forming *perinephric pad of fat*, which is surrounded by a fascial sheath called the *renal fascia* (fascia of Gerota).

#### MACROSCOPIC FEATURES

A vertical section through the kidney reveals its gross internal features (Fig. 13.1):

- The hilum leads to a space called *renal sinus*, which contains, apart from branches of renal vessels and nerves, the pelvis of ureter and its subdivisions, namely, major calyces (2–3) and minor calyces (8–12).
- The substance of the kidney is divided into outer dark granular (reddish brown) zone, the *cortex* and an inner pale striated zone, the *medulla*.
- The medulla is formed by 8–12 *renal pyramids*. The bases of these pyramids face the cortex, whereas their apices (*renal papillae*) are directed towards the renal sinus where they are cupped by the minor calyces. The tip of each renal papilla is pierced by many *papillary ducts* (*ducts of Bellini*) opening into the minor calyx.
- From the base of pyramids, medullary tissue extends into the cortex as *medullary rays*.
- Similarly, cortical tissue extends between adjacent pyramids as *renal column of Bertin*.



**Fig. 13.1** Sagittal section of kidney.

### Lobes and Lobules

- A pyramid and the cortical tissue over its base is referred to as a *renal lobe*.
- A *renal lobule* is the one which has a medullary ray and the surrounding cortical tissue.

### Renal Circulation

The renal artery, after entering the sinus through the hilum divides into five *segmental branches*. These segmental branches divide to form *interlobar arteries* which run between the pyramids. On reaching the corticomedullary junction each interlobar artery bifurcates into *arcuate arteries* that run along the base of the pyramid in the corticomedullary junction. Along its course, the arcuate artery gives out a number of *interlobular arteries* at right angle to it which run outwards through the cortical tissue between the renal lobules. The interlobular arteries give off *afferent arterioles* which supply blood to the capillaries of glomeruli which are drained by *efferent arterioles*.

The efferent arterioles of cortical nephrons branch and form a *peritubular capillary plexus* around the convoluted tubules, whereas the efferent arterioles of juxtamedullary nephrons give long straight thin capillary vessels called *vasa recta* that pass into the medulla and loop back towards the corticomedullary junction. These looped blood vessels play an important role in maintaining the osmotic gradient of the interstitium of medulla. These vessels join other vessels in the cortex to form stellate veins, which empty into interlobar veins. Interlobar veins join to form the renal vein, which leaves the kidney through the hilum.

### MICROSCOPIC STRUCTURE

- The kidney is composed of many compactly packed uriniferous (renal) tubules embedded in a vascular interstitium.
- Each uriniferous tubule consists of two distinct parts which are embryologically derived from two different sources:
  1. *Nephron*—derived from metanephric blastema and is concerned with production of urine.
  2. *Collecting tubule*—derived from ureteric bud of mesonephric duct and is concerned with concentration (hypertonicity) of urine.

## Nephron

- It is the structural and functional unit of kidney and there are about 1–4 million in each kidney.
- It consists of four parts, namely, (a) renal corpuscle, (b) proximal convoluted tubule (PCT), (c) loop of Henle, and (d) distal convoluted tubule (DCT).
- There are two types of nephrons in the kidney:

### Cortical nephrons

- Located in the cortex.
- Have short loops of Henle that extend only up to the outer zone of medulla.

### Juxtamedullary nephrons

- Located in the corticomedullary junction.
- Have long loops of Henle that extend deep into the inner zone of medulla accompanied by vasa recta.
- Produce a hypertonic environment in the interstitium of medulla, a condition necessary for the production of concentrated urine.

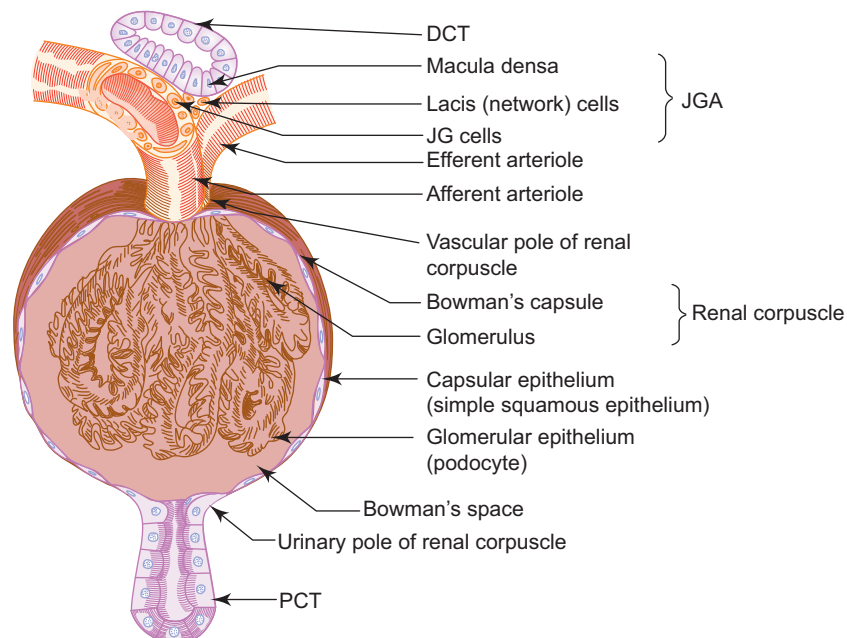
## Renal Corpuscle (Malpighian Corpuscle; Fig. 13.2)

- Renal corpuscle is responsible for filtration of blood (glomerular filtrate).
- It is present in the cortex and measures 200  $\mu\text{m}$  in diameter.
- It is made of two components, namely, Bowman's capsule and glomerulus.
- **Bowman's capsule** is the blind distended end of the nephron, which is converted into a cup-shaped structure by invagination of a tuft of capillaries, the *glomerulus*. Thus Bowman's capsule has two layers, an outer parietal and an inner visceral separated by a space, the Bowman's space.

- The parietal layer is made of simple squamous epithelium, the *capsular epithelium*, which becomes continuous with the cuboidal epithelial lining of PCT at the urinary pole of the corpuscle.

The visceral layer that invests the glomerular capillaries is made of specialised epithelial cells (*glomerular epithelium*) called *podocytes*, which become continuous with the parietal layer at the vascular pole of the corpuscle. Thus, the renal corpuscle has a vascular pole through which the afferent and efferent arterioles enter and leave and an urinary pole from which PCT arises.

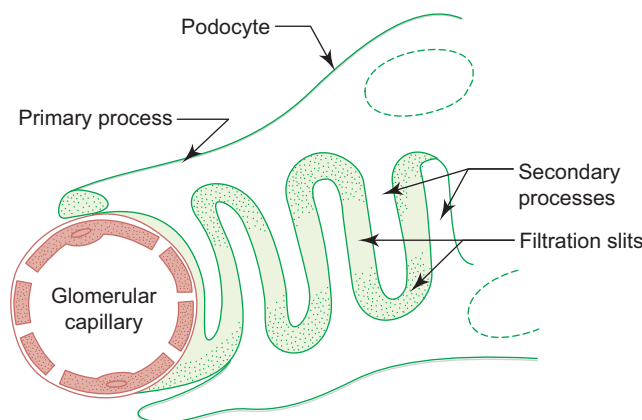
- The space between the parietal and visceral layers is called *Bowman's/urinary/capsular space*.



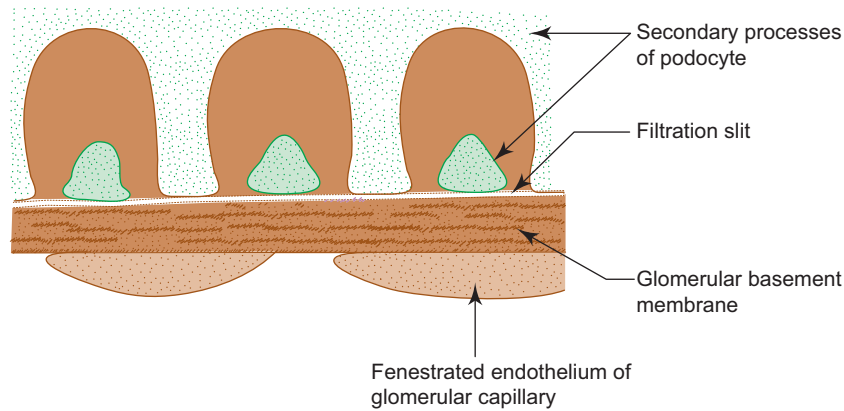
**Fig. 13.2** Renal corpuscle and associated structures.

In diabetic patients, if the blood sugar level is not controlled for a long time, it may lead to degenerative changes of glomeruli (**glomerulonephritis**). In these patients the microscopic structure shows thickening of glomerular basement membrane, increased deposition of mesangial matrix in response to high concentration of glucose. This leads to injury to podocytes and alteration of slit pore membrane. As a result, the glomerular filter becomes more permeable to proteins with subsequent release of protein into urine (**proteinuria**). This is followed by shrinking of kidney and failure.

- **Glomerulus** is a tuft of anastomosing network of capillaries supplied by an afferent arteriole (diameter is large) and drained by an efferent arteriole (diameter is small). Because of the varying diameters of the arterioles a pressure gradient is created which causes active filtration driving many components of blood into Bowman's space as glomerular filtrate.
    - The glomerular capillaries are lined by fenestrated endothelium.
    - The capillary network is supported by specialised connective tissue cells called *mesangial cells*. These are stellate cells with contractile and phagocytic properties. They may be involved in cleaning the glomerular filter.
    - The glomerular capillaries are closely invested with podocytes of visceral layer of renal corpuscle.
    - The numerous nuclei seen in histological section of the glomerulus are those of capillary endothelial cells, mesangial cells and podocytes (large oval pale staining nuclei).
  - **Podocytes** are cells of visceral layer of renal corpuscle that envelop glomerular capillaries.
    - They have long cytoplasmic processes called *primary processes* (like tentacles of octopus), which in turn give rise to short *secondary foot processes* or pedicels (Fig. 13.3).
    - These secondary processes embrace the capillaries and interdigitate with the secondary processes of other podocytes. (The cell bodies of podocytes and their primary processes do not touch the glomerular basement membrane.)
    - The elongated gaps between these interdigitations are of uniform width (25 nm) and are called *filtration slits* or *slit pores*. A slit membrane is seen bridging the slit pores.
  - An unusually thick (100 nm) and well-developed common basement membrane (fused basal laminae of endothelium and podocytes) intervenes between the fenestrated endothelium and the processes of podocytes.
  - **Components of glomerular filter** (Fig. 13.4)
- During filtration the glomerular filtrate passes through three layers:
- (a) *Fenestrated endothelium of glomerular capillary*—acts as a coarse filter preventing passage of cellular elements allowing only the passage of plasma.
  - (b) *Glomerular basement membrane*—is a selective macromolecular filter preventing passage of particles greater than 10 nm in diameter and negatively charged protein with molecular weight greater than that of albumin (68,000).
  - (c) *Filtration slits between secondary processes of podocytes* and the slit membrane bridging them.



**Fig. 13.3** Podocyte.



**Fig. 13.4** Components of glomerular filter.

- The glomerular filtrate has a chemical composition similar to blood plasma sans plasma proteins. It contains no plasma protein because macromolecules do not readily cross the glomerular filter.
- The filtration apparatus of both kidneys produces 125 ml of glomerular filtrate per minute. Of this, 124 ml is reabsorbed by the renal tubules and only 1 ml is released into the renal pelvis as urine. About 1500 ml of urine is formed every 24 h.

### **Proximal Convoluted Tubule (Box 13.1; Fig. 13.5)**

- The proximal convoluted tubule (PCT) starts at the urinary pole of the renal corpuscle.
- It is longer and more convoluted than the distal convoluted tubule and forms the bulk of the cortex.
- It is lined by simple cuboidal epithelium, whose luminal surface is provided with microvilli, which give a brush border appearance to the epithelium when examined under a light microscope. The basal surface of the epithelium also shows striations which are due to infoldings of the plasma membrane and the longitudinal orientation of mitochondria between them.
- Approximately 75% of water and electrolytes (sodium, potassium, chloride) are reabsorbed from the glomerular filtrate by the PCT by a process called *selective reabsorption*.
- It also excretes certain metabolites, dyes and drugs.

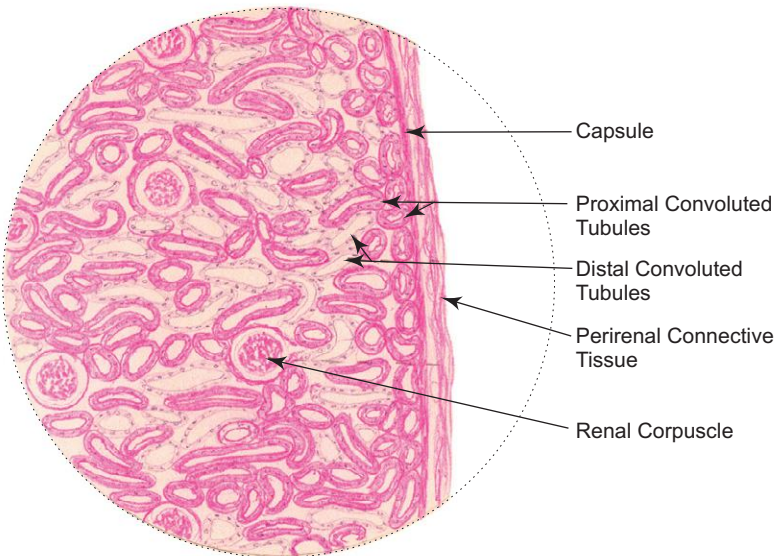
### **Loop of Henle (Fig. 13.5)**

- The loop of Henle arises from the PCT in the cortex, dips down into the medulla as *descending limb* and then loops back as *ascending limb* and becomes continuous with the DCT at the corticomedullary junction.
- The descending limb has a short thick segment, which is the straight part of PCT, and a long thin segment.
- The ascending limb has a short thin segment and a long thick segment, which is the straight part of DCT.
- The structure of the thick segment of descending limb is similar to the structure of PCT, and the thick segment of ascending limb shares the structure with DCT.
- The thin segments of loop of Henle are lined by simple squamous epithelium which is permeable to water and sodium, whereas the thick segments are lined by cuboidal epithelium and is impermeable to water.
- As the descending and ascending limbs are close to each other, water is continuously drawn passively out of the descending limb and sodium and chloride ions are pumped out actively from the ascending limb, making the tubular fluid initially hypertonic and then isotonic as it passes through.
- The loops of Henle are closely associated with the capillary loops of vasa recta which play an important role in maintaining the osmotic gradient of the interstitium of medulla.
- The main function of the loop of Henle is to generate a gradual increasing osmotic gradient (hypertonicity) in the interstitium/tissue fluid of renal medulla by means of a complex countercurrent multiplier system; assisted by the countercurrent exchange mechanism operating in the vasa recta (the medullary interstitium is isotonic at the juxtamedullary zone and is hypertonic at the renal papilla). The high osmotic pressure in medullary tissue fluid permits the removal of water by osmosis from the fluid in the collecting tubules and ducts under the influence of antidiuretic hormone (ADH). (For more details refer to a textbook of Physiology.)

**Box 13.1** Kidney: Cortex.

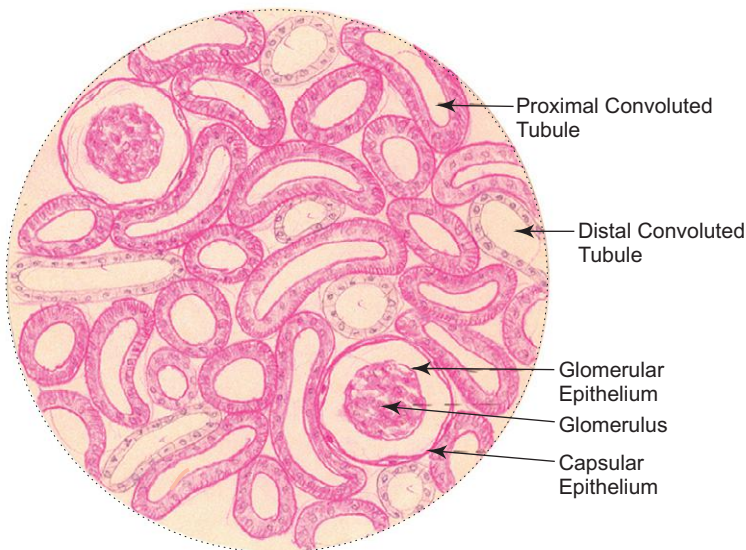
Presence of

- (i) malpighian or renal corpuscles;
- (ii) proximal convoluted tubules with brush border (darkly stained);
- (iii) distal convoluted tubules without brush border (lightly stained).



*L/P*

**Kidney: Cortex**



*H/P*

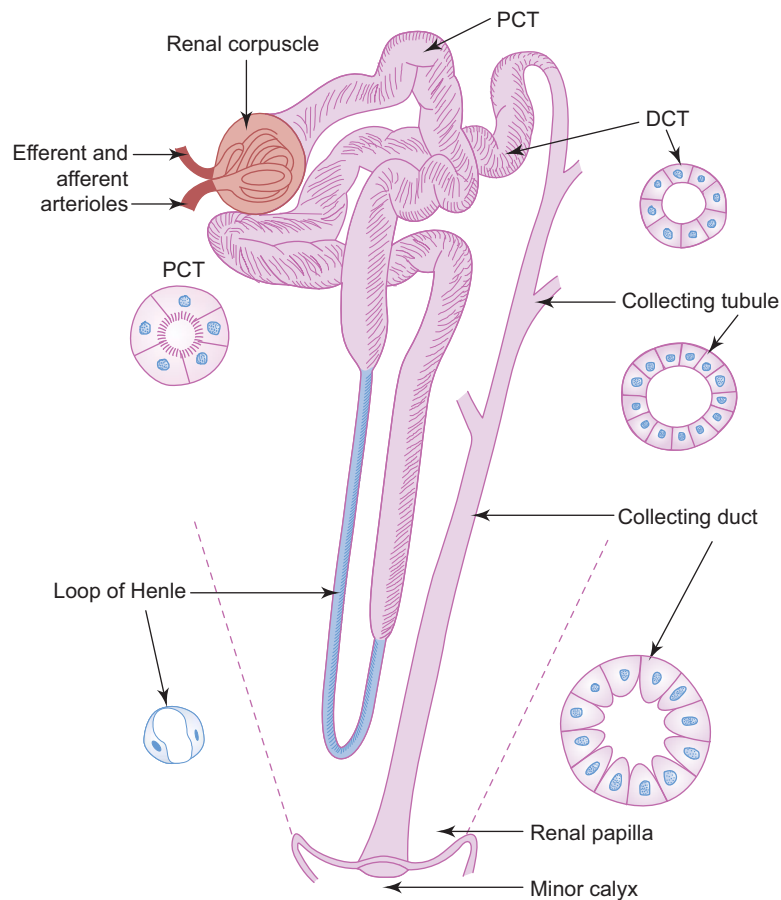
**Kidney: Cortex**

### Distal Convolved Tubule

- The distal convoluted tubule (DCT) is shorter and less convoluted than the PCT and is found in the cortex.
- It is lined by simple cuboidal epithelium (no brush border; Fig. 13.5).
- It actively reabsorbs sodium ions from the tubular fluid. This reabsorptive activity is directly coupled with the secretion of hydrogen or potassium ions into the tubular fluid. (One hydrogen ion or one potassium ion is secreted for every sodium ion reabsorbed.) This process of reabsorption and secretion is controlled by the hormone aldosterone secreted by the adrenal cortex.
- Thus, DCT is involved in maintenance of acid-base balance in body fluids.

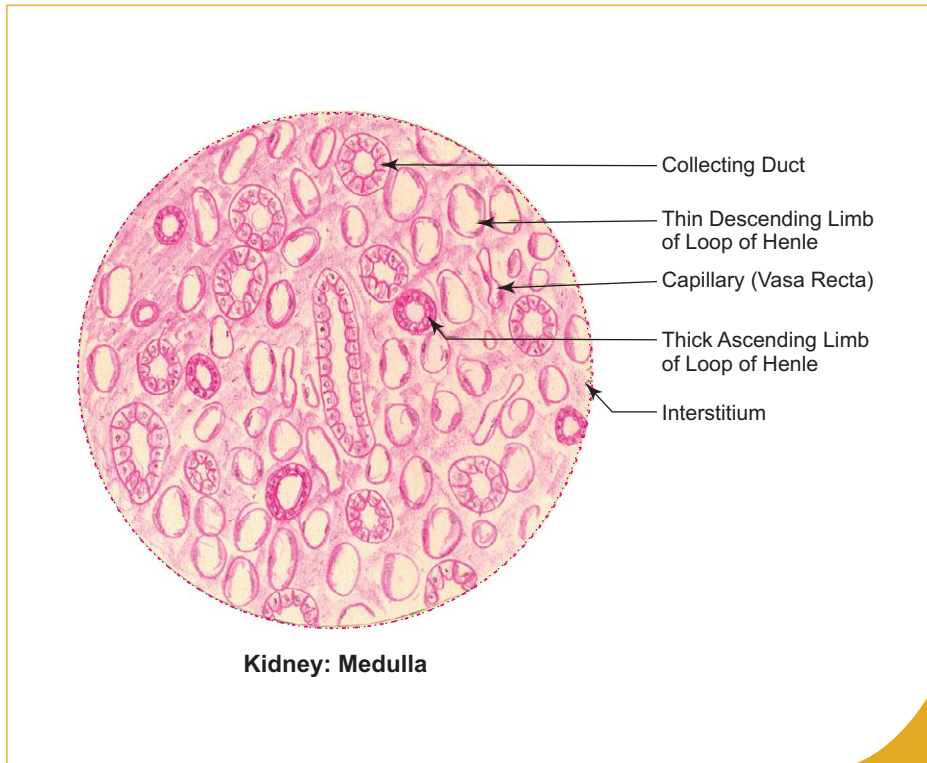
### Collecting Tubule and Collecting Duct (Fig. 13.5; Box 13.2)

- The collecting tubule begins in the medullary ray as the continuation of DCT. As it enters the medulla it is joined by several other collecting tubules to form a larger duct, the *duct of Bellini* or the papillary duct which opens on the apex of the pyramid (renal papilla).
- The collecting tubules are lined by simple cuboidal epithelium with distinct cell boundaries and clear pale cytoplasm.
- The papillary ducts are larger, wider and lined by tall columnar cells with pale-staining cytoplasm.
- The collecting tubules and ducts are not normally permeable to water. However, in the presence of antidiuretic hormone (ADH) secreted by the neurohypophysis, they become permeable to water. As a result, water is drawn out of the collecting ducts because of the hypertonic tissue fluid in the medullary interstitium.
- Thus, the function of the collecting tubules and ducts is to concentrate the urine and conduct it to the calyces.



**Fig. 13.5** Uriniferous (renal) tubule.



**Box 13.2 Kidney: Medulla.**

Presence of

- (i) collecting tubules (cuboidal epithelium) and **collecting ducts** (columnar epithelium);
- (ii) thin segments of **loop of Henle** (squamous epithelium);
- (iii) thick segments of loop of Henle (cuboidal epithelium);
- (iv) **vasa recta** (endothelium).

## JUXTAGLOMERULAR APPARATUS (JGA)

- The JGA is involved in regulation of blood pressure and is made of three components (Fig. 13.6):

### 1. Juxtaglomerular (JG) cells

- The JG cells are modified smooth muscle cells present in the tunica media of afferent arteriole at the point of contact with the DCT. The internal elastic lamina of the afferent arteriole disappears at the site of JG cells.
- EM structure of these cells shows the characteristic features of protein secreting cells. The secretory granules contain the enzyme, *renin*.
- JG cells are sensitive to the pressure of blood in the afferent arteriole (*mechanoreceptor*).

### 2. Macula densa

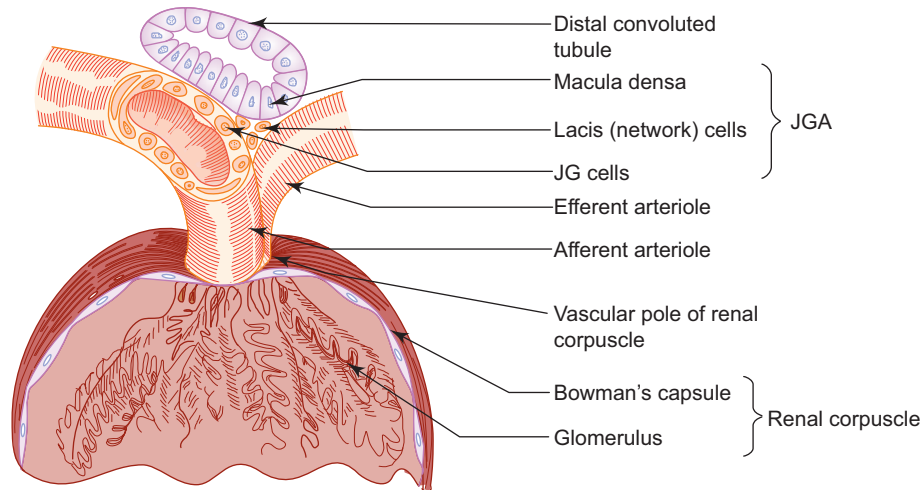
- Macula densa is the specialized region in the wall of the DCT which comes into intimate contact with the JG cells of afferent arteriole. In this region the lining epithelial cells are modified to become macula densa.
- The cells of macula densa are taller and their nuclei are denser and close to one another. The basement membrane is very thin.
- The cells of the macula densa are sensitive to concentration of sodium ions in the fluid present in DCT (*osmoreceptor/chemoreceptor*).

### 3. Lasis (network)/Polkissen cells

- They are the extraglomerular mesangial cells found at the vascular pole of the renal corpuscle in close relationship with the macula densa. The function of these cells are not fully understood. They may be involved in production of hormone, *erythropoietin*, which promotes erythropoiesis in bone marrow.

## Mode of Action of JGA

- A decrease in concentration of sodium ions in the fluid of DCT (due to low blood pressure resulting in low filtration rate) indirectly stimulates the JG cells to release renin. Similarly, a decrease in blood pressure directly stimulates the JG cells to release renin, which activates the angiotensin–aldosterone mechanism promoting an increase in blood pressure.



**Fig. 13.6** Juxtaglomerular apparatus (JGA).

## URETER

### GENERAL FEATURES

- Ureters are muscular tubes that conduct urine from renal pelvis to the urinary bladder by peristaltic contraction of smooth muscle present in the wall.

### STRUCTURE

- The wall of the ureter is made of three coats (Box 13.3). From inner to outer, they are:
  - 1. Mucosa**
    - It consists of transitional epithelium and the supporting underlying connective tissue, the lamina propria rich in elastic fibres.
    - The mucosa is thrown into longitudinal folds which give a star-shaped appearance to the lumen in cross section.
  - 2. Muscle coat**
    - It consists of smooth muscle fibres arranged into two layers in the upper two-third of ureter, an inner longitudinal and an outer circular layers.
    - An additional outer longitudinal layer is added in the lower third of ureter.
  - 3. Adventitia**
    - It is the outermost coat surrounding the muscular coat and is made of loose connective tissue containing blood vessels, lymphatics and nerves.

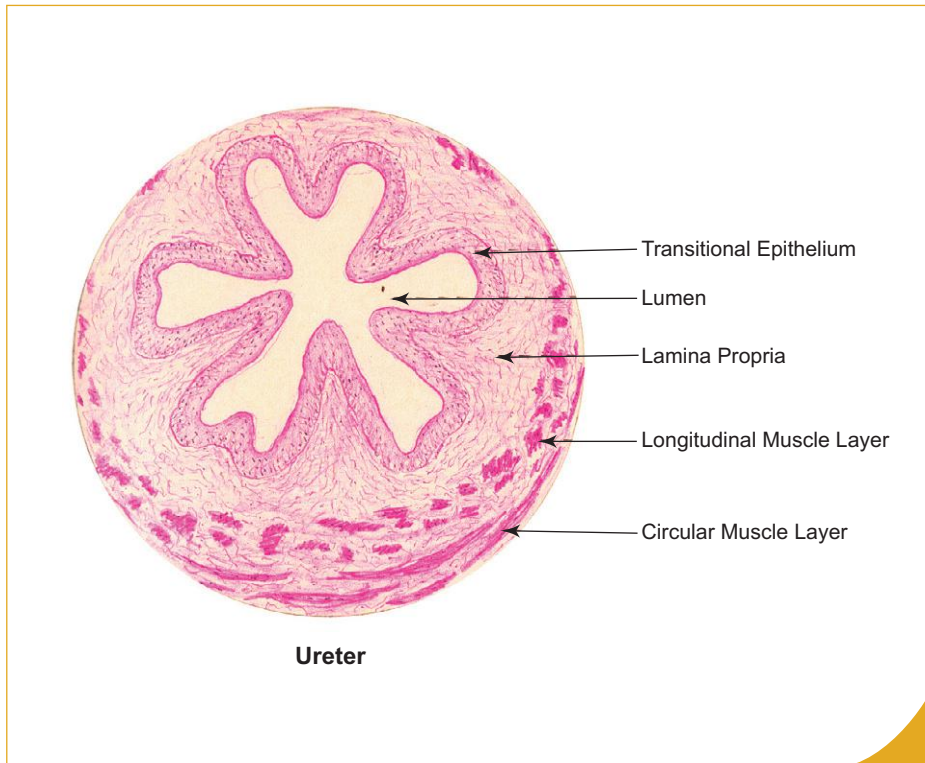
## URINARY BLADDER

### GENERAL FEATURES

- Urinary bladder is a muscular bag, where urine is stored temporarily and is discharged out periodically via urethra during micturition.
- Empty bladder lies within the pelvis behind the pubic symphysis and resembles a four sided pyramid. Its normal capacity is about 200 to 300 ml.

**Box 13.3 Ureter.***Presence of*

- (i) **transitional epithelium;**
- (ii) **starshaped lumen;**
- (iii) muscle coat made up of inner longitudinal and outer circular layers of smooth muscle.

**STRUCTURE**

- Urinary bladder has following three coats (Box 13.4):

**1. Mucosa**

- It consists of transitional epithelial lining and the underlying connective tissue, the lamina propria.
- The transitional epithelium is also called urothelium because it is found only in the urinary system. It lines the conducting passages from the minor calyx to the upper part of urethra. It is specially adapted to stretch, so as to permit great distension of the bladder without damage to its surface integrity.
- When the bladder is empty the mucosa exhibits folds and its epithelium is thick consisting of five or six cell layers. The surface cells of the epithelium are rounded and bulge into the lumen. These cells often contain two nuclei or even are polyploid. The plasma membrane of these superficial cells are specially thickened to form an osmotic barrier between the toxic urine and tissue fluids.
- When the bladder is distended with urine, the mucosal folds disappear and the epithelium becomes thin consisting of three or four cell layers. The superficial cells become flattened.

**2. Muscle coat**

- It is made of three loosely arranged ill-defined layers of smooth muscle fibres, namely, inner longitudinal, middle circular and outer longitudinal. The muscle fibres around the internal urethral orifice form an internal sphincter.

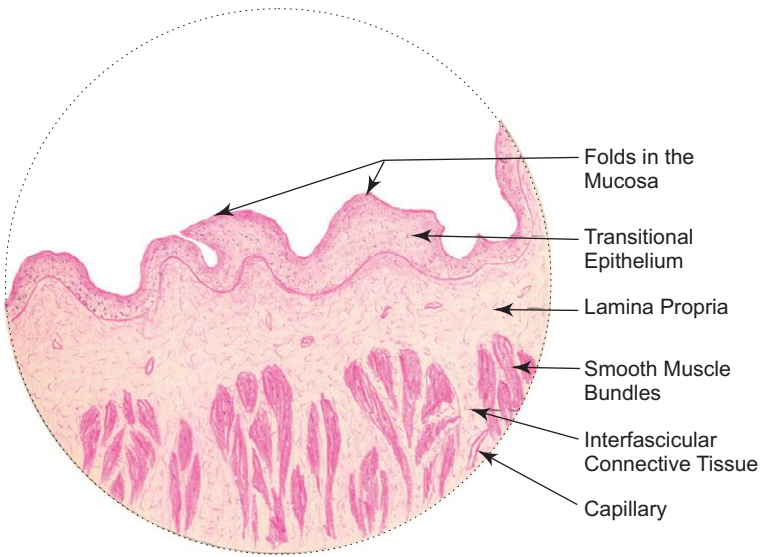
**3. Adventitia**

- It is made of fibroelastic connective tissue carrying blood vessels, nerves and lymphatics. The superior surface of the bladder is covered by mesothelium of peritoneum, forming serosa instead of adventitia.

**Box 13.4 Urinary Bladder.**

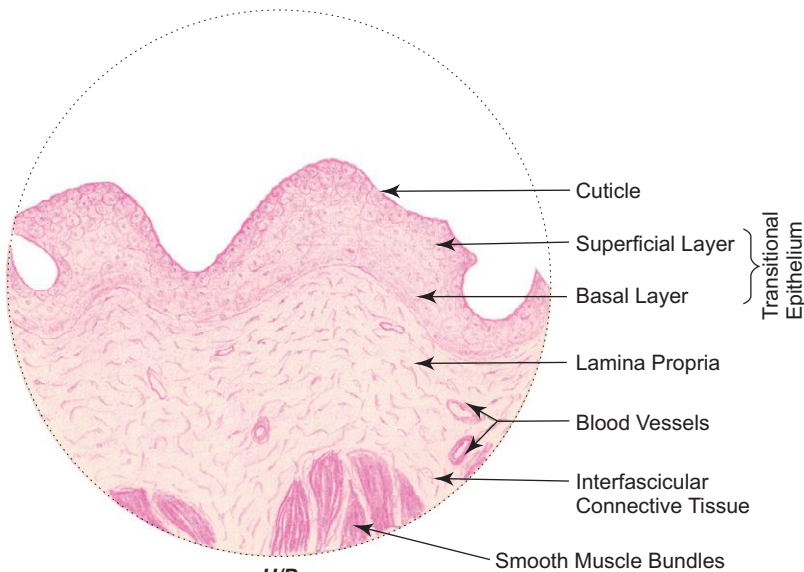
Presence of

- (i) **transitional epithelium;**
- (ii) **thick muscle coat** made up of discrete bundles of smooth muscle separated by connective tissue;
- (iii) glands are absent.



L/P

Urinary bladder



H/P

Urinary bladder

## URETHRA

- The urethra is a tube that carries urine from the bladder to the exterior.
- In the male, semen also passes through it during ejaculation. So, it is considered as part of male reproductive system (described in chapter 14).
- In the female, urethra is exclusively a part of urinary system; it is described here.

### Female Urethra

- The female urethra is a dilatable tube (4 cm long) whose mucous membrane is thrown into longitudinal folds.
- It is lined by stratified squamous epithelium except near the bladder where it is lined by transitional epithelium.
- Many small urethral glands (mucous) homologous to male prostate open into the urethra.
- External to mucosa there is a thin layer of spongy erectile tissue surrounded by smooth muscle fibres arranged into inner longitudinal and outer circular layers.

# Self-assessment Exercise

## I. Write Short notes on:

- (a) Nephron
- (b) Renal circulation
- (c) Podocyte
- (d) Juxtaglomerular apparatus
- (e) Components of glomerular filter
- (h) Histology of ureter
- (i) Histology of urinary bladder

## II. Fill in the blanks:

1. The renal cortical tissue that extends between the pyramids is called \_\_\_\_\_
2. A pyramid and the cortical tissue over it is referred to as a \_\_\_\_\_
3. The cells forming the visceral layer of Bowman's capsule are called \_\_\_\_\_
4. Glomerular capillaries are lined by \_\_\_\_\_
5. The filtration slits are of uniform width and each measures about \_\_\_\_\_

## III. Choose the best answer:

1. Cortex of the kidney contains the following structures *except*
  - (a) proximal convoluted tubule (PCT)
  - (b) distal convoluted tubule (DCT)
  - (c) renal corpuscle
  - (d) thin segment of loop of Henle
2. The PCT can be identified in histological section by the presence of
  - (a) acidophilic cytoplasm of the lining cuboidal cells
  - (b) basophilic cytoplasm of the lining cuboidal cells
  - (c) pale staining cytoplasm
  - (d) large lumen
3. Macula densa is present in
  - (a) PCT
  - (b) DCT
  - (c) afferent arteriole
  - (d) efferent arteriole
4. All of the following statements are true about juxtaglomerular cells *except* that they are
  - (a) modified smooth muscle cells
  - (b) sensitive to concentration of sodium ions
  - (c) responsible for production of renin
  - (d) found in afferent arteriole

5. Aldosterone acts on which of the following parts of uriniferous tubule?
- Collecting duct
  - Collecting tubule
  - DCT
  - PCT

**IV. State whether the following statements are true (T) or false (F):**

- A renal lobe is the one which has a medullary ray and the surrounding cortical tissue ( )
- Nephron is derived from metanephric blastema ( )
- Afferent arterioles of the glomerulus are branches of arcuate artery ( )
- Juxtamedullary nephrons play an important role in creating a hypertonic environment in the interstitium of medulla ( )
- Vasa recta are seen in the renal cortex ( )
- The diameter of afferent arteriole of the glomerulus is smaller than that of efferent arteriole ( )
- Antidiuretic hormone makes the epithelium of collecting duct permeable to water ( )
- DCT is longer and more convoluted than PCT ( )
- Calyces are lined by transitional epithelium ( )
- Polyploidy and binucleated cells are common among cells of the transitional epithelium ( )

**V. Match the items in column 'A' with those of column 'B':**

<b>Column 'A'</b>		<b>Column 'B'</b>	
A.	<i>Parts of kidney tubule</i>		<i>Lining epithelium</i>
1.	PCT ( )	(a)	Simple squamous
2.	DCT ( )	(b)	Simple cuboidal with brush border
3.	Loop of Henle (thin segment) ( )	(c)	Simple columnar
4.	Duct of Bellini ( )	(d)	Simple cuboidal without brush border
B.	<i>Cells</i>		<i>Function</i>
1.	Intraglomerular mesangial cells ( )	(a)	Secretion of renin
2.	Lacis cells ( )	(b)	Support
3.	JG cells ( )	(c)	Glomerular filtration
4.	Podocytes ( )	(d)	Secretion of erythropoietin

**Answers**

- II.** 1. Renal column of Bertin      2. Renal lobe      3. Podocyte      4. Fenestrated endothelium  
5. 25 nm.
- III.** 1. d      2. a      3. b      4. b      5. c
- IV.** 1. (F)      2. (T)      3. (F)      4. (T)      5. (F)      6. (F)      7. (T)      8. (F)      9. (T)      10. (T)
- V.** A. 1. b      2. d      3. a      4. c  
B. 1. b      2. d      3. a      4. c

# Practical No. 13

## Urinary System

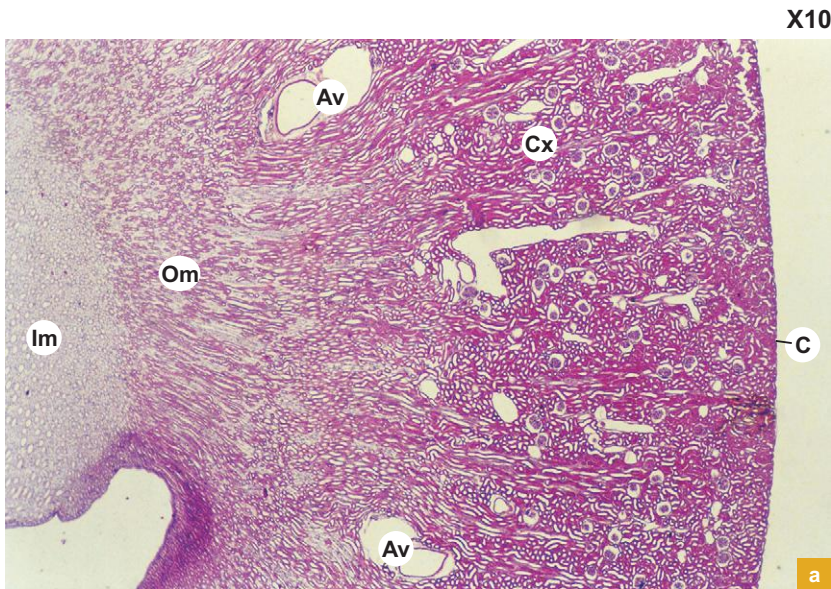


Plate 13:1a

Kidney (panoramic view.).

Examine a section of kidney under scanner (Plate 13:1a).

Note the darkly stained cortex (Cx) and the lightly stained medulla which can be divided into two zones outer (Om) and inner (Im).

- Look for the arcuate vessels (Av) at the corticomedullary junction and the connective tissue capsule (C) at the periphery of the organ.

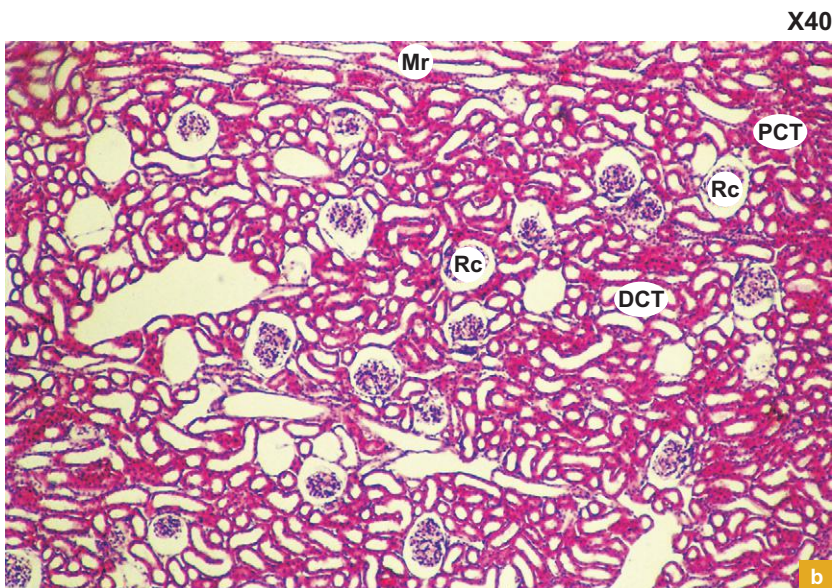


Plate 13:1b

Kidney (cortex).

Examine the cortex at low magnification (Plate 13:1b).

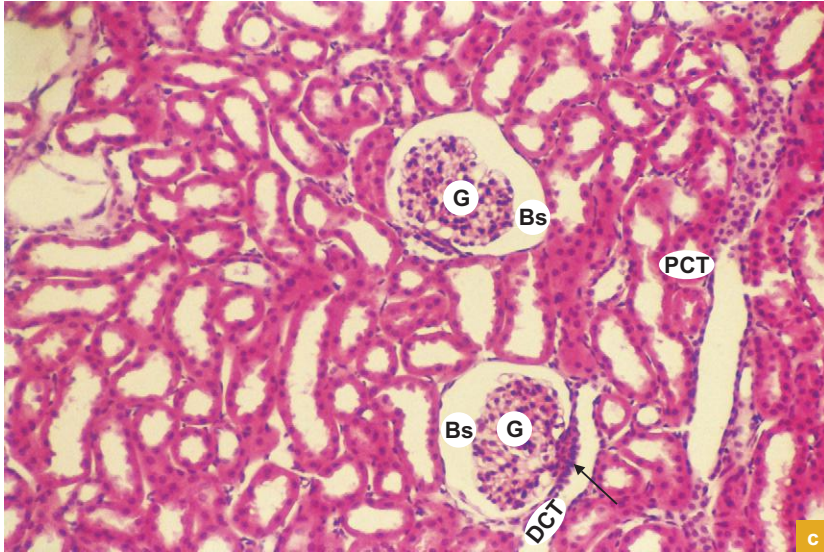
It is characterised by the presence of:

- Large round renal corpuscles (Rc).
- Darkly stained proximal convoluted tubules (PCT).
- Lightly stained distal convoluted tubules (DCT).

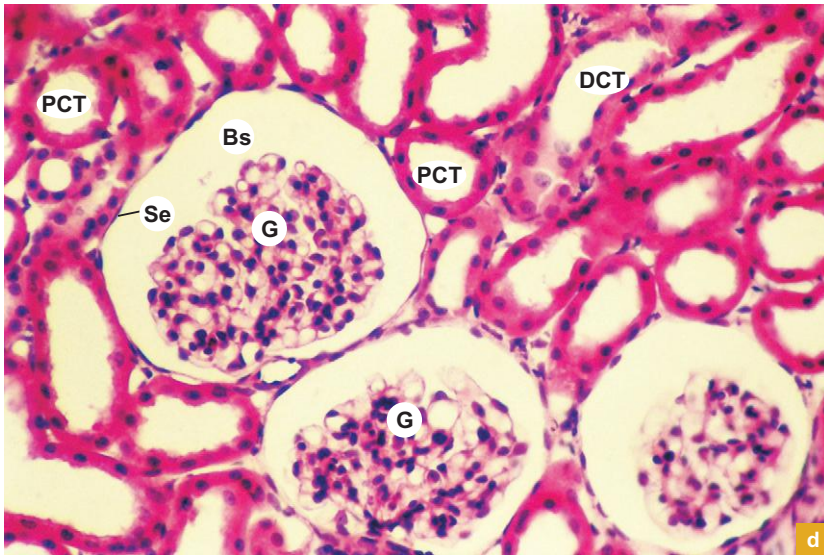
Note the longitudinally cut collecting tubules forming the medullary rays (Mr).



X100



X200

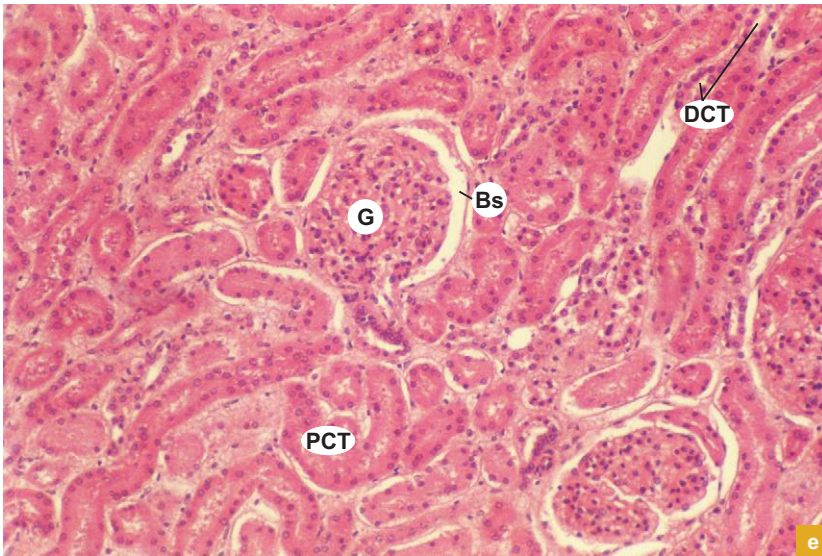

**Plate 13:1** Kidney (cortex).  
**c and d**

At increasing higher magnifications (Plate 13:1c–f) the morphology of the parts of nephron present in the cortex can be appreciated well.

- PCTs are lined by cuboidal epithelium with brush border. Presence of brush border (microvilli) makes the lumen of PCT smaller. These cuboidal cells are bigger and more eosinophilic than in DCT.
- DCTs are also lined by cuboidal epithelium. However, these epithelial cells are smaller in size and have no brush border, which make the lumen larger. The epithelial cells of DCT are less acidophilic than in PCT.
- Renal corpuscles are made of glomerulus (G) and Bowman's capsule. Note the parietal layer of Bowman's capsule lined by simple squamous epithelium (Se) and the visceral layer cells (podocytes) applied to the glomerular capillary network (G). The two layers are separated by Bowman's space (Bs).
- The nuclei which are seen in the glomeruli belong to the endothelium of capillaries, podocytes and the mesangial cells.

(Contd.)

X100

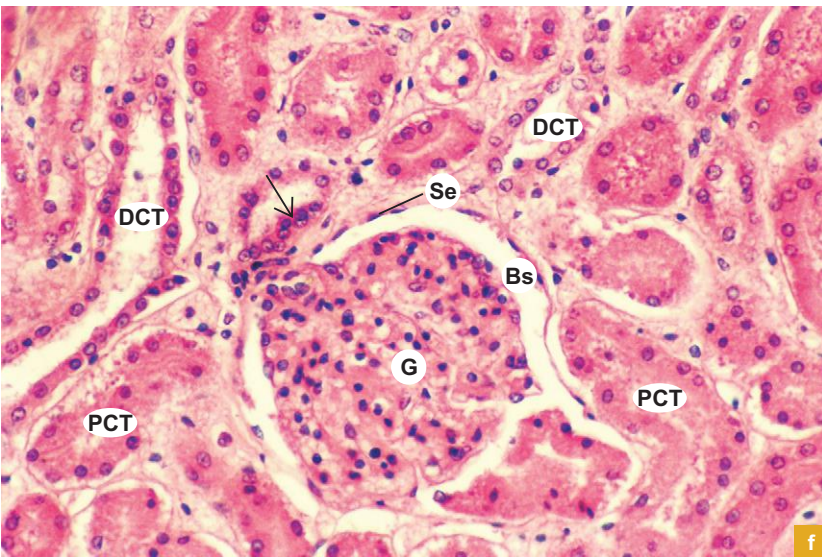


**Plate 13:1** Kidney (cortex).  
**e and f**

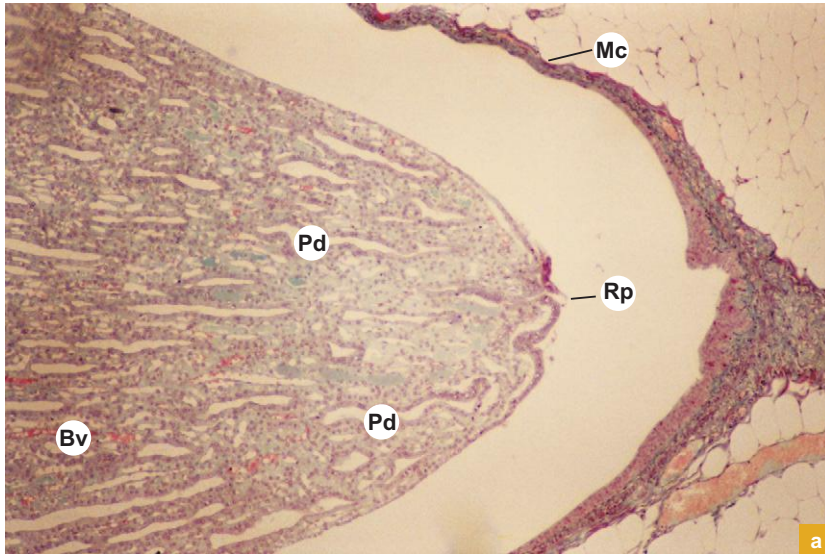
(Contd.)

Plate 13:1f illustrates the high power view of the macula densa (**arrow**) present in the DCT that comes into contact with the afferent arteriole. Note the thickening of the epithelium (columnar) with closely packed nuclei compared to the rest of the area of DCT where the epithelium is cuboidal and the nuclei are situated away from each other.

X200



X40



a

**Plate 13:2**  
**a and b**

**a. Renal papilla.**  
**b. Kidney (medulla).**

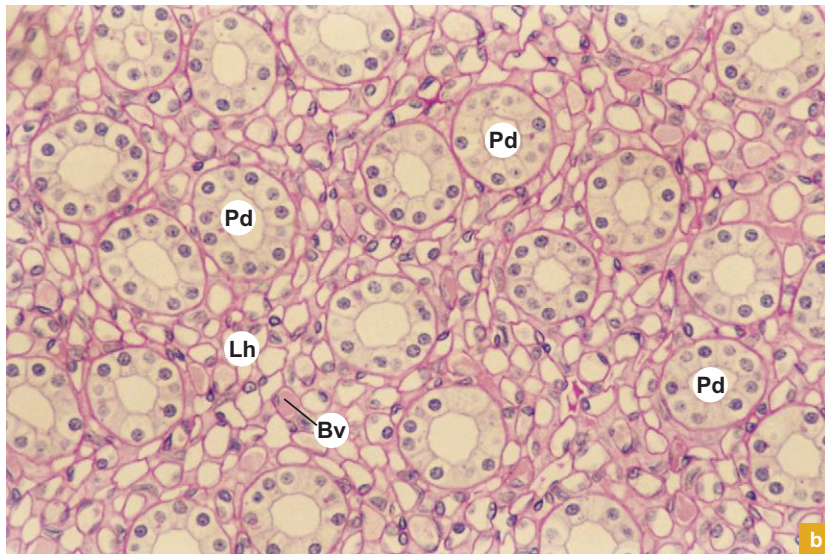
Plate 13:2a illustrates the apex of a renal pyramid, the renal papilla (**Rp**) projecting into the minor calyx (**Mc**). Note the papillary ducts (**Pd**) opening on the summit of the renal papilla.

**Bv** = Blood vessel (vasa recta).

Plate 13:2b illustrates the renal medulla at high magnification and is characterised by the presence of:

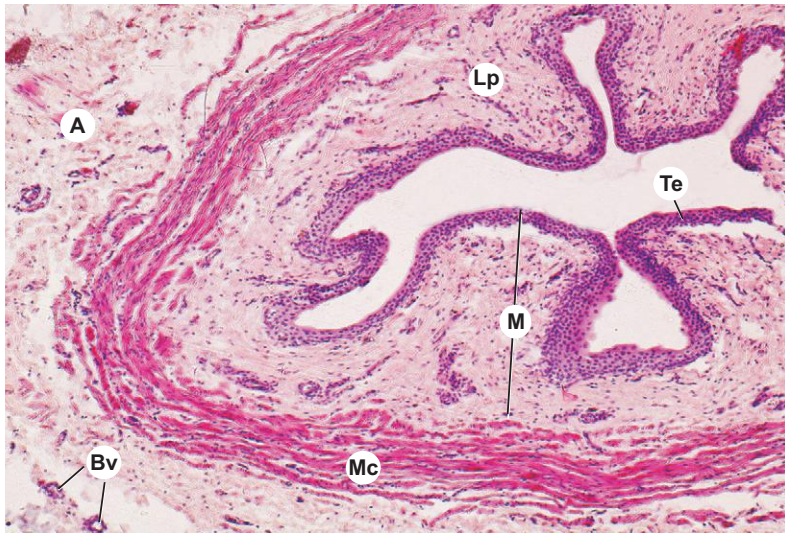- Loop of Henle (**Lh**)—mostly thin segments lined by simple squamous epithelium.
- Collecting tubule (**not seen**)—lined by simple cuboidal epithelium.
- Papillary duct (**Pd**)—lined by simple columnar epithelium.
- Vasa recta (**Bv**)—lined by endothelium (sections of vasa recta resemble thin segment of loop of Henle except for the presence of erythrocytes in the lumen of the former).
- Large amount of interstitial connective tissue.

X200



b

X40



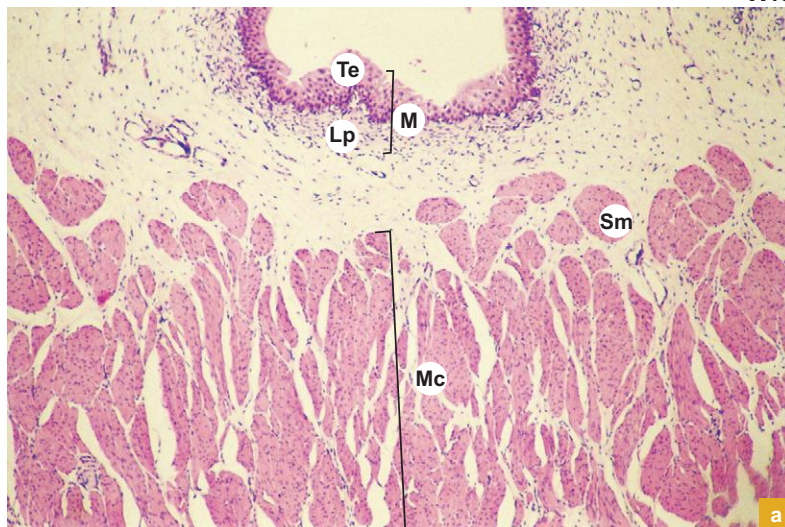
**Plate 13:3 Ureter.**

Identify the three coats of ureter at low magnification:

- Mucosa (M)—composed of *transitional epithelial lining* (Te) and underlying lamina propria (Lp).
- Muscle coat (Mc)—consists of *inner longitudinal* and *outer circular* layers.
- Adventitia (A)—made of fibroelastic connective tissue carrying blood vessels (Bv), nerves and lymphatics.

Note the *star-shaped lumen* due to longitudinal folds of mucosa.

X40

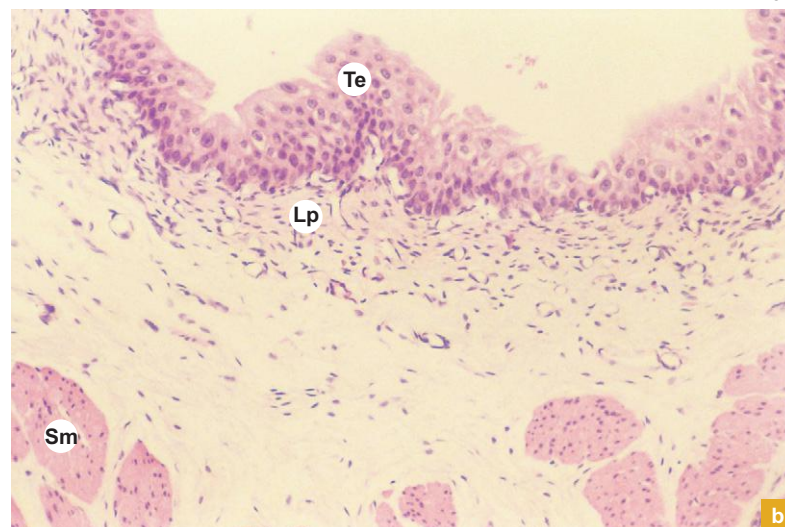


**Plate 13:4 Urinary bladder. a and b**

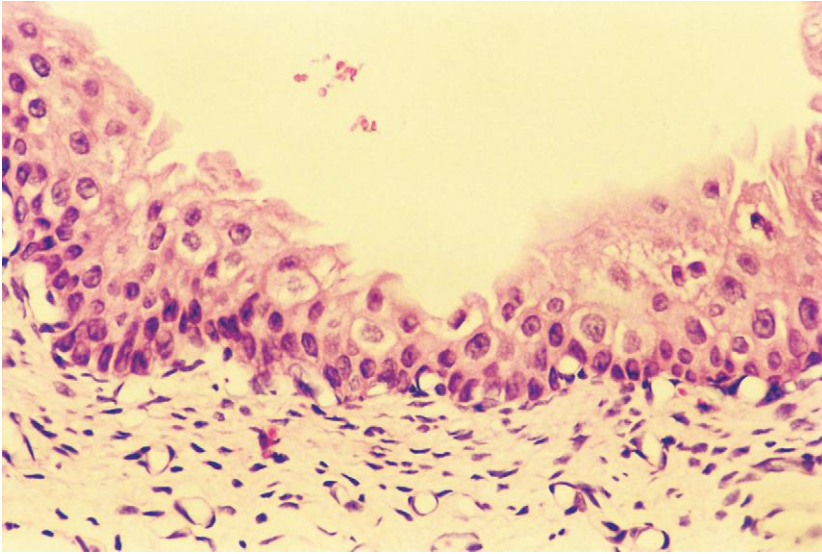
Identify the three coats of urinary bladder in a section (Plate 13.4a and b):

- Mucosa (M)—made of *transitional epithelium* (Te) and lamina propria (Lp).
- Muscle coat (Mc)—is the thickest coat and is made of smooth muscle fibres (Sm) in bundles separated by connective tissue. Though the muscle fibres are organised into three layers, they cannot be distinguished in section.
- Serosa/Adventitia—forms the outermost coat and is made of either peritoneal mesothelium supported by loose connective tissue (serosa) or loose connective tissue only (adventitia).

X100



X200

**Plate 13:5 Transitional epithelium.**

Examine the transitional epithelial lining of the urinary tract at high magnification (Plate 13:5) and appreciate its characteristic features:

- It has a thin basement membrane.
- Its superficial cells are large and dome-shaped giving a characteristic wavy border to the luminal surface of the epithelium and is often stained darkly with eosin.
- The intermediate cells are round and the basal cells columnar in shape.

Islands or nests of transitional epithelium of urinary bladder may become separated from the surface during development and are found embedded in the underlying lamina propria. These are called von Brunn's nests and may undergo central degeneration to form cysts (*cystitis cystica*).

# 14

## MALE REPRODUCTIVE SYSTEM

### INTRODUCTION

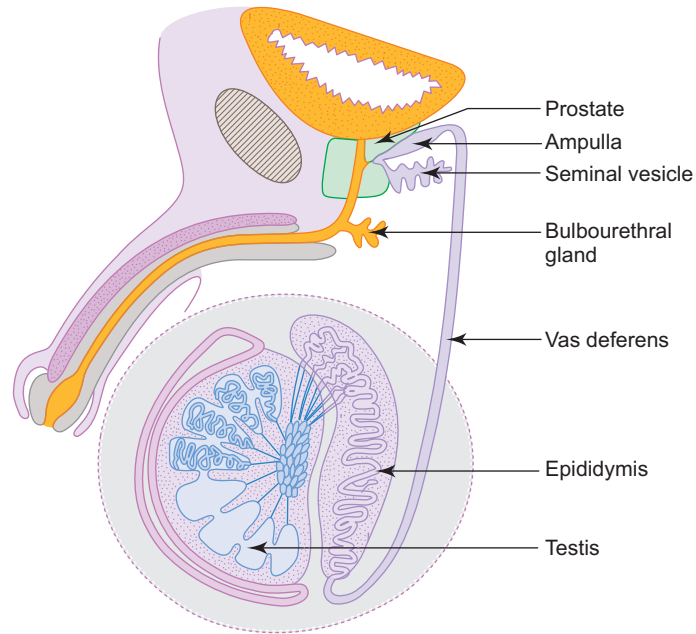
Male reproductive system consists of the following structures:

- A pair of **testes**, the primary sex glands, found in the scrotum. They produce male gametes, the spermatozoa and male sex hormone, testosterone.
- **Genital ducts**, such as *epididymis*, *vas deferens* and *ejaculatory duct* conduct sperms to urethra. As the sperms pass through the duct system especially through the epididymis, they become motile and mature. The contraction of smooth muscle present in the wall of the ducts help to expel the sperms during ejaculation.
- **Accessory sex glands**, which include a pair of seminal vesicles, a single *prostate* and a pair of *bulbourethral glands*. They produce seminal fluid which serves as a medium for transport and nourishment of sperms. They depend on testosterone for their structure and function.
- **Penis**, the organ of copulation.

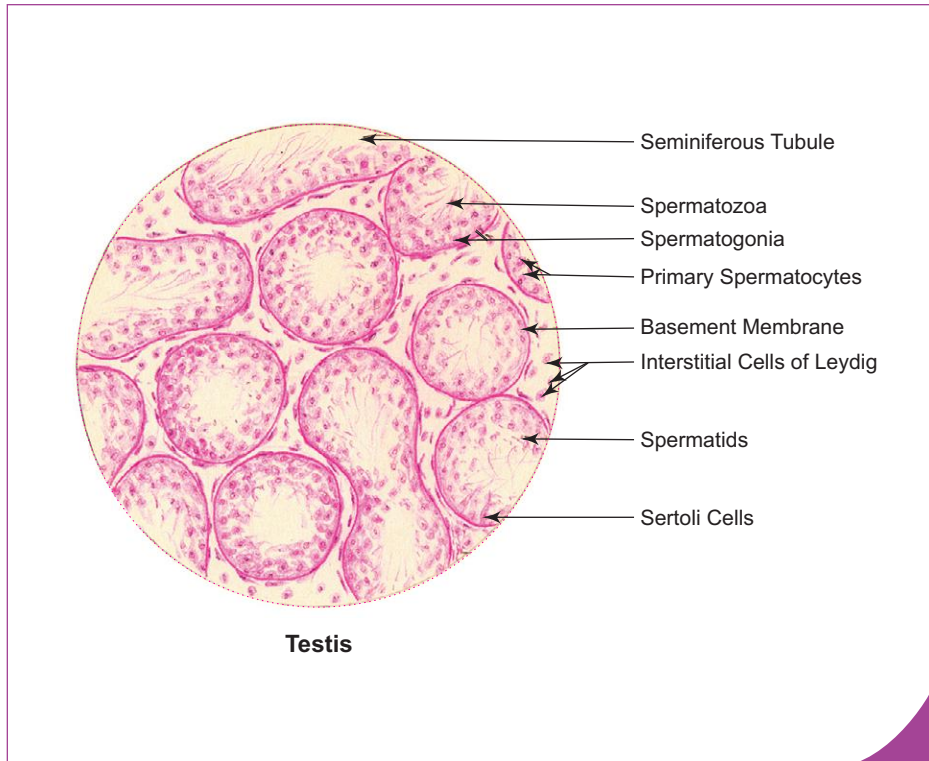
### TESTIS

#### GENERAL ARCHITECTURE OF TESTIS

- Unlike the ovary, the testes (Fig. 14.1) are placed outside the body in the scrotum where the temperature is about 2°–3°C less than the body temperature, which is essential for normal spermatogenesis.
- They are oval in shape and each measures about 5 cm in length, 2.5 cm in width and weighs 10–15 g.
- Each testis is surrounded (except the posterior border) by a serous sac called *tunica vaginalis* derived from peritoneum during descent of testis.
- Deep to the tunica vaginalis there is a thick white fibrous connective tissue capsule, the *tunica albuginea*, which completely encloses the testis. It gets thickened along the posterior border of testis and projects inwards as *mediastinum testis* (Fig. 14.2).
- Thin fibrous septae extend from mediastinum testis to tunica albuginea dividing the testis into many compartments, called lobules.
- Each lobule contains one to four highly coiled *seminiferous tubules*.
- Internal to tunica albuginea there is a layer of vascular loose connective tissue, the *tunica vasculosa*, which extends into the interior as interstitial connective tissue that surrounds and supports the seminiferous tubules. This connective tissue contains clusters of endocrine cells, *interstitial cells of Leydig* which produce testosterone (Box 14.1).
- The *mediastinum testis* contains a network of irregular tubules called *rete testis*, which are connected to seminiferous tubules through straight tubules. The straight tubules are short narrow ducts lined by cuboidal or low columnar epithelium, whereas the rete testis are wider irregular channels lined by simple squamous or cuboidal epithelium.
- The rete testis is connected to the epididymis through *efferent ductules* which are 10–15 in number emerging from the upper part of testis. The efferent ductules are lined by a distinctive epithelium of cells with different heights giving the lumen an uneven contour (groups of tall columnar cells alternate with groups of short cuboidal cells). The tall columnar cells exhibit cilia, while the cuboidal cells exhibit microvilli.



**Fig. 14.1** Parts of male reproductive system.



**Box 14.1 Testis.**

*Presence of*  
 (i) **seminiferous tubules;**  
 (ii) **interstitial cells of Leydig;**  
 (iii) **spermatogenic cells at various stages of maturation.**

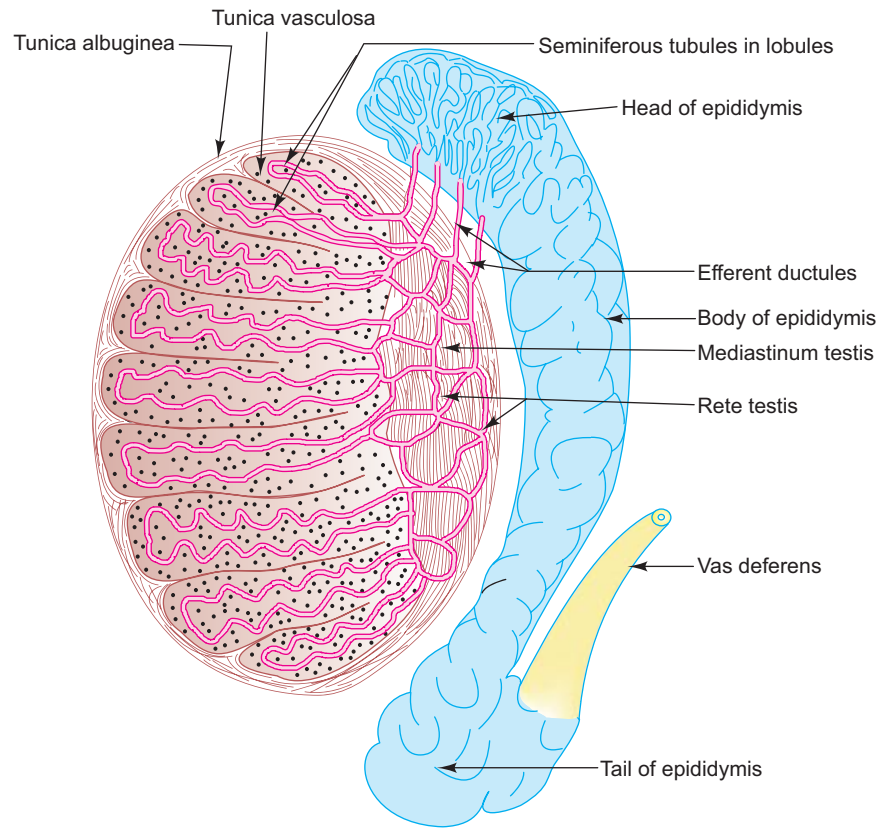


Fig. 14.2 L.S. of testis and epididymis.

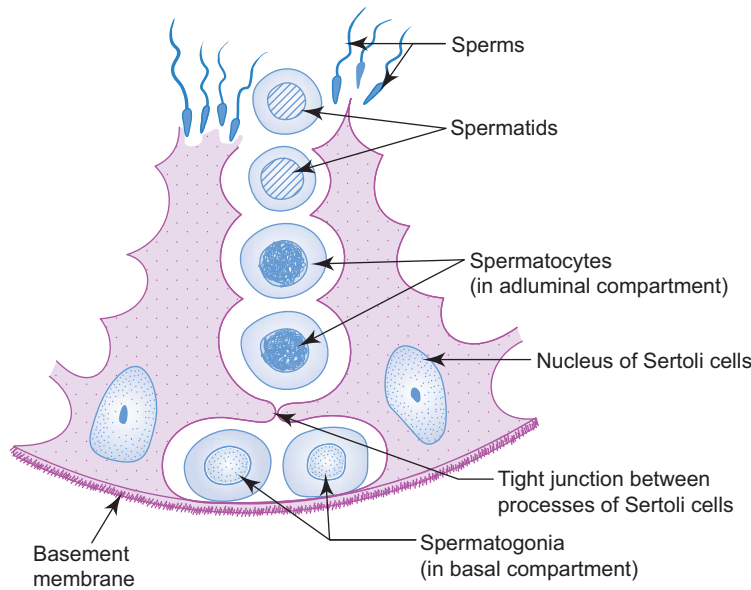
## SEMINIFEROUS TUBULES

- Seminiferous tubules are highly coiled tightly packed tubules present in the testis and each tubule measures about 50–80 cm in length and 150–250  $\mu\text{m}$  in diameter.
- These tubules are the sites where spermatozoa are produced by the process, called spermatogenesis.
- These tubules are lined with a specialised stratified germinal epithelium (seminiferous epithelium).
- This epithelium consists of two distinct population of cells, the *spermatogenic cells* which are involved in spermatogenesis and the *Sertoli cells* which support and nourish the developing spermatozoa.
- This specialised epithelium rests on a basement membrane beneath which lies some slender contractile smooth muscle-like cells, *myoid cells*.

## SPERMATOGENIC CELLS

- Spermatogenic cells are arranged in developmentally higher order from the basement membrane to the lumen, namely, spermatogonia, spermatocytes, spermatids and spermatozoa (Fig. 14.3).
- The process by which spermatogonia divide, differentiate and mature to become spermatozoa is called *spermatogenesis*. This process occurs in waves along the length of the seminiferous tubules taking about  $64 \pm 4$  days to complete in man.
- The *spermatogonia* are the immature spermatogenic cells lying on the basement membrane of seminiferous tubule. They undergo mitosis to produce type A (darkly stained nucleus) and type B (lightly stained nucleus) spermatogonia. The type A spermatogonia serve as stem cells of the germinal epithelium, whereas the type B spermatogonia undergo maturation to become primary spermatocytes.





**Fig. 14.3** Cells of seminiferous epithelium.

- The *primary spermatocytes* are the largest germ cells occupying the middle region of the seminiferous epithelium. They have large nucleus with coarse chromatin clumps or thin strands of chromatin. They undergo first meiotic division to produce secondary spermatocytes with haploid number of chromosomes with reduction in the amount of DNA (from  $4n$  to  $2n$ ).
- The *secondary spermatocytes* are smaller in size with their nuclei having less dense chromatin. They are scarcely seen in the section as they enter into second meiotic division as soon as they are formed. As a result of second meiotic division, spermatids are formed with haploid number of chromosomes ( $23$ ) and reduction in the amount of DNA ( $1n$ ) per cell.
- The *spermatids* are smaller than the spermatocytes and lie in groups in association with Sertoli cells. With the formation of spermatids from spermatogonia the first phase of spermatogenesis, i.e. *spermatocytogenesis* is completed. Now the nonmotile spermatids undergo morphological transformation into motile spermatozoa by a process called *spermiogenesis*, which is the second phase spermatogenesis.
- During this process of maturation (spermiogenesis) the following changes take place in the spermatids converting them into motile spermatozoa (refer to a textbook of Anatomy for details):
  - Formation of acrosomal cap from Golgi apparatus that covers the nucleus.
  - Condensation and elongation of nucleus.
  - Formation of flagellum from centrioles.
  - Formation of helical mitochondrial sheath, around the middle piece, from elongated mitochondria.
  - Casting off of excess cytoplasm as cytoplasmic droplets.
- The spermatozoa are elongated motile male gametes found in close association with Sertoli cells, with their tails projecting into the lumen of seminiferous tubules. Each spermatozoon is about  $60\ \mu\text{m}$  in length and consists of a head, a neck and a tail (Fig. 14.4):
  - **Head ( $5\ \mu\text{m}$ )**—contains dark elongated nucleus with haploid number of chromosomes.
  - **Neck**—is a short segment containing the centriole from which the flagellum arises.
  - **Tail**—is made of three pieces, i.e. middle piece, principal piece and end piece.
  - **Middle piece ( $5\ \mu\text{m}$ )**—contains mitochondrial sheath that provides energy for sperm mobility.
  - **Principal piece ( $45\ \mu\text{m}$ )**—contains the  $9 + 2$  pattern of microtubules (axoneme) in the central core surrounded by 9 coarse fibres enclosed in a fibrous sheath.
  - **End piece ( $5\ \mu\text{m}$ )**—contains  $9 + 2$  axoneme enclosed by plasma membrane.

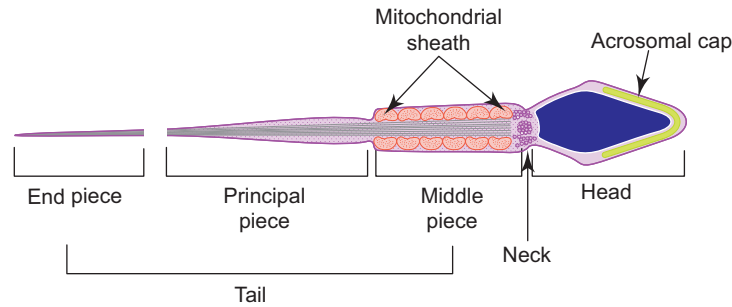


Fig. 14.4 Structure of a spermatozoon.

## Sertoli Cells

- Sertoli cells are basically tall columnar cells which extend from basement membrane to lumen of seminiferous tubule.
- They exhibit many cytoplasmic processes which surround all spermatogenic cells. They have distinct oval nuclei with well developed nucleoli. This feature distinguishes them from other spermatogenic cells.
- Adjacent Sertoli cells are joined together by tight junction through their basal lateral cytoplasmic processes over the spermatogonia. These tight junctions form the *blood testis barrier* and divide the seminiferous tubules into basal and adluminal compartments. The basal compartment contains spermatogonia, whereas the adluminal compartment contains other developing germ cells and spermatozoa (Fig. 14.2).
- The blood testis barrier prevents the entry of harmful substances from blood affecting the developing sperm cells and at the same time prevents the sperm related proteins (antigen) from entering circulation to set up an autoimmune response to one's own sperms.
- The structure and functions of Sertoli cells are under the control of FSH.

## Functions

- *Support:* Provide structural and metabolic support to spermatogenic cells.
- *Protection and nutrition:* Provide protection, nutrition to spermatogenic cells.
- *Phagocytosis:* Phagocytose excess cytoplasm which is shed (as cytoplasmic droplet) from the differentiating spermatids during spermiogenesis.
- *Secretion:*
  - Secrete some components of testicular fluid.
  - Secrete androgen-binding protein (ABP) which helps to concentrate testosterone.
  - Secrete inhibin that inhibits the secretion of FSH from pituitary.
- *Blood testis barrier* (see above).

## INTERSTITIAL TISSUE AND LEYDIG CELLS

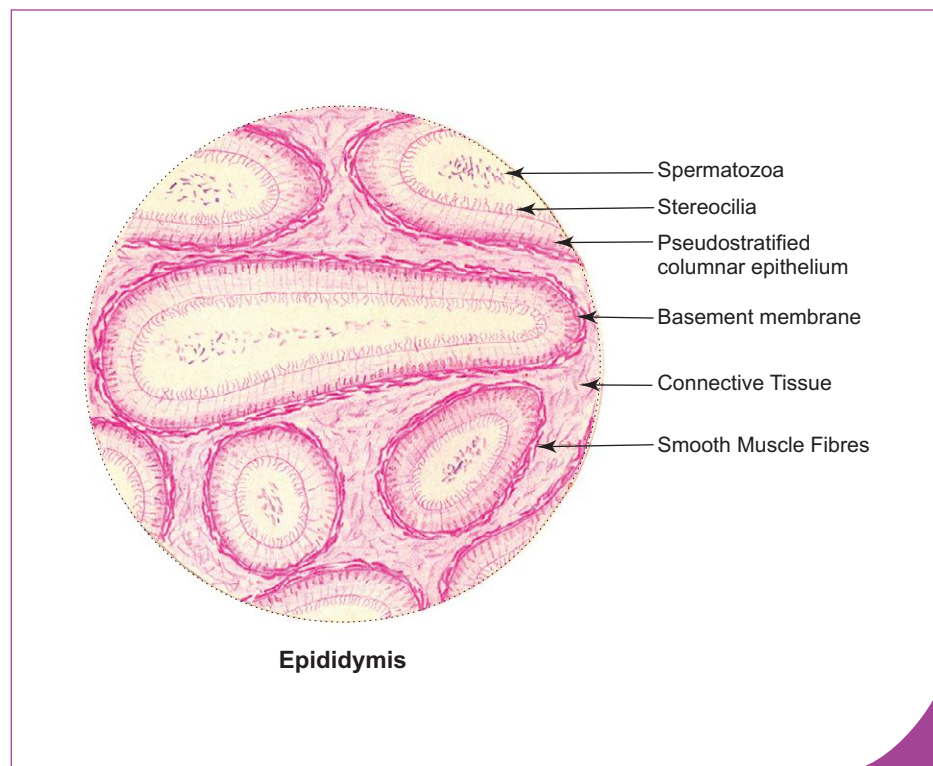
- Interstitial tissue is a delicate vascular connective tissue that surrounds and supports the seminiferous tubules and is continuous with tunica vasculosa of testis at the periphery.
- Apart from conventional connective tissue cells it contains clusters of specialised endocrine cells called *Leydig cells*. These cells are larger in size (15–20  $\mu\text{m}$ ) polyhedral in shape and have acidophilic cytoplasm. The Leydig cells secrete male sex hormone, *testosterone* which is necessary for the spermatogenesis and is responsible for the development of male secondary sexual characters at puberty and growth and maintenance of accessory sex glands.
- Testosterone secretion is under the control of ICSH (LH).

## GENITAL DUCTS

- Genital ducts conduct sperms to urethra. They are epididymis, ductus deferens and ejaculatory duct.

## EPIDIDYMIS

- Epididymis is a comma-shaped structure on the posterolateral aspect of testis.
- It is made of a 6 m long highly coiled tube, ductus epididymis supported by vascular connective tissue.
- It is divided into a head, body and tail (Fig. 14.2).
- The ductus epididymis is lined by pseudostratified columnar epithelium, which is made of two types of cells, tall columnar principal cells and small basal cells. The tall columnar cells bear long microvilli called *stereocilia* and are involved in both secretion and absorption.
- Beneath the epithelium there is a layer of circularly arranged smooth muscle fibres. This muscle layer increases in thickness gradually from head to tail and may be organised into inner circular and outer longitudinal layers in the tail region. The smooth muscle is richly innervated by sympathetic fibres and its intense rhythmic contraction causes expulsion of sperms during ejaculation (Box 14.2).
- Epididymis has the following functions:
  - Storage of spermatozoa, especially in the tail of epididymis.
  - Maturation of spermatozoa—they become motile.
  - Absorption of testicular fluid—90% of testicular fluid is absorbed here.



### Box 14.2 Epididymis.

Presence of

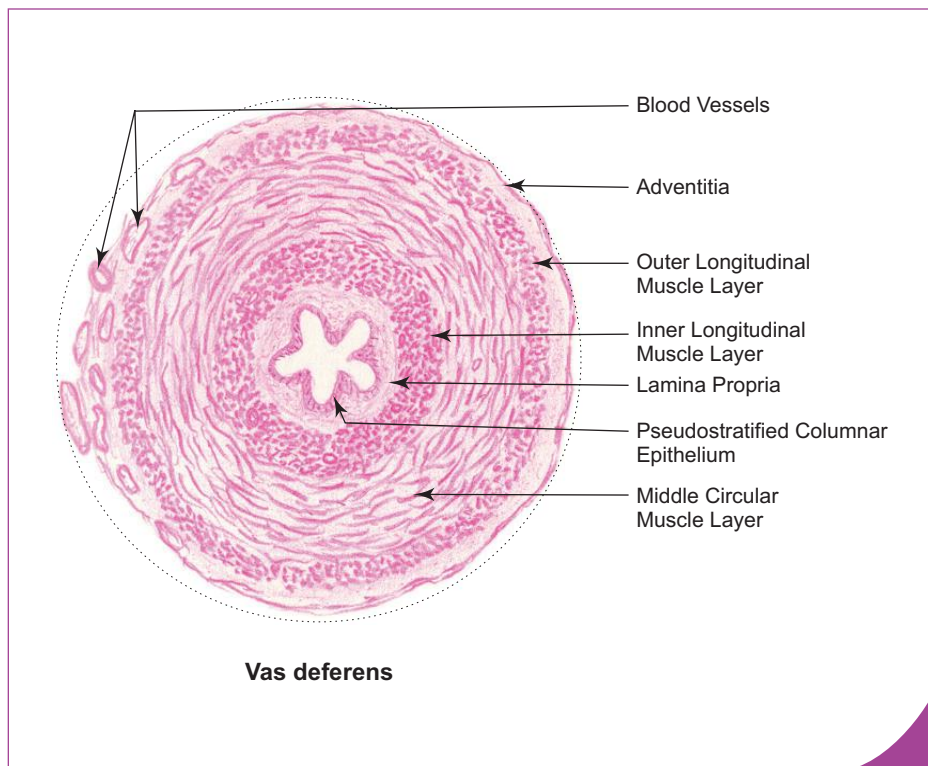
- (i) ductus epididymis lined by **pseudostratified columnar epithelium** with stereocilia;
- (ii) **smooth muscle fibres** surrounding each ductus;
- (iii) **sperms** in the lumen.

## VAS DEFERENS (DUCTUS DEFERENS)

- Ductus deferens is a thick muscular tube extending from the tail of epididymis to the prostatic urethra. Its distal part is dilated to form the ampulla which joins the duct of seminal vesicle to form ejaculatory duct. The ejaculatory duct from each side pierces the prostate and opens into the prostatic urethra.
- The wall of ductus deferens is composed of three coats (Box 14.3), namely,
  1. **Mucosa**
    - It comprises the pseudostratified columnar epithelial lining and the underlying lamina propria. The epithelium is provided with stereocilia.
    - The mucosa is thrown into longitudinal folds which permit expansion of the duct during ejaculation.
  2. **Muscle layer**
    - It consists of smooth muscle fibres arranged into inner longitudinal, middle circular (thickest) and outer longitudinal layers.
  3. **Adventitia**
    - It is made of fibroelastic connective tissue carrying blood vessels and nerves.

## EJACULATORY DUCT

- Ejaculatory ducts are two in number and each duct (2 cm) is formed by the union of duct of seminal vesicle and ampulla of vas deferens.
- Immediately after formation, ejaculatory duct passes through the substance of prostate lateral to prostatic utricle and opens into the prostatic urethra.
- Ejaculatory duct is lined by simple columnar epithelium.



### Box 14.3 Vas Deferens.

*Presence of*

- (i) thick muscle coat made up of three layers:
  1. inner longitudinal
  2. middle circular
  3. outer longitudinal;
- (ii) small stellate lumen lined by pseudostratified columnar epithelium with stereocilia;
- (iii) **sperms** in the lumen.

## ACCESSORY SEX GLANDS

- Accessory sex glands (seminal vesicle, prostate and bulbourethral glands) are androgen-dependent organs, whose secretions (seminal fluid) provide a medium for transport and nourishment of sperms and constitute the bulk of semen (seminal fluid containing sperms).
- The amount of secretion of each of the accessory sex glands during ejaculation is: seminal vesicle (30%), prostate (60%) and bulbourethral glands (10%).

## SEMINAL VESICLE

- Seminal vesicles are paired glands present at the base of the urinary bladder. Each seminal vesicle is an elongated blind tube (12–15 cm) highly coiled upon itself to become reduced to a small size (5 cm). In section the same tube is observed at different orientations.
- The gland secretes a thick yellow viscous alkaline fluid rich in fructose that nourishes the sperms. The secretion also contains ascorbic acid and prostaglandin.
- The wall of seminal vesicle is made of three coats (Box 14.4), namely,

### 1. Mucosa

- It is thrown into complicated folds, which branch and anastomose forming crypts and cavities, giving a honeycomb appearance to the lumen.
- The epithelium of the mucosa is secretory in nature and is of pseudostratified low columnar variety. At some places the epithelium is simple columnar to cuboidal, depending on the degree of secretory activity.
- The lamina propria is rich in elastic fibres and is drawn into the mucosal folds.

### 2. Muscle layer

- This layer is made of smooth muscle fibres, which are arranged into inner circular and outer longitudinal layers.
- Contraction of muscle layer causes expression of secretion into the urethra via ejaculatory duct.

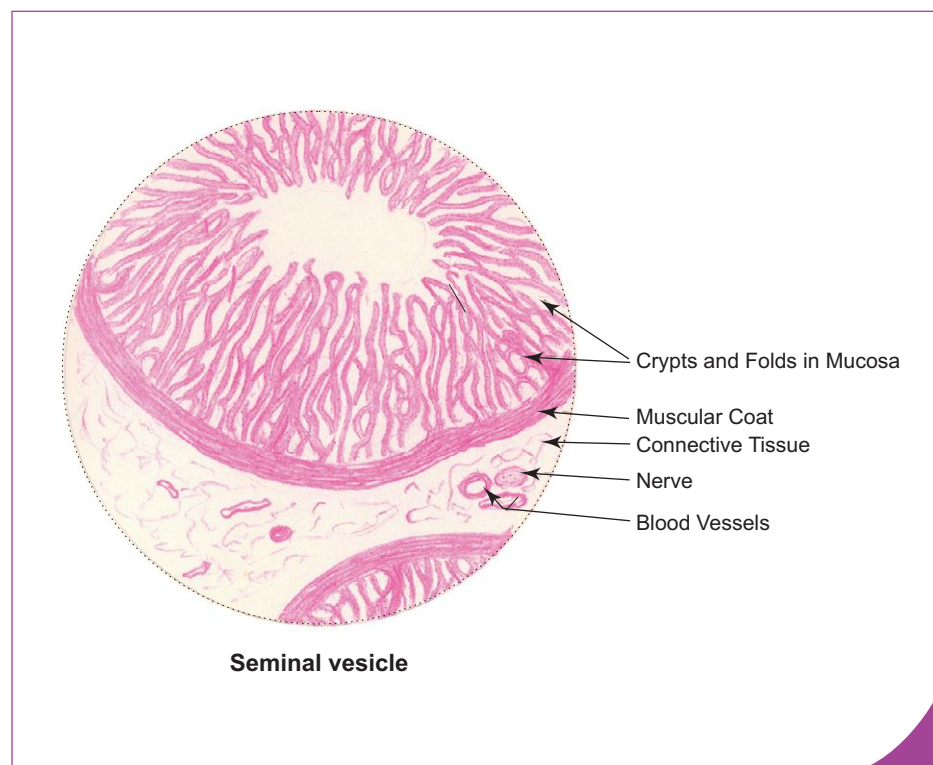
### 3. Adventitia

- This is made of loose connective tissue containing blood vessels and nerves.

### Box 14.4 Seminal Vesicle.

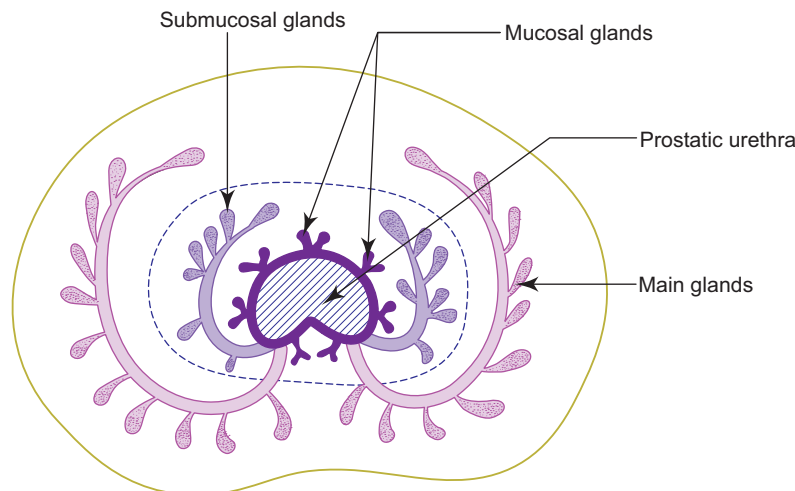
Presence of

- (i) **Mucosa—forms branching and anastomosing folds;**
- (ii) **simple columnar epithelium;**
- (iii) **well developed muscle coat.**

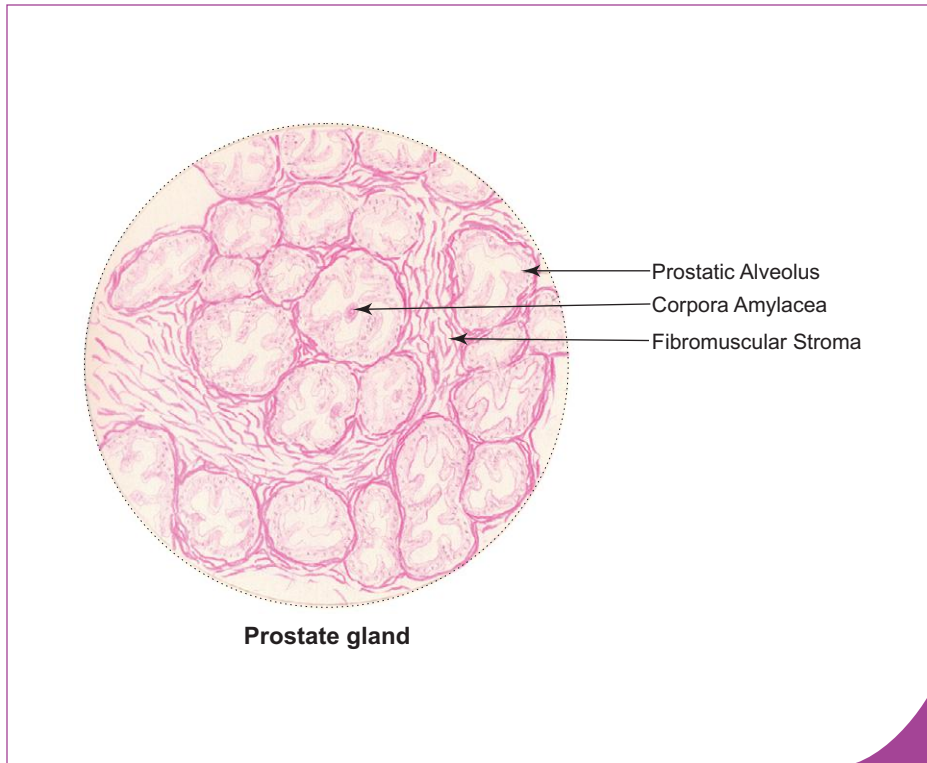


## PROSTATE

- Prostate is the largest accessory sex gland that surrounds the beginning of male urethra.
- It is the size of a chestnut weighing 20 g in adult male.
- It is composed of 30–50 branched *tubuloalveolar glands* embedded in *fibromuscular stroma*. The ducts of the glands open into prostatic urethra.
- Prostate is surrounded by two capsules, a *true capsule* and a *false capsule*. The true capsule is formed by condensation of fibromuscular stroma at the periphery, whereas false capsule is formed by pelvic fascia. A rich venous plexus lies between the two capsules.
- The gland secretes a thin milky fluid rich in citric acid, acid phosphatase, amylase and fibrinolysin. Fibrinolysin liquefies coagulated semen after ejaculation. The secretion constitutes about 75% of the seminal fluid. Serum prostate specific antigen (PSA) level is increased in patients with prostatic tumour.
- The glands of prostate are divided into three groups and are arranged concentrically around the urethra; namely, mucosal, submucosal and main glands. The mucosal glands are small tubular glands present in the inner zone and they open directly into the urethra. The submucosal and main glands are tubuloalveolar glands present in the intermediate zone and outer zone respectively. They open into the prostatic sinus of the urethra through long ducts (Fig. 14.5).
- Histologically the prostate is made of parenchyma (tubulo-alveolar glands) and a characteristic fibromuscular stroma.
- The *parenchyma* is formed by large irregular prostatic alveoli with wide lumen. The secretory lining epithelium of the alveoli varies from cuboidal to columnar depending on activity. The lumen may contain spherical prostatic concretions or *corpora amylacea* which are formed by condensation of prostatic secretions. The number of prostatic concretions increase with age and they may become calcified (Box 14.5).
- The *fibromuscular stroma* supports the parenchyma and is made of smooth muscle fibres mixed with connective tissue fibres running in different directions. The stroma also contains blood vessels lymphatics and nerves.
- The *prostatic urethra* present in the prostate is a crescent-shaped structure with many diverticula (outpocketings). It is lined by transitional epithelium in the upper part and stratified columnar epithelium in the lower part.
- The prostate also contains the following structures apart from glandular tissue and urethra:
  - a pair of ejaculatory ducts, and
  - a single prostatic utricle (uterus masculinus).



**Fig. 14.5** Arrangement of glandular tissue in prostate.

**Box 14.5 Prostate Gland.**

Presence of

- (i) **prostatic urethra** lined by transitional epithelium;
- (ii) **fibromuscular stroma**;
- (iii) large irregular alveoli lined by **simple columnar epithelium**;
- (iv) **corpora amylacea** (prostatic concretions).

Often the mucosal and submucosal glands begin to hypertrophy (benign) in 50% of men after the age of 50 years leading to partial or total obstruction of the urethra. Carcinoma of the prostate (malignant hypertrophy) affects the main glands of prostate and is the second most common cancer in elderly men.

## BULBOURETHRAL GLAND

- Bulbourethral glands are two in number and each is about the size of a pea.
- They lie in the deep perineal pouch and secrete mucus-like fluid that lubricates the penile urethra before ejaculation.

## PENIS

### GROSS FEATURES

- Penis is an erectile male organ of copulation. It is cylindrical in shape. During erection it becomes bigger, lengthened and turgid.
- It is made of three cylindrical bodies of spongy cavernous tissue, a pair of *corpora cavernosa* and a *single corpus spongiosum*.
- The corpora cavernosa are placed side-by-side on the dorsal aspect of the penis and is traversed by the deep artery of penis. The corpus spongiosum is placed ventrally and is traversed by the *penile urethra*. Distally, the corpora cavernosa end blindly under the cover of glans penis which is the enlarged cap-like end of corpus spongiosum.
- The glans penis forms the tip of the penis and is covered by a retractable fold of skin called prepuce. The glans penis is traversed by *fossa navicularis* of urethra which opens on the external urethral meatus.
- The erectile cylindrical bodies are covered by a fibrous sheath known as *tunica albuginea*. The tunica has two layers, an outer and an inner. The outer layer is made of longitudinal collagen fibres and forms a common covering for all the three erectile bodies. The inner layer is made of circular collagen fibres and forms a separate sheath for each body (Fig. 14.6; Box 14.6).

- Penis has the following coverings from superficial to deep:
  - **Skin** – thin and delicate, devoid of hair follicle.
  - **Buck's fascia** – loose connective tissue devoid of fat. It:
    - (a) allows free movement of skin over the organ,
    - (b) rich in elastic fibres and may contain strands of smooth muscle fibres (dartos muscle), and
    - (c) contains superficial and deep dorsal veins in the midline and dorsal artery and nerve on either side.
  - **Tunica albuginea** (described on page 300).

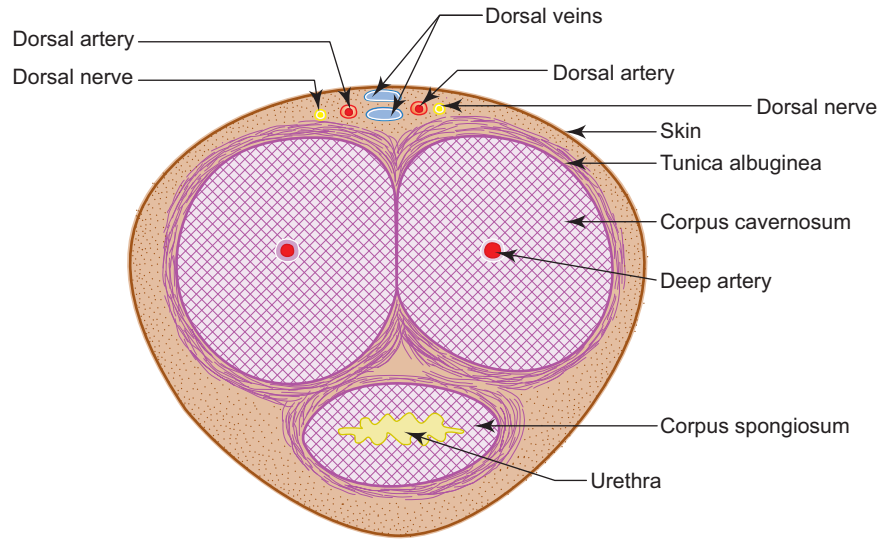
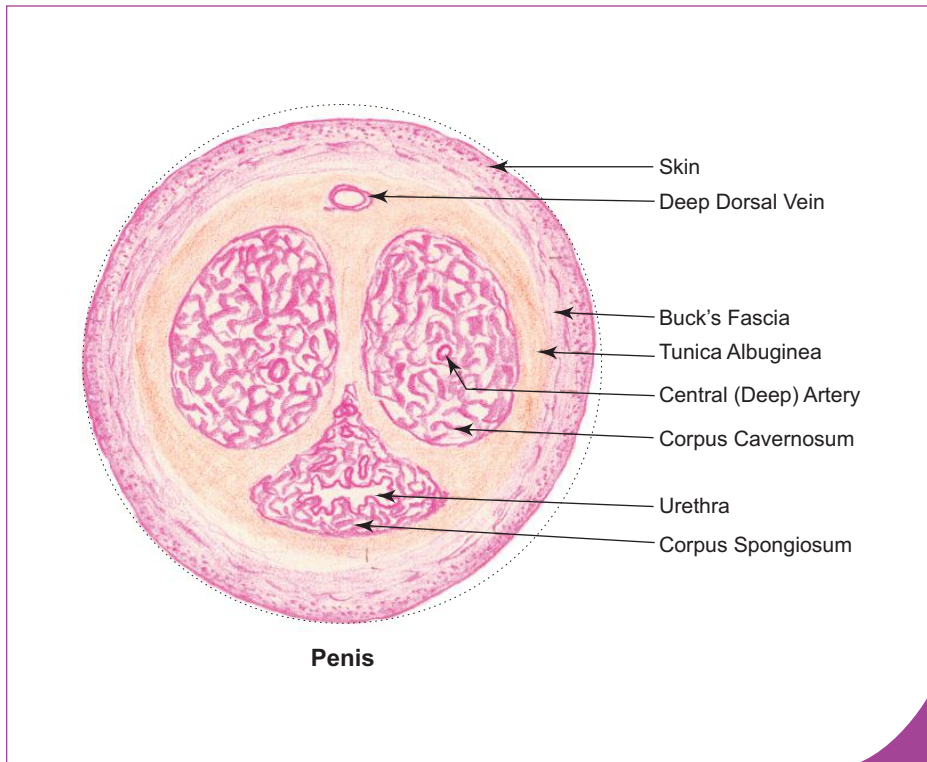


Fig. 14.6 C.S. of penis.



**Box 14.6** Penis.

Presence of

- (i) paired **corpora cavernosa**;
- (ii) **single** corpus spongiosum **traversed by penile urethra (lined by stratified columnar epithelium)**;
- (iii) thick tunica albuginea.



The penile urethra appears as a transverse slit in cross section but the external urethral meatus is a vertical slit. As a result when any fluid, whether urinary or seminal, is ejected outside, the flow is in the form of a spiral jet. This mechanism helps during ejaculation in mixing very well the components of seminal fluid derived from different sources. Thus, the terminal part of the male urethra acts as a mini mixer. (S.C. Mitra: Anatomy of the male urethra. *Indian Journal of Surgery*, Vol. 47, No. (2&3), 1985, pp 51 & 52.)

## MICROSCOPIC STRUCTURE

- The erectile cavernous tissue of corpora cavernosa and corpus spongiosum is made of endothelium-lined cavernous spaces separated by trabeculae. The trabeculae contain collagen, elastic and smooth muscle fibres.
- The cavernous spaces receive blood from the dorsal and deep arteries of penis and also from bulbourethral artery. Blood leaves the cavernous spaces through the dorsal veins.
- During erection of penis, blood fills the cavernous spaces because of vasodilatation of arteries mediated by the parasympathetic fibres causing engorgement of the spaces resulting in compression of peripheral veins restricting venous outflow.
- Penile urethra has an irregular outline due to the presence of deep outpocketings called *sinuses of Morgagni*. It is lined by stratified columnar epithelium. The urethra is lubricated by mucous secretion of *paraurethral glands of Littre*, which open into the outpocketings of penile urethra.
- The glans penis, external urethral meatus and the navicular fossa are lined by stratified squamous epithelium.

# Self-assessment Exercise

## I. Write Short notes on:

- (a) Histology of testis
- (b) Seminiferous tubule
- (c) Sertoli cell
- (d) Spermatogenesis
- (e) Structure of sperm
- (f) Structure of epididymis
- (g) Histology of prostate
- (h) Seminal vesicle

## II. Fill in the blanks:

1. The hormone produced by interstitial cells of Leydig is \_\_\_\_\_
2. Rete testis is present in \_\_\_\_\_ testis.
3. The morphological transformation of spermatids into spermatozoa is called \_\_\_\_\_
4. The condensed and calcified secretion present in the lumen of prostatic alveoli is called \_\_\_\_\_
5. The lining epithelium of epididymis and vas deferens are provided with nonmotile cilia called \_\_\_\_\_

## III. Choose the best answer:

1. Testis has the following coverings *except*
  - (a) tunica adventitia
  - (b) tunica vasculosa
  - (c) tunica albuginea
  - (d) tunica vaginalis
2. The approximate time taken for a spermatogonium to become spermatozoa is
  - (a) 64 hours
  - (b) 64 days
  - (c) 24 hours
  - (d) 24 days
3. The number of chromosomes and the amount of DNA present in a secondary spermatocyte is
  - (a)  $46 + 4n$
  - (b)  $46 + 2n$
  - (c)  $23 + 4n$
  - (d)  $23 + 2n$
4. The epithelium lining the ductus epididymis is
  - (a) simple columnar
  - (b) transitional
  - (c) stratified columnar
  - (d) pseudostratified columnar

5. Which enzyme is increased in serum of patients with prostatic tumour?
  - (a) Acid phosphatase
  - (b) Alkaline phosphatase
  - (c) Prostaglandin
  - (d) Amylase
6. Upper half of prostatic urethra is lined by the following epithelium
  - (a) stratified columnar
  - (b) stratified squamous
  - (c) transitional
  - (d) pseudostratified columnar
7. Which of the following statements is **incorrect** about prostatic carcinoma? It
  - (a) affects the main glands of prostate
  - (b) affects the mucosal glands of prostate
  - (c) causes obstruction of the urethra
  - (d) causes elevation of serum PSA level
8. The secretion of seminal vesicle is rich in
  - (a) citric acid
  - (b) acid phosphatase
  - (c) fibrinolysin
  - (d) fructose
9. Corpora amylacea are present in which of the following organs?
  - (a) Pineal gland
  - (b) Penis
  - (c) Prostate
  - (d) Ovary
10. Tunica albuginea is present in all, *except*
  - (a) penis
  - (b) epididymis
  - (c) testis
  - (d) ovary

**IV. State whether the following statements are true (T) or false (F):**

1. Secondary spermatocytes are smaller than primary spermatocytes ( )
2. Type A spermatogonia are involved in spermatogenesis ( )
3. Blood testis barrier is formed by Sertoli cells ( )
4. Smooth muscle present in the ductus epididymis and ductus deferens, is richly innervated by parasympathetic fibres ( )
5. In the epididymis, the height of the epithelium gradually decreases but the muscle gradually increases from head to tail ( )
6. The subcutaneous tissue in penis is devoid of fat ( )
7. The bulbourethral glands are present in the superficial perineal pouch ( )
8. The urethra at the glans penis is lined by stratified squamous epithelium ( )
9. Leydig cells have basophilic cytoplasm ( )
10. Secondary spermatocytes are rarely encountered in a section of testis ( )

V. Match the items in column 'A' with those of column 'B':

<b>Column 'A'</b>		<b>Column 'B'</b>	
A.	<i>Parts of spermatozoa</i>		<i>Derived from</i>
	1. Acrosomal cap ( )	(a)	Nucleus
	2. Flagellum ( )	(b)	Mitochondria
	3. Middle piece ( )	(c)	Centriole
	4. Head ( )	(d)	Golgi apparatus
B.	<i>Cell</i>		<i>Function</i>
	1. Sertoli cell ( )	(a)	Testosterone secretion
	2. Leydig cell ( )	(b)	Support
	3. Myoid cell ( )	(c)	Spermatogenesis
	4. Spermatogonia ( )	(d)	Contraction

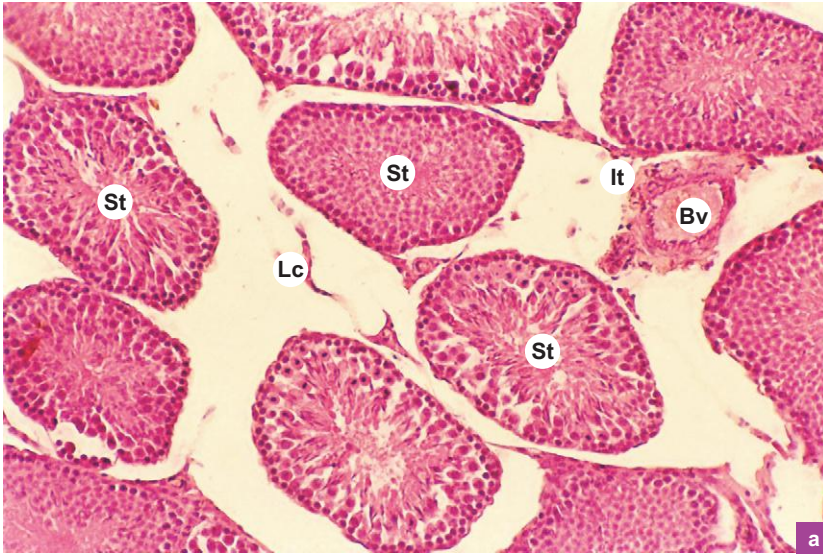**Answers**

- II.** 1. Testosterone    2. Mediastinum    3. Spermiogenesis    4. Prostatic concretions or corpora amylacea  
5. Stereocilia.
- III.** 1. a    2. b    3. d    4. d    5. a    6. c    7. b    8. d    9. c    10. b
- IV.** 1. (T)    2. (F)    3. (T)    4. (F)    5. (T)    6. (T)    7. (F)    8. (T)    9. (F)    10. (T)
- V.** A. 1. d    2. c    3. b    4. a  
B. 1. b    2. a    3. d    4. c

# Practical No. 14

## Male Reproductive System

X100



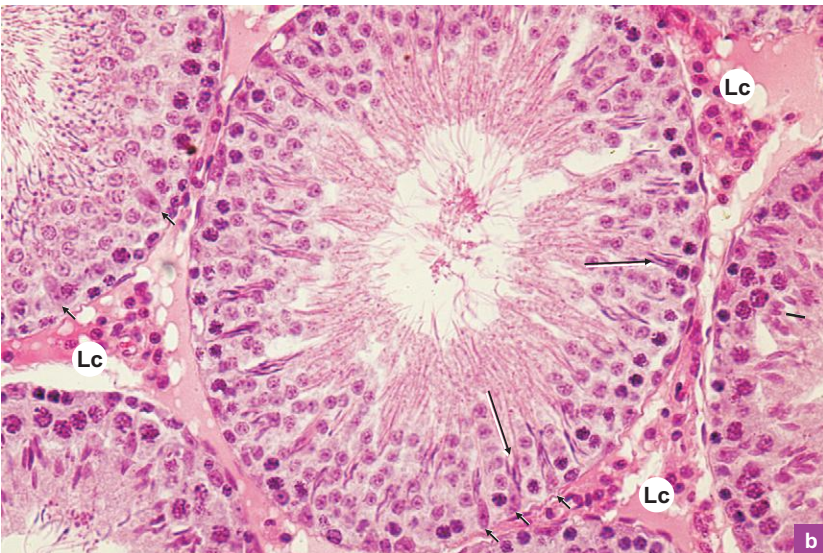a

### Plate 14:1a Testis.

At low magnification (Plate: 14:1a) identify the following structures:

- Thick collagenous connective tissue capsule at the periphery, *tunica albuginea* (not seen).
- Vascular loose connective tissue deep to tunica albuginea, *tunica vasculosa*.
- Sections of *seminiferous tubules* (St) embedded in interstitial connective tissue (It).
- Groups of *interstitial cells of Leydig* (Lc) in the interstitium and blood vessel (Bv).

X400



b

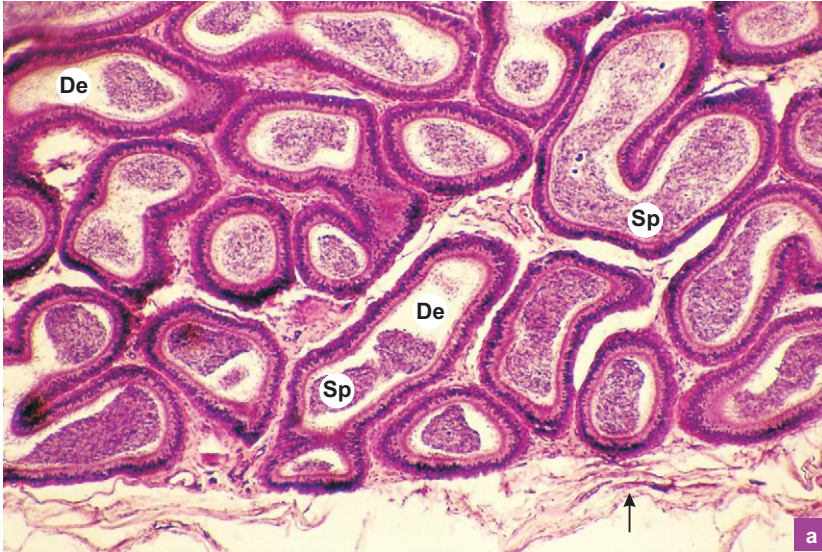
### Plate 14:1b Testis (seminiferous tubule).

Observe the seminiferous tubules at high magnification (Plate 14:1b) and note the following features:

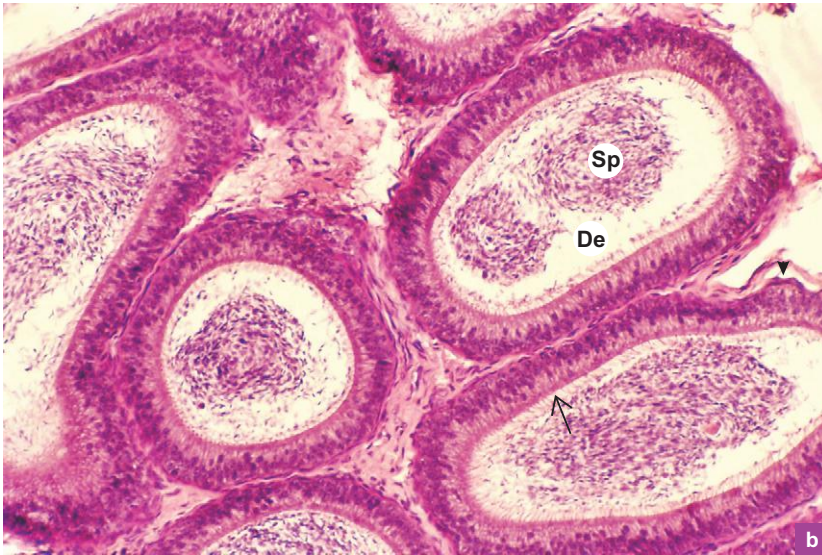
- Spermatogenic cells forming a stratified epithelium. The arrangement of cells from basement membrane to lumen: spermatogonia, spermatocytes (mainly primary spermatocytes having large nucleus with coarse chromatin clumps), spermatids and sperms successively.
- The sperms are often found in clusters (**big arrow**) embedded in the cytoplasm of Sertoli cells.
- The tall columnar Sertoli cells with characteristic pale staining oval or triangular nuclei with well developed nucleoli (**small arrow**). These cells have indistinct cell boundaries because of the presence of cytoplasmic processes.

Also note groups of large acidophilic cells in the spaces between the seminiferous tubules. They are the Leydig cells (Lc).

X40



X100



### Plate 14:2a Epididymis. and b

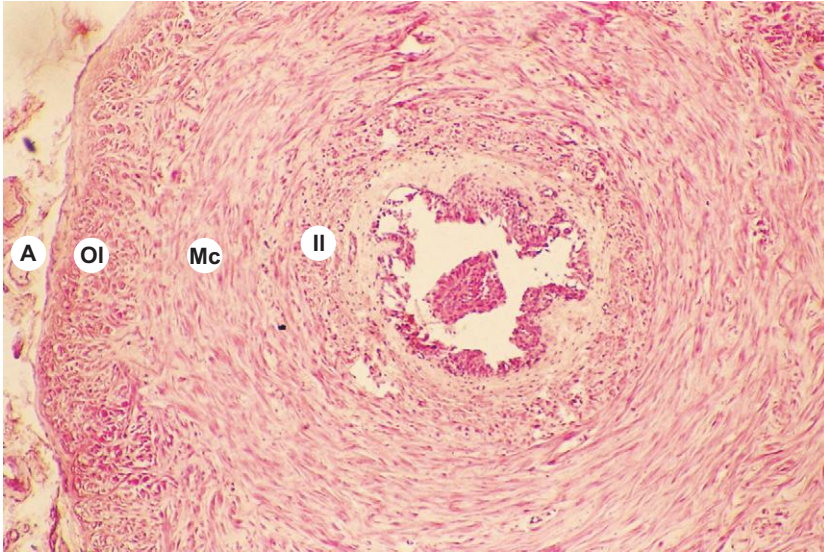
Examine the epididymis at low magnification (Plate 14:2a) and note the following features:

- Connective tissue capsule at the periphery (**arrow**).
- Sections of *ductus epididymis* (**De**) supported by connective tissue carrying blood vessels and nerves.
- Clumps of *spermatozoa* (**Sp**) in the lumen.

At a still higher magnification (Plate 14:2b) observe the following features:

- The lining epithelium which is of *pseudostratified columnar* variety with stereocilia (**arrow**).
- Circularly arranged smooth muscle fibres around the ductus epididymis (**arrow head**).
- Clumps of spermatozoa in the lumen (**Sp**).

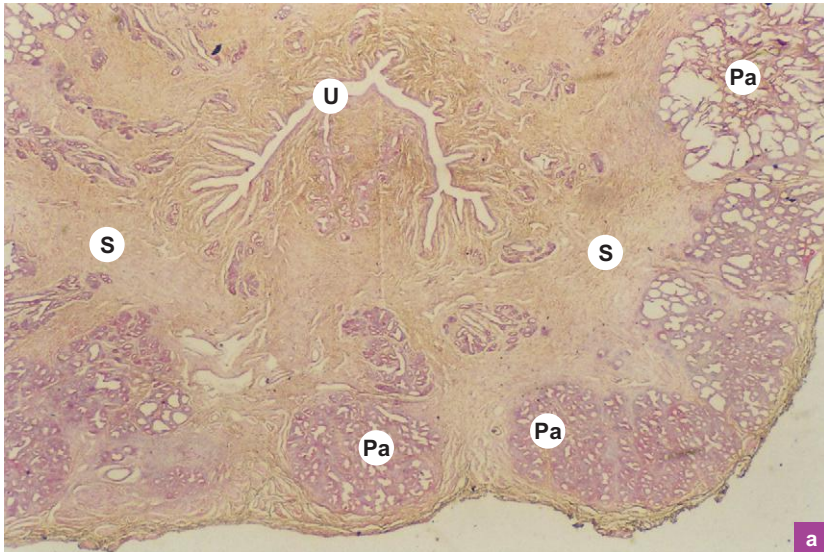
X40

**Plate 14:3 Vas deferens.**

Appreciate the following features at low magnification (Plate 14.3):

- Small irregular lumen lined by *pseudostratified columnar epithelium* with stereocilia.
- Presence of *spermatozoa* in the lumen.
- A *thick layer of smooth muscle fibres* arranged in inner longitudinal (II) middle circular (Mc) and outer longitudinal (OI) layers.
- External adventitial coat (A) carrying blood vessels and nerves.

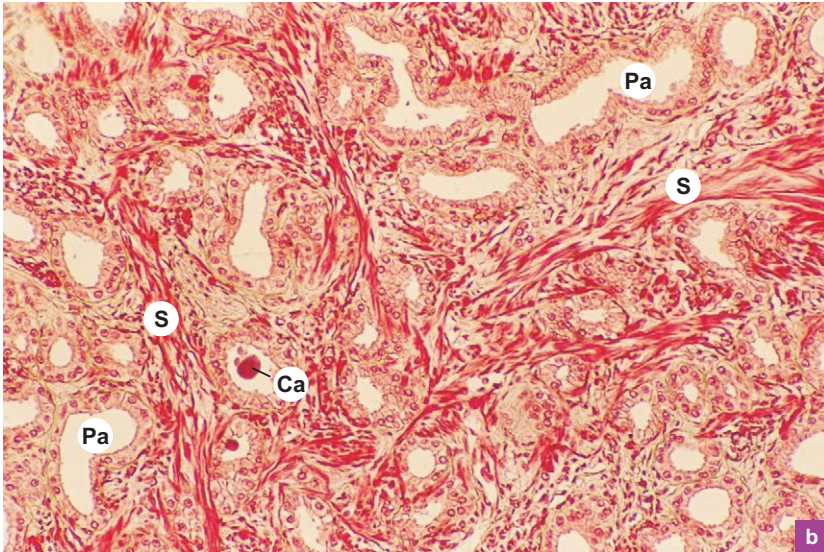
X10

**Plate 14:4a Prostate (panoramic view).**

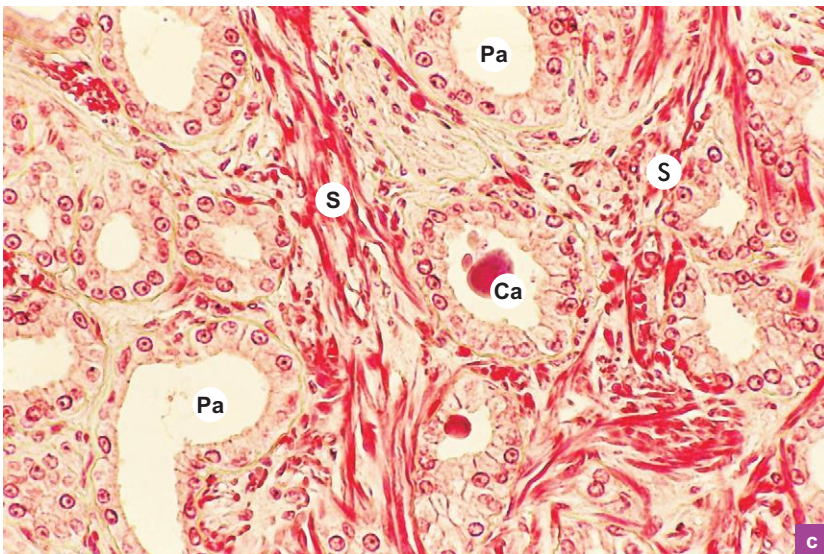
The arrangement of glandular tissue around the urethra can be well appreciated under the scanner (Plate 14:4a). Note the following features:

- Crescentic prostatic urethra (U) with many outpocketings giving an irregular outline to it.
- Prostatic alveoli (Pa) embedded in a fibromuscular stroma (S).
- Large main glands at the periphery and small glands near the urethra.

X100



X200



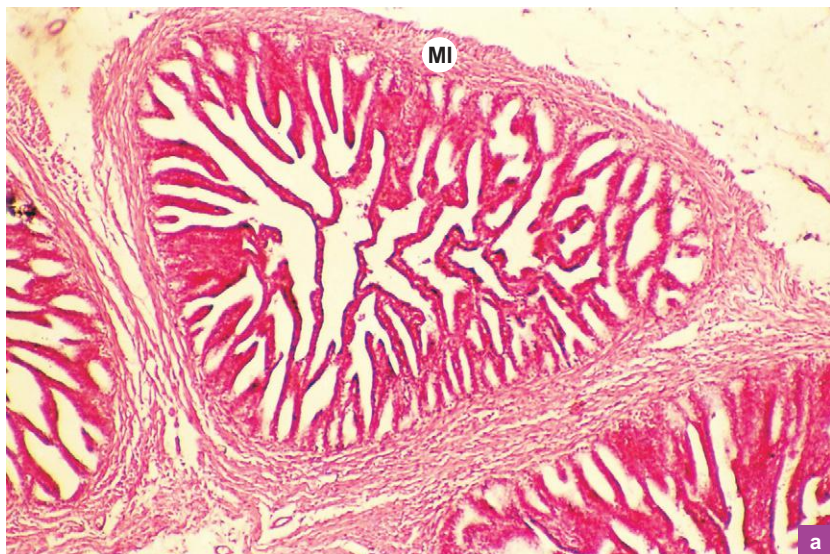**Plate 14:4** Prostate.  
**b and c**

Examine the section at low and high magnifications (Plate 14:4b and c) and note the following features:

- Large irregular prostatic alveoli (**Pa**) lined by simple columnar or *pseudostratified columnar epithelium*.
- Prostatic concretions or *corpora amylacea* (**Ca**; condensed secretion) in the wide lumen.
- *Fibromuscular stroma* (**S**) made of fibrous tissue intermixed with smooth muscle fibres.
- The *prostatic urethra* lined by transitional epithelium (not seen).



X40



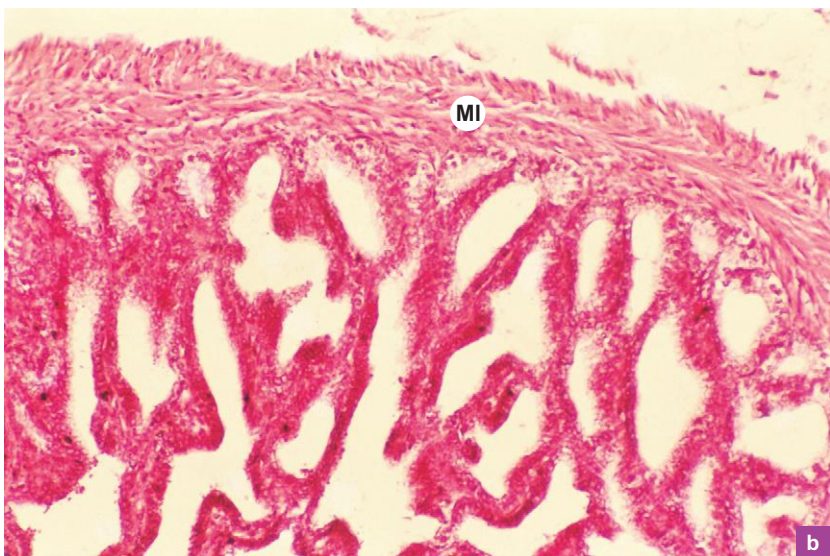
a

**Plate 14:5** Seminal vesicle.  
a and b

Appreciate the following features at low and high magnifications (Plate 14:5a and b):

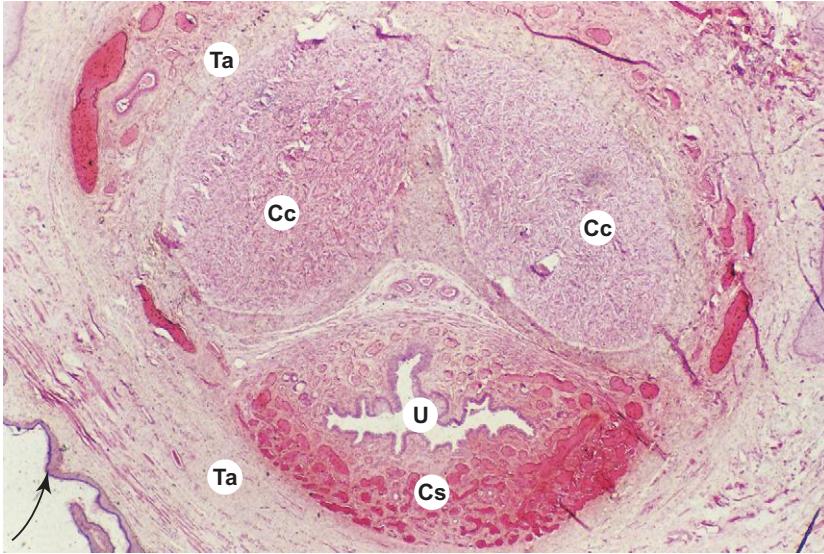
- Complex folds of mucous membrane which branch and anastomose, giving the lumen a *honeycomb appearance*.
- *Pseudostratified columnar epithelial lining*.
- Muscle layer (**MI**) formed by smooth muscle fibres which are arranged into inner circular and outer longitudinal layers.

X100



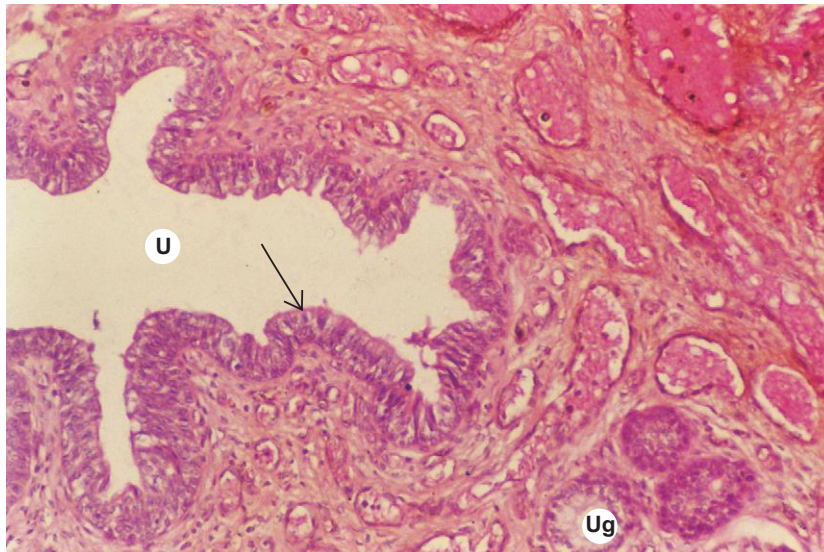
b

X10

**Plate 14:6** Penis.

- A cross section of the penis under scanner (Plate 14:6) illustrates the general arrangement of the three cavernous bodies, namely, the two corpora cavernosa (Cc) on the dorsal aspect and a single *corpus spongiosum* (Cs) on the ventral aspect traversed by the *penile urethra* (U).
- Note the thick fibrous connective tissue sheath, the *tunica albuginea* (Ta) that surrounds the three erectile bodies.
- Note also the external delicate thin skin (**arrow**) made of epidermis and dermis. There is no subcutaneous fat.

X100

**Plate 14:7** Penile urethra.

At low magnification (Plate 14:7), examine the penile urethra:

- Penile urethra (U) is irregular in outline due to the presence of many outpocketings. The paraurethral glands (Ug) open into these outpocketings.
- Note that the urethra is lined by stratified columnar epithelium (**arrow**).
- Also note the high vascularity of the erectile tissue.

"This page intentionally left blank"

# 15

# FEMALE REPRODUCTIVE SYSTEM

## INTRODUCTION

The female reproductive system consists of a group of internal sex organs present in the pelvic cavity and external sex organs situated outside. The internal sex organs are a pair of ovaries, a pair of uterine or Fallopian tubes, uterus and vagina (Fig 15.1). The external sex organs are the external genitalia and the mammary glands (female breasts). The mammary glands placenta and umbilical cord are included here as part of the system because their development and function are directly related to the female reproductive system.

The reproductive life of a female starts at puberty at the age of 13 to 15 years when structural and functional changes occur in ovaries, uterus and breast. The onset of reproductive phase of life is marked by initiation of *menstrual cycle (menarche)*, which occurs regularly and is of 28-day duration. It continues till *menopause* when the menstrual cycle ceases at the age of 45–55 years. Thus, the reproductive life span (fertility period) of a woman lasts for about 30–40 years.

At birth there are about 4,00,000 oocytes present in the ovaries. Most of them undergo degeneration (atresia) before puberty. At puberty there are about 40,000 oocytes present. Of these, only about 400 oocytes undergo ovulation during the reproductive period of an individual. The rest undergo atresia at different stages.

## OVARY

### GENERAL FEATURES

- Ovaries are female gonads that produce ova and hormones like oestrogen and progesterone.
- They are almond-shaped structures attached to the back of broad ligament by a fold of peritoneum, the *mesovarium*.
- Each ovary measures about 3 cm in length, 1.5 cm in width and 1 cm in thickness.

### STRUCTURE

- The surface of the ovary is covered by a layer of simple cuboidal epithelium called *germinal epithelium* which is continuous with mesothelium of peritoneum. The term 'germinal epithelium' is a misnomer because it does not give rise to germ cells (oocytes).
- The germinal epithelium rests on a layer of dense connective tissue called *tunica albuginea*.
- In sectional view, the ovary shows a peripheral cortex and a central medulla. (The boundary between cortex and medulla is indistinct.)
- *Medulla* is made of loose fibroelastic connective tissue containing blood vessels, lymphatics and nerves. It is continuous with mesovarium at the hilum. Here there are cells (hilus cells) with characteristics similar to interstitial cells of Leydig are found. They may be a source of androgen from ovary.
- *Cortex* occupies the greater part of the ovary and it contains *ovarian follicles* at different stages of maturation and degeneration. It may also contain *corpus luteum* and *corpus albicans*. The follicles are embedded in a highly cellular connective tissue stroma, mainly made of large spindle-shaped fibroblasts (Fig. 15.2; Box 15.1).
- During the course of each menstrual cycle a group of ovarian follicles start maturing under the influence of follicle stimulating hormone (FSH). But usually only one attains full maturity while others degenerate (atretic follicles) at various stages of growth.

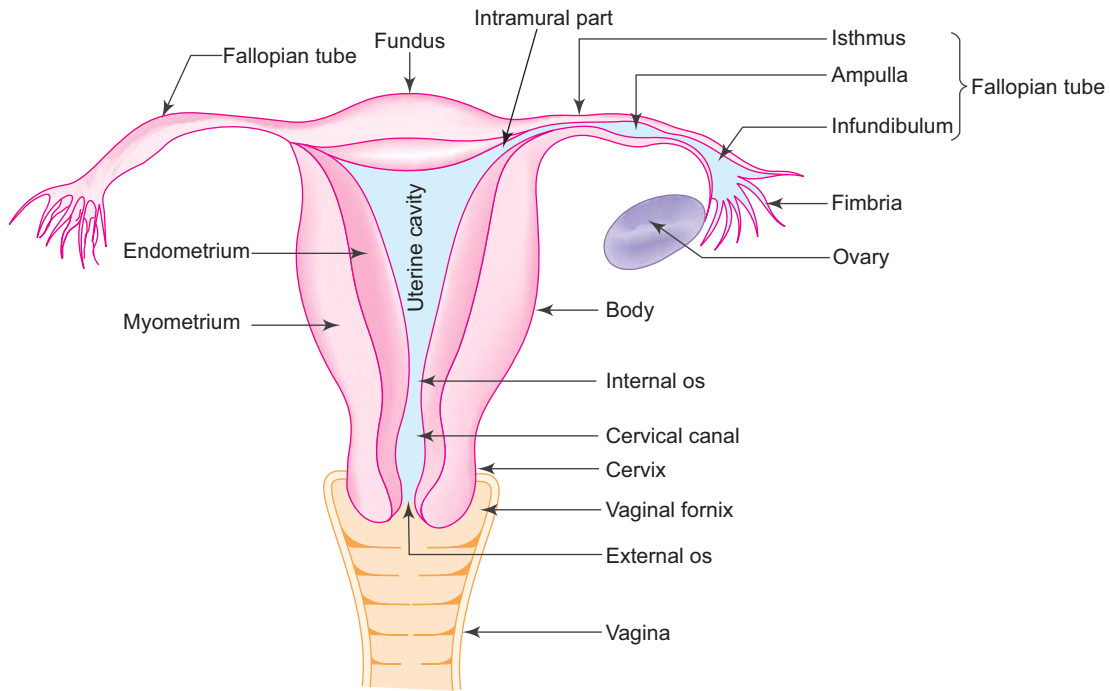


Fig. 15.1 Parts of female reproductive system.

## DEVELOPMENT OF OVARIAN FOLLICLE

The follicular growth and maturation pass through four stages as described below—the process is called *folliculogenesis*.

### 1. Primordial follicle

- Primordial follicles are the smallest and simplest in structure, located at the periphery of the cortex. Each follicle consists of a primary oocyte (20–25  $\mu\text{m}$ ) surrounded by a single layer of squamous follicular cells (Fig. 15.3).

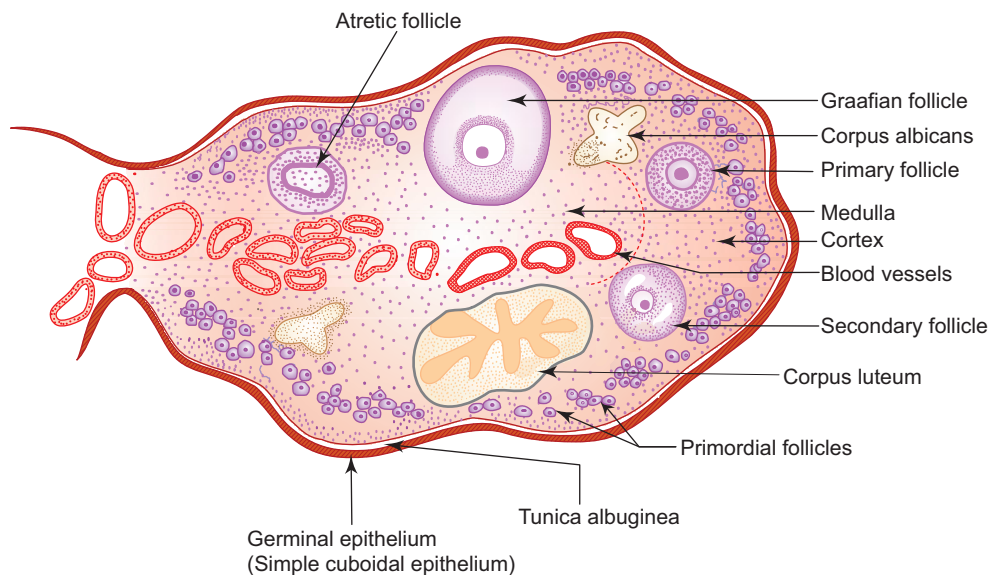
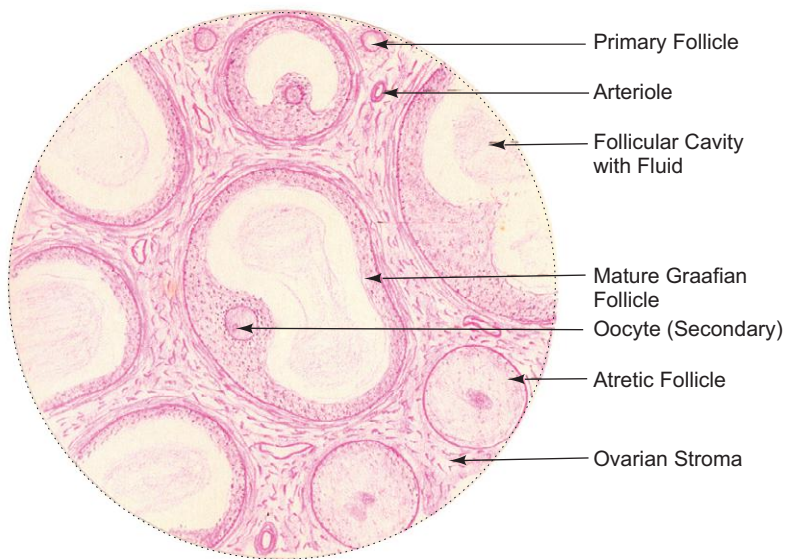


Fig. 15.2 L.S. of ovary.

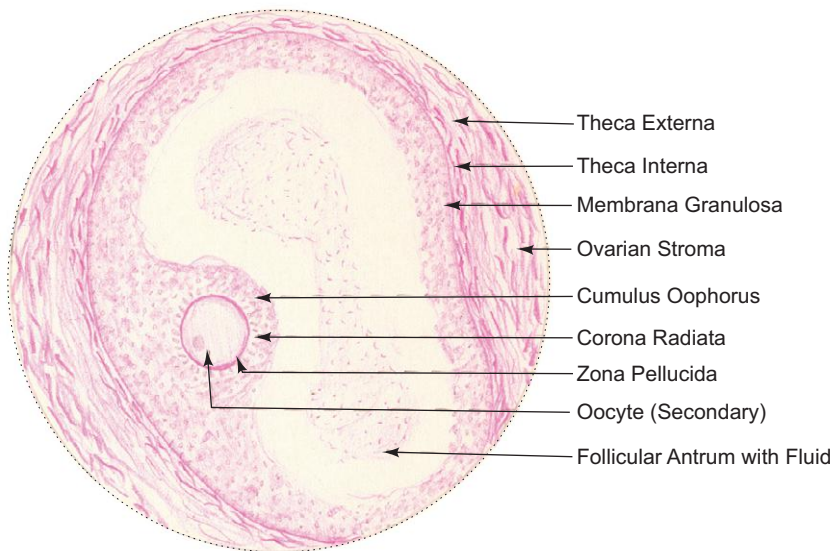
**Box 15.1 Ovary.**

*Presence of*

- (i) **growing ovarian follicles** at various stages of maturation (primordial, primary, secondary and Graafian follicles);
- (ii) simple cuboidal **germinal epithelium**;
- (iii) tunica albuginea;
- (iv) corpus albicans and **atretic follicles**;
- (v) corpus luteum (sometimes).



**Ovary**



**Graafian follicle**

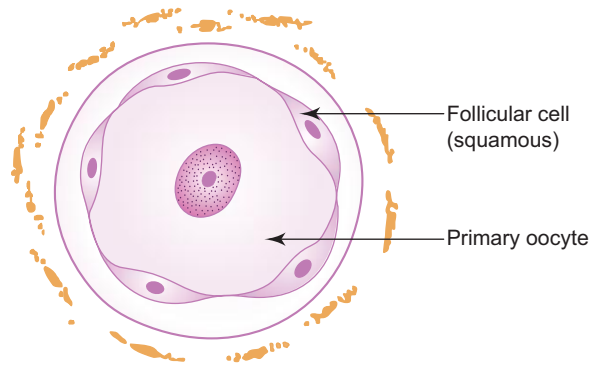


Fig. 15.3 Primordial follicle.

## 2. Primary follicle

- The primordial follicle changes into primary follicle under the influence of FSH and shows the following changes:
  - Primary oocyte enlarges in size (50–80  $\mu\text{m}$  diameter).
  - Flattened squamous follicular cells become cuboidal (*unilaminar primary follicle*—Fig. 15.4) and then divide to form stratified cuboidal layer of granulosa cells (*multilaminar primary follicle*—Fig. 15.5). The outermost layer of follicular cells rests on a well defined *basement membrane* that separates it from the ovarian stroma.
  - The oocyte is separated from the surrounding follicular cells by a glycoprotein layer (derived from both) called *zona pellucida*.
  - The connective tissue stroma surrounding the follicle begins to condense and form *theca folliculi*. Theca folliculi later differentiate into two layers.

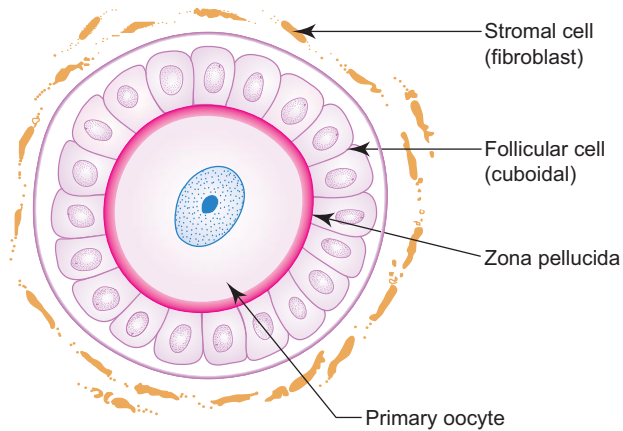


Fig. 15.4 Primary follicle: unilaminar.

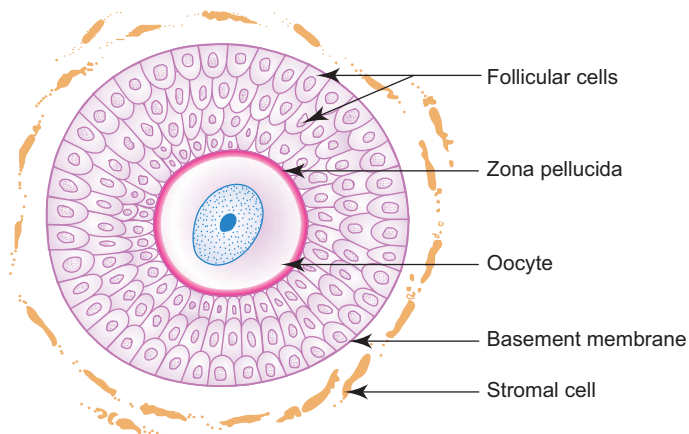


Fig. 15.5 Primary follicle: multilaminar.

### 3. Secondary (antral) follicle

- The primary follicle becomes the secondary follicle (Fig. 15.6) after undergoing following changes:
  - The oocyte enlarges and reaches its full size (125  $\mu\text{m}$ ).
  - Irregular fluid filled spaces appear among the follicular cells and join to form a crescentic space or *antrum* filled with *liquor folliculi*.
  - The follicle increases in size (2 mm) mainly due to the formation of antrum and liquor folliculi.
  - The theca folliculi differentiates into two layers, an internal cellular layer, *theca interna* and an outer fibrous layer, *theca externa*. Follicular cells and cells of theca interna secrete oestrogen (Fig. 15.6).

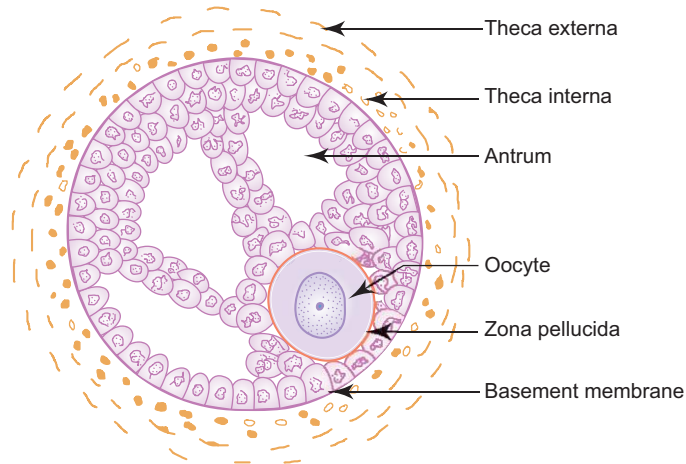


Fig. 15.6 Secondary follicle.

### 4. Mature Graafian (tertiary) follicle

- With further development the follicle enlarges in size as fluid accumulates in the antrum dividing the follicular cells into two sets:
  - The outer set of cells that lines the cavity forms the *membrana granulosa* and the inner set that surrounds the ovum and attaches it to one pole of the follicle forms the *cumulus oophorus*. Now the Graafian follicle measures about 10 mm or more in diameter and is seen bulging out of cortex on the surface (Fig. 15.7; Box 15.1).
  - At this stage the primary oocyte completes its first meiotic division and becomes a *secondary oocyte* (ovum). (*It is worth noting that all the primary oocytes enter into prophase of 1st meiotic division during foetal life but meiosis remains arrested at that stage till just before ovulation*).
- At mid-cycle (about 14th day of a 28-day cycle), under the influence of oestrogen, there is a sudden increase in the amount of liquor folliculi causing rupture of the mature follicle and release of the secondary oocyte along with one layer of loosely adherent *granulosa cells* (*corona radiata*) into the peritoneal cavity. This process is called *ovulation* (Fig. 15.8). From the peritoneal cavity the ovum is rapidly drawn into the uterine tube.

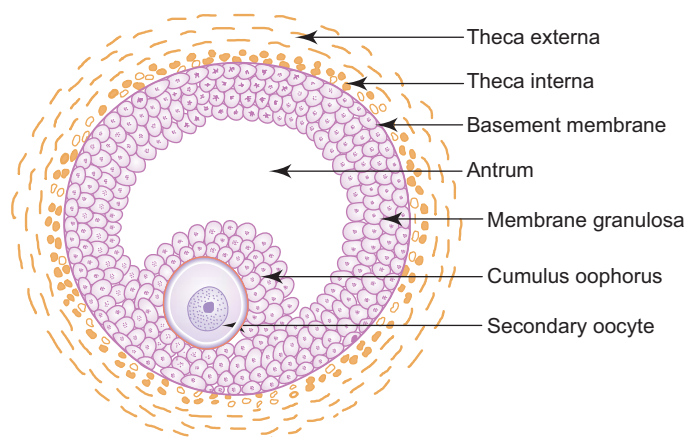
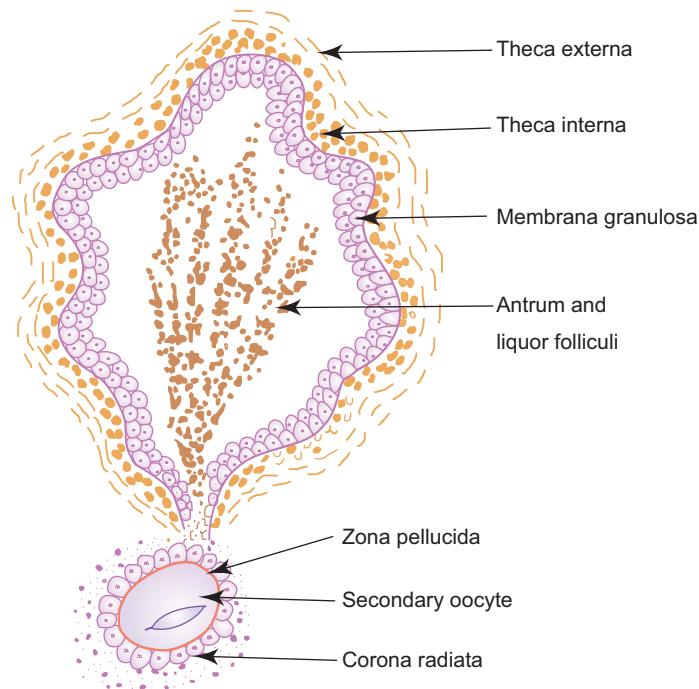


Fig. 15.7 Graafian follicle: mature.





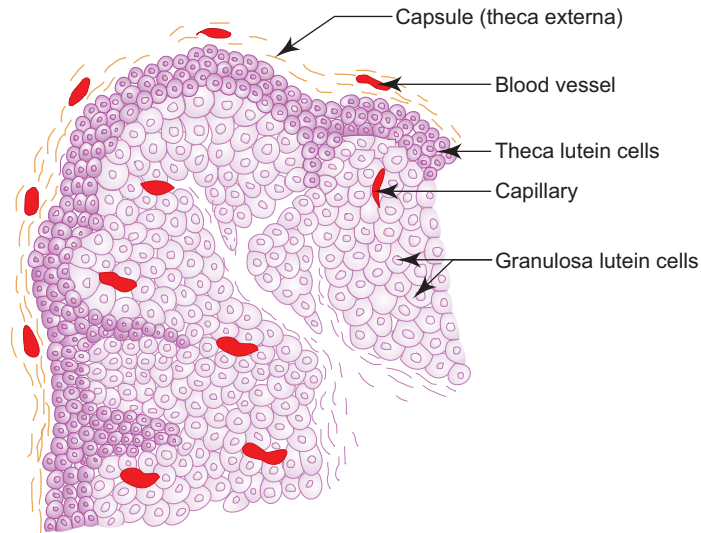
**Fig. 15.8** Ovulating follicle.

#### ***Atretic follicle***

- Several ovarian follicles start maturing during each ovarian cycle, but only one attains full maturity and undergoes ovulation. The other follicles degenerate (*atresia*) at various stages of maturation and become atretic follicles.
- In the process of follicular atresia, the peripheral vascular stroma invades the theca interna, membrana granulosa and antrum.
- In the early stage of degeneration, the granulosa cells and the oocyte are shed into the antrum and degenerate. The wrinkled zona pellucida remains in the antrum for some time.
- The basement membrane between the granulosa and theca cells gets thickened and folded and is now called *hypertrophied glassy membrane*.
- Finally, in the late stage, the entire follicle is replaced by connective tissue stroma and the folded hypertrophied glassy membrane remains for some time as the only indication of a follicle.

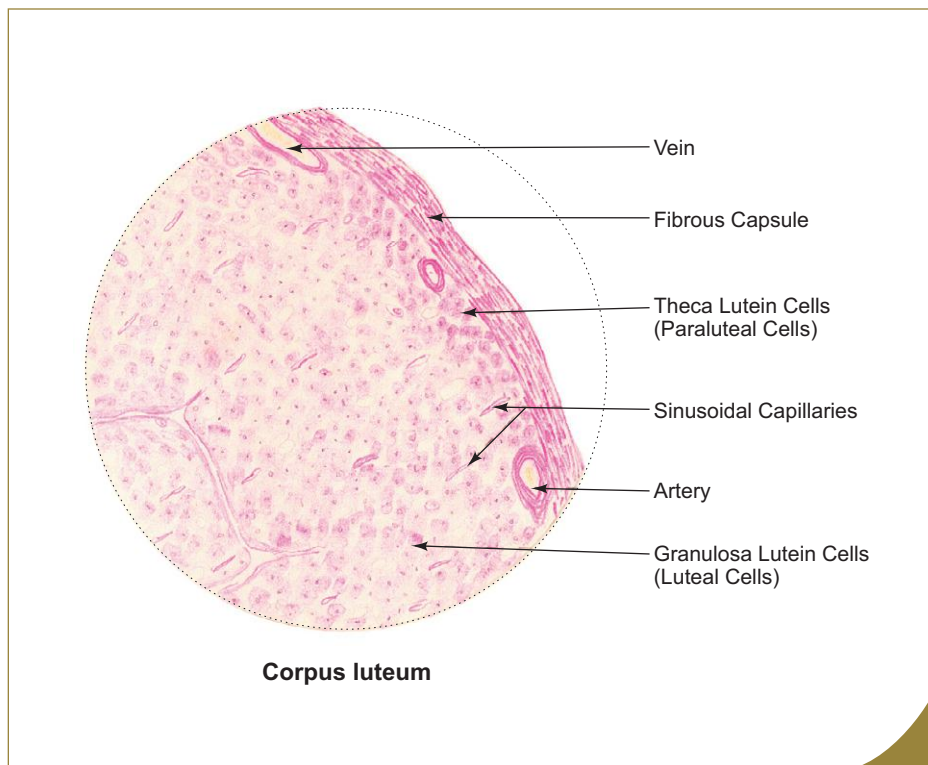
#### ***Corpus luteum***

- After ovulation the wall of the follicle collapses, becomes infolded and gets transformed into a *temporary endocrine organ*, the corpus luteum.
- Theca externa forms a poorly defined capsule around the developing corpus luteum. It invades the granulosa cells along with blood vessels from the periphery to occupy the remnant of follicular cavity in the centre.
- The cells of theca interna and granulosa cells undergo hypertrophy and are filled with lipochrome pigments to become *lutein cells*.
- These lutein cells contain lipid droplets, abundant smooth endoplasmic reticulum and mitochondria (these are the characteristic features of steroid-synthesizing cells).
- Thus two types of lutein cells are seen in corpus luteum (Fig. 15.9; Box 15.2), *viz.*,
  - (a) *Granulosa lutein cells*, that form the predominant cell type of corpus luteum are derived from granulosa cells. They are large pale-staining cells with vesicular nuclei found at the deeper part of corpus luteum. They synthesise and secrete the hormone *progesterone*.
  - (b) *Theca lutein cells* are derived from theca interna cells. They are much smaller, less numerous and darker than the granulosa lutein cells. They are found at the periphery and along the connective tissue strands that invade the structure. These cells secrete *oestrogen*.



**Fig. 15.9** Structure of corpus luteum.

- If the liberated ovum is fertilised, the corpus luteum will survive for 4–5 months under the influence of human chorionic gonadotropin (HCG) and is called *corpus luteum of pregnancy*. If fertilization does not occur, the corpus luteum functions for only 10–12 days and is called *corpus luteum of menstruation*.
- After its functional activity is over, it undergoes regression and is replaced by a fibrous hyalinised scar, the *corpus albicans* (“White body”).



**Box 15.2** Corpus Luteum.

Presence of

- (i) large, lightly stained **granulosa lutein cells** in the centre;
- (ii) small, deeply stained **theca lutein cells** at the periphery;
- (iii) numerous capillaries among the lutein cells.

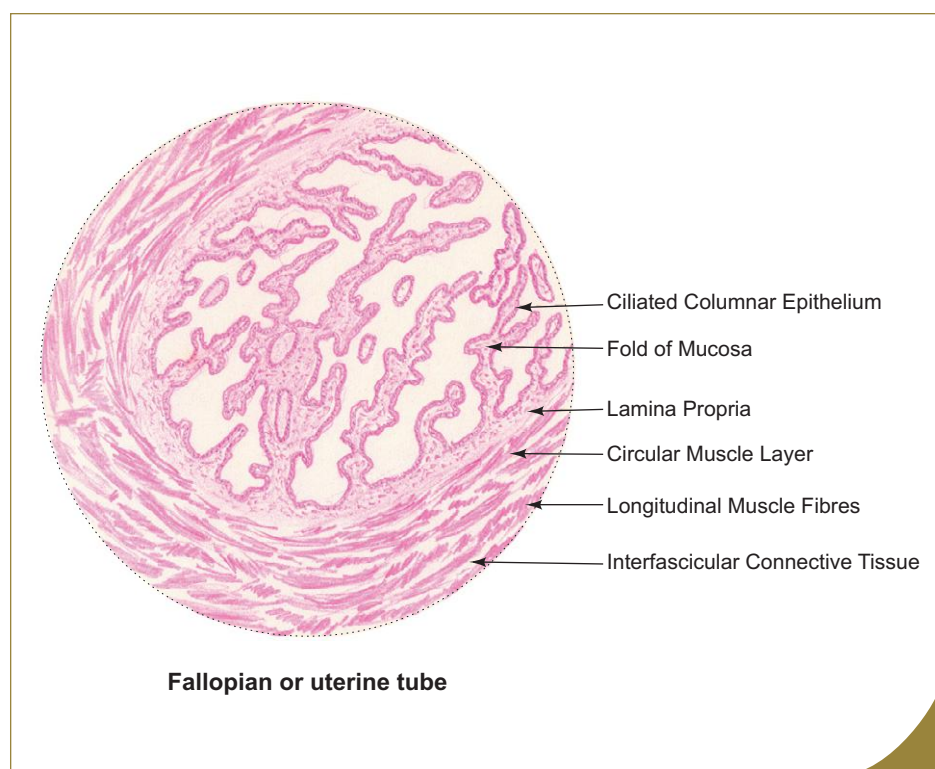
## UTERINE TUBE (FALLOPIAN TUBE)

### GENERAL FEATURES

- Uterine tubes are paired muscular tubes situated in the upper free border of broad ligament on either side of uterus. It is about 10–12 cm long. Its lateral end opens into the peritoneal cavity close to the ovary and its medial end opens into the uterine cavity.
- Uterine tube nourishes and transports the ovum/zygote to the uterine cavity.
- The cilia of the lining epithelium and the rhythmic contraction of the muscle layer are responsible for the transport of ovum.
- Each uterine tube is divided into four segments, namely, infundibulum, ampulla, isthmus and intramural part from lateral to medial. Infundibulum is a funnel-shaped structure provided with fimbria, ampulla is the dilated part where fertilization takes place. Isthmus is the narrow part preceding the intramural part (Fig. 15.1).

### STRUCTURE

- The uterine tube wall is made of three coats (Box 15.3), namely,
  1. **Mucosa**
    - It includes the lining epithelium and the thin underlying lamina propria.
    - The lining epithelium is simple ciliated columnar epithelium and is made of two types of cells, namely, *ciliated columnar cells* and *nonciliated peg (secretory) cells*. The ciliated cells are generally shorter than the secretory peg cells, making the luminal surface of the epithelium somewhat uneven. The proportion of ciliated and nonciliated cells varies with the stages of menstrual cycle. Ciliated cells are more during proliferative phase and less during secretory phase.
    - Mucosa presents many branching folds that make the lumen of uterine tube highly irregular. This arrangement helps in providing nutrition to the fertilised ovum from all sides. (The folds are more complex in ampulla.)
  2. **Muscle layer**
    - This layer is made of smooth muscle which is arranged in inner circular and outer longitudinal layers.
  3. **Serosa**
    - It consists of mesothelium (peritoneum of broad ligament) supported by connective tissue.



#### Box 15.3 Fallopian or Uterine Tube.

Presence of

- (i) **highly folded mucosa** lined by **simple columnar ciliated epithelium**;
- (ii) cellular lamina propria;
- (iii) thick inner circular muscle coat.

## UTERUS

### GENERAL FEATURES

- Uterus is a thick pear-shaped muscular organ present in the pelvic cavity.
- It provides a suitable site and environment for implantation of blastocyst and growth of foetus. It is divided into three parts, namely, fundus, body and cervix.
- It measures 7.5 cm in length, 5 cm in width and 2.5 cm in thickness.
- During pregnancy it undergoes massive enlargement and comes to occupy the abdomen.

### STRUCTURE

- The uterine wall is made of three coats (Box 15.4)—an outer perimetrium (serosa), a thick middle myometrium (muscle layer) and an inner endometrium (mucosa):

#### 1. Perimetrium

- It is the outer serous coat of uterus and is composed of mesothelial lining (simple squamous epithelium) supported by connective tissue rich in blood vessels and elastic fibres. It is continuous with the broad ligament.

#### 2. Myometrium

- It forms the middle muscular coat, 15 mm thick. It is composed of smooth muscle fibres arranged in three ill-defined layers. The fibres in the inner and outer layers are arranged longitudinally (parallel to the long axis of uterus). The middle layer is very thick containing circularly arranged muscle fibres, numerous blood vessels and lymphatics. Because of the high vascularity, this layer is called *stratum vasculare*. During pregnancy the muscle fibres undergo hyperplasia and hypertrophy.

#### 3. Endometrium

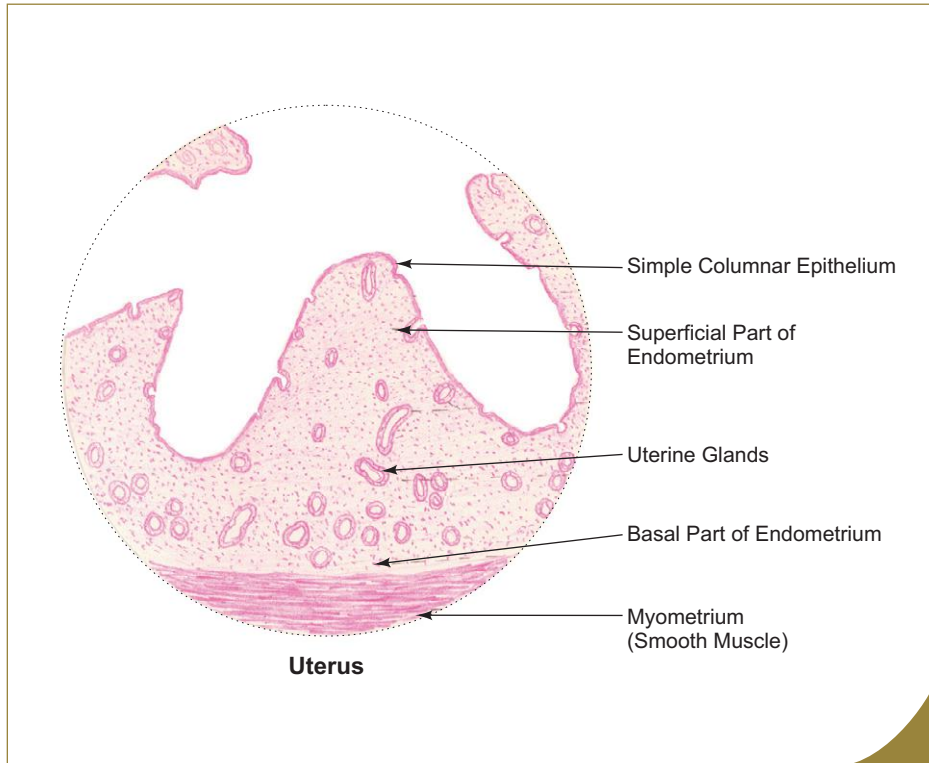
- Endometrium is the mucosal lining of the uterine cavity.
- It is made of the lining epithelium (simple columnar epithelium—partly ciliated) and the underlying connective tissue stroma (lamina propria) which is highly cellular and contains large amount of ground substance and no collagen fibres. The lamina propria contains many blood vessels and simple tubular *uterine glands* which are coiled in the deeper part.
- Endometrium of uterus is normally divided into two layers: the superficial *stratum functionalis* (two-thirds) and the deep *stratum basalis* (one-third).
- The arteries in the endometrium are of two types—(i) *Straight or basal arteries*—supply the stratum basalis and (ii) *coiled or spiral arteries*—supply the functional stratum of the endometrium. Spiral arteries are highly sensitive to changes in hormone level (oestrogen and progesterone) during menstrual cycle.
- Stratum functionalis exhibits cyclic structural changes in response to ovarian hormones (oestrogen and progesterone). These changes prepare the uterus for implantation and nourishment of the embryo and foetus. If implantation does not occur, the superficial functional layer is shed during menstruation leaving the deep basal layer intact for reconstruction of a new functional layer.

### CYCLIC CHANGES IN THE ENDOMETRIUM

During each menstrual cycle, the endometrium undergoes cyclic changes that are closely related to maturation of ovarian follicles and formation of corpus luteum. These cyclic changes affect only the endometrium of fundus and body, and not the cervix. The cyclic changes of endometrium are divided into following three phases:

#### 1. Menstrual phase (menses): 1–4 days

- Menstrual phase begins when fertilization and implantation fail to occur and is marked by the vaginal discharge of menstrual flow containing blood, uterine fluid and fragments of necrotic endometrial tissue of the functional layer.
- This phase is triggered by the reduced level of circulating progesterone, owing to the regression of corpus luteum. This causes intermittent arterial dilatation and constriction (blushing and blanching of endometrium) resulting in rupture of spiral arteries leading to ischaemia and necrosis of the functional layer followed by shedding of endometrium. Shedding continues until only raw surface of the stratum basalis is left.



**Box 15.4 Uterus.**

Presence of

- (i) **highly cellular endometrium** containing uterine glands;
- (ii) simple columnar epithelium lining the uterine cavity;
- (iii) **thick myometrium** having a thick middle circular layer of smooth muscle with many blood vessels.

**Table 15.1** Structural differences in the endometrium of proliferative phase and secretory phase

	Proliferative phase	Secretory phase
<i>Diagram</i>		
<i>Thickness of endometrium</i>	2–3 mm	4–6 mm
<i>Lining epithelium</i>	Simple columnar epithelium	Hypertrophied columnar epithelium
<i>Uterine glands</i>	<ul style="list-style-type: none"> <li>● Few, simple straight tubular glands with narrow lumen</li> <li>● No synthesis and storage of glycogen by glandular epithelium</li> <li>● No secretory material in the glandular lumen</li> </ul>	<ul style="list-style-type: none"> <li>● Many, highly tortuous glands with dilated lumen (step ladder appearance)</li> <li>● Synthesis and storage of glycogen in the basal part of glandular epithelium (basal vacuolation)</li> <li>● Lumen is filled with secretion rich in glycogen and glycoprotein.</li> </ul>
<i>Stroma</i>	Highly cellular and nonoedematous	Highly vascular and oedematous
<i>Stromal granulocytes</i>	Less	More
<i>Mitotic figures</i>	More	Less
<i>Spiral arteries</i>	Do not reach the superficial part of endometrium and are less coiled	Reach the superficial part of endometrium and are more coiled and prominent

## 2. Proliferative phase (follicular phase): 5–14 days

- Proliferative phase coincides with the secretion of oestrogen from the maturing follicles in the ovary.
- It is characterised by rapid proliferation of cells of the stratum basalis (stromal cells and remnants of glandular cells) and restoration of lost endometrial surface that was denuded during menstruation.

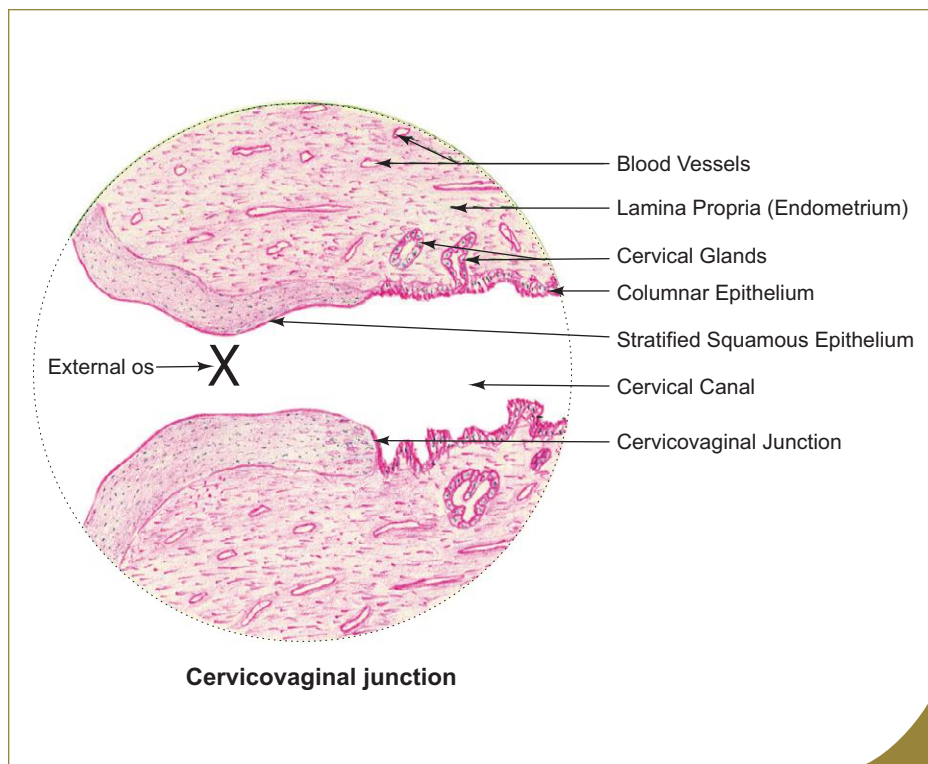
## 3. Secretory phase (luteal phase): 15–28 days

- Secretory phase coincides with the secretion of progesterone from the corpus luteum.
- It is characterised by increased secretory activity of the uterine glands. The endometrium becomes succulent and oedematous, preparing ground for the reception of blastocyst for implantation.

The endometrium of secretory phase differs structurally from the endometrium of the proliferative phase (Table 15.1).

## CERVIX OF UTERUS

- The cervix is the lower narrow part of uterus which projects partly into the vagina through its anterior wall. This intra-vaginal part of the cervix is surrounded by vaginal fornix and is covered by stratified squamous epithelium. The cavity of the cervix is called *cervical canal* which communicates with the uterine cavity through internal os and with the vagina through external os. At the external os, the simple columnar epithelial lining of the cervical canal changes into stratified squamous epithelium (Box 15.5).
- The endometrium of cervix differs from the endometrium of body and fundus in following ways:
  - It does not undergo changes during menstrual cycle, and therefore, is not shed during menstruation.
  - It contains large branched cervical glands which show altered secretory activity during different phases of the cycle. The secretion is thin and watery during proliferative phase whereas thick and viscous during secretory phase. This altered secretion is functionally important for the passage of sperms through the genital tract.
  - There are no spiral arteries.



### Box 15.5 Cervicovaginal Junction: Cervix.

Presence of

- (i) change of simple columnar epithelium lining in the cervical canal into stratified squamous epithelium lining in the vaginal portion of the cervix (*portio vaginalis*) at the external os;
- (ii) branched tubular cervical glands in the lamina propria (endometrium).

**Fibroid uterus** (uterine leiomyoma) is a very common benign tumour in which there are circumscribed nodules composed of whorls of smooth muscle within the myometrium. The nodule is surrounded by a pseudocapsule of compressed smooth muscle separating it from the normal myometrium.

**Cancer of cervix** (cervical carcinoma) arise from stratified squamous epithelium that lines the intravaginal part of cervix. Although cervical cancer is frequently observed, the mortality rate is low because of possible early detection and treatment. Cytological examination of cells collected from cervical epithelium (**Papanicolaou test**) provides information about cervical cancer.

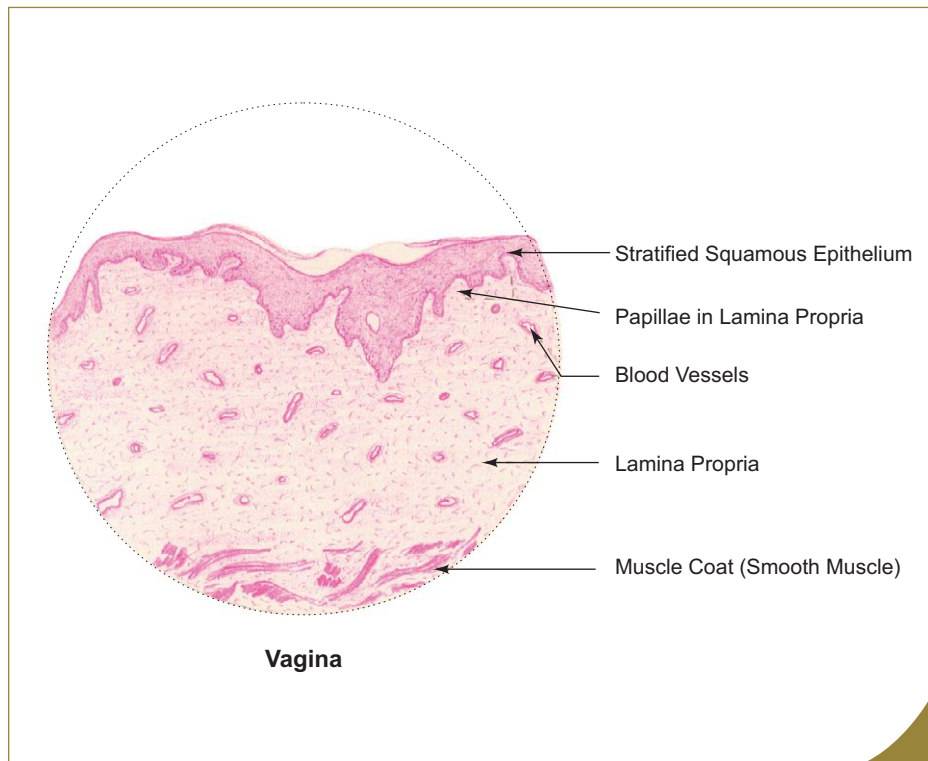
## VAGINA

### GENERAL FEATURES

- Vagina is a fibromuscular elastic tube that permits great distension during parturition.
- Its anterior and posterior walls are in contact with each other measuring 7.5 cm and 9 cm respectively.
- The upper end of vagina surrounds the vaginal portion of the cervix of uterus forming a circular groove or recess called *fornix*.

### STRUCTURE

- The wall of vagina is composed of the following three coats (Box 15.6):
  1. **Mucosa**
    - Mucosa is the innermost layer and it shows numerous transverse folds that extend from the longitudinal ridges on the anterior and posterior walls.



#### Box 15.6 Vagina.

Presence of

- thick stratified squamous epithelium** (may be partly keratinized);
- lamina propria rich in elastic fibres and blood vessels;
- no glands.**

- It is composed of the epithelial lining (*stratified squamous epithelium*) and the underlying lamina propria.
  - The epithelium is very thick (150–200 µm) and may show partial keratinization. It is often invaded by lymphocytes and neutrophils from the underlying lamina propria. Under the influence of oestrogen the vaginal epithelium synthesises and accumulates large quantity of glycogen. During menstrual cycle the epithelium undergoes cyclic changes; its glycogen content also varies. Bacteria in the vagina (*Dooderlein's bacillus/lactobacillus acidophilus*) anaerobically metabolize glycogen to form lactic acid, which lowers the pH of the vaginal fluid. This acidic environment inside vagina inhibits the growth of some pathogenic microorganisms.
  - The *lamina propria* is made of loose connective tissue rich in elastic fibres and vascular plexus and is devoid of glands.
  - The lubricative fluid found in the vagina comes from the glands of uterine cervix and as a fluid transudate from the rich vascular plexus of lamina propria.
2. **Muscle layer**
    - The smooth muscle fibres of muscular layer are arranged in ill-defined thin inner circular and thick outer longitudinal layers.
  3. **Adventitia**
    - It is made of dense connective tissue rich in thick elastic fibres. It contains blood vessels, lymphatics and nerve fibres.

## MAMMARY GLAND (BREAST)

### GENERAL FEATURES

- Mammary glands are modified apocrine sweat glands present only in mammals to produce milk for nourishing the newborn.
- They are rudimentary in males. Only in women they become functional and undergo development at puberty under the influence of hormones. They reach their highest developmental and functional activity during pregnancy and lactation. They undergo progressive atrophy and involution after menopause.

### GROSS STRUCTURE

- Each mammary gland consists of 15–20 independent units called *breast lobes*. The lobes are separated by interlobular septae, composed of dense connective and adipose tissues. Each lobe is formed by a compound tubuloalveolar gland whose duct, the *lactiferous duct*, opens on the surface of the nipple. Thus, there are about 15–20 lactiferous ducts opening on the nipple. Each duct presents a dilatation beneath the areola called *lactiferous sinus*.
- The *areola* is the dark pigmented skin around the nipple. The colour of the areola darkens during pregnancy and becomes lighter after delivery, but never returns to its original shade. The dermis of the areola contains circularly arranged smooth muscle fibres and in the nipple they are disposed longitudinally. Stimulation of these causes erection of nipple. Many large sebaceous glands are present at the periphery of areola and are responsible for the formation of surface elevations called *tubercles of Montgomery*.
- Within each lobe the lactiferous duct divides to form a number of terminal ducts, each of which leads to a lobule consisting of many alveoli. The alveoli are embedded in loose cellular connective tissue (intralobular connective tissue).
- The intralobular loose connective tissue supporting the alveoli contains many lymphocytes and plasma cells. These plasma cells are responsible for the secretion of *immunoglobulin (IgA)* into the *colostrum* towards the end of pregnancy and it gives passive immunity to the newborn.
- The lobules are separated by moderately dense collagenous interlobular connective tissue septae.

### HISTOLOGICAL STRUCTURE

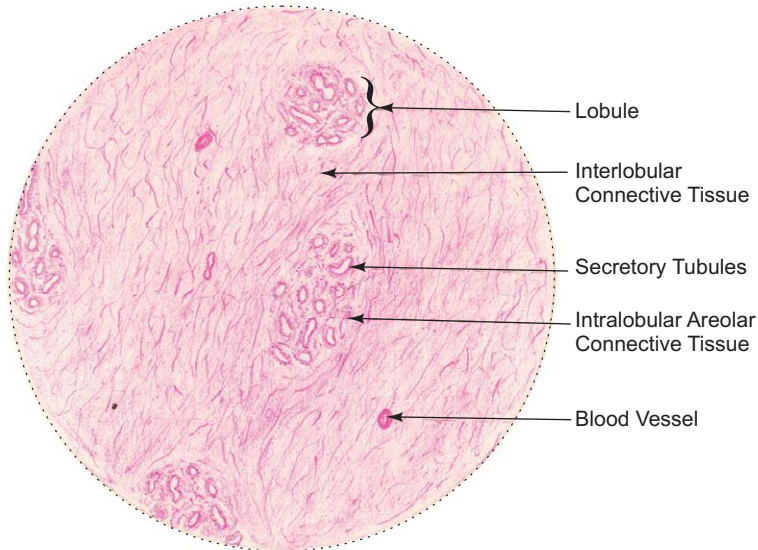
- The histological structure of mammary glands varies according to the physiological status of the woman. The differences between the nonlactating and lactating mammary glands (Boxes 15.7 and 15.8) are presented in Table 15.2.



**Box 15.7 Nonlactating Mammary Gland.**

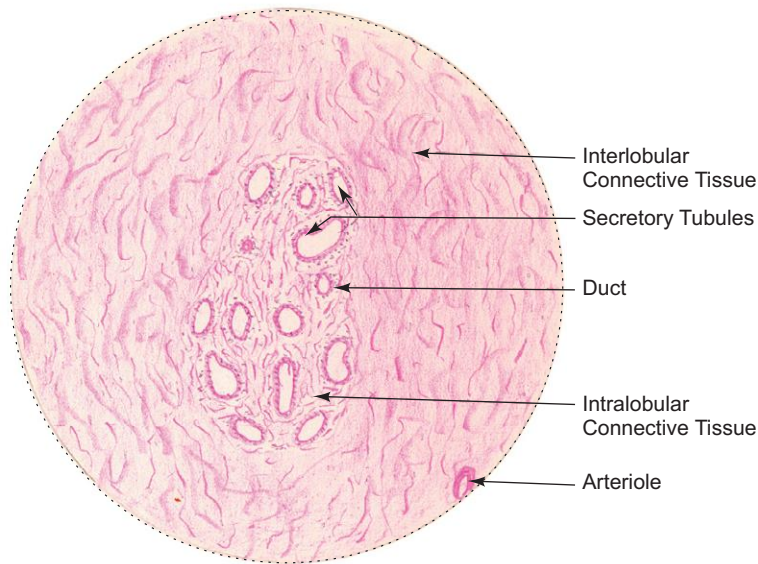
*Presence of*

- (i) more connective tissue and less of glandular tissue;
- (ii) underdeveloped alveoli represented by cords of cells;
- (iii) extensive branching of duct system.



*L/P*

**Nonlactating mammary gland**



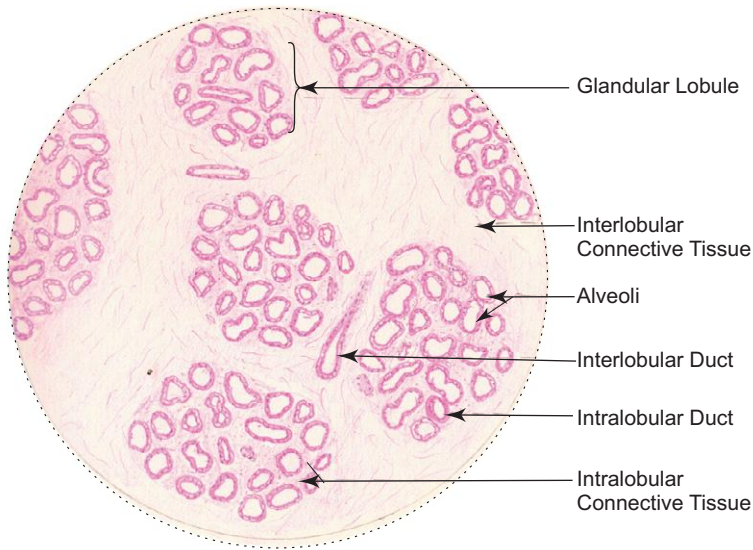
*H/P*

**Nonlactating mammary gland**

**Box 15.8** Lactating Mammary Gland.

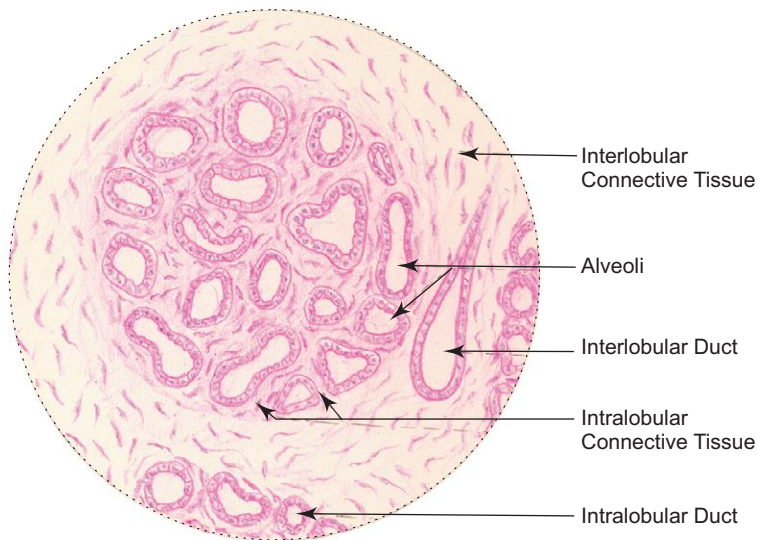
Presence of

- (i) less connective tissue and more glandular tissue;
- (ii) compactly packed, well developed **alveoli with distended lumen** containing **milk**;
- (iii) **simple cuboidal epithelium** lining the alveoli.



L/P

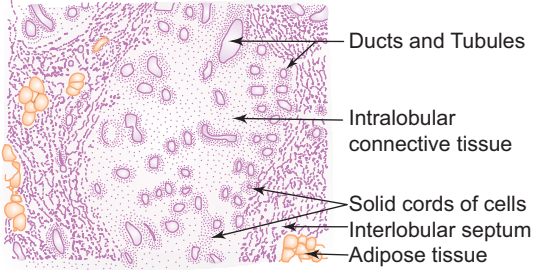
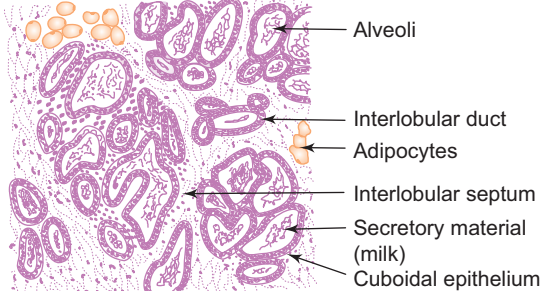
Lactating mammary gland



H/P

Lactating mammary gland

**Table 15.2** Differentiating features of nonlactating and lactating mammary glands

Nonlactating mammary gland	Lactating mammary gland
 <p>Ducts and Tubules Intralobular connective tissue Solid cords of cells Interlobular septum Adipose tissue</p>	 <p>Alveoli Interlobular duct Adipocytes Interlobular septum Secretory material (milk) Cuboidal epithelium</p>
<p><b>Parenchyma</b></p> <ul style="list-style-type: none"> <li>• Less glandular tissue (parenchyma)</li> <li>• Alveoli are not developed – represented by solid cords of epithelial cells</li> <li>• Extensive branching of duct system form the lobule</li> <li>• The intralobular ducts are lined by two layers of cells: luminal layer of cuboidal epithelial cells and basal layer of myoepithelial cells</li> <li>• Duct lumen is not clearly visible and contains no secretion</li> </ul>	<p><b>Parenchyma</b></p> <ul style="list-style-type: none"> <li>• More glandular tissue</li> <li>• Alveoli are well developed and are large and branched, lined by cuboidal epithelium and associated myoepithelial cells</li> <li>• Extensively branching alveoli form the lobule. Ducts are few</li> <li>• The intralobular ducts are lined by cuboidal epithelium, whereas the lactiferous ducts are lined by stratified columnar or cuboidal epithelium</li> <li>• Lumina of alveoli and ducts are filled with eosinophilic secretory material (milk) and appear vacuolated due to the presence of fat droplets</li> </ul>
<p><b>Stroma</b></p> <ul style="list-style-type: none"> <li>• More connective tissue and adipose tissue</li> <li>• Interlobular connective tissue septum is thick and is composed of dense collagen fibres and adipose tissue</li> <li>• Abundant intralobular loose connective tissue containing many fibroblasts</li> </ul>	<p><b>Stroma</b></p> <ul style="list-style-type: none"> <li>• Less connective tissue and adipose tissue</li> <li>• Interlobular connective tissue septum is thin</li> <li>• Scanty intralobular connective tissue, often infiltrated with lymphocytes and plasma cells</li> </ul>

During breast-feeding, the sucking effect of the child stimulates the sensory receptors in the nipple causing liberation of oxytocin from posterior pituitary. This hormone causes contraction of myoepithelial cells in the alveoli and ducts resulting in ejection of milk (**milk ejection reflex**).

**Breast cancer** is one of the most common malignant tumours in women. It is due to malignant proliferation of epithelial cells lining the lactiferous ducts. Early detection of breast cancer by self-examination for any lump reduces the mortality rate.

## PLACENTA

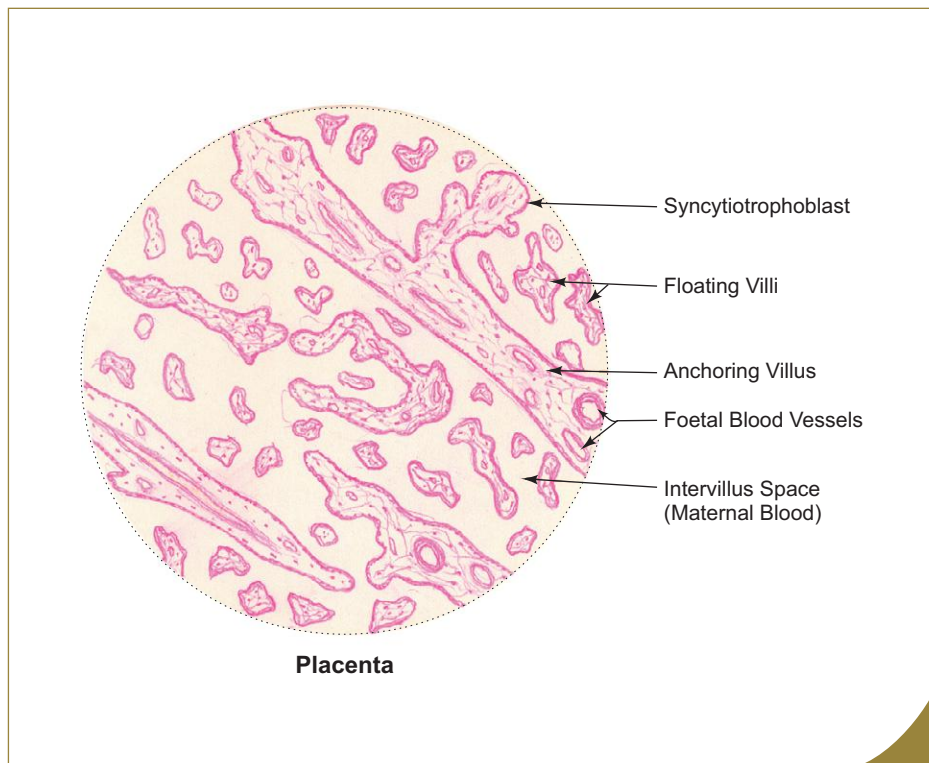
### GENERAL FEATURES

- Placenta is a specialised extraembryonic tissue in which blood vessels of the foetus are brought into close intimacy with the maternal blood for the purpose of nutrition, respiration, excretion and other metabolic activities during intrauterine life of the foetus.

- Placenta at term is discoidal in shape.
- It weighs about 500 gm and measures 15–20 cm in diameter and 3 cm in thickness.
- It is derived from both foetal (chorion) and maternal (decidua basalis) components.
- Its foetal surface is smooth and shiny covered with amnion; whereas, the maternal surface is rough covered with a layer of decidua basalis (decidual plate), which sends incomplete septae towards the chorionic plate in the foetal surface dividing the placenta into 15–20 cotyledons (for more detail refer to a textbook of Embryology).

### STRUCTURE (BOX 15.9)

- A section of placenta shows many villi cut at different planes.
- Villi are separated by intervillous space containing maternal blood that comes to the space through spiral arteries of decidua.
- Exchange of gases and metabolites takes place between the maternal blood in the intervillous space and foetal blood present in capillaries in villi across the placental barrier.
- Each villus has (Box 15.9)
  - a central core of connective tissue containing foetal blood vessels (branches of umbilical vessels),
  - a covering of inner layer of cytotrophoblast (cuboidal epithelium) during the first half of pregnancy, which disappears during the second half of pregnancy, and
  - an outer layer of syncytiotrophoblast (a multinucleated syncytium with indistinct cell margins). The syncytiotrophoblast produces progesterone, oestrogen, HCG and other placental hormones.



#### Box 15.9 Placenta.

*Presence of*

- (i) **villi** cut in various planes;
- (ii) **intervillous space** containing maternal blood;
- (iii) **syncytiotrophoblast** and **syncytial knots**.

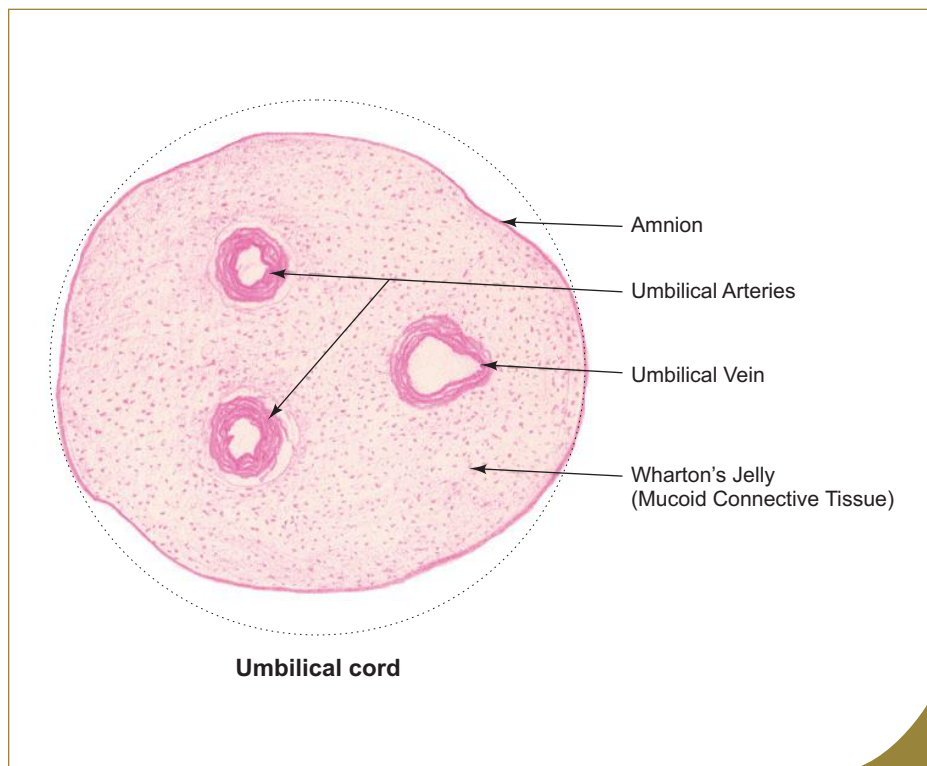
## UMBILICAL CORD

### GENERAL FEATURES

- Umbilical cord connects the foetus with placenta.
- It measures about 50 cm in length and 1–2 cm in width.
- It is derived from connecting stalk of the embryo.

### STRUCTURE

- A cross section of umbilical cord at term shows the following features (Box 15.10):
  - A single umbilical vein (thin wall with wide lumen) bringing oxygenated blood from placenta to the foetus.
  - Two umbilical arteries (thick wall with narrow lumen) carrying deoxygenated blood from the foetus to placenta.
  - A mass of gelatinous mucoïd connective tissue (Wharton's jelly) in which the umbilical vessels are embedded.
  - A tube of amnion (simple cuboidal epithelium) ensheathing all the above structures.



#### Box 15.10 Umbilical Cord.

*Presence of*

- (i) **two arteries and one vein;**
- (ii) **Wharton's jelly** (mucoïd connective tissue);
- (iii) amniotic epithelium (simple cuboidal epithelium).

# Self-assessment Exercise

## I. Write Short notes on:

- (a) Structure of ovary
- (b) Ovarian follicles
- (c) Graafian follicle
- (d) Corpus luteum
- (e) Uterine tube
- (f) Structure of uterus
- (g) Structure of vagina
- (h) Differentiating features of proliferative and secretory phases of uterus
- (i) Differentiating features of lactating and nonlactating mammary glands

## II. Fill in the blanks:

1. Nonciliated secretory cells present in the lining epithelium of uterine tube are called \_\_\_\_\_
2. The endometrial layer that is shed during each menstrual cycle is called \_\_\_\_\_
3. Granulosa cells that are adherent to the zona pellucida form \_\_\_\_\_
4. Mucosa of the uterus is commonly called \_\_\_\_\_
5. Fornix of vagina is lined by \_\_\_\_\_
6. Cervical cancer can be detected by a special cytological test called \_\_\_\_\_ test.
7. The superficial cells of the stratified squamous epithelium of vagina synthesise and store \_\_\_\_\_
8. Corpus luteum is derived from \_\_\_\_\_ and \_\_\_\_\_ of the ovarian follicle.
9. Ovulation occurs usually on the \_\_\_\_\_ day of a 28-day menstrual cycle.
10. Mammary gland is a modified \_\_\_\_\_ gland.

## III. Choose the best answer:

1. Primordial follicle is identified in section by the presence of
  - (a) zona pellucida
  - (b) single layer of flattened follicular cells
  - (c) theca folliculi
  - (d) antrum folliculi
2. The life span of corpus luteum of pregnancy is
  - (a) 10–12 days
  - (b) 4–5 weeks
  - (c) 4–5 months
  - (d) 10 lunar months
3. Fertilization takes place at
  - (a) ampulla of uterine tube
  - (b) uterine cavity
  - (c) vagina
  - (d) cervical canal

4. Uterine tube is lined by the following epithelium
  - (a) simple columnar
  - (b) simple cuboidal
  - (c) pseudostratified ciliated columnar
  - (d) simple columnar ciliated
5. Primary oocyte completes its first meiotic division at the time of
  - (a) ovulation
  - (b) fertilization
  - (c) puberty
  - (d) none of the above
6. Secretory phase of endometrium is characterised by the presence of
  - (a) oedematous endometrium
  - (b) tortuous uterine glands
  - (c) secretion rich in glycogen
  - (d) all of the above
7. The secretion found in the vagina comes from glands present in
  - (a) vaginal wall only
  - (b) fornix of vagina only
  - (c) cervix of uterus only
  - (d) both vagina and cervix
8. Lactating mammary gland presents all of the following features **except** that
  - (a) alveoli are large and branched
  - (b) alveoli contain secretory material
  - (c) connective tissue septae are thick and well developed
  - (d) intralobular ducts are few
9. Granulosa lutein cells of corpus luteum secrete
  - (a) luteinizing hormone
  - (b) oestrogen
  - (c) progesterone
  - (d) chorionic gonadotropin
10. Theca lutein cells of corpus luteum are
  - (a) small dark cells
  - (b) large pale staining cells
  - (c) the predominant cell type
  - (d) derived from membrana granulosa

**IV. State whether the following statements are true (T) or false (F):**

1. Germinal epithelium covering the ovary gives rise to ova ( )
2. Glassy membrane is the last structure to disappear in an atretic follicle ( )
3. Zona pellucida is derived from oocyte only ( )
4. The cells of theca interna secrete progesterone ( )
5. During pregnancy the myometrium undergoes hypertrophy ( )
6. Straight arteries supply the superficial layer of the endometrium ( )
7. Coiled arteries are under the influence of ovarian hormones ( )
8. Proliferative phase of uterus coincides with the development of ovarian follicles ( )
9. The alkaline environment of vagina prevents growth of microorganisms ( )
10. Colostrum gives passive immunity to the newborn ( )

**Answers**

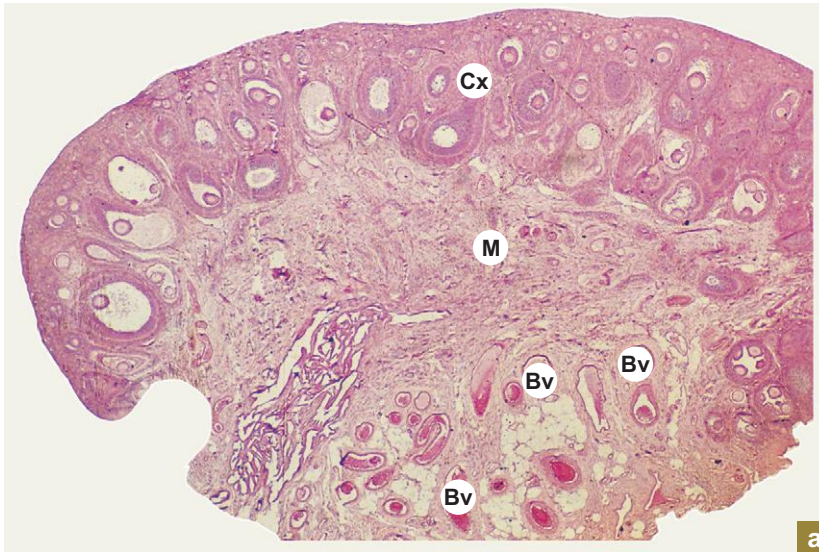
- II.** 1. Peg cells      2. Stratum functionalis      3. Corona radiata      4. Endometrium  
5. Stratified squamous epithelium      6. Papanicolaou's      7. Glycogen  
8. Theca interna and membrana granulosa      9. 14th      10. Apocrine sweat gland
- III.** 1. b      2. c      3. a      4. d      5. a      6. d      7. c      8. c      9. c      10. a
- IV.** 1. (F)      2. (T)      3. (F)      4. (F)      5. (T)      6. (F)      7. (T)      8. (T)      9. (F)      10. (T)



# Practical No. 15.I

## Female Reproductive System

X10



a

**Plate 15.I:1**  
a and b

**Ovary.**  
a. Panoramic view.  
b. Cortex.

Examine a section of ovary under scanner (Plate 15.I:a) and note the following features:

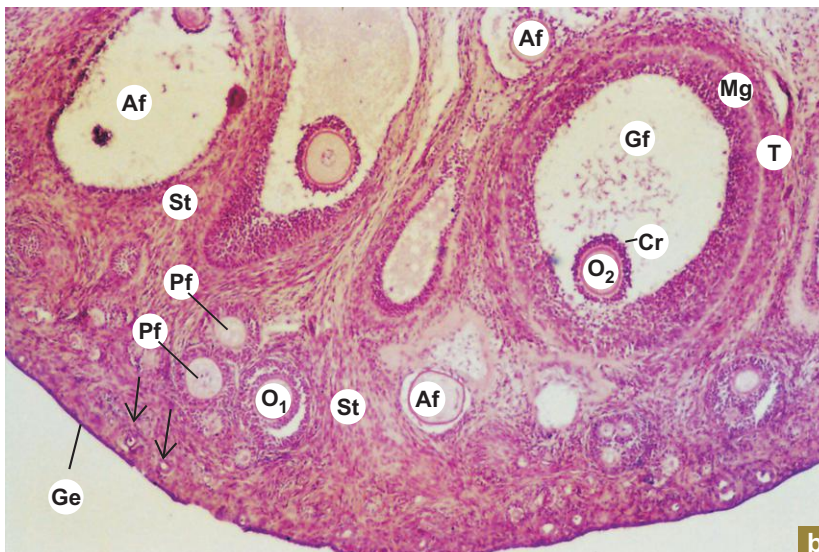
- Peripheral cortex (Cx) showing ovarian follicles at different stages of maturation.
- Central medulla (M) containing blood vessels (Bv).

Examine the cortex at low magnification (Plate 15.I:1b) and identify the different types of ovarian follicles embedded in the cellular stroma (St):

- *Primordial follicle* (arrows) containing primary oocyte surrounded by squamous follicular cells.
- *Primary follicle* (Pf) containing primary oocyte ( $O_1$ ) surrounded by cuboidal follicular cells.
- *Graafian follicle* (Gf) containing secondary oocyte ( $O_2$ ) surrounded by cornea radiata (Cr). The cavity of the follicle is lined by membrana granulosa (Mg). Externally the follicle is covered by theca folliculi (T).
- *Atretic follicle* (Af).

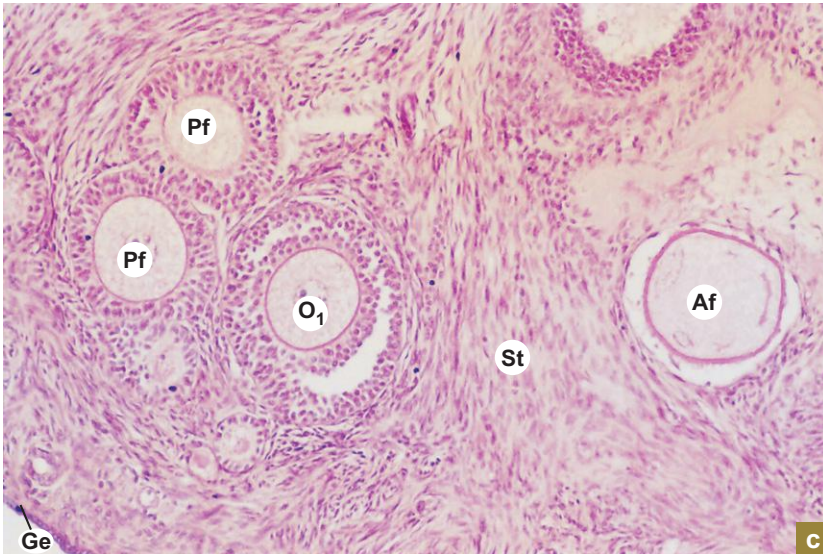Note the germinal epithelium (Ge) lining the surface of the ovary.

X40



b

X100



**Plate 15.I:1**  
c and d

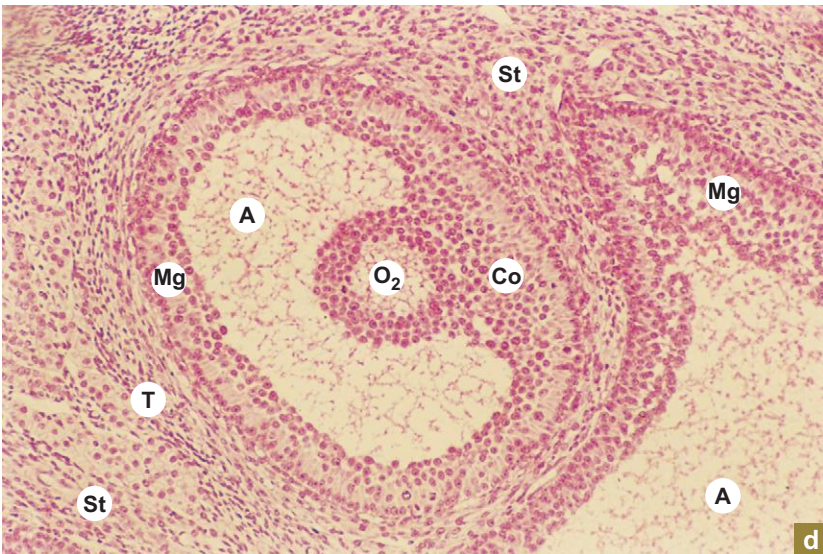
**Ovary.**  
c. Primary follicles.  
d. Graafian follicles.

Plate 15.I:1c illustrates a group of primary follicles (Pf) containing primary oocyte (O<sub>1</sub>) and an atretic follicle (Af) containing the wrinkled zona pellucida in the antrum.

Examine a Graafian follicle at low/high magnification (Plate 15.I:d) and note the following features:

- Theca folliculi (T) surrounding the follicle.
- Membrana granulosa (Mg) lining the antrum folliculi (A).
- Eccentrically placed secondary oocyte (O<sub>2</sub>) surrounded by cumulus oophorus (Co).

X100



X200

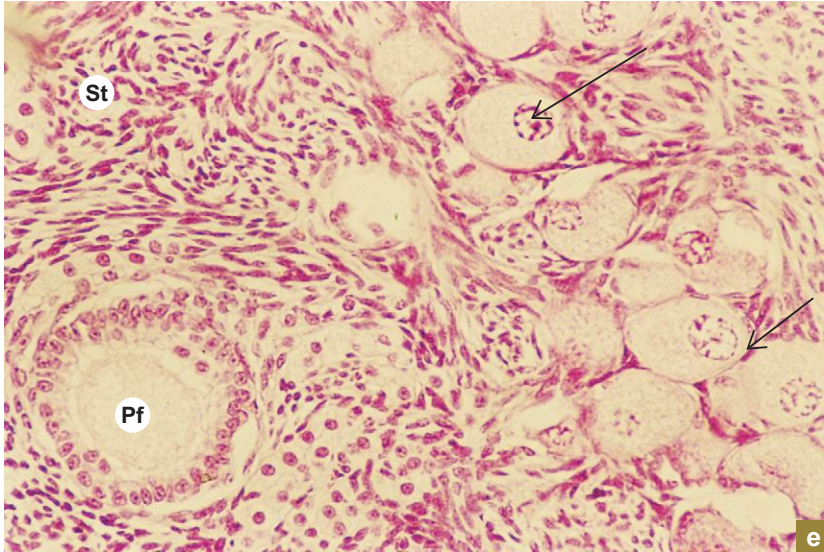


Plate 15.I:1  
e and f

Ovary.  
e. Primordial follicles.  
f. Corpus luteum.

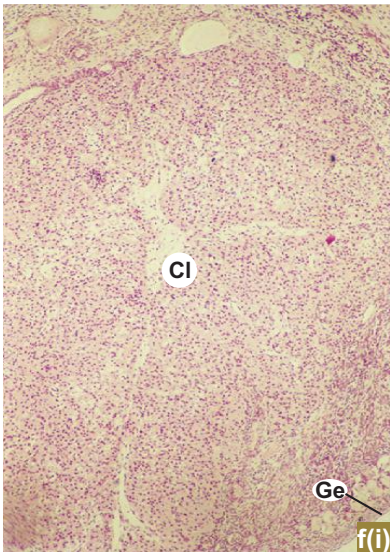
Plate 15.I:1e illustrates a group of primordial follicle (arrows) and a primary follicle (Pf) embedded in stroma (St).

Examine a section of corpus luteum (Cl) at low magnifications (Plate 15.I:1f) and identify the cell types.

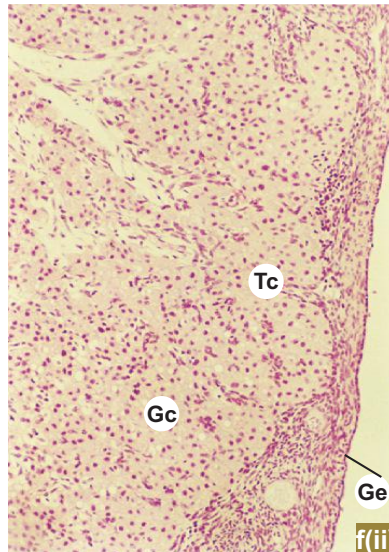
- Granulosa lutein cells (Gc) are large pale staining cells with vesicular nuclei found at the deeper part of the corpus luteum
- Theca lutein cells (Tc) are smaller, less numerous and darker than the granulosa lutein cells. They are found at the periphery and along the connective tissue strands that invade the structure.

Ge = germinal epithelium of ovary.

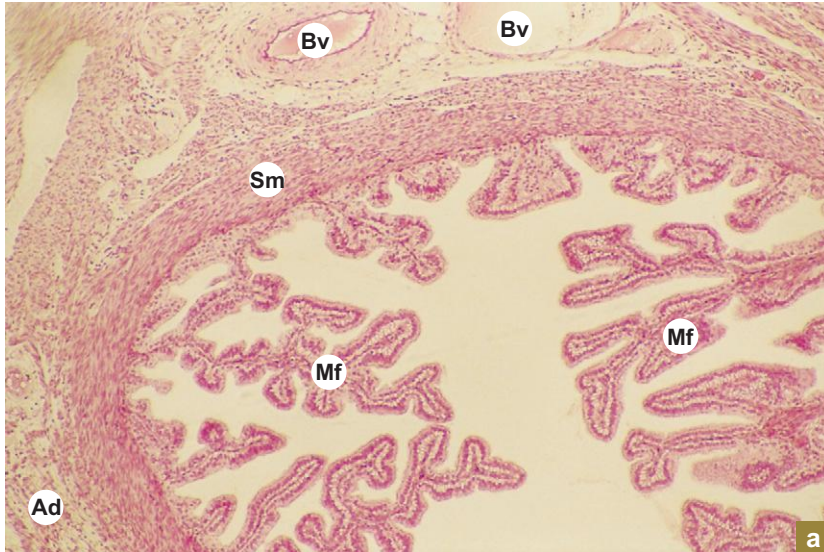
X40



X100



X40


**Plate 15.I:2 Fallopian tube.  
a and b**

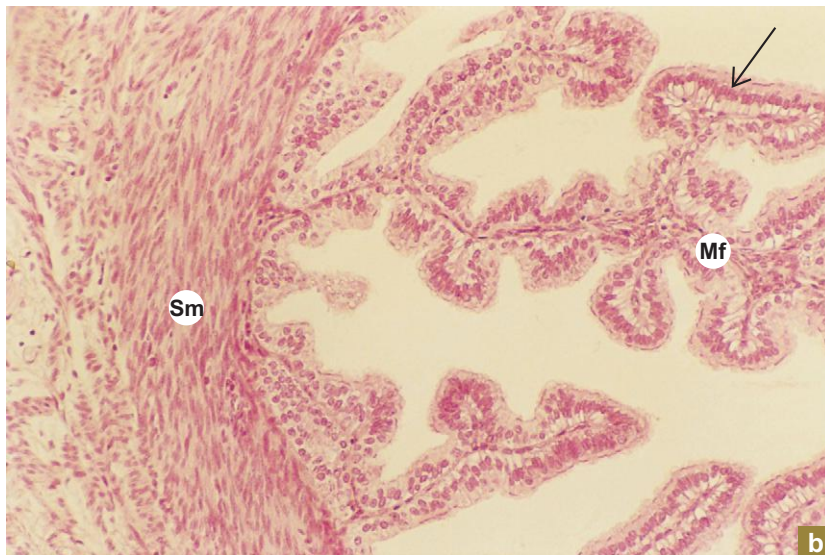
Examine a section of Fallopian tube under low power (Plate 15.I:2a) and note the following features:

- Highly branched mucosal folds (**Mf**) occupying the lumen of Fallopian tube.
- Smooth muscle fibres (**Sm**) arranged in two layers, inner circular and outer longitudinal.
- Serosa/adventitia (**Ad**) carrying blood vessels (**Bv**).

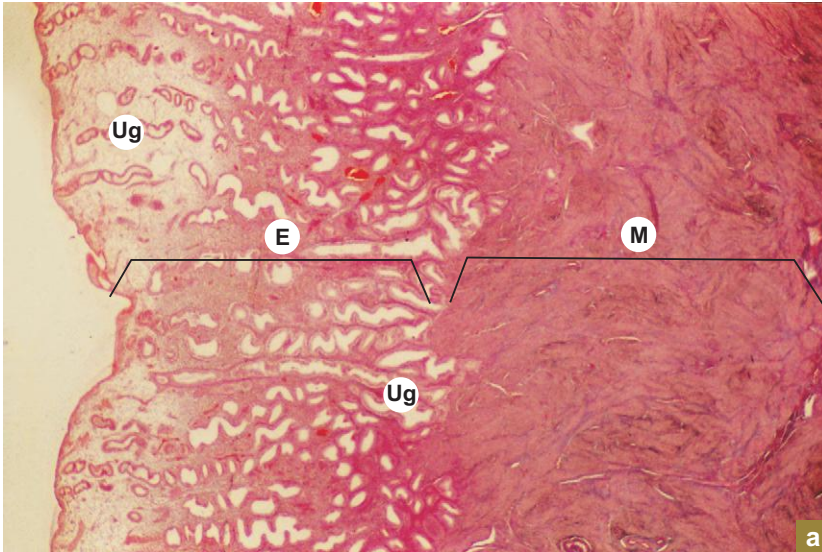
At higher magnification (Plate 15.I:2b) observe a mucosal fold (**Mf**).

- It is lined by *simple ciliated columnar epithelium* (**arrow**).
  - Nonciliated peg (secretory) cells can be seen among the ciliated columnar cells with still higher magnification.
- Sm** = smooth muscle.

X100



X10

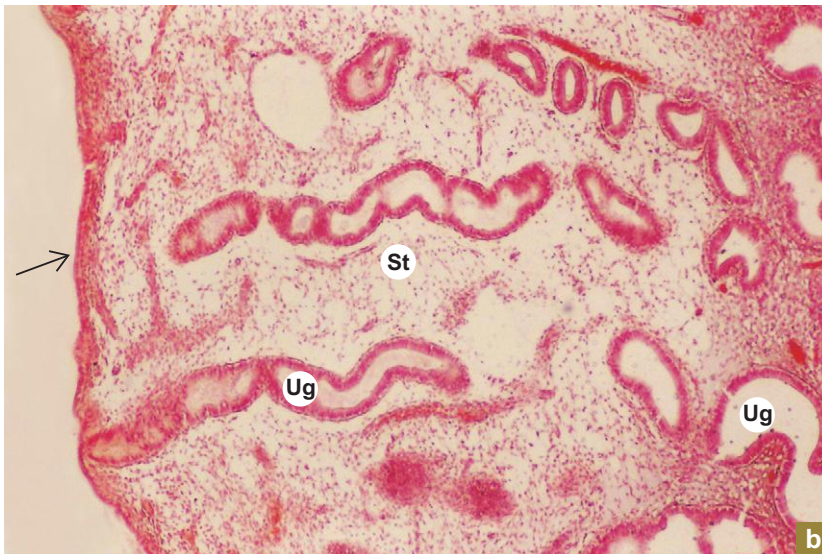


**Plate 15.I:3**  
a and b

**Uterus.**  
a. Panoramic view.  
b. Endometrium  
secretory phase.

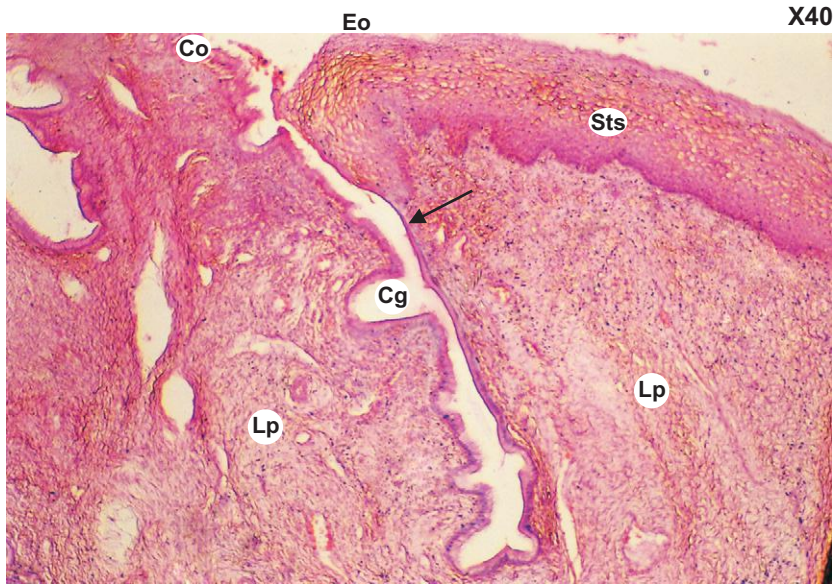
Panoramic view of the uterus (Plate 15.I:3a) shows the entire thickness of the *endometrium* (E) and part of *myometrium* (M). Note the dilated *uterine glands* (Ug) in the endometrium.

X40



Examine the endometrium at a still higher magnification (Plate 15.I:3b) and appreciate—

The highly cellular and oedematous stroma (St) and dilated uterine glands (Ug) which are the salient features of uterus in secretory phase. The uterine cavity is lined by simple columnar epithelium (arrow).

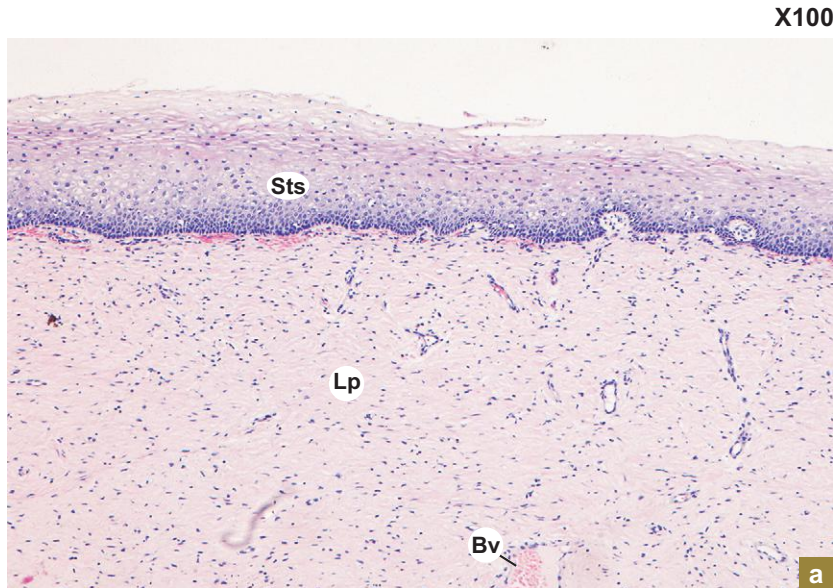


X40

**Plate 15.I:4** Cervix of uterus (vaginal part).

Examine a longitudinal section of cervix cut through its cavity and note the following features (Plate 15.I:4):

- Simple columnar epithelium (Co) lining of the cervical canal.
- Branched tubular cervical glands (Cg) in the lamina propria (Lp) (endometrium).
- Abrupt change of epithelium (arrow) from simple columnar to stratified squamous (Sts) at the external os (Eo) and extending over the vaginal surface of the cervix.

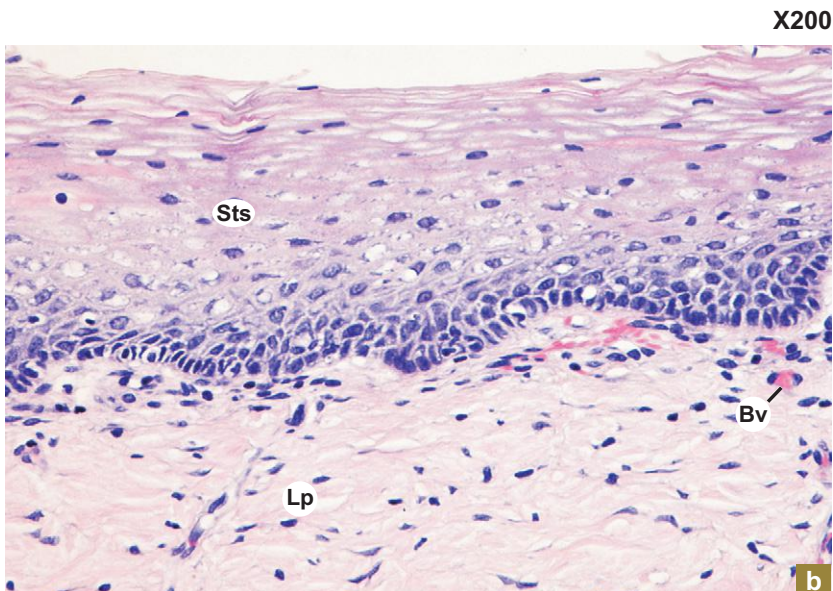


X100

**Plate 15.I:5** Vagina. a and b

A section of vagina shows the following features (Plate 15.I:5a and b):

- Stratified squamous epithelium (Sts) which is very thick (150–200 μm) and often shows partial keratinization. It is involved in synthesis and storage of glycogen. (This gives the cells a vacuolated appearance in histological section.)
- Lamina propria (Lp) is rich in elastic fibres and blood vessels (Bv).



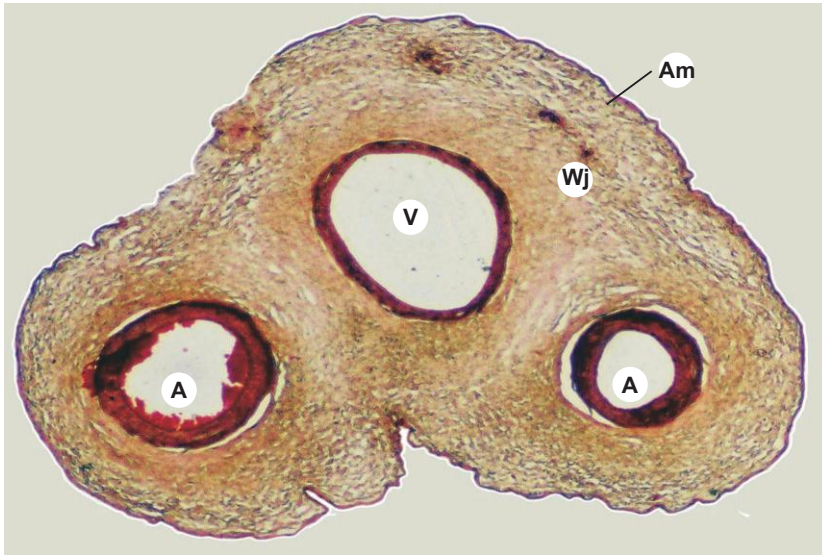
X200

b

# Practical No. 15.II

## Female Reproductive System

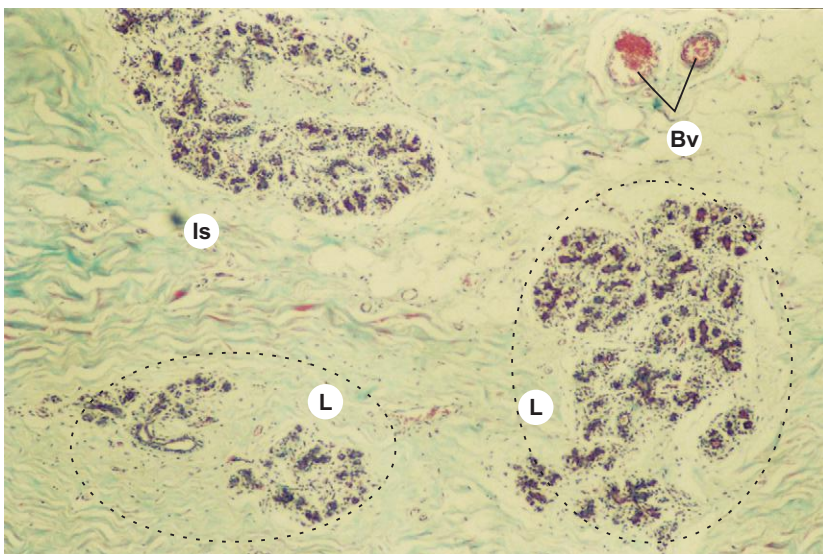
X10



**Plate 15.II:1 Umbilical cord.**

Umbilical cord is identified by the presence of two umbilical arteries (A) which carry deoxygenated blood from the foetus to the placenta and a single umbilical vein (V) that conveys oxygenated blood to the foetus. All the three umbilical vessels are embedded in mucoid connective tissue (mesenchyme) called Wharton's jelly (Wj). The umbilical cord is surrounded by amnion (Am) and is made of simple cuboidal epithelium.

X100



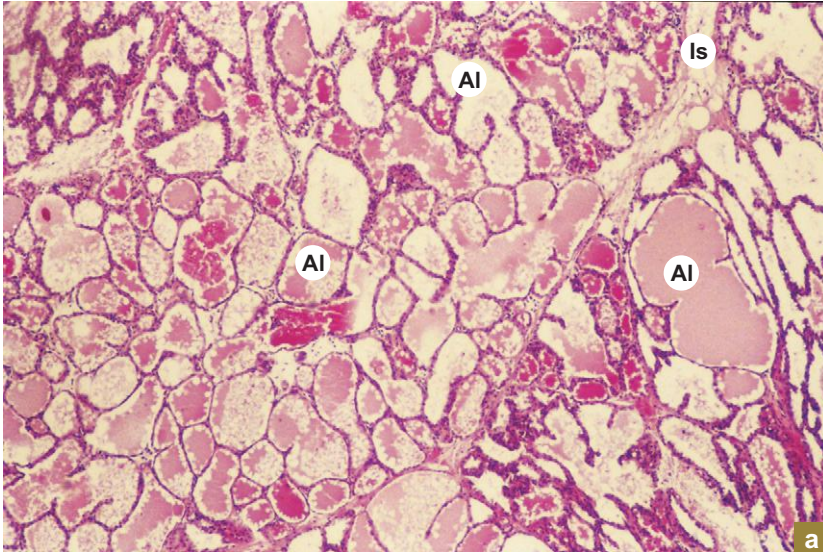
**Plate 15.II:2 Nonlactating mammary gland.**

Examine a section of nonlactating mammary gland under low power (Plate 15.II:2).

Nonlactating mammary gland contains more connective tissue and less glandular tissue (parenchyma). The lobules (L) are separated by thick interlobular connective tissue septum (Is). The lobules are formed by extensive branching of the duct system and solid cord of cells representing underdeveloped alveoli.

Bv = blood vessel.

X40



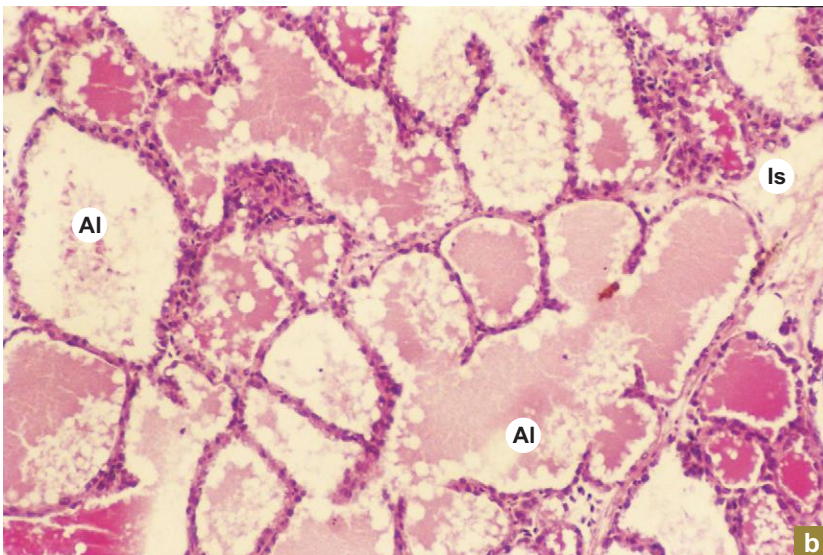
a

**Plate 15.II:3** Lactating mammary gland.  
**a and b**

Examine a section of the lactating mammary glands (Plate 15.II:3a and b). It shows the following features:

- Less connective tissue (stroma) and more glandular tissue (parenchyma).
- The interlobular connective tissue septum (Is) is very thin and separates the lobules which are well developed. The lobules are formed by compactly packed alveoli (AI). The alveoli are lined by simple cuboidal secretory epithelium and associated myoepithelial cells. Their lumen contains eosinophilic secretory material (milk) which appear vacuolated due to the presence of fat droplets.

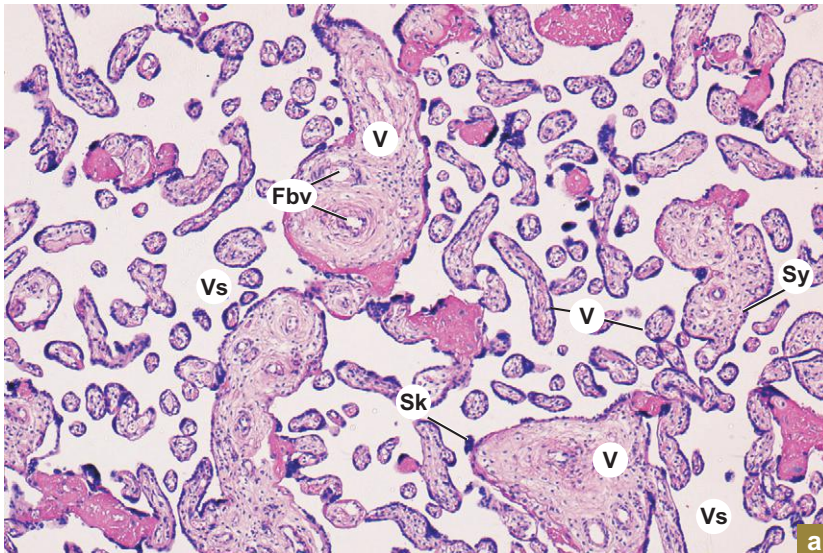
X100



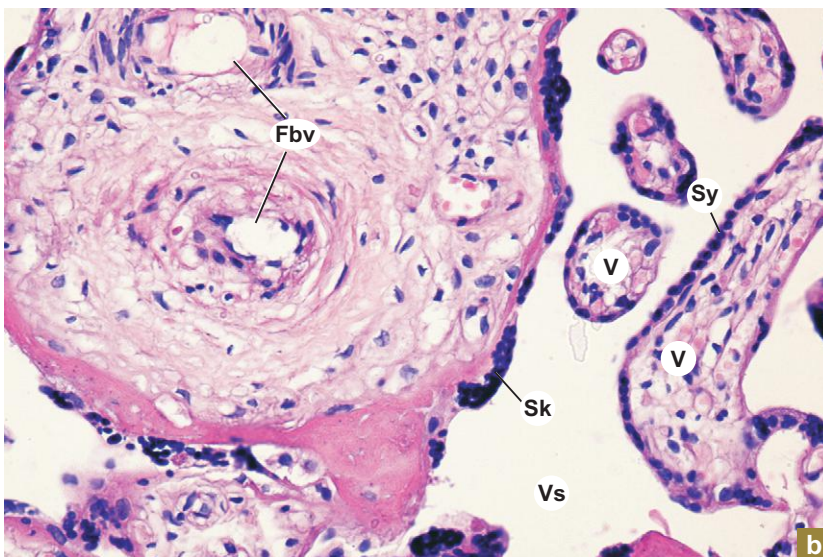
b



X100



X400



#### Plate 15.II:4 Placenta. a and b

Examine the placenta at low magnification (Plate 15.II:4a) and note the following features:

- The large number of villi (V) cut in various planes.
- The villi are separated by intervillous space (Vs) which appears empty.
- In some sections traces of maternal blood may be seen in the intervillous space.

Plate 15.II:4b illustrates placenta at high magnification. It shows the following features:

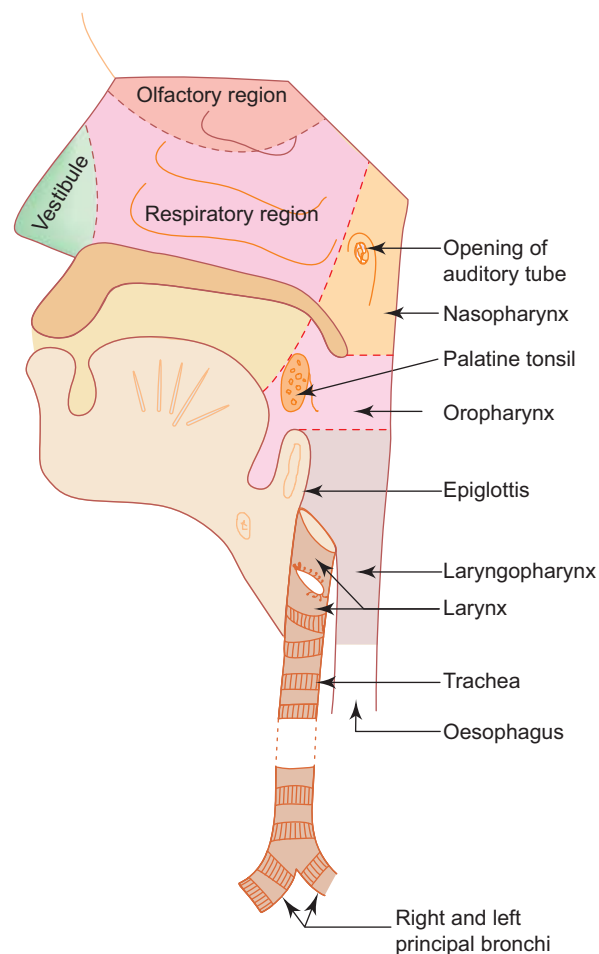
- Large stem villi and small terminal villi (V) reflecting the extensive branching nature of villi. The villi are separated by intervillous space (Vs).
- The villi are lined by syncytiotrophoblast (Sy) and at places the syncytiotrophoblast nuclei are aggregated to form syncytial knots (Sk).
- Foetal blood vessels (Fbv) are prominently seen in the central core of large stem villi. In the small villi the capillaries are located at the periphery very close to the trophoblast reducing the placental barrier which becomes very thin.

# 16

## RESPIRATORY SYSTEM

### INTRODUCTION

The respiratory system is functionally divided into two portions, namely, the *conducting portion* and the *respiratory portion*. The conducting portion includes the upper respiratory tract (nasal cavity, pharynx and larynx) and parts of lower respiratory tract (trachea, bronchi and bronchioles). The respiratory portion includes the terminal parts of lower respiratory tract, namely, respiratory bronchioles, alveolar ducts, alveolar sacs and alveoli (Fig. 16.1). The conducting portion provides passage of air as well as conditions the inspired air. The respiratory portion is involved in exchange of oxygen and carbon dioxide between blood and inspired air. Thus, it constitutes the functional unit of the respiratory system.



**Fig. 16.1** Sagittal section of head and neck (nasal cavity, pharynx, larynx and trachea).

## GENERAL STRUCTURE OF THE CONDUCTING PORTION OF THE RESPIRATORY TRACT

- In general, the respiratory tract is made of four coats (Fig. 16.2), namely,
  - Mucosa**
    - It includes the epithelial lining and the underlying lamina propria. The epithelium is usually pseudostratified ciliated columnar epithelium with goblet cells.
  - Submucosa**
    - It is a layer of loose connective tissue containing mixed glands.
  - Cartilage layer**
    - This layer is mostly formed by hyaline cartilage plus smooth muscle.
  - Adventitia**
    - It is a layer of fibroelastic connective tissue merging with the surrounding tissue.

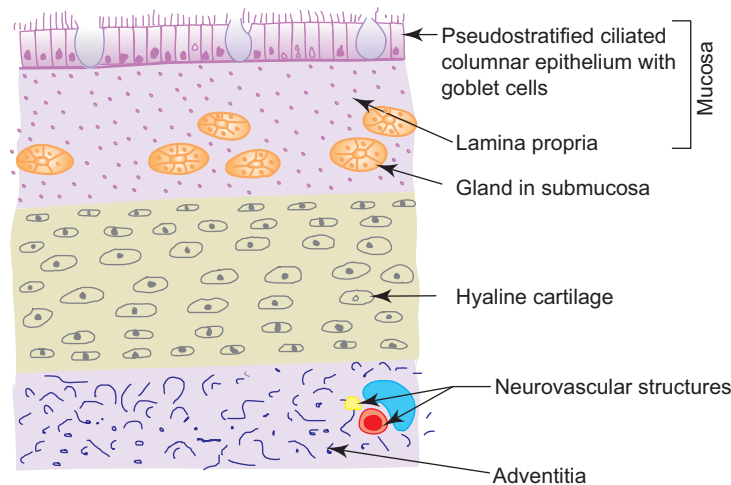


Fig. 16.2 General plan of respiratory tract.

## STRUCTURAL CHANGES IN THE CONDUCTING PORTION OF THE RESPIRATORY TRACT (FROM LARYNX TO BRONCHIOLE)

- The epithelium gradually decreases in thickness (from pseudostratified columnar ciliated to simple cuboidal ciliated).
- Goblet cells in the epithelium gradually reduce in number and completely disappear in the bronchiole.
- Similarly, glands in the submucosa gradually decrease and completely disappear distally (no glands in the bronchioles).
- Elastic fibres gradually increase in amount.
- The cartilage gradually reduces and disappear distally (no cartilage in the bronchioles).
- Smooth muscle fibres relatively increase.

## NASAL CAVITY

### GENERAL FEATURES

- The nasal cavity is the beginning of the respiratory system.
- It extends from the nostrils in front to the posterior nasal apertures behind.
- Its framework is formed by bones and cartilages covered by mucous membrane.
- It is divided into right and left halves by nasal septum.

## STRUCTURE

- Histologically, based on the lining epithelium, the nasal cavity is divisible into following three regions (Fig. 16.1):

### 1. Vestibule

- It is the anterior dilated part of the nasal cavity lined by skin.
- It contains thick short hairs called *vibrissae* which filter large particles from inspired air.

### 2. Olfactory region

- This region is confined to a smaller area and is found in the roof and the adjoining parts of nasal septum and lateral wall of nasal cavity. It is covered by a thick yellow olfactory mucosa functioning as the *organ of smell*.
- **Olfactory mucosa** is made of a thick olfactory epithelium and the underlying connective tissue, the lamina propria (Fig. 16.3).

The lamina propria contains serous glands (*Bowman's glands*), bundles of olfactory nerves (*fila olfactoria*), blood vessels and lymphatics. The secretion of Bowman's glands moistens the olfactory epithelium and serves as a solvent which dissolves odoriferous substances and thus stimulates the olfactory cells.

- The olfactory epithelium is made of the following three types of cells (Fig. 16.3):
  - (a) *Olfactory cells*—are the modified bipolar nerve cells. Each cell has a cell body, a dendrite and an axon. The cell bodies contain round nuclei and are found at different levels in the epithelium forming a broad *zone of round nuclei*. The dendritic processes extend to the surface and end in knob-like structures, the *olfactory vesicles* from which nonmotile *olfactory hair* arise. The axonal processes pass into the lamina propria and are collected into bundles of olfactory nerves (*fila olfactoria*).
  - (b) *Sustentacular cells*—are tall columnar cells that support the olfactory cells. They bear microvilli on their free surfaces. Each cell has a broad superficial part containing oval nucleus and a slender deep part attached to the basement membrane. The nuclei of the sustentacular cells lie near the free surface of the epithelium in the same level constituting a narrow *zone of oval nuclei*. The presence of yellow lipofuscin pigments in the cytoplasm suggests their phagocytic function as well.
  - (c) *Basal cells*—are conical in shape, do not reach the surface and give rise to other cell types.

### 3. Respiratory region

- It occupies the rest of the area of the nasal cavity. It is covered by *respiratory mucosa* which is pink in colour and less thick compared to olfactory mucosa. The respiratory mucosa is firmly adherent to the underlying periosteum or perichondrium.

**Respiratory mucosa** consists of respiratory epithelium (pseudostratified ciliated columnar epithelium with goblet cells) and the underlying lamina propria containing mixed glands, lymphatic nodules and rich vascular plexuses.

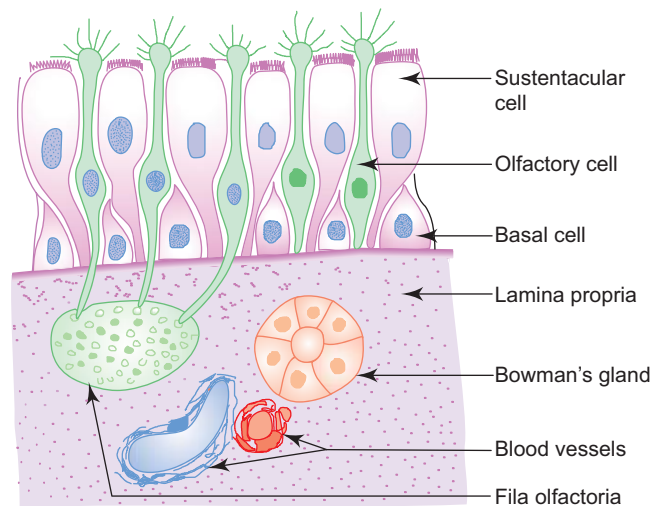


Fig. 16.3 Olfactory mucosa.

- The respiratory epithelium is made of five cell types (Fig. 16.4). These are:
  - (a) *Ciliated cells*—columnar cells with cilia on their free surfaces, the most abundant cell type, cilia beat towards the pharynx.
  - (b) *Goblet cells*—flask-shaped mucus secreting cells.
  - (c) *Brush cells*—columnar cells with microvilli on their free surfaces (may have sensory function).
  - (d) *Basal cells*—small pyramidal cells, do not reach the surface, give rise to other cell types.
  - (e) *Granule cells*—small round cells with many cytoplasmic granules (form part of the APUD cell series).

The main function of the respiratory mucosa is conditioning of air, i.e. the inspired air is

- cleaned by the sticky mucus of dust particles,
- warmed by the vascular plexus in the lamina propria, and
- moistened by the secretory fluid provided by the glands.

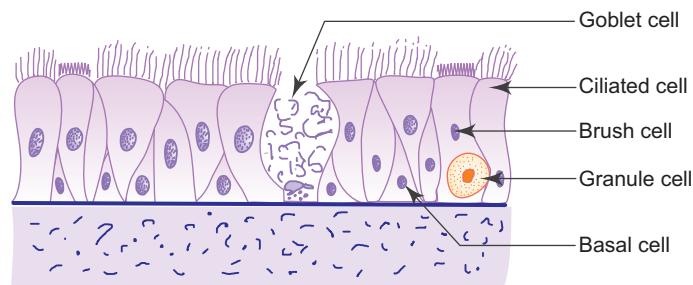


Fig. 16.4 Respiratory epithelium.

In **immotile cilia syndrome** the ciliary movement of the respiratory epithelium is impaired causing chronic respiratory tract infections. Male patients may also suffer from infertility due to sluggish movement of spermatozoa. This is due to the absence of a protein, **dynein** normally present in the cilia and flagella, responsible for their motility.

## PHARYNX

### GENERAL FEATURES

- Pharynx is a fibromuscular tube extending from the base of the skull to the level of the sixth cervical vertebra where it becomes continuous with the oesophagus.
- It lies behind the nasal cavity (*nasopharynx*), oral cavity (*oropharynx*) and larynx (*laryngopharynx*).

### STRUCTURE

- Pharynx is composed of the following four coats:

#### 1. Mucosa

- This comprises epithelium and lamina propria. The epithelium is pseudostratified ciliated columnar type in the nasopharynx and stratified squamous type in the oropharynx and laryngopharynx.
- Aggregation of lymphatic nodules in the lamina propria of the posterior wall and around the opening of the auditory tube in the nasopharynx results in the formation of *pharyngeal* and *tubal tonsils*, respectively. The palatine tonsil present in the lateral wall of the oropharynx and the lingual tonsil in the pharyngeal part of tongue, are already dealt with under lymphatic system.

#### 2. Submucosa

- It is formed by loose areolar connective tissue (pharyngobasilar fascia).

#### 3. Muscle coat

- This layer is formed by skeletal muscle arranged into inner longitudinal and outer circular layers. The circular layer is formed by the constrictors of pharynx.

#### 4. Adventitia

- It is formed by fibroelastic connective tissue (buccopharyngeal fascia).

## LARYNX

### GENERAL FEATURES

- Larynx is a specialised organ responsible for production of voice. It houses the vocal cords.
- Above it opens into the laryngopharynx, below it is continuous with the trachea.
- It has a cartilaginous framework which is made of nine cartilages (3 paired and 3 unpaired) that are connected to each other by membranes and ligaments and moved by skeletal muscles.
- The cartilages are either hyaline or elastic in nature. These are:

#### Hyaline cartilages

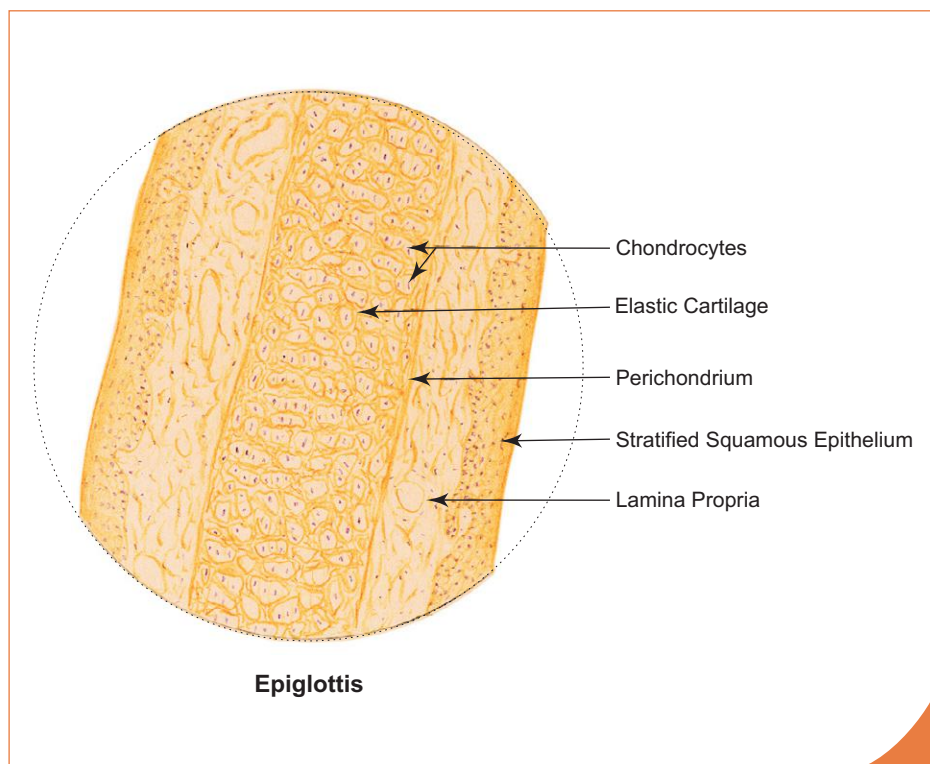
- Thyroid (unpaired)
- Cricoid (unpaired)
- Arytenoid (paired)

#### Elastic cartilages

- Epiglottis (unpaired)
- Cuneiform (paired)
- Corniculate (paired)

### STRUCTURE

- Most of the larynx is lined by pseudostratified ciliated columnar epithelium with goblet cells, except where it is subjected to friction or comes in contact with food where it is lined by stratified squamous epithelium (e.g. *anterior surface and upper part of the posterior surface of epiglottis and vocal folds*; Box 16.1). The lamina propria may contain seromucous glands and lymphatic tissue.



#### Box 16.1 Epiglottis.

Presence of

- (i) **elastic cartilage** in the middle;
- (ii) **stratified squamous epithelium** on one surface;
- (iii) stratified squamous or pseudostratified ciliated columnar epithelium on the other surface (depending on the plane of section).

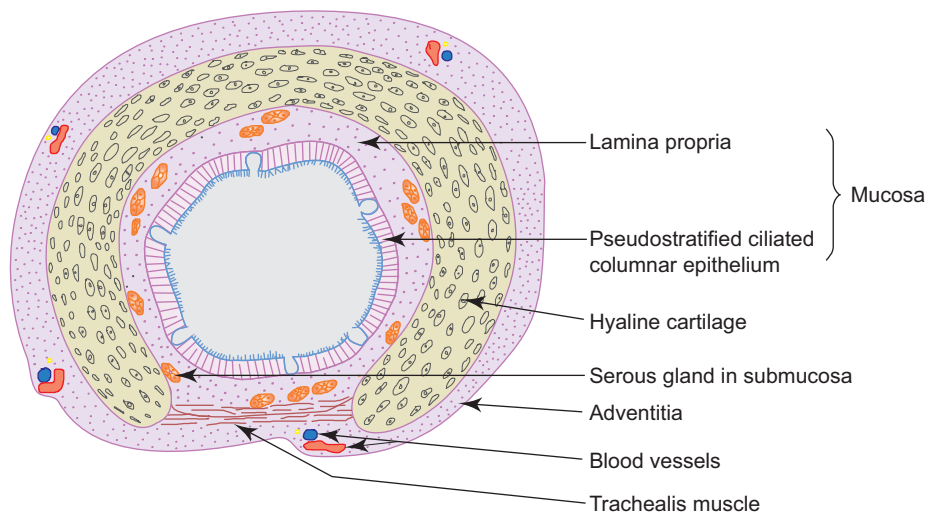
## TRACHEA

### GENERAL FEATURES

- Trachea is a flexible fibroelastic cartilaginous tube allowing expansion in width and extension in length during inspiration.
- It is 10 cm long and 2 cm wide.
- It extends from the lower border of cricoid cartilage ( $C_6$ ) to its level of bifurcation ( $T_4$ ) into right and left bronchi.
- It is also called the windpipe; the airway through which respiratory air is transported.
- It is supported by 16–20 C-shaped hyaline cartilage which keep the lumen patent.
- The free posterior ends of the C-shaped cartilage are joined by a band of smooth muscle (trachealis) and a fibroelastic ligament. The ligament prevents overdistension of the lumen and the muscle reduces the diameter on contraction during coughing which involves increased velocity of expired air required for cleaning the air passages.

### STRUCTURE

- The trachea is made of four coats, similar to the general plan of the respiratory tract (Fig. 16.5; Box 16.2). From inner to outer they are:
  1. **Mucosa**
    - It is composed of epithelium and lamina propria.
    - The epithelium is thick and is formed of pseudostratified ciliated columnar variety with goblet cells (respiratory epithelium).
    - The lamina propria consists of fibroelastic vascular connective tissue in which the elastic fibres are longitudinally oriented. Lymphocytes and mast cells are abundant.
  2. **Submucosa**
    - It is made of loose connective tissue found deep to lamina propria, containing mixed glands. (There is no clear demarcation between lamina propria and submucosa.)
  3. **Cartilage and smooth muscle layer**
    - It is formed by C-shaped hyaline cartilaginous rings. The posterior free ends of the cartilage ring is bridged by smooth muscle and fibroelastic ligament.
  4. **Adventitia**
    - It is made of fibroelastic connective tissue containing neurovascular structures.

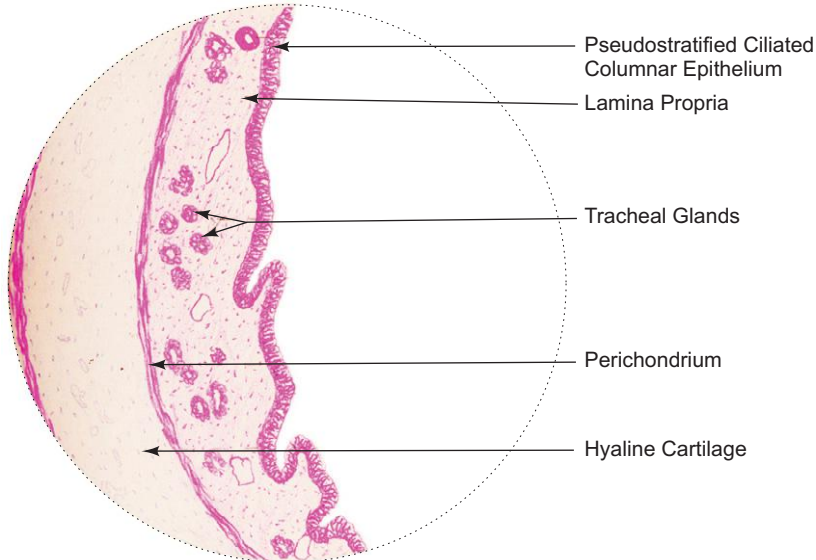


**Fig. 16.5** C.S. of trachea.

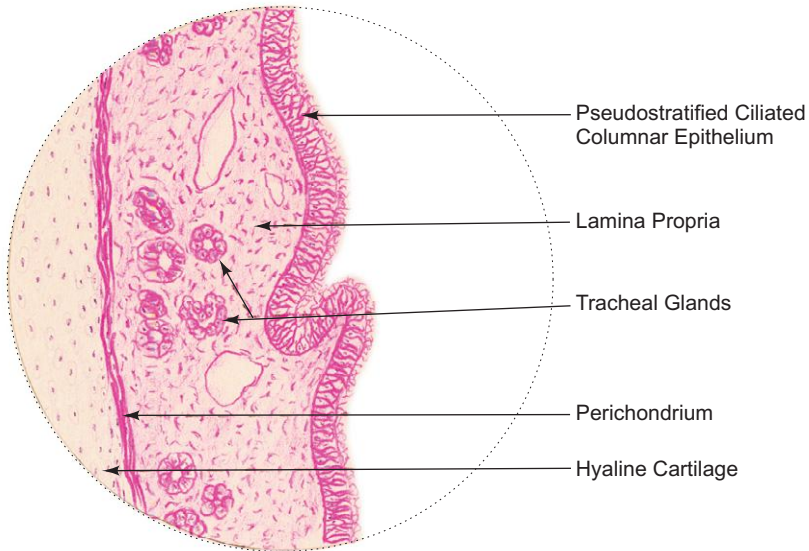
**Box 16.2** Trachea.

*Presence of*

- (i) **pseudostratified ciliated columnar epithelium** with goblet cells;
- (ii) **hyaline cartilage** (C-shaped);
- (iii) tracheal glands (mixed).



**L/P**  
**Trachea**



**H/P**  
**Trachea**



## PRINCIPAL BRONCHUS

- Trachea divides into principal bronchi in the thorax at the level of T<sub>4</sub>.
- Each principal bronchus enters the lung at the hilum.
- The structure of principal bronchus is similar to that of trachea.

## LUNGS: INTRAPULMONARY BRONCHUS AND ITS SUBDIVISIONS AND LUNG PARENCHYMA

### GENERAL FEATURES

- Lungs are the principal organs of respiration, situated in the thoracic cavity one on either side of the mediastinum.
- Each lung is conical in shape and is covered with visceral pleura.
- It contains the terminal parts of the bronchial tree, namely, intrapulmonary bronchus, bronchiole, respiratory bronchiole and lung parenchyma (alveolar ducts and alveoli) along with blood vessels.

### STRUCTURE

- The lining epithelium of bronchial tree gradually decreases in thickness as it is traced distally.
- Similarly, glands and goblet cells also gradually decrease and disappear completely at the distal part.
- The cartilagenous support decreases while the number of elastic fibres increase as the bronchial tree is traced distally.

#### 1. Intrapulmonary bronchus (i.e. secondary and tertiary bronchi)

- In the lung each principal bronchus divides into secondary or lobar bronchi which in turn divide into tertiary or segmental bronchi (Figs 16.6 and 16.7; Boxes 16.3 and 16.4). Following layers are observed in these bronchi from inner to outer:

##### (a) Mucosa

- It consists of epithelium and lamina propria.
- The epithelium is pseudostratified ciliated columnar variety with few goblet cells.
- The lamina propria is rich in elastic fibres (longitudinally oriented).
- Mucosa is thrown into folds by the contraction of underlying smooth muscle.

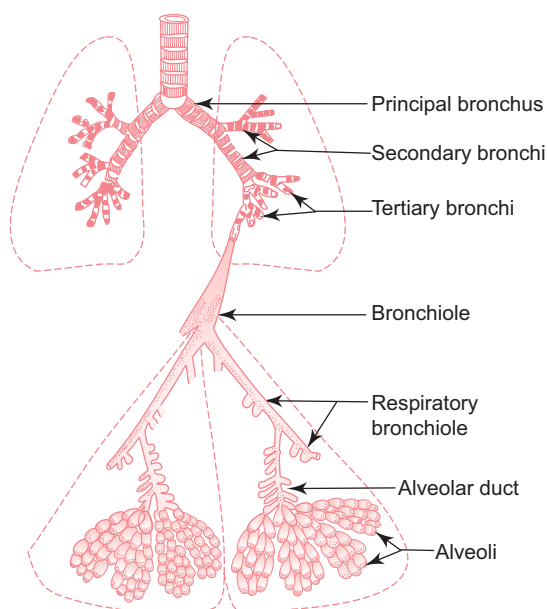


Fig. 16.6 Parts of bronchial tree.

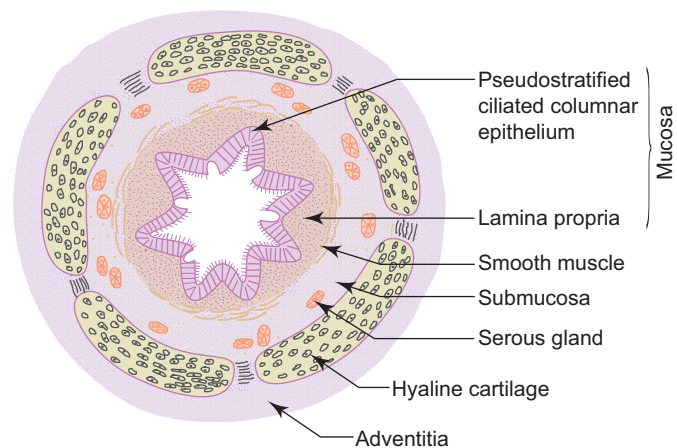


Fig. 16.7 C.S. of intrapulmonary bronchus.

(b) **Smooth muscle layer**

- This layer consists of spirally running criss-cross bundles of smooth muscle. Thus, in section the muscle layer appears to be discontinuous.

(c) **Submucosa**

- It contains few seromucous glands.

(d) **Cartilage layer and adventitia**

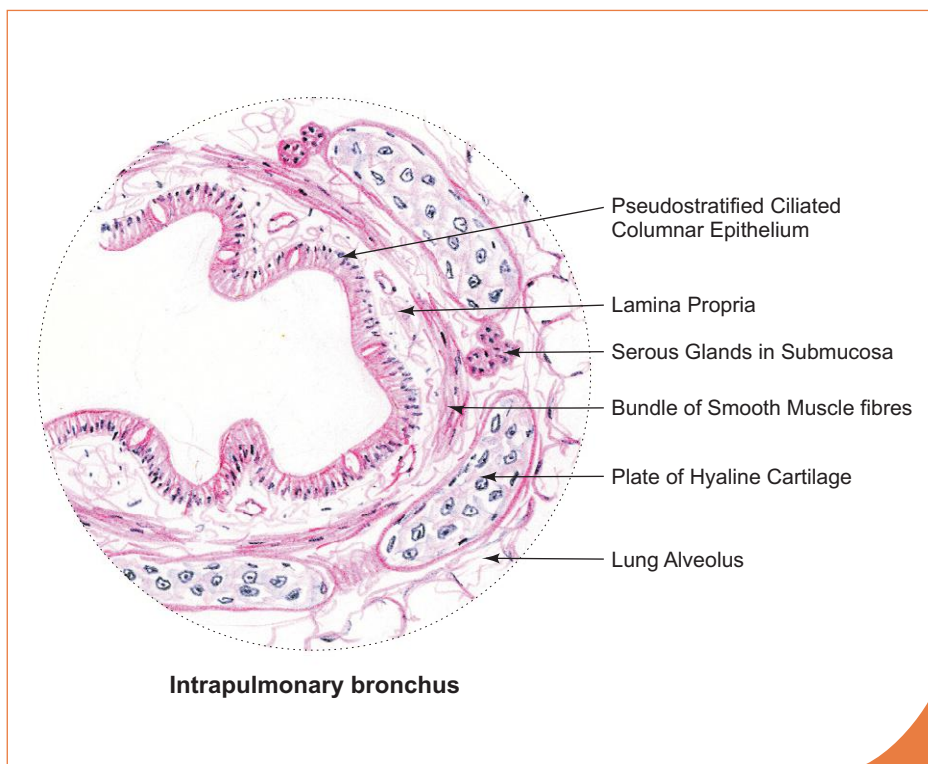
- In contrast to C-shaped cartilage present in the trachea, the intrapulmonary bronchus contains isolated plates of hyaline cartilage.

**2. Bronchiole**

- Bronchioles are formed by repeated division of the tertiary bronchi. Each bronchiole enters a pulmonary lobule, where it divides to form 5 to 7 terminal bronchioles.
- The diameter of the terminal bronchiole is less than 1 mm.
- Bronchioles are characterised by the presence of the following features (Fig. 16.8):
  - Simple columnar or cuboidal ciliated epithelial lining with no goblet cells. Here goblet cells are replaced by *Clara cells* which secrete a glycoprotein that protects the bronchiolar lining against oxidative pollutants and inflammation.
  - Thick smooth muscle layers (under the control of vagus and sympathetic nerves). Stimulation of vagus causes bronchoconstriction. Stimulation of sympathetic nerve causes bronchodilation.
  - Many elastic fibres
  - No glands
  - No cartilage

**3. Respiratory bronchiole**

- Respiratory bronchioles are derived from terminal bronchioles. It is the transitional part between conducting and respiratory portions of the lung.
- The structure of respiratory bronchiole is similar to that of terminal bronchiole, except that its wall is interrupted by alveoli as outpouchings.

**Box 16.3** **Intrapulmonary Bronchus.**

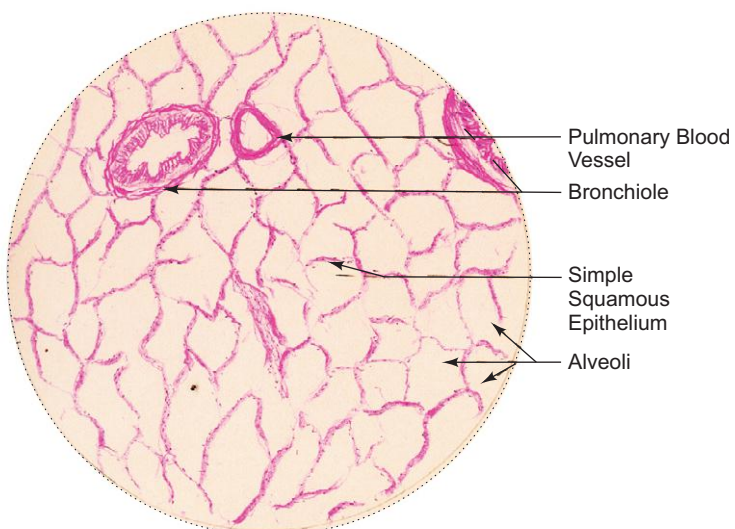
Presence of

- (i) **wavy mucous membrane** lined by **pseudostratified ciliated columnar epithelium**;
- (ii) isolated **plates of hyaline cartilage**;
- (iii) discontinuous bundles of **smooth muscle** separating mucosa from submucosa;
- (iv) glands in submucosa.

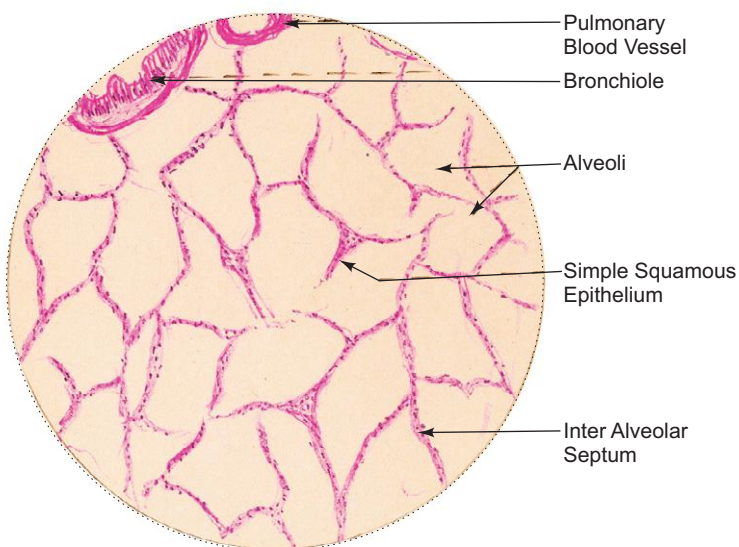
**Box 16.4 Lung.**

*Presence of*

- (i) **pulmonary alveoli** giving honey comb appearance in section;
- (ii) **simple squamous epithelium** lining the alveoli;
- (iii) bronchi, bronchioles and respiratory bronchioles.



L/P  
Lung



H/P  
Lung

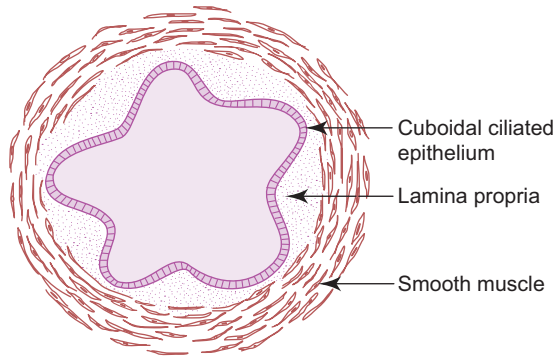


Fig. 16.8 T.S. of bronchiole.

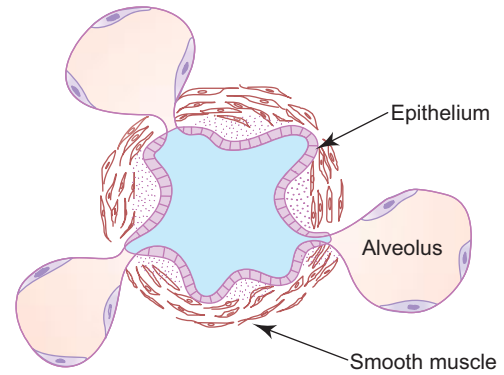


Fig. 16.9 T.S. of respiratory bronchiole.

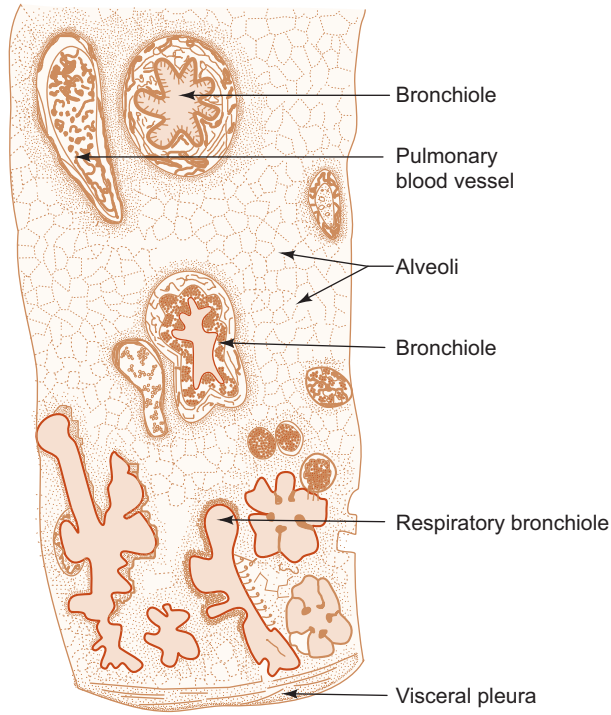
- The wall between the alveolar outpouchings is made of ciliated cuboidal epithelium with Clara cells, supported by smooth muscle and elastic fibres. The alveoli are lined by squamous alveolar epithelial cells (Fig. 16.9). Distally, respiratory bronchioles divide into alveolar ducts.

#### 4. Alveolar duct

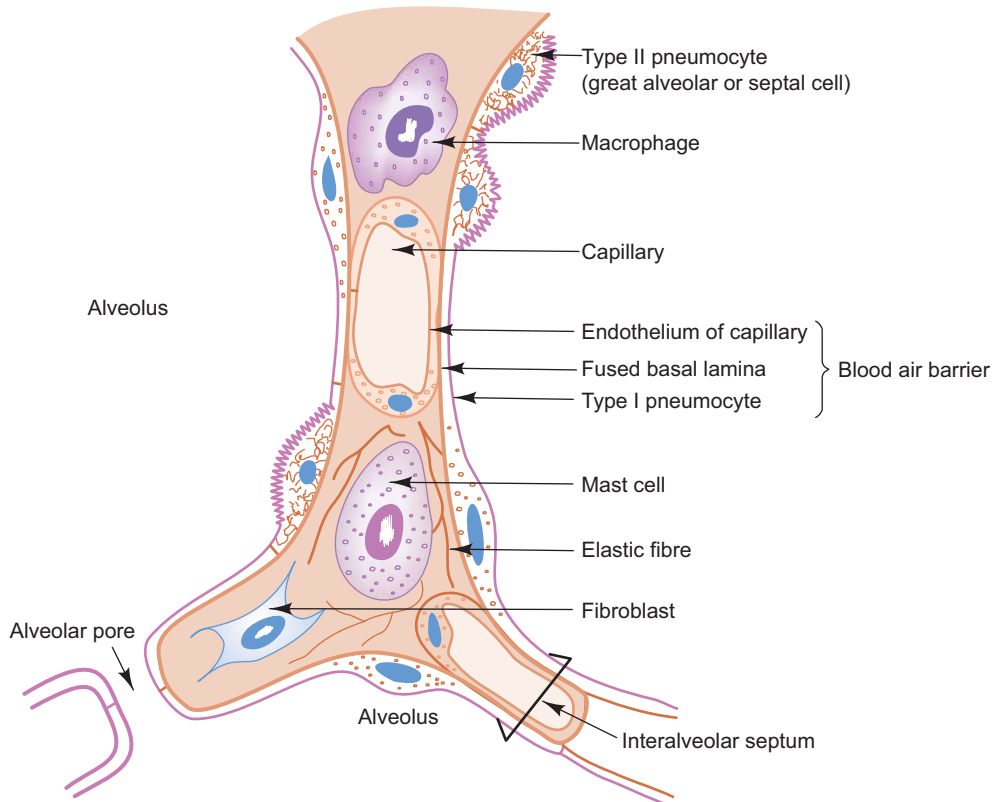
- Alveolar ducts arise from the respiratory bronchiole. They are lined by squamous epithelial cells supported by smooth muscle fibres and fibroelastic connective tissue. Many alveoli open into it along the length of the duct. So, in section the wall appears as knobs of smooth muscle between adjacent alveoli.
- Alveolar ducts open into atria, which communicate with alveolar sacs and alveoli.

#### 5. Alveoli

- Alveoli form the parenchyma of lung.
- They are sac-like evaginations present at the terminal part of the bronchial tree.
- They are responsible for the exchange of gases between air and blood.
- They give a spongy texture to the lung.
- The alveoli are compactly packed with many sides, of which one side opens into the alveolar sac. In section they resemble a honeycomb (Fig. 16.10; Box 16.4).
- Alveoli are separated by interalveolar septum which lies between thin squamous epithelial linings of two neighbouring alveoli.
- The interalveolar septum (Fig. 16.11) contains a network of capillaries supported by reticular and elastic fibres, and occasionally fibroblasts, mast cells and macrophages. The septum may contain pores (alveolar pores of Kohn) which help in passage of air from one alveolus to another, thus equalizing the pressure in the alveoli.
- The elastic fibres enable the alveoli to expand during inspiration and passively contract during expiration.
- The reticular fibres support and prevent overdistension of the alveoli.
- Capillaries present in the interalveolar septum are lined by continuous endothelium, the cytoplasm of which contains numerous pinocytotic vesicles. The organelles are grouped around the nucleus to make the rest of the area extremely thin allowing better exchange of gases.
- Alveolar macrophages (*dust cells*) are derived from monocytes and are a part of mononuclear phagocytic system. The cytoplasm of macrophages contain phagocytosed inhaled carbon and dust particles which are passed on to them from pneumocyte I through pinocytotic vesicles. The alveolar macrophages sometimes migrate from septum to alveolar surface (having come, cannot go back to septum) and are carried to the pharynx through sputum and their characteristics is of diagnostic importance.



**Fig. 16.10** Section of lung.



**Fig. 16.11** Components of interalveolar septum.

- The lining epithelium of the alveolus is made of two types of cells, viz.,
  - (a) *Type I pneumocytes/squamous epithelial cells*
    - Extremely thin squamous cells (25 nm thick).
    - Cover 97% of alveolar surface.
    - Contain abundant pinocytic vesicles which play a role in absorption of surfactant and removal of particulate contaminants from the surface.
    - Form part of the *blood-air barrier*.
  - (b) *Type II pneumocytes/great alveolar cells/septal cells*
    - Roughly cuboidal in shape, found in groups of 2 or 3 cells between type I pneumocytes.
    - Cover 3% of alveolar surface.
    - Bear microvilli on their free surfaces.
    - Contain foamy vacuolated cytoplasm due to presence of lamellated bodies.
    - These lamellated bodies contain a complex lipoprotein which on release spreads over the alveolar surface forming *pulmonary surfactant* that lowers the surface tension and prevents the alveoli from collapsing during expiration. The surfactant also has bactericidal properties. The surfactant layer is constantly being renewed. It is removed from the surface by type I pneumocytes and macrophages.

In case of premature birth, newborns exhibit **respiratory distress syndrome** (hyaline membrane disease) due to absence of surfactant since surfactant is produced only in the last week of gestation. These premature babies have difficulty in expanding the already collapsed alveoli due to insufficient production of surfactant. A fibrin rich eosinophilic material called hyaline membrane lines the respiratory bronchioles and alveolar ducts of these babies. Synthesis of surfactant can be induced by administration of glucocorticoids.

**Asthma** is an acute airway obstruction due to contraction of bronchiolar smooth muscle (bronchospasm) and swelling of mucosa in response to certain allergic condition (pollen, dust, etc). Asthma is treated with epinephrine and other sympathomimetic drugs, which relax smooth muscle in bronchioles.

The respiratory tract mucosa is subjected to many irritants including inhaled carbon and other toxic elements as in smokers and some industrial workers. Prolonged or repeated damage to the respiratory epithelium leads to change of its pseudostratified ciliated columnar epithelium into stratified squamous epithelium (**squamous metaplasia**). This transformation is the first step in the development of the **squamous cell carcinoma** which is the main type of cancer of lung.

Cigarette smoking may also lead to **emphysema**, a condition in which the lung alveoli are enlarged with destruction of interalveolar septum caused by impairment of synthesis of elastic fibres and other components of septum.

# Self-assessment Exercise

## I. Write Short notes on:

- (a) Olfactory mucosa
- (b) Histology of trachea
- (c) Epiglottis
- (d) Pulmonary alveolar epithelium
- (e) Histology of lung

## II. Fill in the blanks:

1. Vestibule of nose is lined by \_\_\_\_\_
2. In the bronchiole, goblet cells are replaced by \_\_\_\_\_
3. Bronchial tree ends in \_\_\_\_\_
4. Pulmonary surfactant is produced by \_\_\_\_\_
5. The conducting portion of the respiratory system is generally lined by \_\_\_\_\_

## III. Choose the best answer:

1. Septal cells of the lung alveoli are involved in
  - (a) blood-air barrier
  - (b) phagocytosis
  - (c) production of surfactant
  - (d) allergic reaction
2. Which one of the following is an example of elastic cartilage?
  - (a) Epiglottis
  - (b) Cricoid cartilage
  - (c) Arytenoid cartilage
  - (d) Thyroid cartilage
3. Bowman's glands are present in
  - (a) submucosa of duodenum
  - (b) submucosa of oesophagus
  - (c) olfactory mucosa
  - (d) cortex of kidney
4. Bronchiole is characterised by
  - (a) presence of Clara cells
  - (b) absence of glands
  - (c) absence of cartilage
  - (d) all of the above
5. Which one of the following is *not* lined by stratified squamous epithelium?
  - (a) Oropharynx
  - (b) Nasopharynx
  - (c) Vocal cord
  - (d) Lingual surface of epiglottis

**IV. State whether the following statements are true (T) or false (F):**

1. The wall of the bronchiole is supported by plates of hyaline cartilage ( )
2. Vocal cord is lined by stratified squamous epithelium ( )
3. Fila olfactoria are derived from dendritic processes of olfactory cells ( )
4. The respiratory epithelium is thicker than the olfactory epithelium ( )
5. Type I pneumocytes cover 97% of the alveolar surface ( )

**V. Match the items in column 'A' with those of column 'B':**

- | Column 'A'                          |     |     | Column 'B'               |
|-------------------------------------|-----|-----|--------------------------|
| 1. Respiratory distress syndrome    | ( ) | (a) | Bronchodilation          |
| 2. Stimulation of vagus nerve       | ( ) | (b) | Bronchoconstriction      |
| 3. Stimulation of sympathetic nerve | ( ) | (c) | Respiratory mucosa       |
| 4. Conditioning of the inspired air | ( ) | (d) | Hyaline membrane disease |
| 5. Removal of surfactant            | ( ) | (e) | Type I pneumocytes       |

**Answers**

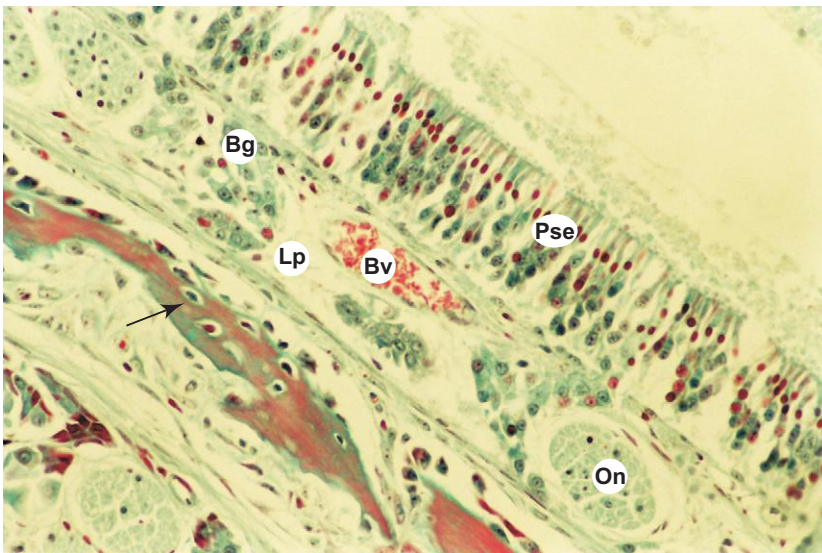
- II.** 1. Skin      2. Clara cells      3. Alveolus      4. Type II pneumocytes or septal cells  
5. Pseudostratified ciliated columnar epithelium
- III.** 1. c      2. a      3. c      4. d      5. b
- IV.** 1. (F)      2. (T)      3. (F)      4. (F)      5. (T)
- V.** 1. d      2. b      3. a      4. c      5. e



# Practical No. 16

## Respiratory System

X200



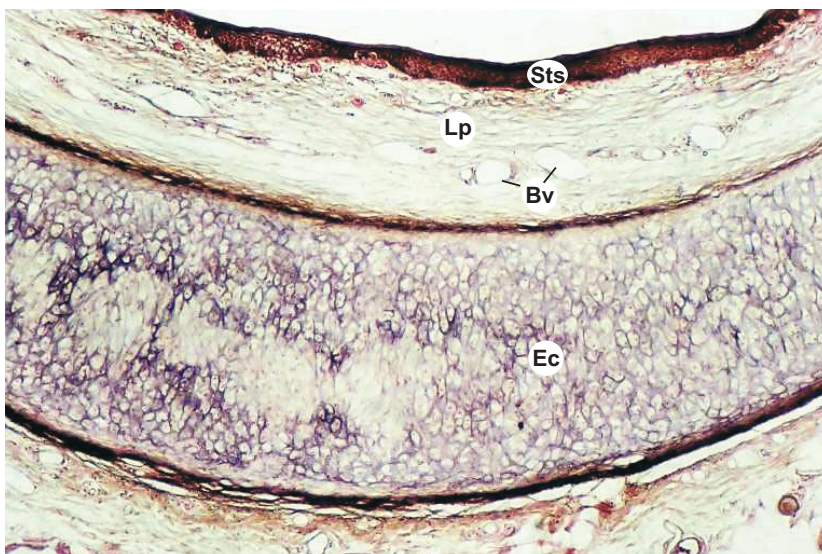
### Plate 16:1 Olfactory mucosa (special stain).

In a section of olfactory mucosa (Plate 16:1), note the following features:

- The thick *pseudostratified columnar epithelium* (Pse) with olfactory hair. It is devoid of goblet cells.
- The nuclei of different types of cells present in the epithelium, arranged into a superficial narrow *zone of oval nuclei* of sustentacular cells and a deep broad *zone of round nuclei* of olfactory and basal cells.
- *Bowman's glands* (Bg; serous), *olfactory nerves* (On) and blood vessels (Bv) in the lamina propria (Lp).

Arrow = bony trabeculum.

X40

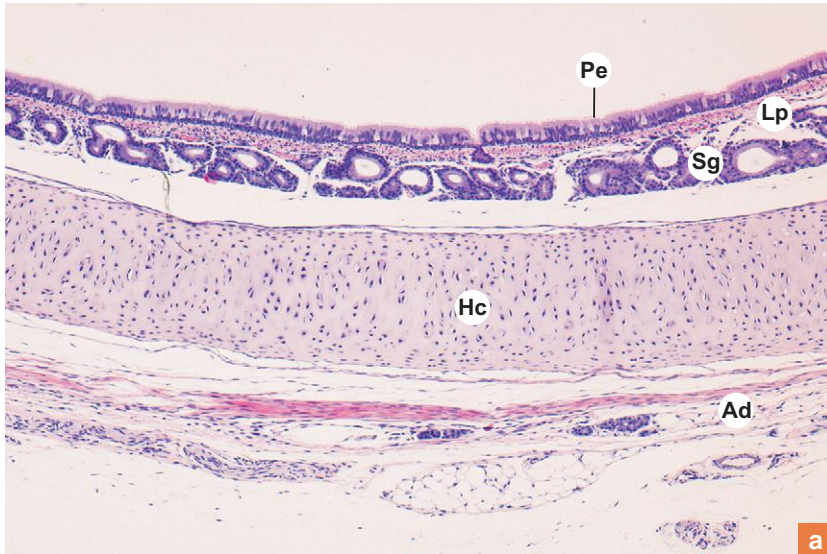

### Plate 16:2 Epiglottis (special Stain).

A section of epiglottis at low magnification (Plate 16:2) shows the following features:

- Elastic cartilage (Ec) forming the central core, covered by mucous membrane on either side.
- The epithelium of the mucous membrane is stratified squamous epithelium (Sts) on one side (anterior surface) and stratified squamous or pseudostratified ciliated columnar epithelium on the other side (posterior surface) depending on the level of section (not seen).
- The lamina propria (Lp) contains blood vessels (Bv) and mixed glands (not seen).

X40



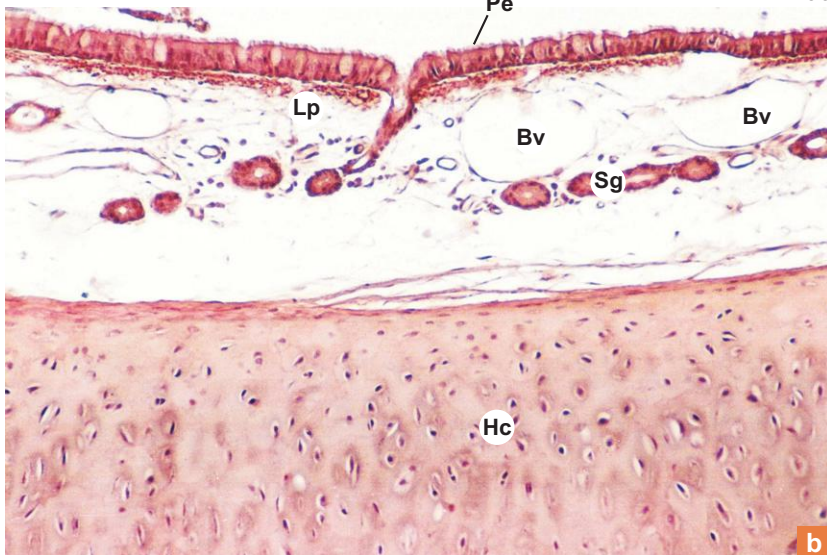
a

**Plate 16:3** Trachea.  
**a and b**

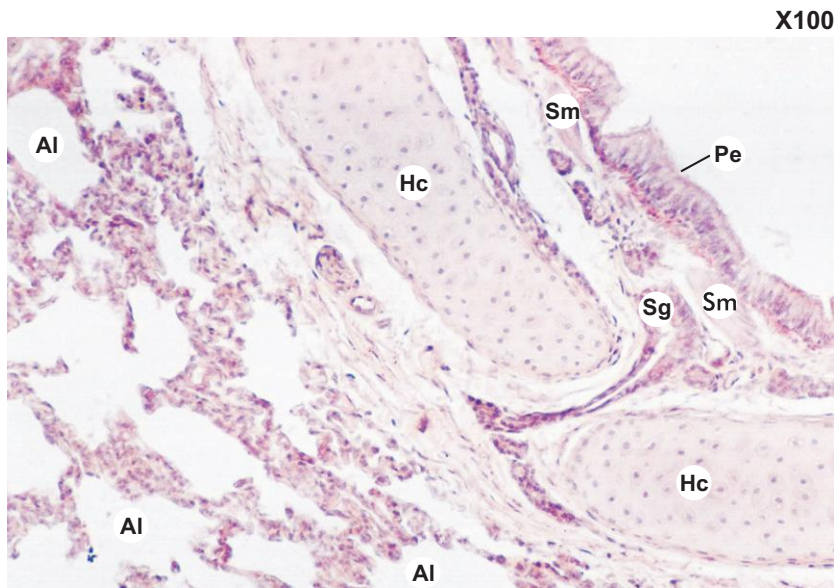
Examine a section of trachea (Plate 16:3a and b) and identify the various layers;

- Mucosa is formed by the pseudostratified ciliated columnar epithelium (Pe) with goblet cells and the underlying lamina propria (Lp).
- Submucosa is the deeper part of lamina propria made of loose connective tissue containing mucous/serous glands (Sg) and blood vessels (Bv).
- The next layer is made of hyaline cartilage (Hc). External to it is the adventitia (Ad) carrying neurovascular structures.

X100



b

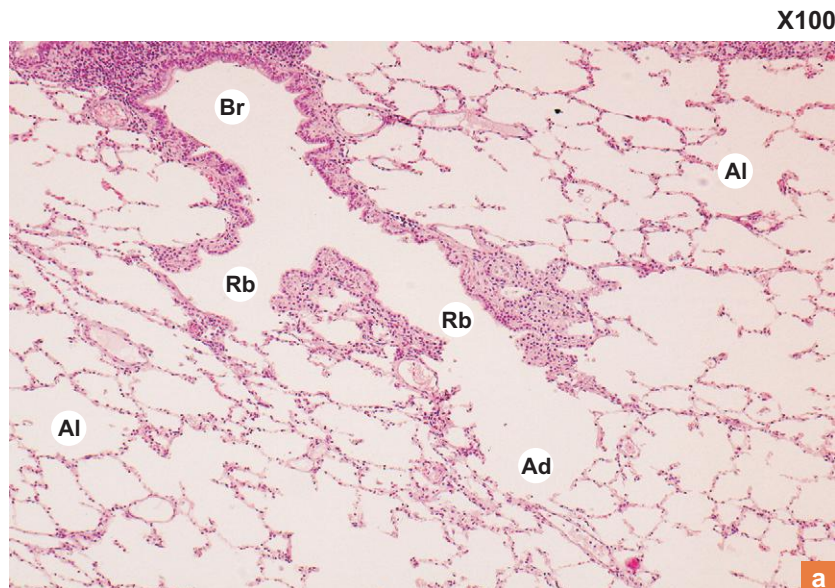


X100

**Plate 16:4** Intrapulmonary bronchus.

In a section of lung, look for large intrapulmonary bronchus (Plate 16:4) which is characterised by the presence of following structures:

- Wavy mucosa lined by pseudostratified ciliated columnar epithelium (**Pe**) with few goblet cells.
- Discontinuous bundles of smooth muscle (**Sm**).
- Submucosa containing serous glands (**Sg**).
- Plates of hyaline cartilage (**Hc**).
- Lung alveoli (**Al**) surrounding the bronchus.

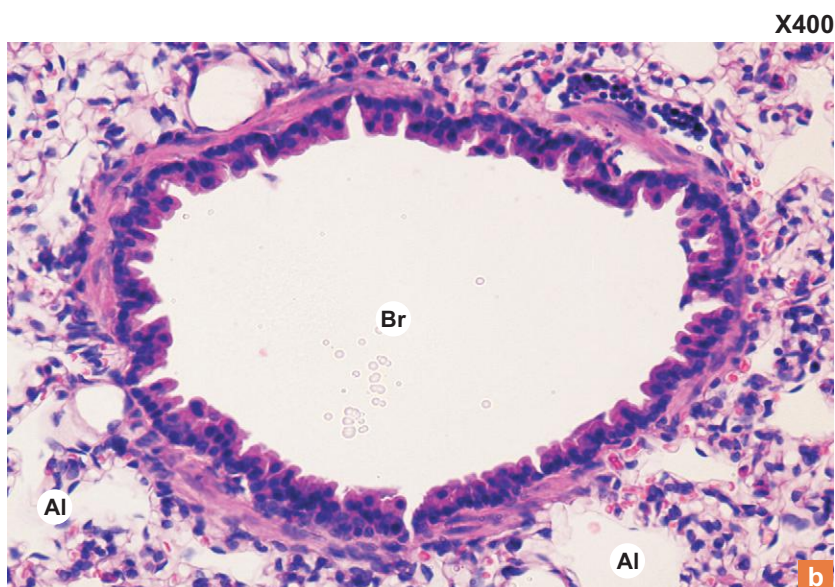


X100

**Plate 16:5** a. Lung.  
a and b b. Lung bronchiole.

At low magnification (Plate 16:5a) examine the entire section of lung by moving the slide both horizontally and vertically and identify the various parts of the bronchial tree. Then examine each part at higher magnification (Plate 16:5b) for their structural detail. Each of them can be identified by the presence of the following features:

- *Terminal bronchiole (Br)* – the presence of thick smooth muscle layer and absence of glands and cartilage in its wall.
- *Respiratory bronchiole (Rb)* – its wall is interrupted by the opening of alveoli. Both the bronchioles are lined by ciliated cuboidal epithelium, with clara cells replacing goblet cells.
- *Alveolar ducts (Ad)* – squamous epithelial lining supported by smooth muscle fibres.
- *Alveoli (Al)* – honeycomb appearance in section. The alveoli are lined by simple squamous epithelium.



X400

b

# 17

## ENDOCRINE GLANDS

### INTRODUCTION

Endocrine glands are ductless glands. They secrete hormones which are discharged into the interstitial spaces from which they are rapidly absorbed into the blood stream. So, they are highly vascular with fenestrated sinusoidal capillaries. In general, the secretory cells of endocrine glands are characterised by prominent nucleus and well developed organelles, especially mitochondria, endoplasmic reticulum and Golgi complex.

Most of the biological phenomena of the body are under the control of both endocrine and nervous systems. So, they are often regarded as a single *neuro-endocrine system*.

The endocrine glands exist either as discrete organs or are found as small collection of cells in association with other organs. The discrete endocrine glands are:

1. Pituitary (hypophysis cerebri)
2. Thyroid
3. Parathyroid
4. Adrenal (suprarenal)
5. Pineal

Endocrine tissues found in association with other organs are:

1. *Islet of Langerhans*—in pancreas
2. *Interstitial cells of Leydig*—in testis
3. *Ovarian follicle and Corpus luteum*—in ovary
4. *Chorion*—in placenta
5. *Lacis cells, JG cells*—in kidney
6. *Enteroendocrine cells*—in GIT (APUD cell system)

These endocrine tissues are described along with the organs they are associated with.

### PITUITARY (HYPOPHYSIS CEREBRI)

#### GENERAL FEATURES

- Pituitary is oval in shape and weighs 0.5 g.
- It measures 15 mm transversely, 10 mm anteroposteriorly and 6 mm vertically.
- It lies in a bony cavity in the sphenoid bone called *sella turcica* and is covered by a fold of dura mater called *diaphragma sellae*.
- It is attached by a stalk (infundibular stalk) to the median eminence of the tuber cinereum (part of hypothalamus) in the floor of the third ventricle.
- Pituitary is regarded as the *master endocrine gland* because some of the hormones secreted by it control the secretory activity of other endocrine glands. However, its own activity is under the direct influence of the regulatory hormones produced by the hypothalamus.

## DEVELOPMENT

- Pituitary develops partly from oral ectoderm and partly from neurectoderm.
- The posterior part of the pituitary, the *neurohypophysis*, is derived from neurectoderm and it develops as a downgrowth of diencephalon (infundibular process).
- The anterior part of the pituitary, the *adenohypophysis* is derived from oral ectoderm as an outpouching (Rathke's pouch) from the roof of the stomodeum or primitive oral cavity.
- The Rathke's pouch detaches from the primitive oral cavity but the infundibular process remains attached to the base of the brain and forms the infundibular stalk.

## Subdivisions of Pituitary (Fig. 17.1)

- As stated earlier, pituitary gland consists of two lobes, adenohypophysis that produces and secretes most of the hormones, and neurohypophysis that stores and releases neurohormones received from the hypothalamus.
- The **adenohypophysis** is subdivided into three parts by a cleft or a row of follicles or cysts-like spaces which represent the remains of the cavity of Rathke's pouch:
  1. *Pars distalis*—the main anterior part found in front of hypophyseal cleft.
  2. *Pars tuberalis*—the cranial projection of pars distalis that surrounds the infundibulum.
  3. *Pars intermedia*—the part lying between neurohypophysis and hypophyseal cleft.
- The **neurohypophysis** is divided into two parts:
  1. *Pars nervosa*—the part that lies posterior to pars intermedia.
  2. *Infundibulum*—the stalk that connects the pars nervosa to the hypothalamus in the floor of III ventricle.

## Blood Supply (Hypothalamo-hypophyseal Portal System)

- Pituitary is supplied by two sets of hypophyseal arteries (superior and inferior) derived from internal carotid artery.
- The superior hypophyseal arteries (right and left) supply and break up into a capillary network in the median eminence and the adjoining parts of infundibulum and pars tuberalis. This fenestrated capillary network is called *primary capillary plexus*. The axons of tuberohypophyseal neurons of hypothalamus terminate close to this plexus and pour their neurosecretion (regulatory hormones) into it.

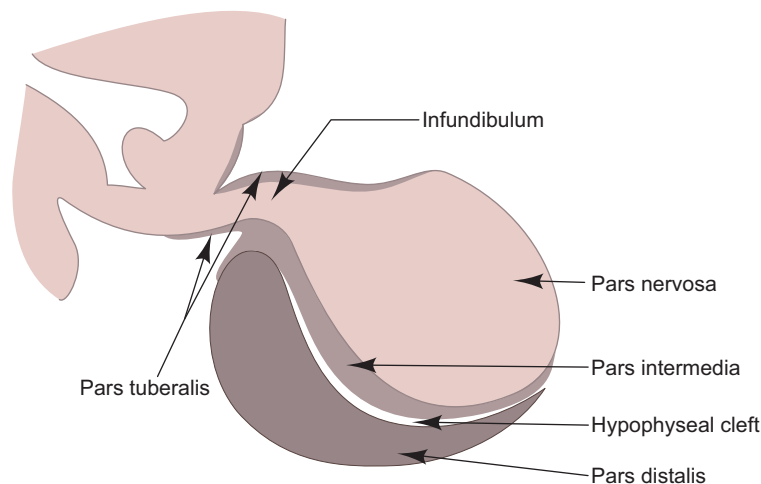
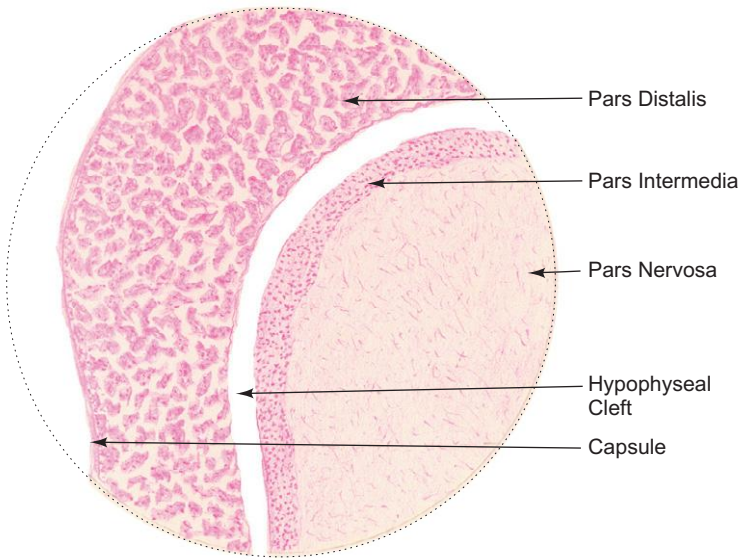


Fig. 17.1 Pituitary gland.

**Box 17.1 Pituitary Gland.**

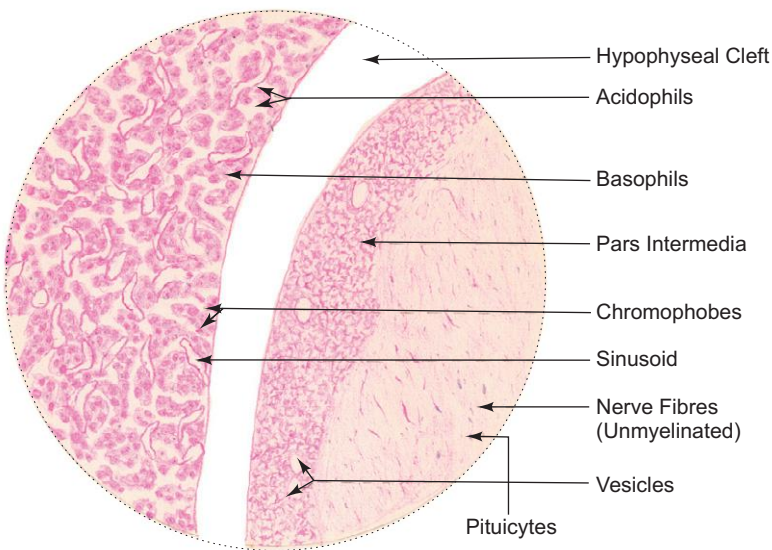
*Presence of*

- (i) **pars distalis** containing; chromophobes and chromophils;
- (ii) **pars nervosa** containing unmyelinated nerve fibres and pituicytes;
- (iii) **pars intermedia** separated from pars distalis by hypophyseal cleft.



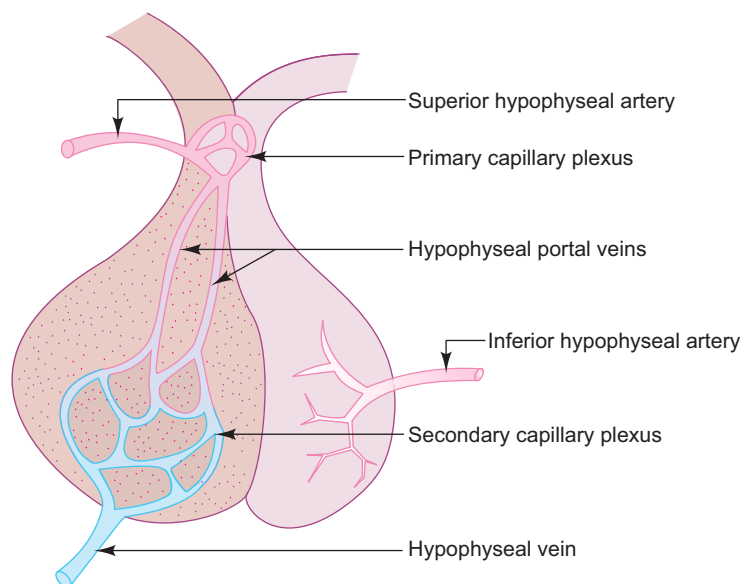
*L/P*

**Pituitary gland**



*H/P*

**Pituitary gland**



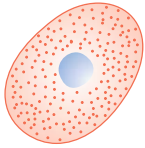
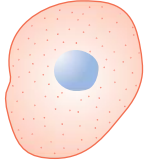
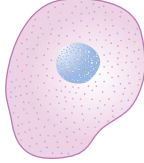
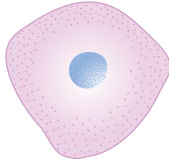
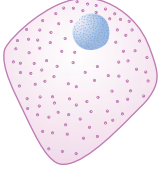
**Fig. 17.2** Hypothalamo-hypophyseal portal system.

- Long hypophyseal portal veins arise from the primary plexus, traverse the pituitary stalk and break up into a *secondary capillary plexus* in relation to pars distalis. This vascular arrangement is referred to as hypothalamo-hypophyseal portal system (Fig. 17.2).
- The significance of this portal circulatory system is that it enables regulatory hormones (releasing and inhibiting) produced by certain hypothalamic neurons to reach adenohypophysis where they regulate the secretory activities of different types of cells.
- The inferior hypophyseal arteries (right and left) mainly supply the pars nervosa and adjoining part of infundibulum.
- The venous blood is carried to hypophyseal veins that in turn drains into the cavernous sinuses.

## Adenohypophysis

- The cells of the adenohypophysis are arranged as irregular cords or clusters in between the secondary capillary plexus of hypothalamo-hypophyseal portal system. These cells are broadly classified into two major groups, namely, *chromophils* and *chromophobes*, based on the affinity of their granules for specific stains. Chromophils are darkly stained owing to the presence of secretory granules, while chromophobes are poorly stained because they contain few or no granules. Chromophils are further classified into *acidophils* and *basophils* based on their staining characteristics (Box 17.1) with either acid dyes (eosin, orange G, erythrosin, etc.) or basic dyes (haematoxylin, aniline blue, etc.).
- Electron microscopic and immunocytochemical studies reveal that acidophils and basophils can be further divided into subtypes on the basis of the size and shape of the secretory granules and the hormones produced by them.
- The various cell types, their structure and functions are enumerated in Table 17.1.
- Pars intermedia of adenohypophysis is well developed in lower vertebrates (amphibians and fishes) but poorly developed in man. In lower vertebrates, it produces melanocyte-stimulating hormone (MSH), which increases pigmentation of skin by activating melanocytes. In man, pars intermedia remains rudimentary and is made of colloid-filled cysts or follicles. These follicles are remnants of Rathke's pouch and are lined by basophils. The function of these cells is not clearly known. It is believed that they produce MSH, ACTH and lipotropic hormone (LPH).

**Table 17.1** Characteristic features of different types of chromophils

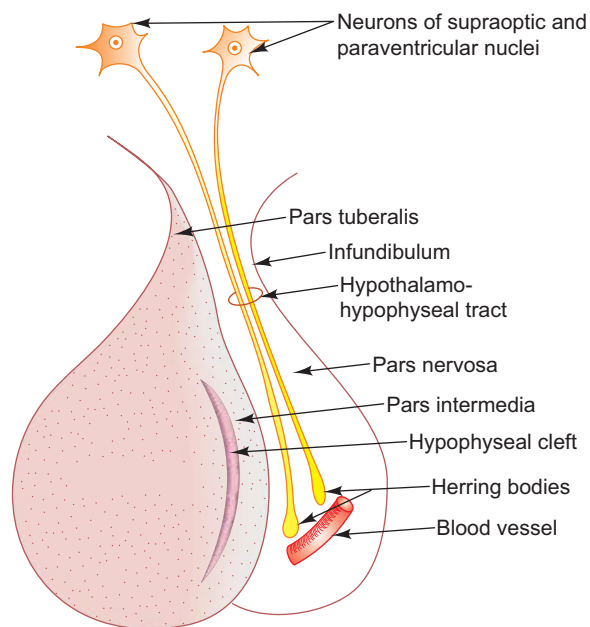
	Chromophils				
	Acidophils		Basophils		
	Somatotrophs	Lactotrophs	Gonadotrophs	Thyrotrophs	Corticotrophs
<i>Diagram</i>					
<i>Shape of cells</i>	Round or oval	Small irregular	Large rounded	Polyhedral	Polygonal
<i>Affinity for stain</i>	Orange G	Carmine and Erythrosin	Aniline blue and PAS +	Aniline blue and PAS +	Aniline blue and PAS (Weakly )
<i>Size of secreting granules</i>	350–400 nm	200 nm (600 nm during lactation)	275–375 nm	120–200 nm	375–550 nm
<i>Hormone</i>	GH	Prolactin (PRL)	LH and FSH	TSH	ACTH and MSH
<i>Site of action (target organ) and effect</i>	Skeletal tissue (epiphyseal cartilage and muscle)	Mammary gland  PRL   Breast development and milk secretion	Ovary and Testis  FSH   Follicular development in females and spermiogenesis in males  LH (ICSH)   Ovulation and formation of corpus luteum in females and stimulation of Leydig cells to secrete testosterone in males	Thyroid T <sub>3</sub> and T <sub>4</sub>	Adrenal cortex and ACTH   Corticosteroid secretion MSH   Pigmentation of skin

Tumours of pituitary are usually benign in type and cause excessive secretion of hormones (ACTH and GH) uncontrolled by any feedback mechanism. Tumours of corticotrophs secrete excess ACTH which stimulates the adrenal cortex to produce large quantities of corticosteroids leading to **Cushing's syndrome**. Tumours of somatotrophs secrete excess growth hormone causing **gigantism** in children and **acromegaly** in adults. Some tumours of pituitary produce no hormones but grow out of the sella turcica and may compress the optic chiasma above causing **bitemporal hemianopia** and sometimes blindness.



## Neurohypophysis

- Neurohypophysis, unlike adenohypophysis, does not contain secretory cells. It is composed mainly of *unmyelinated axons* (100,000) and highly branched glial cells called *pituitocytes*. The neuronal cell bodies of these axons are situated in the supraoptic and paraventricular nuclei of the hypothalamus. They are secretory neurons involved in synthesis of neurosecretory materials, *oxytocin* and *vasopressin or antidiuretic hormone (ADH)*. These two hormones are transported along the axons (hypothalamo-hypophyseal tract) and stored at their nerve terminals in the pars nervosa as *Herring bodies*. From Herring bodies, they are released into the fenestrated capillaries as and when impulses reach them from hypothalamus. It is understood that supraoptic nuclei are mainly concerned with vasopressin and paraventricular nuclei with oxytocin secretion (Fig. 17.3).
- Oxytocin performs important function in the female during final stage of pregnancy, parturition and lactation. It stimulates contraction of smooth muscle (myometrium) of the uterus during parturition. After delivery, while nursing, the sucking action of the infant stimulates secretion of oxytocin which causes contraction of myoepithelial cells of secretory alveoli causing milk ejection from breast.
- Vasopressin (ADH) is released in response to hypertonicity of blood usually resulting from water loss or excess salt intake. Its main action is to increase the permeability of the collecting tubules and ducts of kidney to water. This allows more water to be reabsorbed by the kidney than eliminated in the urine. Thus, it helps to regulate the osmotic balance of the internal milieu. Vasopressin may also induce vasoconstriction causing increased blood pressure.



**Fig. 17.3** Sagittal section of pituitary gland.

Deficiency of ADH due to lesion of hypothalamus may lead to a condition called **diabetes insipidus** in which the individual drinks large quantity of liquid/water and excretes excess of urine (20 l per day, i.e. polyuria).

## THYROID

### GENERAL FEATURES

- Thyroid is a highly vascular bilobed (right and left) endocrine gland situated in the lower part of the neck clasping trachea and larynx. The right and left lobes are connected by a median isthmus.
- It is brownish red in colour and weighs 25–30 g. It is heavier in females (enlarges during menstruation and pregnancy).
- It is covered by two capsules, an inner fibroelastic true capsule and an outer fascial false capsule, which is derived from pre-tracheal fascia.
- Among endocrine glands, thyroid is unique as it stores large quantity of its hormonal secretion extracellularly as colloid in contrast to other endocrine glands which store very small quantities intracellularly as secretory granules only.

### DEVELOPMENT

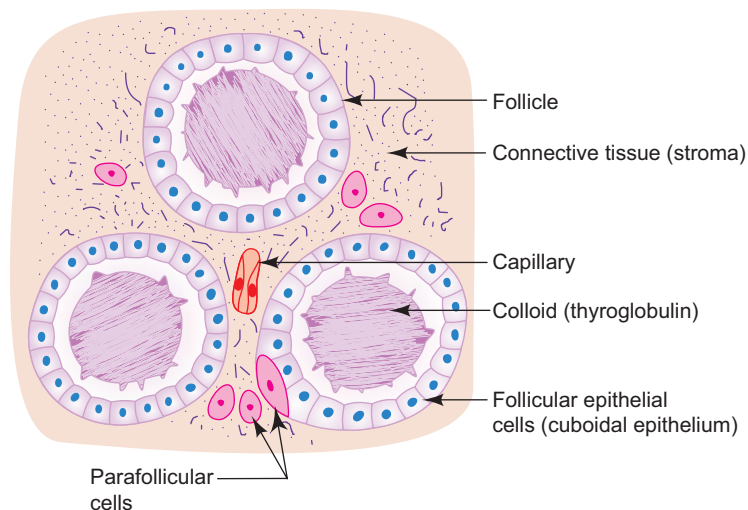
- Bulk of the gland (follicular cells) is derived from *thyroglossal duct* which develops as an outgrowth from the floor of the primitive pharynx just behind the tuberculum impar, whereas the parafollicular cells develop from ultimobranchial body of the fourth branchial pouch.

### STRUCTURE

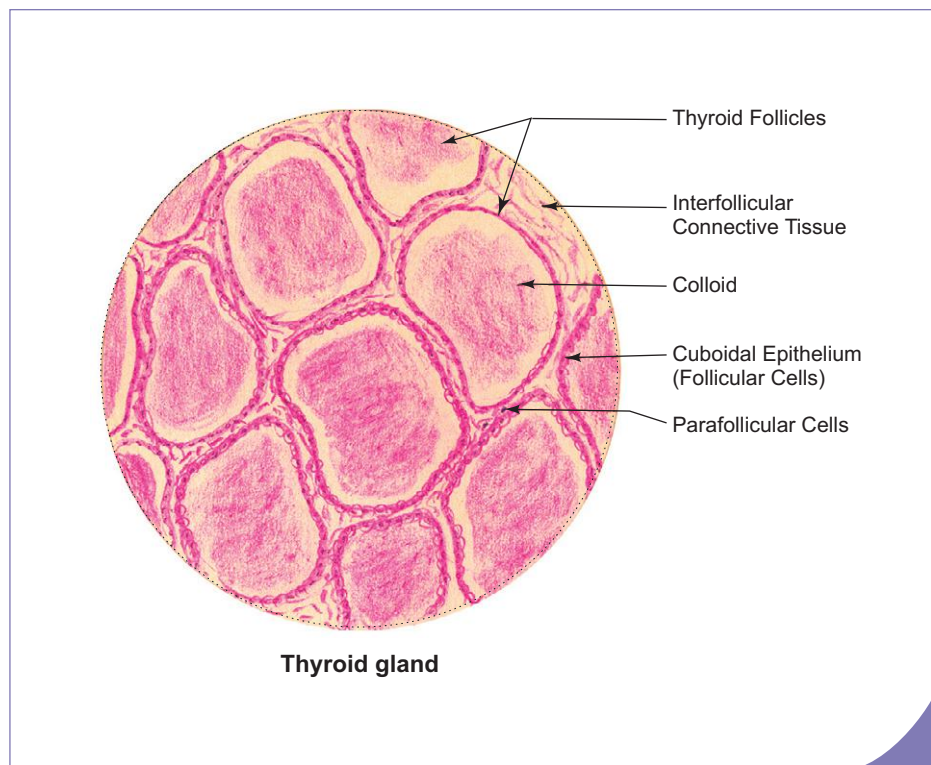
- Microscopically, thyroid gland is composed of stroma (connective tissue interspersed with capillaries) and parenchyma (thyroid follicles).

#### Stroma

- The connective tissue framework of the gland forms the stroma of the organ, which includes the capsule and the supporting intralobular loose areolar connective tissue.
- The fibroelastic true capsule covers the gland and sends delicate septae dividing the gland into a number of ill-defined lobules.
- The intralobular loose areolar and reticular tissue provide bed for the parenchyma (thyroid follicles) and blood vessels (Fig. 17.4).



**Fig. 17.4** Structure of thyroid gland.

**Box 17.2 Thyroid Gland.**

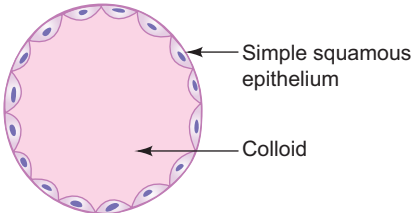
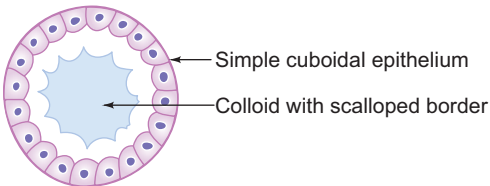
Presence of

- (i) **thyroid follicles lined by simple cuboidal epithelium;**
- (ii) thyroid follicles filled with **colloid (thyroglobulin);**
- (iii) **parafollicular cells** or clear (C) cells between thyroid follicles (some times within the follicles).

### Parenchyma (Thyroid Follicles)

- The structural and functional units of the gland are known as *thyroid follicles*, which are spherical in shape (0.9 mm diameter).
- In general, thyroid follicles are lined by a simple cuboidal epithelium consisting of follicular cells. The height of the *follicular cells* varies with the secretory activity of the gland (Fig. 17.4; Box 17.2).
- The follicular cells are responsible for the synthesis and secretion of thyroid hormones, namely, *tri-iodothyronine* ( $T_3$ ) and *tetra-iodothyronine* ( $T_4$ ) or thyroxine.
- The lumen of the follicle contains a homogeneous gel-like substance called *colloid* or *thyroglobulin* which is the stored inactive form of thyroid hormones.
- Whenever active thyroid hormone is required, the follicular epithelial cells take up some of the stored colloid and convert it into  $T_3$  and  $T_4$  which pass into the adjacent capillaries.
- $T_4$  is released in much larger quantities (90%) than  $T_3$ . However,  $T_3$  is more potent and acts more rapidly than  $T_4$ .
- The morphological appearance of thyroid follicles varies in different regions of the gland depending on the needs of the body. In the same gland, active as well as resting follicles are seen. The difference between these two types is presented in Table 17.2.
- The secretory activity of the follicular cells is controlled by TSH of adenohypophysis.
- In addition to follicular cells, the thyroid gland contains *parafollicular cells* or clear cells or C cells.
- These cells are large pale staining cells with granular cytoplasm and are found either singly or in small groups within a follicle or between the follicles in the interfollicular space. Those found within the follicular epithelium never reach the follicular lumen.

**Table 17.2** Differences between resting and active follicles

Resting follicle	Active follicle
	
<ul style="list-style-type: none"> <li>• Follicles are large.</li> <li>• Lined by squamous epithelium with few microvilli on the luminal surface.</li> <li>• Nucleus of epithelial cell is dark.</li> <li>• Large amount of acidophilic colloid in the lumen.</li> </ul>	<ul style="list-style-type: none"> <li>• Follicles are small.</li> <li>• Lined by cuboidal to low columnar epithelium with more microvilli.</li> <li>• Nucleus of epithelial cell is pale.</li> <li>• Little amount of colloid with scalloped border.</li> </ul>

- The parafollicular cells synthesise and secrete the hormone, *calcitonin* which is an antagonist of parathormone. Calcitonin lowers blood calcium level by inhibiting bone resorption.
- Calcitonin is secreted in response to blood calcium level and is not dependent on pituitary or parathyroid hormones.

## SYNTHESIS AND SECRETION OF THYROID HORMONES

- Synthesis and secretion of thyroid hormones by follicular cells involves the following steps:
  1. Synthesis of thyroglobulin (a glycoprotein) which is stored in the follicular cavity, as colloid.
  2. Uptake of circulating iodide.
  3. Oxidation of iodide into iodine, which passes into follicular cavity.
  4. Iodination of tyrosine residues of colloid in the cavity.
  5. Uptake and hydrolysis of thyroglobulin by follicular cells to  $T_3$  and  $T_4$ .
  6. Liberation of  $T_3$  and  $T_4$  into the blood stream. (For details, refer to a textbook of Biochemistry.)

## EFFECT OF THYROID HORMONES

- Thyroid hormones increase the metabolic activity of most cells of the body, increasing oxygen consumption and heat production. Thus, they increase the basal metabolic rate.
- Thyroid hormones influence the growth and tissue differentiation of nervous system.
- They are also essential for growth and development of reproductive and musculoskeletal systems.
- They are involved in protein, carbohydrate and lipid metabolism:
  - *Protein metabolism*
    - promotes protein synthesis
  - *Carbohydrate metabolism*
    - increases absorption of glucose from intestine
    - stimulates breakdown of glycogen into glucose in the liver, heart and skeletal muscle
  - *Lipid metabolism*
    - increases mobilization of lipids from adipose tissue and stimulates oxidation of free fatty acids
    - reduces plasma cholesterol level.

Enlargement of thyroid gland due to deficiency of iodine in diet leads to **iodine deficiency goitre**, in which the synthesis of thyroid hormones is reduced (**hypothyroidism**). Reduced levels of thyroid hormone stimulate the production of TSH, which in turn causes enlargement of thyroid gland. **Hypothyroidism** in children causes **cretinism** and in adults **myxoedema**.

One of the causes of **hyperthyroidism** (thyrotoxicosis) is **Grave's disease** (exophthalmic goitre) which is more common in females. It involves enlargement of thyroid gland (diffused hyperplasia) and increased production of thyroid hormone. This thyroid hyperfunction is due to formation of an autoantibody called **long acting thyroid stimulator (LATS)**, which mimics TSH and constantly stimulates the thyroid to secrete excess hormone. Hyperthyroid patients present raised BMR, heat intolerance, hyperexia, tachycardia, weight loss, weakness, insomnia, tremor, etc., besides exophthalmos (bulging of eyes) and goitre in Grave's disease. (For details refer to a textbook of Physiology.)

## PARATHYROID

### GENERAL FEATURES

- There are two pairs of parathyroid glands present in man and are identified by their location as superior and inferior parathyroids.
- They are small oval structures, yellowish brown in colour, situated on the posterior surface of the thyroid gland, but are separated from it by a thin connective tissue capsule. (Sometimes they are embedded in the thyroid gland.)
- Parathyroids are essential for life as they are involved in regulation of calcium and phosphate levels in blood. Therefore, care is taken to avoid removal of parathyroids during thyroidectomy. In the event of their removal, blood calcium level falls resulting in tetanic contraction of respiratory and laryngeal muscles leading to death.

### DEVELOPMENT

- Parathyroid glands are derived from endoderm of the pharyngeal pouches. The superior parathyroids are derived from the fourth pharyngeal pouch and the inferior from the third pouch along with thymus.

### STRUCTURE

- A thin connective tissue capsule surrounds the glands and it sends septae into the interior where they merge with reticular fibres that support the parenchyma.
- The parenchyma is made of secretory endocrine cells which are arranged in clusters or anastomosing cords between sinusoidal capillaries. The cells are of two types, namely, chief or principal cells and oxyphil cells.
- *Chief cells* are smaller and more numerous than oxyphil cells. They are polygonal in shape with round vesicular nucleus and pale staining granular cytoplasm. These cells are involved in synthesis and secretion of parathyroid hormone or parathormone (PTH), which increases calcium and decreases phosphate levels in blood.
- *Oxyphil cells* are larger and less numerous than chief cells. They are polygonal in shape with dark nucleus and highly acidophilic cytoplasm. The oxyphil cells do not appear until puberty and their number increases with age. The function of these cells is not known (Fig. 17.5; Box 17.3).
- As age advances the gland is infiltrated with adipose tissue. Adipocytes constitute more than 50% of the parenchyma in the aged.
- The secretion of parathormone is controlled by blood calcium level and not by pituitary hormone. PTH increases blood calcium level in the following three ways:
  1. Stimulates the osteoclasts to increase the rate of bone resorption, promoting liberation of calcium from bone matrix.
  2. Influences the distal convoluted tubules of kidney to increase tubular reabsorption of calcium ions from the glomerular filtrate.

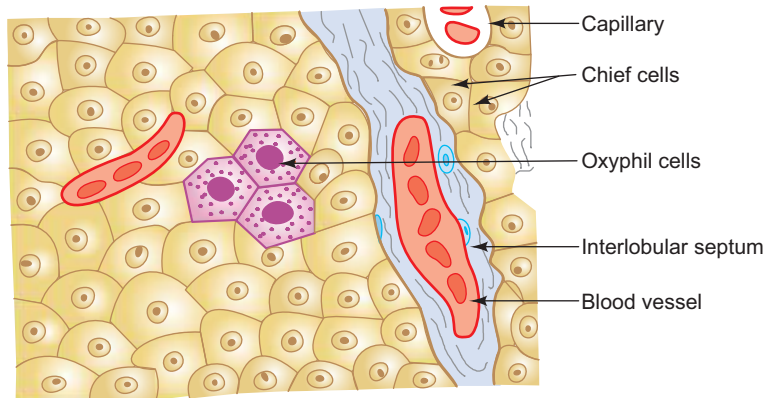
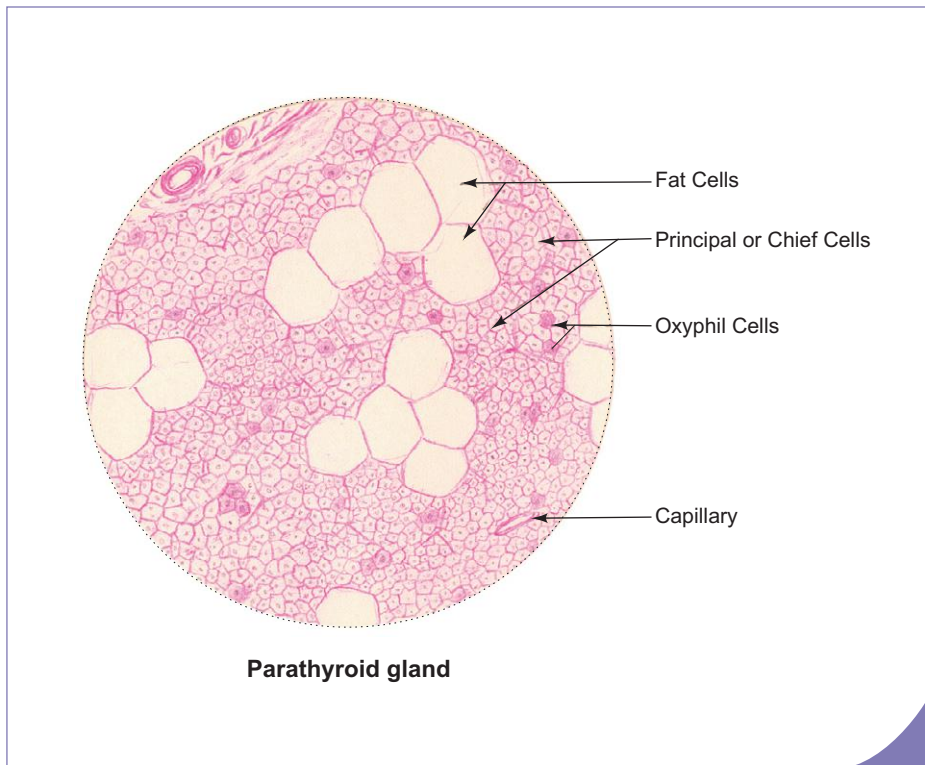


Fig. 17.5 Structure of parathyroid gland.



### Box 17.3 Parathyroid Gland.

Presence of

- (i) small basophilic **chief cells** in large number;
- (ii) large eosinophilic **oxyphil cells** in small number.

3. Stimulates the synthesis of calcitriol which is the active form of vitamin D. The latter increases absorption of calcium from small intestine.

**Hyperparathyroidism** is a condition in which the parathyroids produce excessive parathormone, unresponsive to normal feedback mechanism. This leads to increase in blood calcium level (hypercalcaemia) and subsequent deposition of calcium in several organs such as kidneys and arteries. Because of depletion of calcium from bone in these patients, the bones become weak and are prone to fracture, a condition called **osteitis fibrosa cystica**.

**Hypoparathyroidism** is rare and is due to inadvertent surgical removal of parathyroid glands during total thyroidectomy, which results in decreased concentration of blood calcium. In these cases the bone becomes denser and more mineralised and muscles undergo convulsions called **tetany**.

## ADRENAL (SUPRARENAL)

### GENERAL FEATURES

- Adrenal glands are a pair of flattened structures situated on the upper pole of kidneys. The right one is triangular and the left is crescentic in shape. Each is 4–6 cm long, 2–4 cm wide and 1–2 cm thick.
- The weight of the gland depends on age and physiological state of the individual (weighs approximately 5–8 g).
- Each gland consists of a yellow peripheral region, the *cortex* (90% of total weight) and a brown central region, the *medulla*.
- The cortex produces *steroid* hormones and the medulla produces *catecholamines*—*epinephrine* and *norepinephrine*.

### DEVELOPMENT

- The adrenal cortex and medulla are structurally, functionally and developmentally distinct organs that become united during development.
- The cortex arises from *mesoderm* along with gonads, while the medulla arises from *neural crest* along with the sympathetic system. In fact, the cells of the medulla are considered to be *modified postganglionic sympathetic neurons* which lose their processes and become secretory cells.

### Blood Supply

- Each suprarenal gland is supplied by three arteries derived from three different sources, *viz.*,
  1. Superior suprarenal artery—from inferior phrenic artery.
  2. Middle suprarenal artery—from abdominal aorta.
  3. Inferior suprarenal artery—from renal artery.

The above arteries divide and form a subcapsular plexus beneath the capsule. From the subcapsular plexus the parenchyma of the gland is supplied with the following two sets of vessels:

  1. Arteries of the cortex—form capillary network among the parenchymal cells of the cortex and finally drain into the medullary capillaries.
  2. Arteries of the medulla—pass through the cortex and form capillary network in the medulla among its parenchymal cells.
- The cells of the medulla are, thus, bathed in both arterial blood from the medullary arteries and venous blood, rich in corticosteroids, originating from the capillaries of the cortex. This vascular arrangement is believed to have an important influence on the synthesis of catecholamines by the medulla.
- The medullary capillaries join to form a central vein of the medulla which leaves the organ as suprarenal vein which drains into inferior vena cava on the right side and left renal vein on the left side.

### STRUCTURE

#### Adrenal Cortex (Box 17.4)

- Adrenal cortex consists of three histological zones, namely, zona glomerulosa, zona fasciculata and zona reticularis from superficial to deep.
- The cells of the cortex show characteristic features of steroid synthesizing cells, i.e. they have lipid droplets, many mitochondria with long tubular cristae and smooth endoplasmic reticulum. Enzymes necessary for synthesis of steroid hormones are found in mitochondria and smooth endoplasmic reticulum.
- These secretory cells do not store their secretory products in granules. They synthesise and secrete hormones only on demand. The release of the hormone is by diffusion through plasma membrane and not by exocytosis.
- The secretory activity of the cortex, in general, is controlled by ACTH.

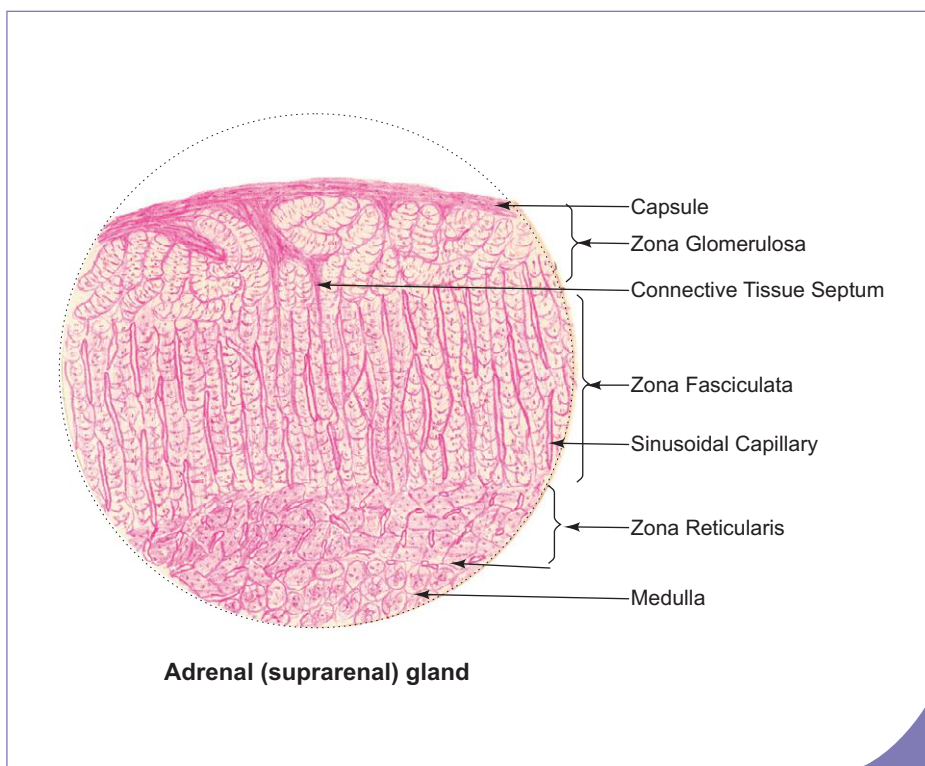
## Characteristics of Zones of Adrenal Cortex (Fig. 17.4)

### Zona glomerulosa

- It forms the outermost zone beneath the capsule.
- This zone constitutes 15% of the total volume.
- It is formed by rounded or arched clusters of columnar or pyramidal cells. They have acidophilic cytoplasm with few lipid droplets.
- Fenestrated capillaries are found among the clusters of cells.
- It secretes *mineralocorticoids*, primarily *aldosterone*, which is involved in maintenance of electrolyte and water balance by stimulating the reabsorption of sodium in DCT of kidney, striated duct of salivary gland, sweat gland and gastric mucosa.
- The main factor controlling secretion of aldosterone is the renin–angiotensin system and not ACTH. However, ACTH is necessary for normal maintenance and structural integrity of the glomerulosa cells.

### Zona fasciculata

- It forms the intermediate zone.
- It constitutes 65% of the total volume.
- Zona fasciculata is formed by straight parallel cords of polyhedral cells (1 or 2 cells thick). They have pale-staining cytoplasm with many lipid droplets. These lipid droplets give a vacuolated or spongy appearance to the cytoplasm. For this reason these cells are called *spongiocytes*.
- Fenestrated capillaries are found between the cords of cells.
- It secretes *glucocorticoids*, mainly *cortisol* and small amount of corticosterone and cortisone.
- Glucocorticoids are concerned with the regulation of carbohydrate, protein and fat metabolism:
  - synthesise glucose in liver (gluconeogenesis),
  - stimulate breakdown of lipid into free fatty acid, and
  - inhibit protein synthesis.
- Glucocorticoids suppress the immune response by decreasing the number of circulating eosinophils and lymphocytes.



### Box 17.4 Adrenal Gland.

Presence of

- |   |                  |
|---|------------------|
| (i) <b>zona glomerulosa</b>   | } in the cortex; |
| (ii) <b>zona fasciculata</b>  |                  |
| (iii) <b>zona reticularis</b>   |                  |
| (iv) <b>chromaffin cells</b> and sympathetic ganglion cells in the medulla. |                  |



### Zona reticularis

- This zone forms the innermost layer of the cortex.
- It occupies 5–10% of the total volume.
- Zona reticularis is composed of small irregular anastomosing cords of cells. The cells are smaller and more acidophilic than those of the other two layers. The cytoplasm contains elongated mitochondria, glycogen, lipofuscin pigments and few lipid droplets.
- It secretes small amount of androgen [dehydroepiandrosterone (DHEA)] and glucocorticoids.

### Adrenal Medulla (Fig. 17.6; Box 17.4)

- It is composed of clumps or cords of *chromaffin cells* (phaeochromocyt) which are polyhedral in shape with fenestrated capillaries in between them. Cells are supported by fine reticular fibres. Apart from chromaffin cells few *parasympathetic ganglion cells* are also present.
- Chromaffin cells are regarded as *modified sympathetic postganglionic neurons* which lose their axons and dendrites to become secretory cells. They are derived from neural crest. They can be stained with chromium salts. With this stain catecholamines are oxidized to a brown compound, a process known as *chromaffin reaction*.
- Chromaffin cells are innervated by cholinergic endings of preganglionic sympathetic neurons. Thus, medulla is under neuronal control whereas cortex is under ACTH control. Another contrasting feature is that the cells of medulla accumulate and store their secretory products in granules, whereas the cells of cortex do not store their hormones in granules.
- The secretory granules, contain catecholamines, namely, epinephrine (adrenaline) and norepinephrine (noradrenaline).
- Recent evidences suggest that epinephrine and norepinephrine are secreted by two different types of cells. Epinephrine secreting cells have small less electron dense granules, whereas norepinephrine secreting cells have large more electron dense granules.

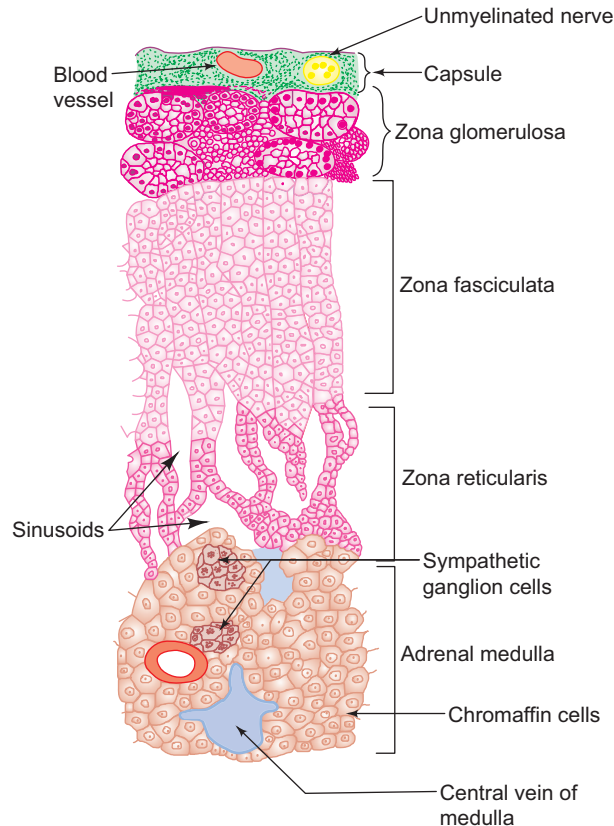
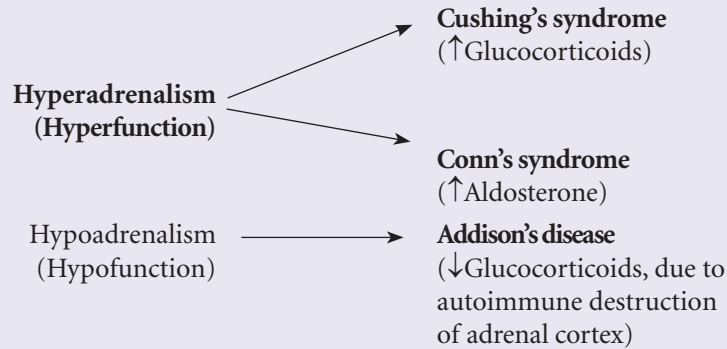


Fig. 17.6 Structure of adrenal gland.

Various disorders of adrenal cortex are a result of either hyperfunction or hypofunction of the cortex.



In response to emotional reaction such as fright, fight or flight response, adrenal medulla secretes large amount of catecholamine which causes vasoconstriction, hypertension, increase in heart rate and elevation of blood glucose level. Tumours of adrenal medulla (**pheochromocytoma**) cause transient elevation of blood pressure.

## PINEAL BODY (EPIPHYSIS)

### GENERAL FEATURES

- Pineal body is a small flattened conical glandular organ situated in the posterior end of the roof of the third ventricle below the splenium of corpus callosum. In lower vertebrates, it lies on the skin surface functioning as the *third eye* (photoreceptor).
- It is connected to the diencephalon by a stalk that contains posterior commissure.
- It is covered by pia mater which forms the capsule. The capsule sends trabeculae carrying blood capillaries and unmyelinated postganglionic sympathetic fibres derived from superior cervical ganglion.
- Pineal body synthesises and secretes the hormone *melatonin* which acts as an endocrine transducer, inducing rhythmic changes in the endocrine activity of the hypothalamus, pituitary and gonads in response to changes in photoperiod. Secretion of melatonin is induced by darkness and inhibited by light.

### STRUCTURE

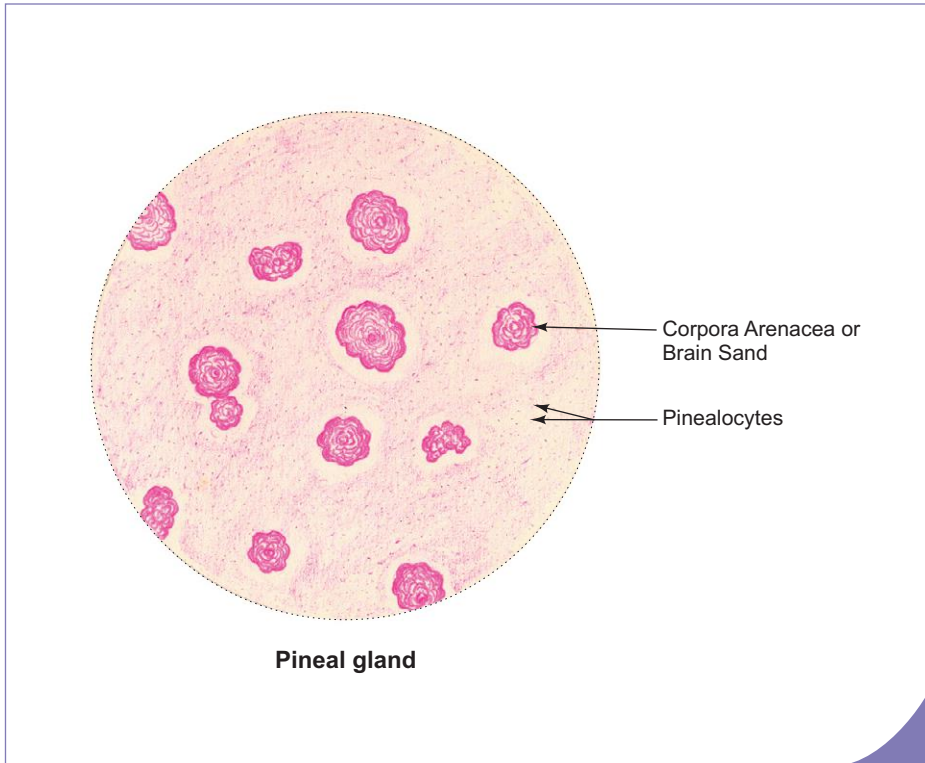
- Pineal body is made of two types of cells. They are pinealocytes and astroglial cells or interstitial cells. These cells are arranged in the form of cords and clusters among capillaries.
- In addition, it contains *brain sands* (*corpora arenacea*) which are basophilic bodies found extracellularly in the matrix. They are composed of concentric layers of calcium and magnesium phosphate. Their number increase with age. They serve as a landmark for radiologist in the X-ray of skull.
- *Pinealocytes* are the main cell type forming 95% of the cell population. They are modified neurons characterised by large irregular nuclei and prominent nucleoli (Box 17.5). They have long tortuous cytoplasmic processes ending in relation to blood vessels as swellings. These swellings store granules containing melatonin and its precursor serotonin.
- *Astroglial cells* are neuroglial cells characterised by dark elongated nuclei. They have long cytoplasmic processes that support pinealocytes and blood vessels.

### FUNCTIONS

- The role of pineal as an endocrine gland is poorly understood. Animal studies reveal that it secretes many neurotransmitters, e.g. melatonin, serotonin and norepinephrine. Of these only melatonin is shown to be released into blood and can be considered as a true hormone. It may also secrete a trophic hormone which regulates the secretion of aldosterone from adrenal cortex.

**Box 17.5 Pineal Gland.***Presence of*

- (i) lamellated basophilic bodies, the **brain sand** or **corpora arenacea**;
- (ii) **pinealocytes** with irregular nuclei.



- The quantity of melatonin released differs according to changes of light and dark periods (diurnal and circadian rhythms). The concentration of melatonin in blood is highest during darkness and lowest during day.
- Melatonin may inhibit gonadotrophin release until puberty preventing the onset of precocious gonadal function (precocious puberty). In lower vertebrates, melatonin is responsible for changing skin colour.

# Self-assessment Exercise

## I. Write short notes on the microscopic structure of:

- (a) Pituitary
- (b) Thyroid
- (c) Parathyroid
- (d) Adrenal cortex
- (e) Adrenal medulla

## II. Fill in the blanks:

1. Oxytocin and vasopressin are stored in the neurohypophysis as \_\_\_\_\_
2. The cells involved in secretion of parathormone are called \_\_\_\_\_
3. Inferior parathyroid is developed from \_\_\_\_\_
4. Zona glomerulosa of adrenal cortex secretes \_\_\_\_\_
5. Adrenal medulla is derived from \_\_\_\_\_
6. Adrenal medulla is composed primarily of \_\_\_\_\_ cells.
7. Adrenal medulla secretes \_\_\_\_\_ and \_\_\_\_\_
8. \_\_\_\_\_ are the calcified lamellated bodies present in the pineal gland.
9. In lower vertebrates pineal gland lies on the skin surface and is known as \_\_\_\_\_

## III. Choose the best answer:

1. Adenohypophysis is derived from
  - (a) neural ectoderm
  - (b) oral ectoderm
  - (c) mesoderm
  - (d) endoderm
2. Pars intermedia lies between
  - (a) hypophyseal cleft and pars nervosa
  - (b) hypophyseal cleft and pars distalis
  - (c) pars distalis and pars tuberalis
  - (d) pars tuberalis and pars nervosa
3. The hormones involved in breast development and lactation are
  - (a) FSH and LH
  - (b) GH and TSH
  - (c) prolactin and oxytocin
  - (d) vasopressin and aldosterone
4. Thyroid gland differs from other endocrine glands in
  - (a) having anastomosing cords of cells
  - (b) having less vasculature
  - (c) storing the secretion intracellularly
  - (d) storing the secretion extracellularly

5. Which of the following is *not true* about the parafollicular cells? They
- secrete calcitonin
  - are also called C or clear cells
  - contain secretory granules in the cytoplasm
  - are dependent on pituitary hormone for their secretion

**IV. State whether the following statements are true (T) or false (F):**

- Hypothalamo-hypophyseal portal system helps to transport the regulatory hormones of hypothalamus to pars distalis ( )
- Chromophobes contain many secretory granules in the cytoplasm ( )
- Basophils can be stained with periodic acid Schiff reagent ( )
- The active thyroid follicles are lined by simple squamous epithelium ( )
- Triiodothyronine ( $T_3$ ) is more potent than thyroxine ( $T_4$ ) ( )
- Calcitonin antagonises parathormone and lowers blood calcium level ( )
- Superior parathyroid is developed from second pharyngeal pouch ( )
- Cells of zona fasciculata contain more lipid droplets than glomerulosa cells ( )
- Chromaffin cells of adrenal medulla are modified postganglionic parasympathetic neurons ( )
- Adrenal medulla is not under the control of ACTH ( )

**V. Match the items in column 'A' with those of column 'B':**

Column 'A'		Column 'B'	
A.	<i>Clinical condition</i>		<i>Causative factor</i>
1.	Cushing's syndrome ( )	(a)	Excessive secretion of GH
2.	Acromegaly ( )	(b)	Excessive secretion of aldosterone
3.	Diabetes insipidus ( )	(c)	Excessive secretion of glucocorticoids
4.	Conn's syndrome ( )	(d)	Insufficient secretion of glucocorticoids
5.	Addison's disease ( )	(e)	Insufficient secretion of ADH
B.	<i>Cells/Structures</i>		<i>Hormone</i>
1.	Lactotrophs ( )	(a)	Aldosterone
2.	Parafollicular cells ( )	(b)	Prolactin
3.	Paraventricular nucleus ( )	(c)	Calcitonin
4.	Zona glomerulosa ( )	(d)	Melatonin
5.	Pinealocytes ( )	(e)	Oxytocin

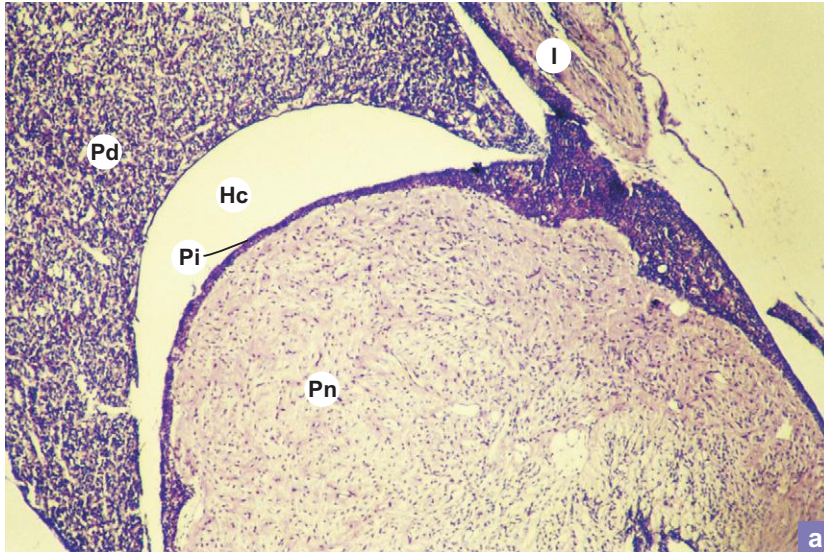
**Answers**

- II.** 1. Herring bodies                      2. Chief cells                      3. Third pharyngeal pouch  
 4. Mineralocorticoids/Aldosterone      5. Neural crest cells              6. Chromaffin  
 7. Epinephrine and norepinephrine      8. Corpora arenacea              9. Third eye
- III.** 1. b    2. a    3. c    4. d    5. d
- IV.** 1. (T)    2. (F)    3. (T)    4. (F)    5. (T)    6. (T)    7. (F)    8. (T)    9. (F)    10. (T)
- V.** A. 1. c    2. a    3. e    4. b    5. d  
 B. 1. b    2. c    3. e    4. a    5. d

# Practical No. 17

## Endocrine Glands

X40

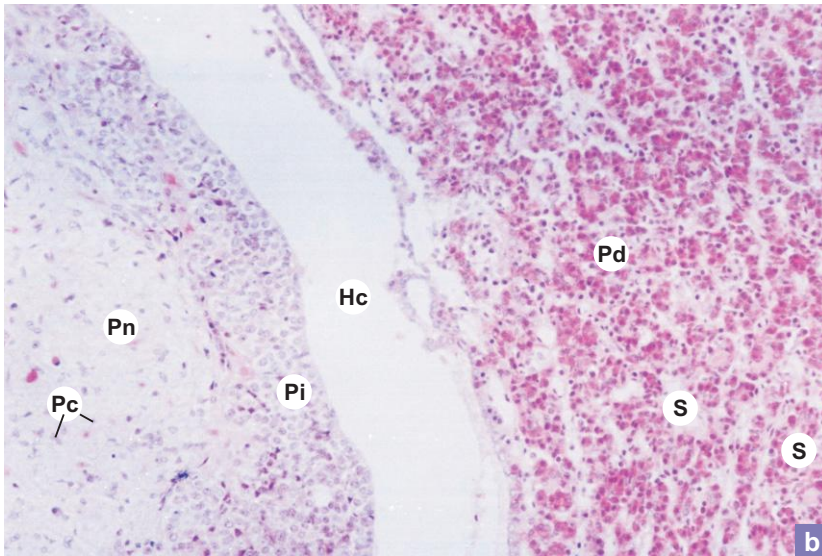


### Plate 17:1a Pituitary.

Identify the various parts of the pituitary at low magnification (Plate 17:1a):

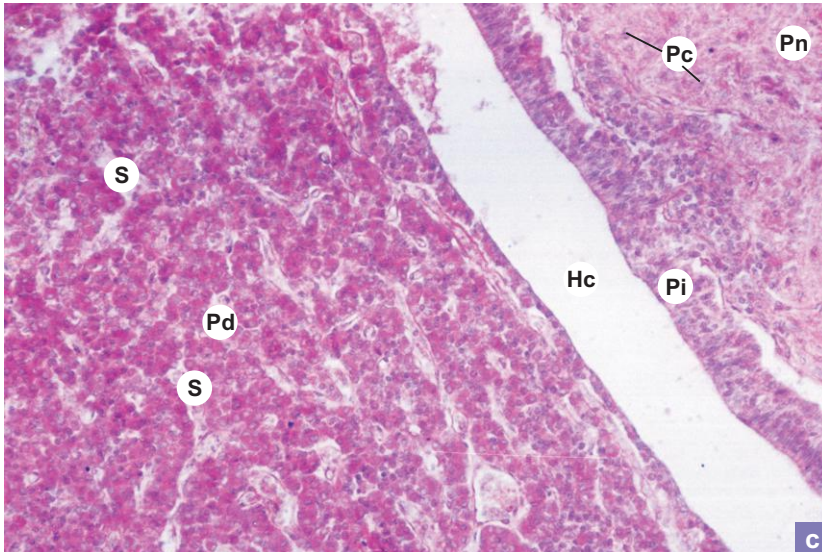
- Pars distalis (**Pd**).
- Pars intermedia (**Pi**).
- Pars nervosa (**Pn**).
- Infundibular stalk (**I**).
- Hypophyseal cleft (**Hc**).

X100



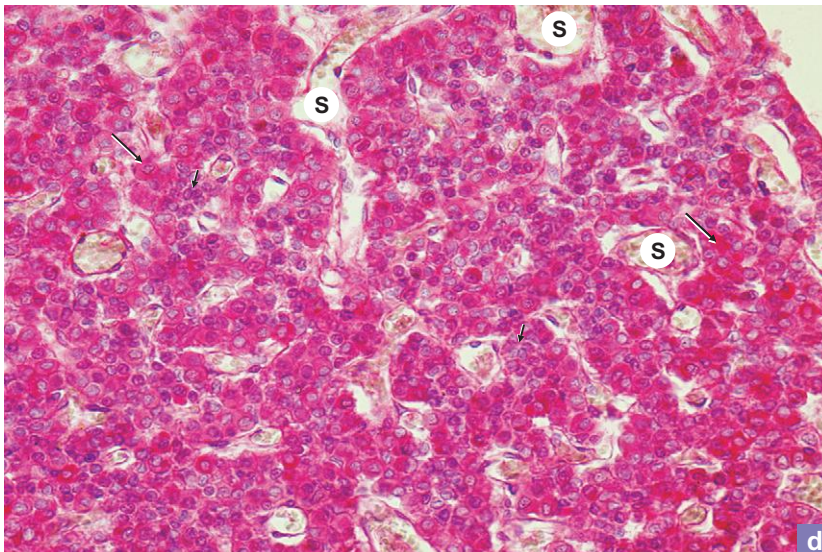
b

X100



c

X200



d

**Plate 17:1  
b and c**
**Pituitary.**

At a still higher magnification (Plate 17:1b and c) the arrangement and composition of cells can be made out.

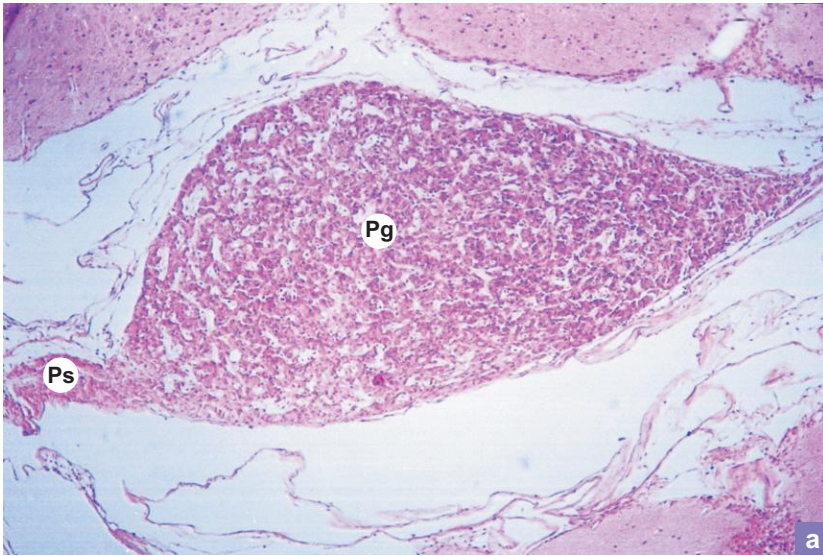
- In the pars distalis (**Pd**), the chromophobes (light cells) and chromophils (dark cells) are arranged as cords or clusters in between the sinusoidal capillaries (**S**).
- In pars intermedia (**Pi**), colloid filled cysts or follicles may be seen. Pars intermedia is separated from pars distalis by the hypophyseal cleft (**Hc**).
- Pars nervosa (**Pn**) is made of unmyelinated axons arising from hypothalamic nuclei, supported by pituicytes (**Pc**).

**Plate 17:1d**
**Pituitary.: Pars distalis.**

Examine the pars distalis under high power (Plate 17.1d).

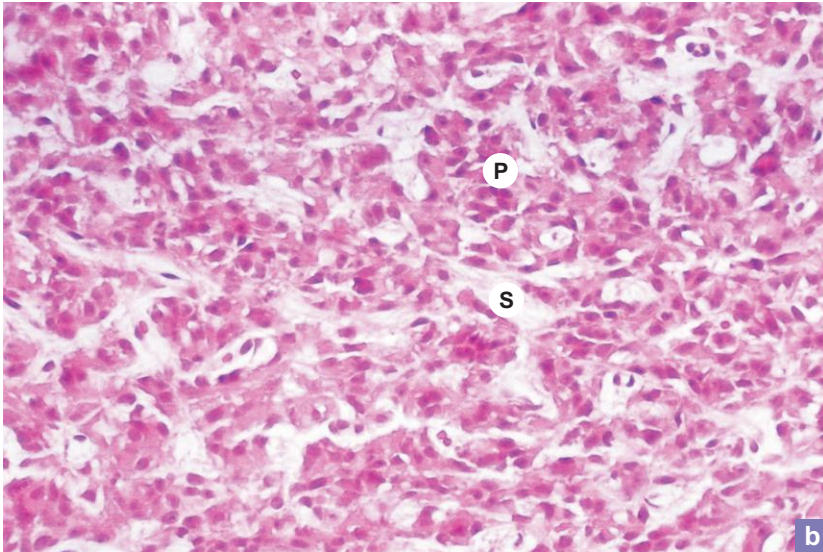
- Identify the lightly stained chromophobes (**arrow heads**) and darkly stained chromophils (**arrow**). They are arranged as cords or clusters.
- Note the large number of sinusoidal capillaries (**S**) with traces of blood elements among the clusters of cells.

X40

**Plate 17:2** Pineal gland.  
**a and b**

At low magnification (Plate 17:2a), note the club-shaped pineal gland (**Pg**) attached to the thalamus by pineal stalk (**Ps**).

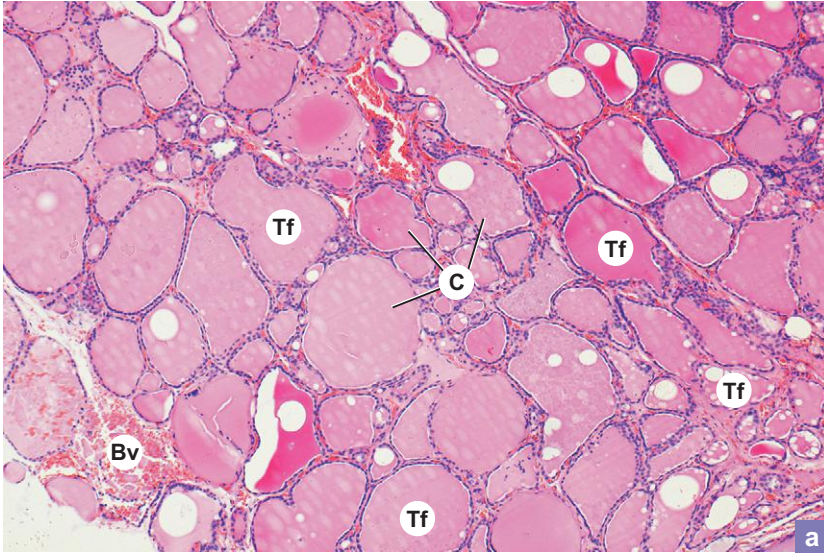
X200



At higher magnification (Plate 17:2b), note the pinealocytes (**P**), arranged around the sinusoids (**S**).



X100



**Plate 17:3** Thyroid gland.  
a and b

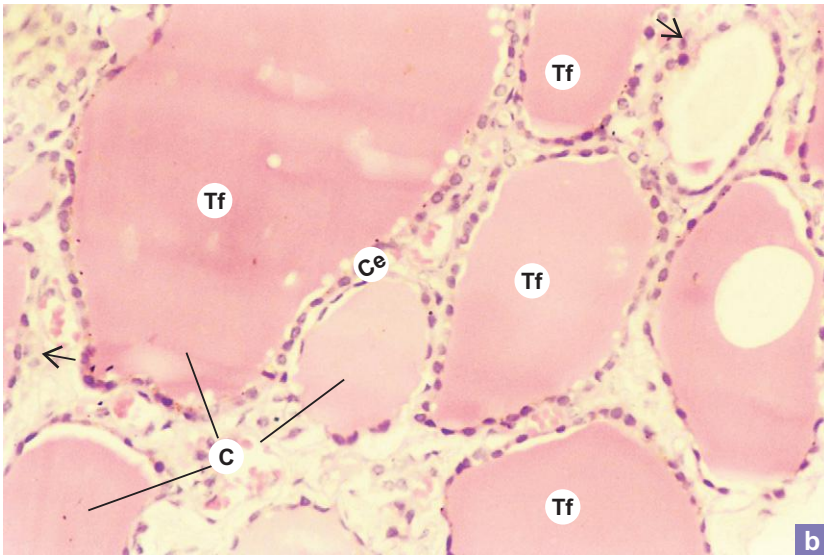
Examine a section of thyroid gland at low and high magnifications (Plate 17:3a and b).

Thyroid follicles (**Tf**) are embedded in vascular stroma. The follicles are lined by simple cuboidal epithelium (**Ce**). Thyroglobulin is stored in the lumen as colloid (**C**).

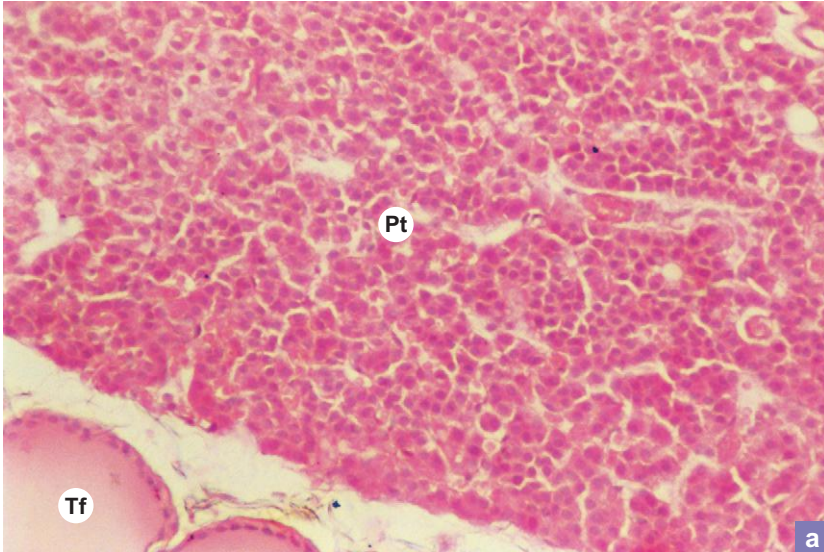
In the same section, active as well as resting follicles can be seen side by side (not seen in present section). The differences between these two types of follicles are given in the text.

**Arrows** = parafollicular cell.

X200



X100



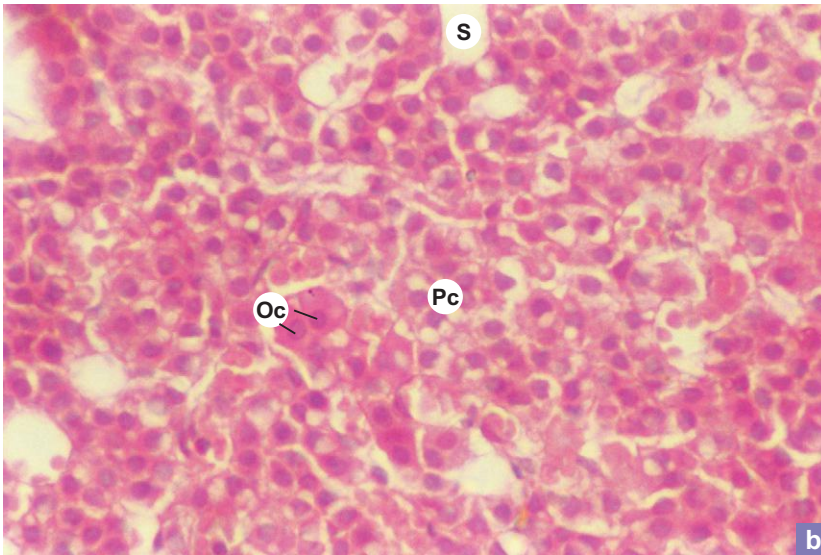
a

**Plate 17:4  
a and b Parathyroid.**

Plate 17:4a illustrates parathyroid (Pt) surrounded by thyroid follicles (Tf).

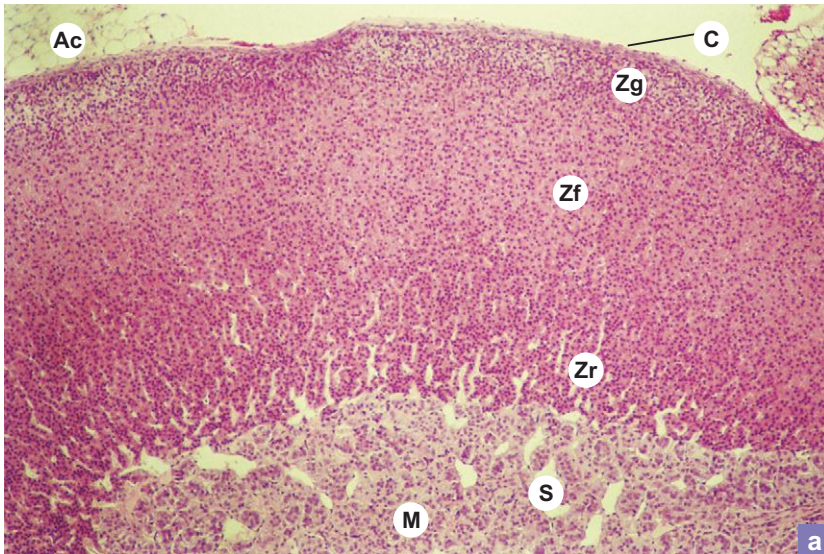
At high magnification (Plate 17:4b) the lightly stained chief or principal cells (Pc) and large acidophilic oxyphil cells (Oc) can be identified. These cells are arranged in clusters or anastomosing cords between sinusoidal capillaries (S).

X200



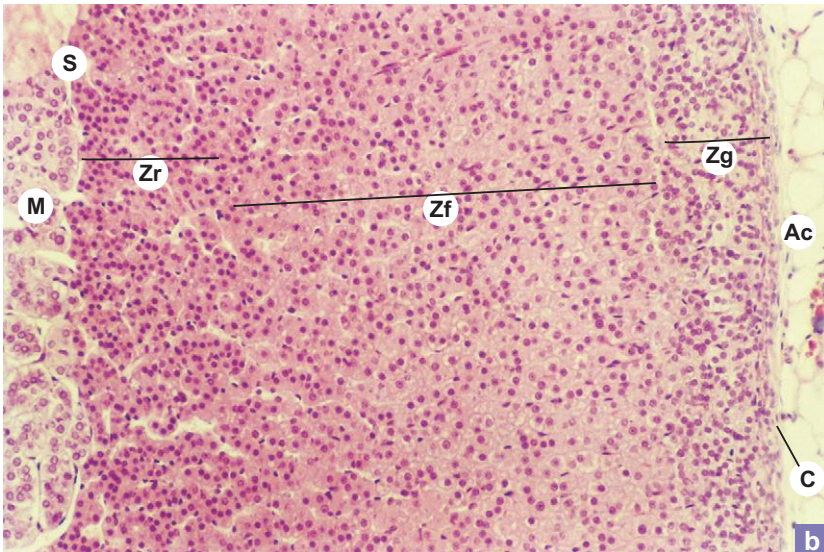
b

X40



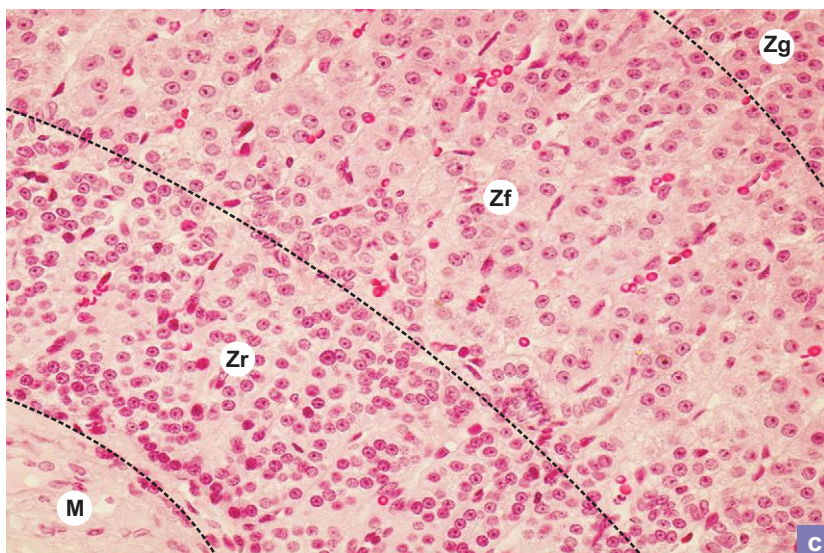
a

X100



b

X400



c

**Plate 17:5**    **Suprarenal.**  
**a, b and c**

Section of suprarenal (Plate 17:5a and b) shows a peripheral cortex (darkly stained) and a central medulla (lightly stained). In the cortex, identify the following three zones:

*Zona glomerulosa (Zg)* – columnar cells are arranged in the form of rounded clusters.

*Zona fasciculata (Zf)* – polyhedral cells are arranged in the form of fascicles or columns.

*Zona reticularis (Zr)* – small dark acidophilic cells are arranged in the form of anastomosing cords.

*Medulla (M)* is composed of clumps of large polyhedral cells called chromaffin cells.

S = sinusoid; C = capsule; AC = Adipocyte.

At high magnification (Plate 17:5c) the arrangement and composition of cells of the zones (as stated above) can be well appreciated.

Zg – zona glomerulosa; Zf – zone fasciculata; Zr – zona reticularis; M – medulla.

Note the crowding of nuclei in the zona reticularis, as there cells are smaller in size.

# 18

## SPECIAL SENSES

### INTRODUCTION

Information about the external environment is conveyed to the central nervous system through sense organs (general and special). General sense organs concerned with pain, temperature, touch and pressure are situated in the skin (refer to chapter 11). Special sense organs, e.g. *olfactory mucosa* (smell) and *taste buds* (taste) have already been described under respiratory and digestive systems respectively. The remaining special sense organs, e.g. *eye* (vision) and *ear*, (hearing and equilibrium) are described in this chapter.

### EYE

#### GENERAL FEATURES

- The eyeball is the peripheral organ of vision.
- It is spherical in shape and is lodged in a bony cavity, the *orbit*.
- Certain accessory structures are intimately associated with the eyeball, namely, the extraocular muscles to move the eyeball, the eyelids to protect it in front and the lacrimal gland to lubricate the cornea.

### STRUCTURE

#### Coats of the Eyeball (Box 18.1)

- The wall of the eyeball has three concentric coats which enclose three compartments, namely, anterior, posterior and vitreous chambers (Fig. 18.1). These chambers contain fluid media of eye. The three coats are:
  1. Outer fibrous coat/Sclerocorneal layer
  2. Middle vascular coat/Uveal tract
  3. Inner photosensitive coat/Retina

#### Outer Fibrous Coat/Sclerocorneal Layer

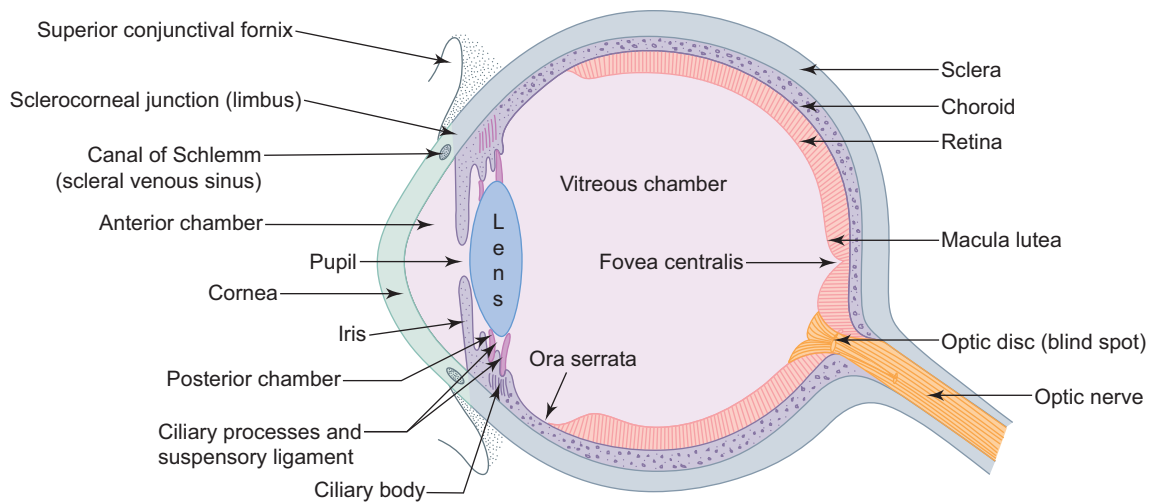
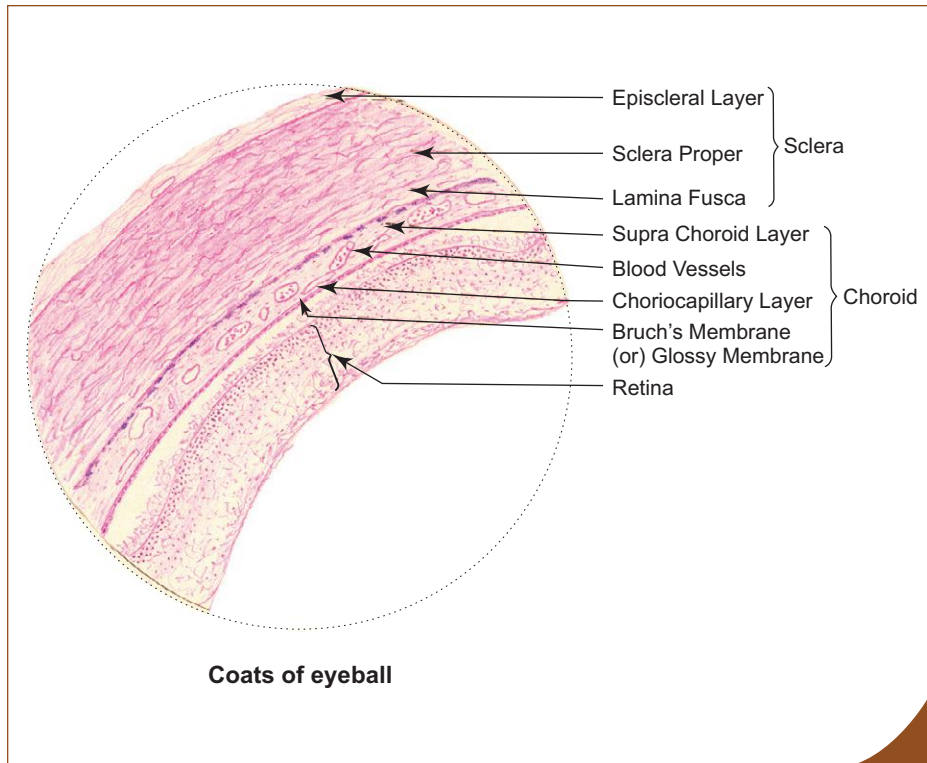
- This coat consists of the opaque posterior four-fifth, the *sclera* and the anterior transparent one-fifth, the *cornea*.
- The sclera and cornea become continuous with each other at the *limbus* or the *sclerocorneal junction*.

#### Sclera

- It is composed mostly of dense collagen fibres and few elastic fibres.
- Sclera is separated externally from *Tenon's capsule* (fascial sheath of eyeball) by *episcleral layer* of loose connective tissue (*Tenon's space*) and internally from the choroid by *lamina fusca* (suprachoroidal lamina) of dark pigmented fibroelastic tissue.
- Posteriorly it is pierced by axons of ganglionic cells of retina at *lamina cribrosa* to form optic nerve.

**Box 18.1** Coats of Eyeball.*Presence of*

- (i) sclera – composed of collagen fibres;
- (ii) choroid – composed of blood vessels and pigment cells;
- (iii) retina – composed of pigment epithelium and nervous layer.

**Fig. 18.1** Horizontal section of eyeball.**Cornea**

- It is a colourless transparent anterior one-fifth of the outer coat.
- It becomes continuous with the posterior opaque sclera at the limbus.
- Cornea is thinner at the centre (0.7 mm) and thicker at the periphery (1.1 mm).
- It is an avascular structure. This is mainly responsible for maintaining its transparency.
- Cornea is nourished by diffusion from aqueous humour of the anterior chamber.
- The refractive power of cornea is greater than that of the lens.

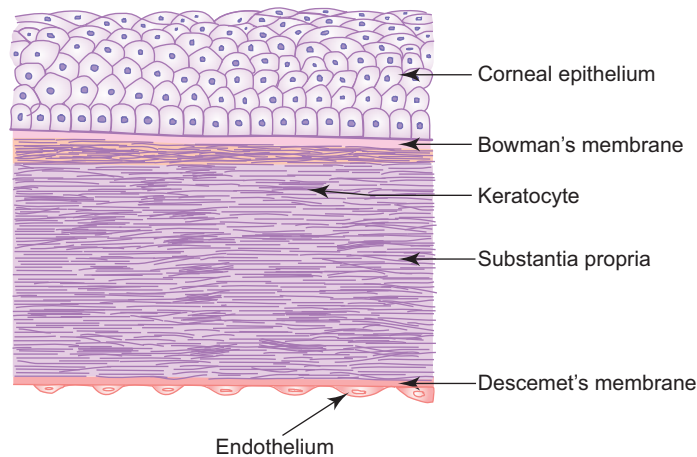
- Cornea is composed of the following five layers (Fig. 18.2; Box 18.2):

### 1. Corneal epithelium

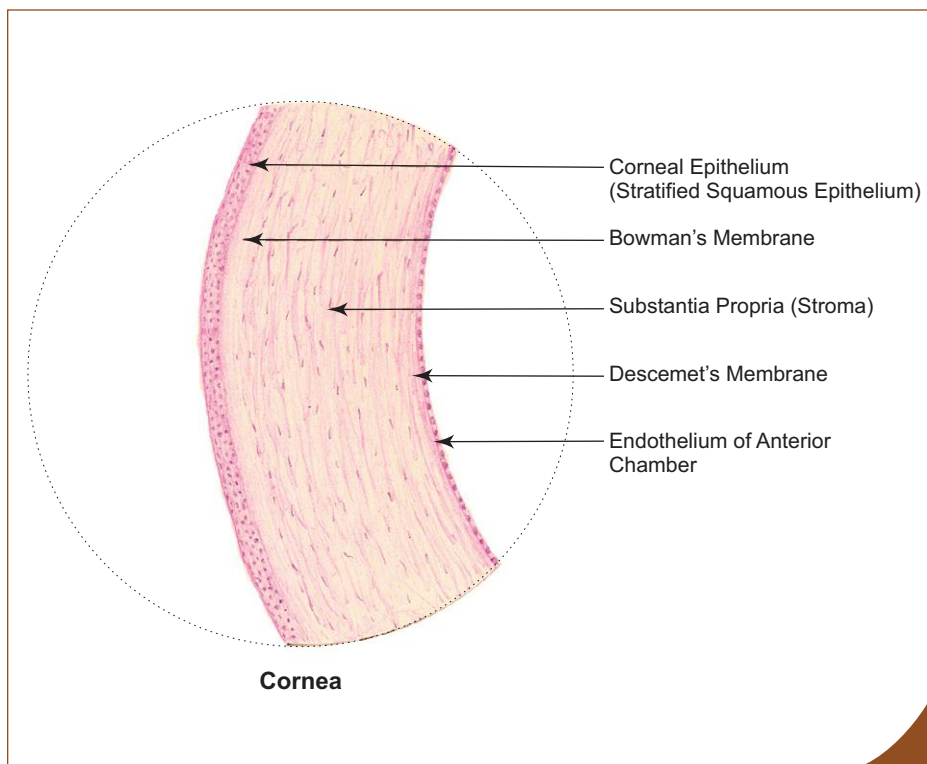
- It is made of stratified squamous nonkeratinized epithelium (5 or 6 layers).
- Superficial cells show microvilli that retain a thin film of tears on the surface of the cornea to keep it moist.
- The epithelium shows remarkable capability of regeneration.
- It has rich sensory nerve supply.
- At the limbus, the corneal epithelium becomes continuous with the epithelium (10–15 layers) of the bulbar conjunctiva.

### 2. Bowman's membrane or anterior limiting membrane (10–12 $\mu\text{m}$ )

- It is a homogeneous acellular layer, lying beneath the corneal epithelium.
- The membrane is made of compactly packed collagen fibrils.
- It gives great stability and strength to cornea.



**Fig. 18.2** Layers of cornea.



### Box 18.2 Cornea.

*Presence of*

- (i) **corneal epithelium (stratified squamous epithelium);**
- (ii) Bowman's membrane;
- (iii) substantia propria;
- (iv) Descemet's membrane;
- (v) endothelium of anterior chamber (simple squamous or cuboidal epithelium).

### 3. Substantia propria or stroma

- This constitutes the bulk of the cornea (90% of its thickness).
- Substantia propria is composed of several layers of collagen fibrils that are arranged in an orderly manner parallel to the surface of the cornea. All the fibrils are of uniform size and are embedded in ground substance rich in chondroitin sulphate and keratosulphate.
- Flattened fibroblasts (keratocytes) are found between the layers.

### 4. Descemet's membrane or posterior limiting membrane (7–10 µm)

- It is a homogeneous acellular layer that separates the substantia propria from endothelium.
- It is made of compactly packed collagen fibrils.
- At the limbus, this layer breaks up into a trabecular meshwork enclosing *spaces of Fontana* at the iridocorneal angle.

### 5. Endothelium

- It is a single layer of squamous or cuboidal cells covering the posterior surface of cornea.
- At the limbus it becomes continuous with the endothelial lining of the spaces of Fontana.

Corneal opacity can be surgically treated by **corneal transplantation (keratoplasty)**. Corneal transplants are not immunologically rejected because of the **avascularity of the cornea**.

## Sclerocorneal Junction/Limbus (Box 18.3)

- The sclerocorneal junction is marked by a shallow depression externally and it is the place where the transparent cornea becomes continuous with the opaque sclera.
- It contains an important circular canal lined by endothelium called *canal of Schlemm* or *scleral venous sinus* concerned with drainage of aqueous humour as this canal is connected externally to the anterior ciliary veins and internally to the anterior chamber through spaces of Fontana at iridocorneal angle. In section, the canal appears as an oval cleft whose inner wall is formed by trabecular meshwork enclosing *spaces of Fontana*.
- Aqueous humour is dialysate of blood. It is a clear watery fluid (similar to CSF in composition) produced by the ciliary epithelium, covering the ciliary processes into the posterior chamber. From there it passes into the anterior chamber via pupil and is continuously reabsorbed (drained) through the canal of Schlemm into the bloodstream. Aqueous humour serves as a medium for exchange of metabolites to and from the avascular lens and cornea. It is also responsible for the intraocular pressure (normal pressure is 20 mmHg).

Normally, the canal of Schlemm contains no blood, as the communication between the canal and the ciliary veins are oblique and flattened preventing the reflux of blood into the sinus. However, under venous congestion blood may pass into the canal.

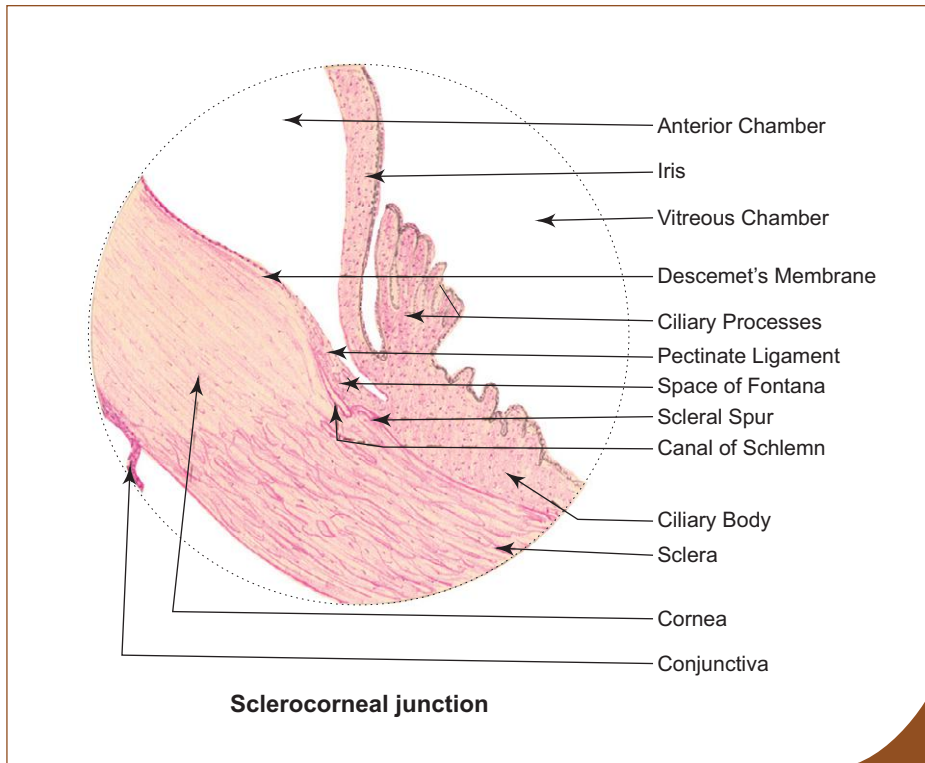
Obstruction to the drainage of aqueous humour leads to sustained increase in the intraocular pressure/tension, causing **glaucoma**. If untreated, this may cause damage to retina resulting in blindness.

## Middle Vascular Pigmented Coat/Uveal Tract

- This is a heavily pigmented vascular coat that absorbs light that has passed through the retina, creating a dark chamber for the eyeball.
- It consists of three parts, namely, choroid, ciliary body and iris.
- The arteries of this layer are derived from branches of ophthalmic artery and are responsible for nourishment of 1st–4th layer of retina.

## Choroid

- Choroid is the posterior part of the middle coat and lies between sclera and retina.
- It is rich in small blood vessels and pigment cells, which give a purple black colour to this coat.



### Box 18.3 Sclerocorneal Junction.

Presence of

- (i) **scleral venous sinus;**
- (ii) **spaces of Fontana** of iridocorneal angle;
- (iii) corneal epithelium becoming ocular conjunctiva.

- It is made of the following layers from superficial to deep:
  1. *Suprachoroidal layer* – loose connective tissue rich in melanocytes.
  2. *Vascular layer* – loose connective tissue rich in melanocytes and medium-sized blood vessels.
  3. *Choriocapillary layer* – capillary network essential for nourishment of retina.
  4. *Bruch's membrane* (glossy membrane) – refractile hyaline layer forming basement membrane of the pigment epithelium of retina.

## Ciliary Body

- The ciliary body is a circumferentially thickened part of the middle coat extending from the ora serrata to the edge of lens. Its anterior part presents radially oriented ridges called *ciliary processes* and they give attachment to the suspensory ligament (zonule) of lens.
- The ciliary body is triangular on cross section. It is mainly formed by *ciliary muscle* (smooth muscle) oriented in longitudinal, circular and radial directions.
- Ciliary muscle is innervated by parasympathetic nerve fibres. When it contracts it pulls the ciliary body forwards resulting in relaxation of suspensory ligament of lens causing the lens to become more convex so that the nearer object is focused on the retina. This muscle is also called *muscle of accommodation*.
- The inner surface of the ciliary body and the ciliary processes are covered by a double layer of epithelial cells, the *ciliary epithelium* responsible for production of aqueous humour.
- Ciliary epithelium, is the forward prolongation of nonsensitive part (*ciliary part*) of retina beyond the ora serrata.
- Of the two layers of ciliary epithelium, the superficial layer is the pigmented cuboidal epithelium and is continuous with the pigment epithelium of retina and the deep layer is the nonpigmented columnar epithelium which is continuous with the nervous layer of retina at the ora serrata. Anteriorly, both layers are pigmented and line the posterior surface of the iris as iridial part of retina.



## Iris

- Iris is the anterior most part of the middle coat. It forms a *pigmented circular diaphragm* placed in front of the lens with an aperture in the centre, the *pupil*. Through the pupil the anterior and posterior chambers communicate.
- The size of the aperture is controlled by two muscles present in it. They are *sphincter pupillae* and *dilator pupillae*, innervated by parasympathetic and sympathetic nerve fibres respectively. Sphincter pupillae (smooth muscle) is circularly arranged near the pupillary margin of the iris and it causes constriction of pupil. Dilator pupillae (myoepithelial cells—derived from posterior pigment epithelium of iris) is radially arranged and causes dilation of pupil.
- The rough anterior surface of iris has no epithelial lining and is covered by a discontinuous layer of pigmented cells and fibroblasts. Its smooth posterior surface is covered by a double layer of pigmented cuboidal epithelium (*iridial part of retina*). The central core is formed by vascular pigmented connective tissue stroma. The colour of the eye depends on the amount of stromal pigment. (Blue eyes contain little pigment whereas brown eyes have more pigments.)

## Inner Photosensitive Coat/Retina

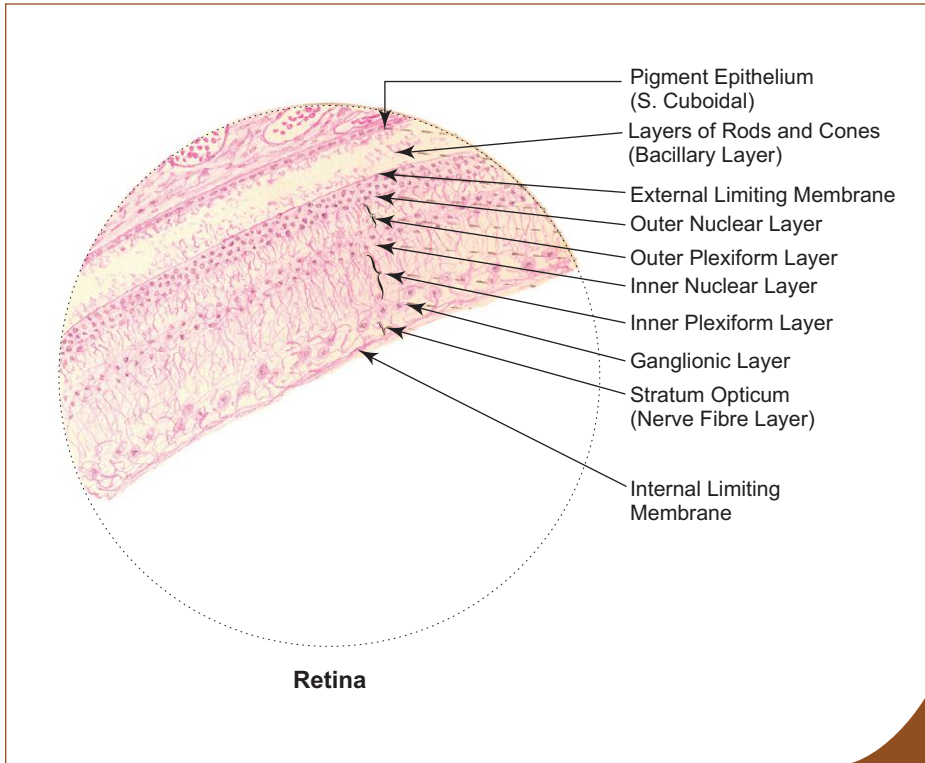
- Retina is the innermost coat of the eyeball.
- It is soft, translucent and pinkish red in colour in fresh unbleached state.
- It consists of two parts. The posterior three-fourth is sensitive to light and is called the *optic part* of retina, which extends from the optic disc to a scalloped margin behind the ciliary body, the *ora serrata*. The anterior one-fourth is nonsensitive to light and it lines the ciliary body (*ciliary part* of retina) and the posterior surface of the iris (*iridial part* of retina) as a double layer of epithelial cells.
- The visual axis of the eyeball passes through a depression in the retina called *fovea centralis*. Here
  - the retina is very thin as some layers are absent,
  - rods are absent, but cones are present,
  - visual acuity is maximum, and
  - blood vessels are absent.
- Fovea is surrounded by an oval yellow pigmented area called *macula lutea*.
- About 4 mm medial to fovea centralis the retina shows a round pale pink area called *optic disc* or *optic papilla*. It is
  - the area through which optic nerve leaves the retina,
  - pierced by central vessels of retina, and
  - considered to be the *blind spot of retina* as here photoreceptors are absent.

## Microscopic Structure of Retina (Box 18.4)

- The photosensitive optic part of retina is principally composed of two layers, the *pigment epithelium* and the *nervous layer*. They are derived embryologically from the double wall of the optic cup, which develops initially as an outgrowth (optic vesicle) from the diencephalon. The outer wall of the optic cup gives rise to pigment epithelium and the inner wall to nervous layer of retina. The space between these walls is known as intraretinal space which gets obliterated once the walls fuse to form retina.

### Pigment epithelium

- Pigment epithelium is formed by a layer of cuboidal pigmented cells attached firmly to the Bruch's membrane of choroid.
- The epithelial cells contain basal nuclei, abundant mitochondria, plenty of melanin granules and many lysosomes together with residual bodies and phagosomes.
- The basal surface of the cells show many infoldings of plasma membrane and the apical surface shows many microvilli. These microvilli continuously phagocytose the tips of rods.
- **Functions:** Pigment epithelium is involved in
  - *absorption of light*—melanin pigments absorb light after photoreceptors are stimulated, thus preventing reflexion of light back.

**Box 18.4 Retina.**

*Presence of*

- (i) pigment epithelium (simple cuboidal);
- (ii) layer of rods and cones;
- (iii) outer and inner nuclear layers;
- (iv) outer and inner plexiform layers;
- (v) ganglionic cell layer.

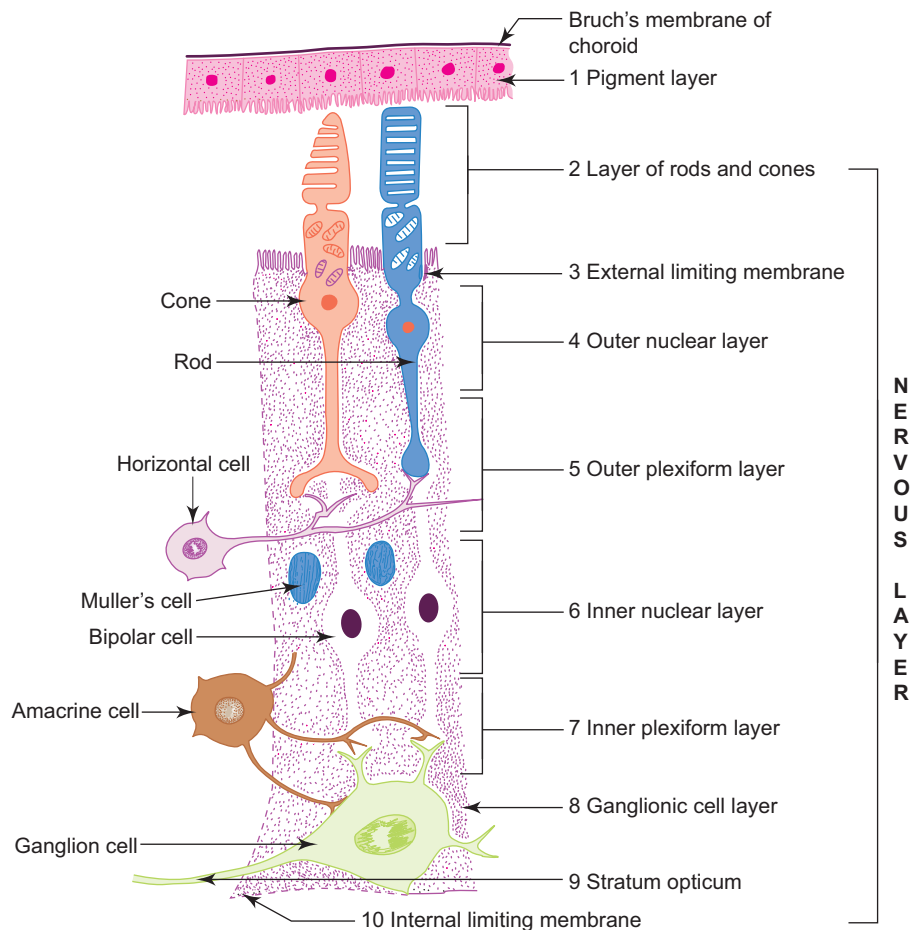
- *phagocytosis of tips of rods*—by lysosomes.
- *structural and metabolic support*—for photoreceptors.
- *storage, esterification and release of vitamin A*—by SER (vitamin A is precursor of photopigments).
- *transport of ions*—by mitochondria and basal infoldings of plasma membrane.

**Nervous layer**

- It is made of three main neurons which are in the visual pathway:
  1. *Photoreceptors*—rods and cones
  2. *Bipolar neurons*
  3. *Ganglionic multipolar neurons*
 and other association neurons and glial cells, namely,
  1. *Horizontal cells* (association neuron)—establish contact between different photoreceptors.
  2. *Amacrine cells* (association neuron)—establish contact between ganglionic neurons.
  3. *Muller's cell* (glial cell)—support other cells, extending from external to internal limiting membranes.
- Thus these cells along with pigment epithelium form ten layers, which can be identified under light microscope (Fig. 18.3):
  1. *Pigment layer* (described already).
  2. *Layer of rods and cones*—made of outer and inner segments of rods and cones (Table 18.1).
  3. *External limiting membrane*—not a membrane, but a series of junctional complexes between apices of Muller's cells and photoreceptors.
  4. *Outer nuclear layer*—consists of cell bodies of rods and cones containing nuclei. Cone nuclei lie close to the external limiting membrane.
  5. *Outer plexiform layer*—is a synaptic layer formed by the axons (fibres) of rods and cones with the dendrites of bipolar neurons and processes of horizontal cells.

6. *Inner nuclear layer*—formed mainly by the cell bodies of bipolar neurons and also by horizontal and amacrine cells. Bipolar cells are of two types:
  - (a) Diffuse bipolar cells—which have synapses with more than one photoreceptors.
  - (b) Monosynaptic bipolar cells—which make synapse with only one photoreceptor (mainly cones).
7. *Inner plexiform layer*—is another synaptic zone, formed by axons of bipolar cells with dendrites of ganglionic neurons and processes of amacrine cells.
8. *Ganglionic cell layer*—consists of large multipolar neurons (ganglionic cells) with large euchromatic nuclei
  - receive input from bipolar neurons and their axons form the optic nerve,
  - two types of neurons are present (diffuse and monosynaptic), and
  - this layer also contains branches of central vessels of retina that nourish 5th–10th layer of retina.
9. *Nerve fibre layer* (stratum opticum)— is composed of bundles of unmyelinated axons from the ganglionic neurons which run towards the optic disc and pass through lamina cribrosa of sclera to form optic nerve (outside the eyeball these axons are myelinated by oligodendrocytes, unlike other peripheral nerves which are myelinated by Schwann cells).
10. *Internal limiting membrane*—is formed by expanded basal ends of Muller’s cells and their basement membrane.

The pigment layer of retina is more firmly attached to the choroid than to the nervous layer. This nervous layer may become detached (**retinal detachment**) from the pigment layer. Retinal detachment usually occurs in myopics. This may lead to blindness if not treated at once. The detachment occurs along the line of obliteration of intraretinal space.



**Fig. 18.3** Layers of retina.

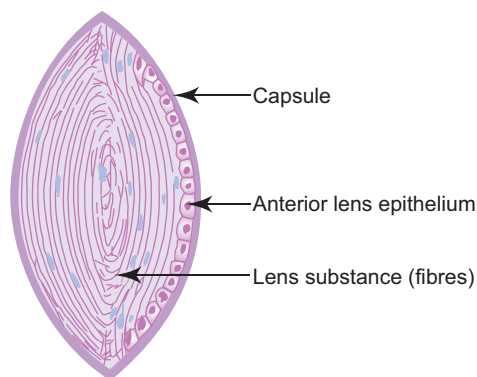
**Table 18.1** Differences between rods and cones

Rod	Cone
<p>Membranous discs Outer segment Modified cilium Inner segment Mitochondria Cell body Rod fibre Rod spherule</p>	<p>Membranous discs Outer segment Modified cilium Inner segment Mitochondria Cell body Cone fibre Cone pedicle</p>
<b>General properties</b>	<b>General properties</b>
<ul style="list-style-type: none"> <li>• 120 million in each eye</li> <li>• Distributed around the periphery</li> <li>• Absent in fovea centralis</li> <li>• Sensitive to light of low intensity (dim light vision), i.e. for night vision</li> <li>• Low resolution, so image without clear detail</li> <li>• Not for colour discrimination</li> </ul>	<ul style="list-style-type: none"> <li>• 6 million in each eye</li> <li>• Concentrated in the centre</li> <li>• Present in large number in fovea</li> <li>• Sensitive to light of high intensity (bright light vision), i.e. for day vision</li> <li>• High resolution, so image is sharp and clear</li> <li>• For colour discrimination</li> </ul>
<b>Microscopic</b>	<b>Microscopic</b>
<ul style="list-style-type: none"> <li>• Outer segment is thin, long and cylindrical (100–120 <math>\mu\text{m}</math>)</li> <li>• Dark round nuclei situated deep to external limiting membrane</li> <li>• Rod fibre (axons) ends in knob-like rod spherule</li> <li>• Groups of rods are connected with bipolar neurons (polysynaptic)</li> <li>• Membranous discs (in outer segment) are independent</li> <li>• Discs contain photopigment, rhodopsin</li> <li>• Tips of the rods are constantly shed and phagocytosed by pigment epithelium</li> <li>• Protein is concentrated at the base of recently formed discs</li> </ul>	<ul style="list-style-type: none"> <li>• Outer segment is thick short and conical (65–75 <math>\mu\text{m}</math>)</li> <li>• Pale oval nuclei situated close to external limiting membrane</li> <li>• Cone fibres end in cone pedicle having a branched expansion</li> <li>• One cone synapse with single bipolar neuron (monosynaptic)</li> <li>• Membranous discs (in outer segment) are continuous with plasma membrane</li> <li>• Discs contain photopigment iodopsin</li> <li>• Tips of the cones are neither shed nor phagocytosed by pigment epithelium</li> <li>• Protein is uniformly distributed</li> </ul>

## Refractive Media of Eyeball

The refractive media include all the transparent structures through which light rays pass. These are:

1. **Cornea** (described already).
2. **Aqueous humour**
  - It is present in anterior and posterior chambers (described with sclerocorneal junction).
3. **Vitreous body**
  - It is the transparent gel present behind the lens.
  - It is made of water (99%), hyaluronic acid and collagen fibrils.
4. **Lens**
  - Lens is a transparent, flexible biconvex disc, that alters its refractive power by changing its curvature.
  - Its posterior surface is less curved than the anterior surface.
  - It lies behind the iris and its most convex anterior surface is in contact with the pupillary margin of the iris.
  - It is held in position by the suspensory ligament of lens which attaches the equator of the lens (circumferential border) with the ciliary processes.
  - Lens comprises three components, namely, capsule, anterior subcapsular epithelium and lens substance (Fig. 18.4).
  - *Capsule*—is a homogeneous elastic basement membrane that envelops the entire lens. It is made of type IV collagen and proteoglycans.
  - *Anterior subcapsular epithelium*—is a simple cuboidal epithelium covering only the anterior surface of lens beneath the capsule. Towards the equator of lens, the cuboidal cells become columnar and become lens fibres.
  - *Lens substance*—is formed by *lens fibres* that are laid concentrically around the original central core by differentiation and elongation of anterior lens epithelial cells at the equator. The young fibres are nucleated, whereas the old fibres lose their nuclei.



**Fig. 18.4** Lens.

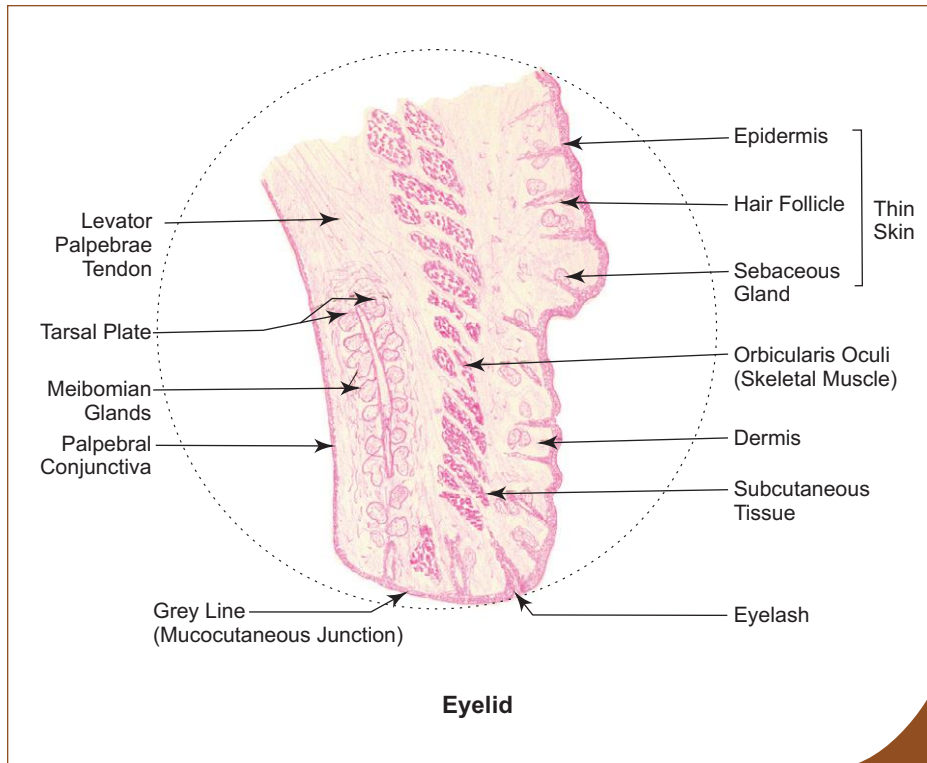
With increasing age, the lens loses its elasticity leading to difficulty in focusing an object at close range, a condition called **presbyopia**. This condition is corrected by wearing glasses with convex lens.

The transparent lens may become opaque (**cataract**) with increasing age or in diabetes mellitus. This leads to interference with clear vision. In this condition the opaque lens is removed and replaced by a synthetic one.

## Accessory Structures of Eye

### *Eyelid (Box 18.5)*

- Eyelids are two movable folds placed in front of the eye to protect it from injury and excessive light.
- The upper eyelid is larger and more mobile than the lower. The external surface is covered by thin skin and the internal surface is covered by mucous membrane called *conjunctiva*. The free border (mucocutaneous junction) presents many short curved hairs, the *eyelashes*, which are arranged in double or triple rows.
- The sebaceous glands (*glands of Zeis*) open into hair follicles.
- The *ciliary glands of Moll* (modified sweat glands) open on the free margin.

**Box 18.5 Eyelid.***Presence of*

- (i) **thin skin** lined by stratified squamous keratinized epithelium (epidermis) on one side;
- (ii) **palpebral conjunctiva** lined by stratified columnar epithelium on the other side;
- (iii) tarsal plate containing **Meibomian glands**;
- (iv) C.S. of **skeletal muscle** (orbicularis oculi).

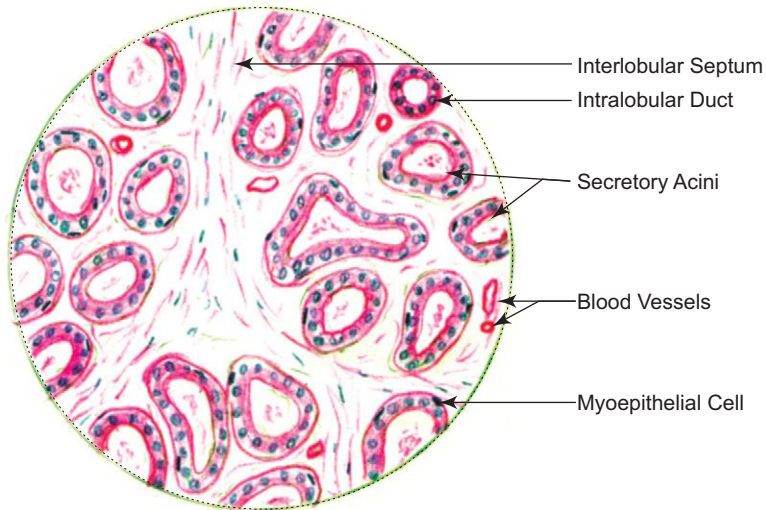
- The eyelid has the following layers from superficial to deep:
  1. *Thin skin*—covers the external surface and contains fine hair follicles.
  2. *Subcutaneous layer*—is very lax and delicate and is devoid of fat.
  3. *Muscle layer*—is formed by skeletal muscle of *orbicularis oculi*.
  4. *Loose connective tissue layer*—lies deep to the muscle layer and is continuous with the subaponeurotic layer of scalp. Effusion of blood can track down into this layer causing *black eye*.
  5. *Tarsal plate and Tarsal glands*—tarsal plate is a crescent-shaped lamina of dense fibrous tissue giving support to each eyelid. The tarsal plates are attached to the orbital margin by orbital septum. Tarsal plate contains 15–20 *tarsal (Meibomian) glands* arranged in a single row oriented vertically at right angle to the free margin. The ducts of these glands open on the lid margin. Tarsal glands are modified sebaceous glands and secrete an oily substance which prevents evaporation and overflow of tears.
  6. *Palpebral conjunctiva*—is the mucous membrane that lines the inner surface of eyelid and is reflected on to the sclera at superior and inferior fornices as ocular conjunctiva. The conjunctiva forms a closed sac when eyelids are closed. This is called *conjunctival sac*. The conjunctiva is made of a lining epithelium supported by vascular connective tissue. The epithelium of palpebral conjunctiva is *stratified columnar epithelium with goblet cells*, whereas that of ocular conjunctiva is *stratified squamous epithelium*.

**Lacrimal Gland (Box 18.6)**

- Lacrimal gland is a compound tubuloacinar gland responsible for secretion of tears.
- Tears contains antibacterial enzyme, lysozyme and electrolytes (similar to plasma).
- The general architecture of the gland is similar to that of salivary glands.
- The secretory acini have distended lumen and are composed of low columnar secretory cells of serous type. Well developed myoepithelial cells surround the acini and intralobular ducts.
- Lacrimal gland consists of two parts, a larger *orbital part* situated in the lacrimal fossa of the orbit and a smaller, *palpebral part* situated in the upper eyelid. Both parts are separated from and also become continuous with each other around the lateral margin of aponeurosis of levator palpebrae superioris. The gland is drained by 12–15 ducts which arise from the orbital part and pass through the lacrimal part to drain into the *superior conjunctival fornix*.

**Box 18.6 Lacrimal Gland.***Presence of*

- (i) **serous acini** having distended lumen;
- (ii) **low columnar epithelial lining** and myoepithelial cells.

**Lacrimal gland****EAR****GENERAL FEATURES**

- Ear is a peripheral sense organ concerned with hearing and equilibrium.
- It is subdivided into three parts, the external ear, middle ear or tympanic cavity and the internal ear or labyrinth.

**STRUCTURE****External Ear**

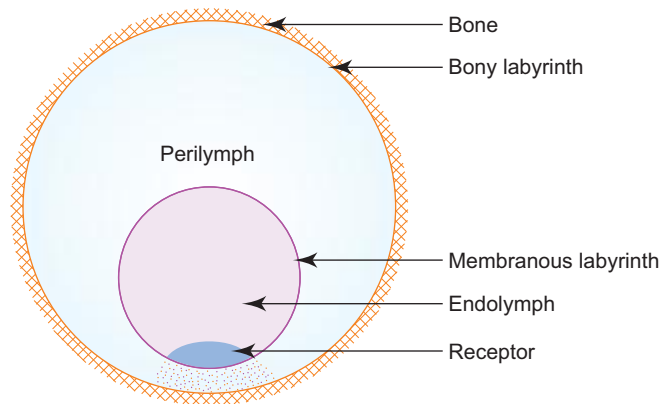
- The external ear consists of the auricle that collects sound waves and the external acoustic meatus that conducts these waves to the tympanic membrane (ear drum).
- The auricle and the outer third of external acoustic meatus are made of *elastic cartilage* covered by thin skin. This skin is provided with hair, sebaceous and *ceruminous* (modified sweat glands) glands.
- The tympanic membrane separates the external ear from the middle ear. It is a trilaminar structure, lined externally by stratified squamous epithelium and internally by simple cuboidal epithelium and is supported in the middle by fibrous tissue.

**Middle Ear**

- The middle ear is a narrow air space compressed mediolaterally, occupying the petrous part of temporal bone. It contains a chain of three tiny auditory ossicles (*malleus*, *incus* and *stapes*) whose function is to transmit the vibrations of tympanic membrane to the perilymph of internal ear.
- The middle ear also has two small muscles (tensor tympani and stapedius) attached to the ear ossicles. These muscles reflexly contract to dampen excessive vibration caused by loud noise.
- Middle ear cavity communicates anteromedially with the nasopharynx through auditory tube. This helps to equalize air pressure on both surfaces of tympanic membrane.

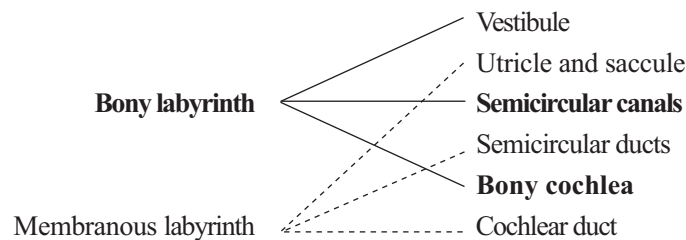
## Internal Ear

- The internal ear consists of a *bony labyrinth*, comprising a series of cavities within the petrous part of temporal bone and a *membranous labyrinth*, comprising a series of membranous sacs and ducts present within the bony labyrinth (Fig. 18.5).



**Fig. 18.5** General organisation of labyrinth.

- The bony labyrinth is lined by endosteum and contains a clear fluid, *perilymph*, in which the membranous labyrinth is suspended.



- The membranous labyrinth is lined by simple squamous epithelium and contains *endolymph*. The squamous epithelial lining of the membranous labyrinth is specialised in certain regions to form *receptor organs*.

## Bony Labyrinth

- Bony labyrinth consists of three parts, *vestibule*, *semicircular canals* and *bony cochlea*. These structures are described, as follows:

### 1. Vestibule

- It is the centrally situated cavity containing *utricle* and *saccule* (the larger and the smaller sac respectively) of membranous labyrinth. It communicates anteriorly with cochlea and posteriorly with three semicircular canals through five orifices (one being common to two of the canals).
- In its lateral wall there are two openings, the *fenestra vestibuli* (oval window) closed by the base of stapes and *fenestra cochleae* (round window) closed by the secondary tympanic membrane.

### 2. Semicircular canals

- They are three in number (superior, posterior and lateral) and are arranged at right angle to each other, so that all the three planes are represented.
- Each canal has a swelling at one end called the *ampulla*. These canals open into the vestibule through five orifices.
- The semicircular canals contain *semicircular ducts*.

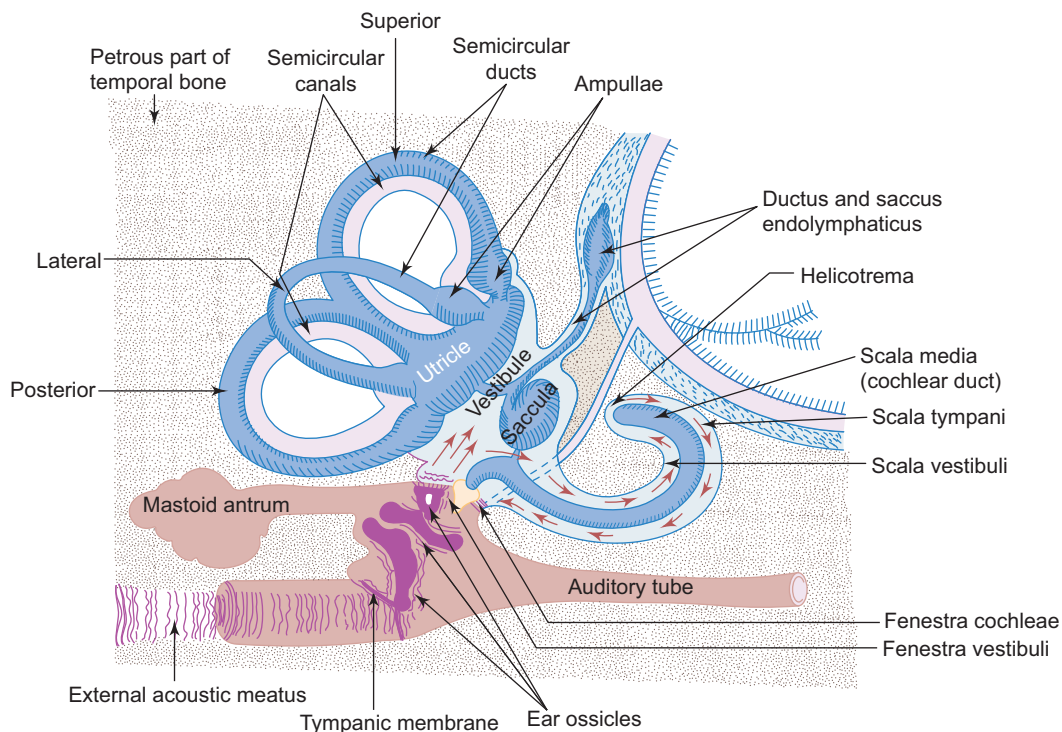


### 3. Bony cochlea

- It consists of a central pillar of bone, the *modiolus*, around which the *cochlear canal* makes two and a half spiral turns. Each successive turn is of decreasing radius, so that the whole structure is conical in shape, resembling the shell of a snail. Its base is directed towards the internal acoustic meatus and is pierced by the cochlear part of the vestibulocochlear nerve.
- A spiral bony shelf or ledge, the *osseous spiral lamina* winds round the modiolus like a thread of a screw and projects into the interior of bony canal. The endosteum over it is thickened to form *limbus spiralis*. The endosteum on the opposite outer wall is thickened to form *spiral ligament* which projects into the interior of the canal as a prominence called *crista basilaris*. Extending between the osseous spiral lamina and crista basilaris is the *basilar membrane*.
- The cochlear duct of the membranous labyrinth, which is triangular in cross section occupies the interior of cochlear canal.
- In cross section, cochlea shows three compartments, the *scala vestibuli* above, the *scala tympani* below (these belong to the canal), and *scala media* in the middle (this belongs to the duct). The scala vestibuli and scala tympani communicate with each other at the apex of cochlea through a narrow space, the *helicotrema*.
- The perilymph in the scala vestibuli is separated from the tympanic cavity by the base of stapes at the fenestra vestibuli.
- The perilymph in the scala tympani is separated from the tympanic cavity by the secondary tympanic membrane at the fenestra cochleae (Fig. 18.6).

### Membranous Labyrinth

- Membranous labyrinth is lodged within the bony labyrinth.
- It consists of two sacs, the *utricle* and *sacculle* besides *semicircular* and *cochlear ducts*. All these structures freely communicate with one another and form a closed system of membranous sacs and ducts.



**Fig. 18.6** Schematic diagram of ear (red arrows indicate the direction of vibration of perilymph).

The structures are described as follows:

### 1. Utricle and saccule

- The utricle and saccule are two membranous sacs lodged in the bony vestibule. These two sacs are connected with each other and with the *saccus endolymphaticus* by means of a Y-shaped *utrículosaccular duct*. (The saccus endolymphaticus lies beneath the dura mater on the posterior surface of petrous part of temporal bone.) The saccule is connected to the cochlear duct by *ductus reuniens* (Fig. 18.6). The epithelial cells lining the wall are specialized in certain regions to form sensory receptors, the *maculae* of *utricle and saccule*.
- **Maculae** are receptors found on the lateral wall of utricle and medial wall of saccule. The macula consists of two types of cells, namely, the *sustentacular cells* and *hair cells*. The sustentacular cells are columnar supporting cells with microvilli on their free surface. Hair cells are flask shaped sensory cells lying between sustentacular cells. Hair cells are innervated by vestibular part of the vestibulocochlear nerve. Each hair cell is provided with long microvilli (*stereocilia*) of varying length and single nonmotile *kinocilium*. The stereocilia and kinocilia are embedded in a thick gelatinous plaque of glycoprotein called *otolithic membrane*, secreted by sustentacular cells. It contains numerous crystalline bodies called *otoliths* or *otoconia* (Fig. 18.7; Box 18.7). Maculae are sensitive to orientation of the head in relation to gravity or other acceleration forces. It is an organ of static balance or position sense.

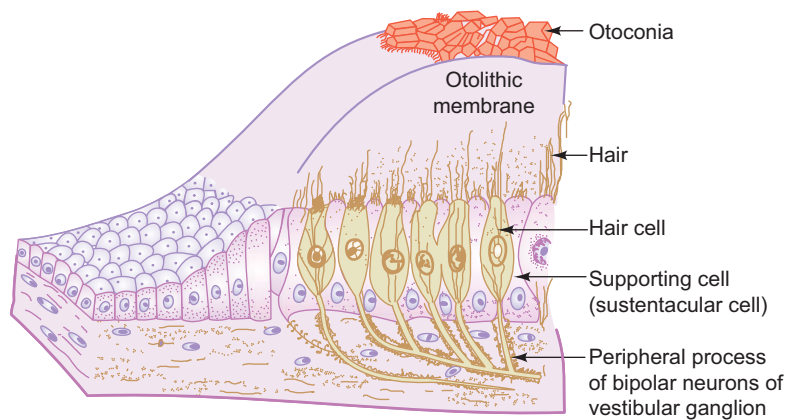
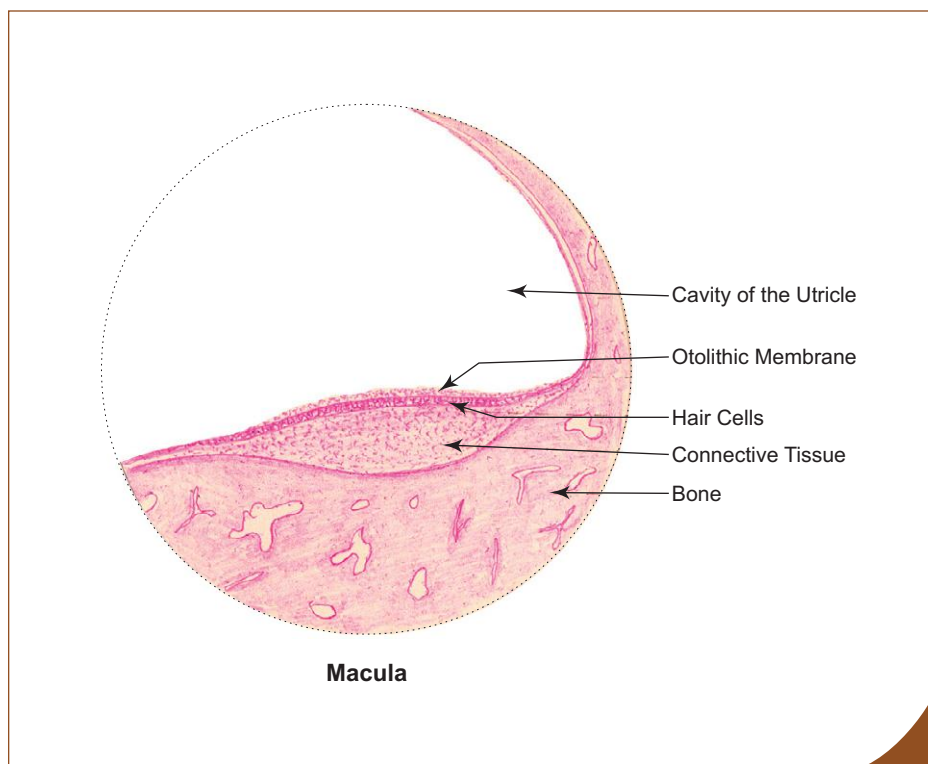


Fig. 18.7 Macula.



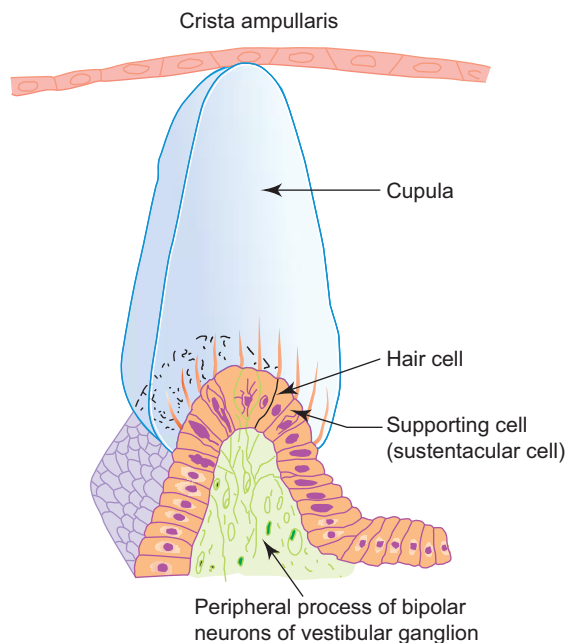
#### Box 18.7 Macula of Utricle.

Presence of

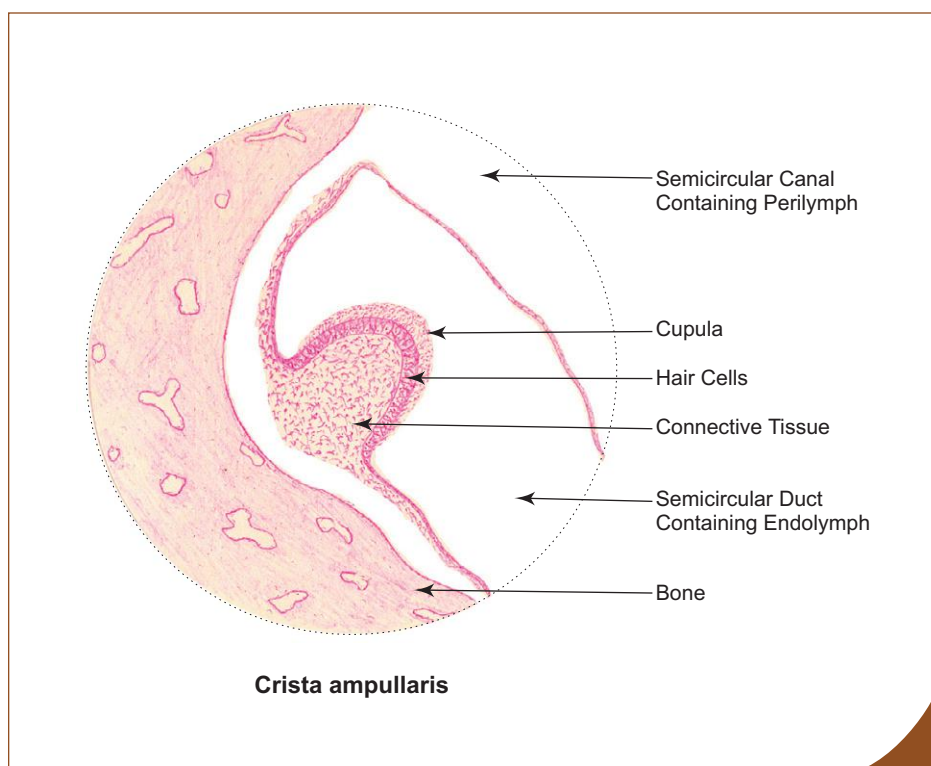
- otolithic membrane and otoconia;
- hair and sustentacular cells.

## 2. Semicircular ducts

- Semicircular ducts are three in number, small in size and found within the semicircular canals. These ducts have the same configuration as the semicircular canals. Sensory receptors are found in the ampullae of semicircular ducts as transverse thickening called crista ampullaris.
- **Crista ampullaris** is similar in structure to macula, but the glycoprotein layer is very thick and conical in shape in cross section. It is called *cupula* (Fig. 18.8; Box 18.8). There are no crystalline bodies in the cupula. Crista is sensitive to angular movement of head (changes in rotational velocity). It is an organ of kinetic balance (movement sense). (For more detail refer a textbook of Physiology.)



**Fig. 18.8** Structure of crista ampullaris.



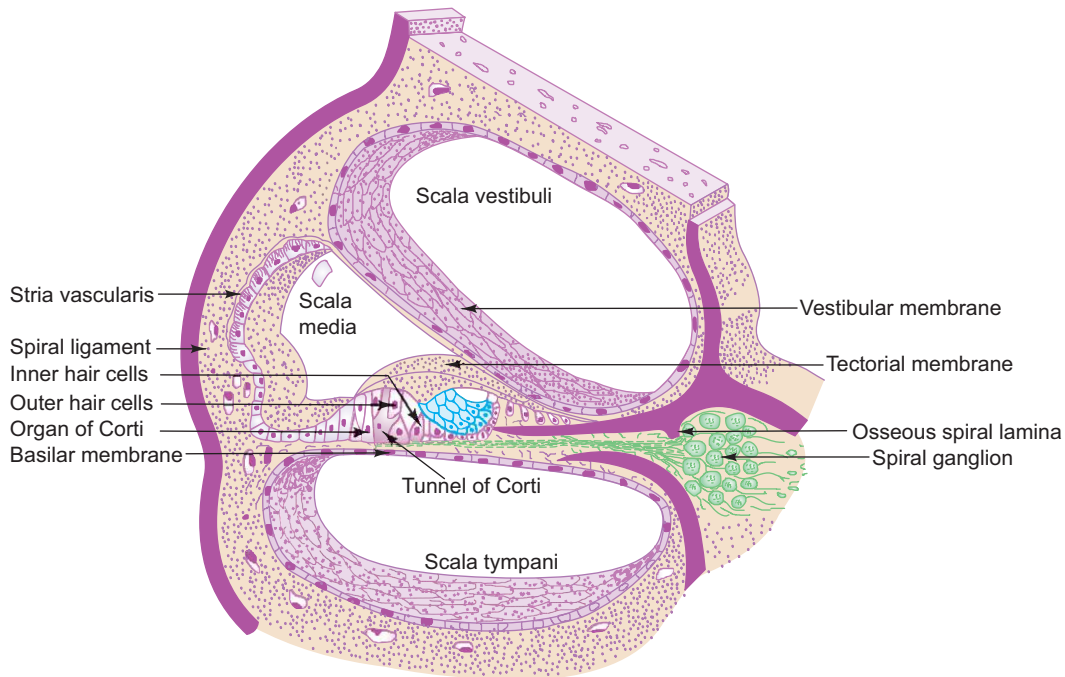
### Box 18.8 Crista Ampullaris.

*Presence of*

- (i) cupula;
- (ii) conical-shaped sense organ comprising hair and sustentacular cells.

### 3. Cochlear duct

- Cochlear duct (scala media) lies within the bony cochlear canal and is triangular in cross section. The base (outer wall) is formed by *stria vascularis*, which is a stratified vascular epithelium lining the spiral ligament. *Stria vascularis* is responsible for maintaining the correct ionic composition of endolymph. The apex of cochlear duct is at the osseous spiral lamina. The roof is formed by *vestibular (Reissner's) membrane* which separates the scala media from scala vestibuli. The floor is formed by basilar membrane which separates the scala media from scala tympani. The basilar membrane supports the organ of Corti, which is the receptor sense organ of hearing (Fig. 18.9; Box 18.9).



**Fig. 18.9** Cross section of cochlear canal with cochlear duct in situ.

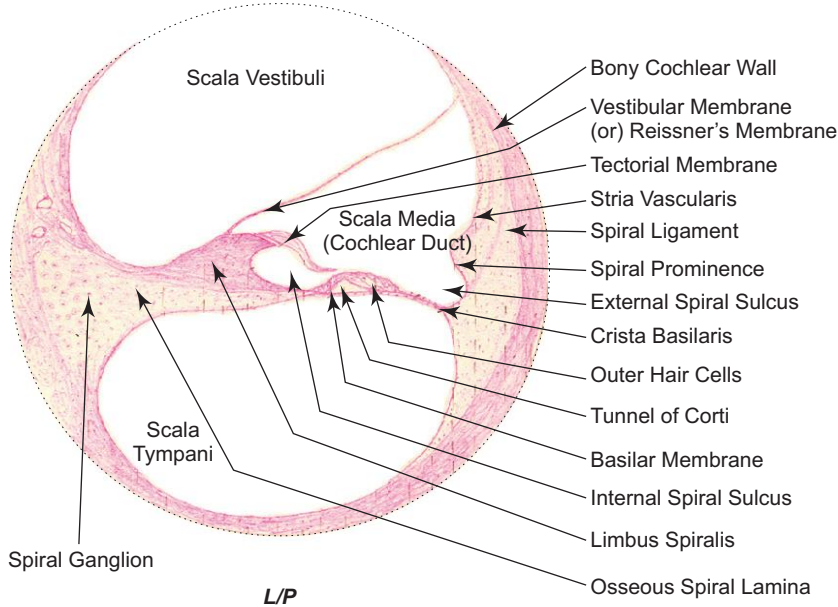
### Organ of Corti

- The organ of Corti consists of two groups of cells. These are:
  - (a) *Hair (sensory) cells*
    - Inner hair cells
    - Outer hair cells
  - (b) *Supporting cells*
    - Inner and outer pillar cells
    - Inner and outer phalangeal cells
    - Border cells
    - Hensen's cells
- In the centre of the organ of Corti there is a canal, the *tunnel of Corti*, bounded by *inner* and *outer* rows of *pillar cells*. The pillar cells are rod-like cells containing tonofibrils.
- On the inner aspect of the inner row of pillar cells is a single row of columnar cells, the *inner phalangeal cells*. They support the bases of *inner hair cells*, arranged in a single row. The inner hair cells are flask-shaped cells. They bear stereocilia (hair) which are arranged in the form of letter 'U'.
- On the outer aspect of the outer row of pillar cells, there are three to five rows of *outer phalangeal cells*. They support the same number of rows of *outer hair cells*. Outer hair cells are much taller than the inner hair cells and their hair (stereocilia) are arranged in the form of letter 'W'.
- Both inner and outer hair cells do not reach the basilar membrane and they are supported by the inner and outer phalangeal cells through their apices. The hair cells have no kinocilium and have only stereocilia (hair). The hair project into a

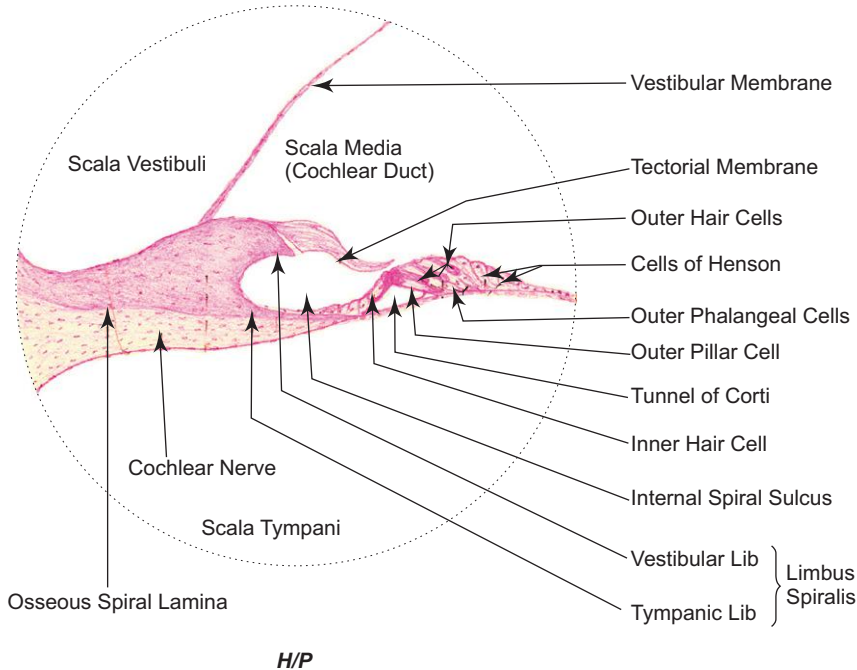
**Box 18.9 Cochlea.**

*Presence of*

- (i) organ of Corti;
- (ii) scala vestibuli, scala media, scala tympani;
- (iii) spiral ganglion.



**Cochlea/organ of Corti**



**Cochlea/organ of Corti**

gelatinous layer, the *tectorial membrane*, which overhangs the organ of Corti from the limbus spiralis. The hair cells are innervated by peripheral processes of bipolar neurons whose cell bodies are situated at the base of the osseous spiral lamina as *spiral ganglion*. Their central processes pass through the modiolus as cochlear nerve.

- The organ of Corti is limited internally by the *border cells*. These are columnar cells arranged in a single row on the inner aspect of inner phalangeal cells.
- *Hensen's cells* limit the outer boundary of the organ of Corti. They are arranged in several rows on the outer aspect of the outer phalangeal cells.
- Stereocilia are agitated due to vibration of basilar membrane caused by conduction of sound from bone to fluid. This results in excitation of the cochlear nerve that supplies them. (Refer to a textbook of Physiology for details.)

# Self-assessment Exercise

## I. Write short notes on:

- |                            |                    |
|----------------------------|--------------------|
| (a) Cornea                 | (e) Eyelid         |
| (b) Retina                 | (f) Lacrimal gland |
| (c) Sclerocorneal junction | (g) Cochlea        |
| (d) Iris                   | (h) Organ of Corti |

## II. Fill in the blanks:

1. Palpebral conjunctiva is lined by \_\_\_\_\_ epithelium.
2. The sclera and choroid are separated by \_\_\_\_\_
3. The sensitive and nonsensitive parts of retina meet at a scalloped margin called \_\_\_\_\_
4. Aqueous humour is secreted by \_\_\_\_\_
5. The blind spot of retina is called \_\_\_\_\_
6. Pigment epithelium of retina is embryologically derived from \_\_\_\_\_ wall of optic cup.
7. Optic nerve is derived from axons of \_\_\_\_\_ present in retina.
8. The glial cell that gives structural and metabolic support to neurons of retina is \_\_\_\_\_
9. \_\_\_\_\_ is the photopigment present in cones.
10. Membranous labyrinth is filled with \_\_\_\_\_

## III. Choose the best answer:

1. Which one of the following statements is *not true* about cornea. It is
  - (a) an avascular structure
  - (b) lined by stratified columnar epithelium
  - (c) nourished by aqueous humour
  - (d) thinner at the centre and thicker at the periphery
2. Anterior surface of lens is lined by which epithelium?
  - (a) Simple cuboidal
  - (b) Simple squamous
  - (c) Simple columnar
  - (d) Pseudostratified columnar
3. Fovea centralis
  - (a) is a nonsensitive pit
  - (b) is highly vascular
  - (c) contains only cones
  - (d) contains only rods
4. Pigment epithelium of retina is involved in
  - (a) absorption of light
  - (b) phagocytosis of tips of rods
  - (c) storage and release of vitamin A
  - (d) all of the above

5. Crista ampullaris is present in

- (a) utricle
- (b) saccule
- (c) semicircular duct
- (d) cochlear duct

**IV. State whether the following statements are true (T) or false (F):**

- 1. Eyeball has no lymphatics ( )
- 2. The corneal epithelium has poor regenerative capacity ( )
- 3. Dilator pupillae is made of smooth muscle ( )
- 4. Bruch's membrane of choroid forms the basement membrane of pigment epithelium ( )
- 5. Uveal tract is the middle vascular pigmented coat of eyeball ( )
- 6. Retina is nourished by central artery of retina only ( )
- 7. Rods are responsible for colour vision ( )
- 8. The number of cones present in each eye is around six million ( )
- 9. Vestibular membrane separates scala media from scala vestibuli ( )
- 10. Spiral ganglion is made of pseudo-unipolar neurons ( )

**V. Match the items in column 'A' with those of column 'B':**

A.	Column 'A'		Column 'B'
	1. Spaces of Fontana	( )	(a) Constriction of pupil
	2. Limbus	( )	(b) Cones
	3. Sphincter pupillae	( )	(c) Scleral venous sinus
	4. Ciliary muscle	( )	(d) Iridocorneal angle
	5. Fovea centralis	( )	(e) Muscle of accommodation
B.	<i>Clinical condition</i>		<i>Causative factor</i>
	1. Cataract	( )	(a) Separation of nervous layer
	2. Presbyopia	( )	(b) Increased intraocular pressure
	3. Glaucoma	( )	(c) Loss of accommodation
	4. Retinal detachment	( )	(d) Collection of blood in the eyelid
	5. Black eye	( )	(e) Opacity of lens

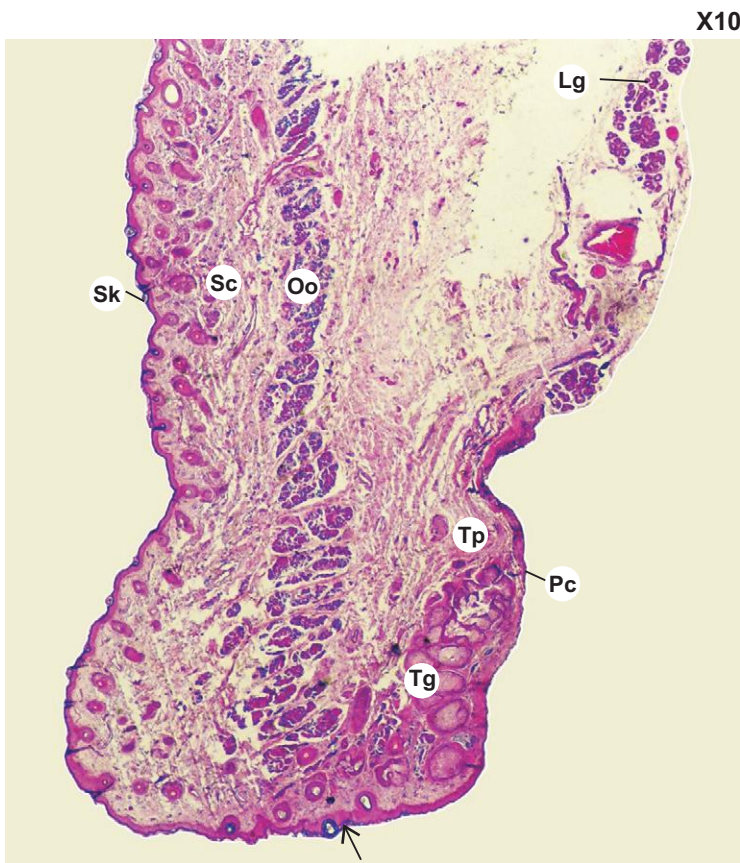
**Answers**

- II.** 1. Stratified columnar      2. Suprachoroidal lamina or lamina fusca      3. Ora serrata  
 4. Ciliary epithelium      5. Optic disc or papilla      6. Outer      7. Ganglionic neurons  
 8. Muller's cell      9. Iodopsin      10. Endolymph
- III.** 1. b      2. a      3. c      4. d      5. c
- IV.** 1. (T)      2. (F)      3. (F)      4. (T)      5. (T)      6. (F)      7. (F)      8. (T)      9. (T)      10. (F)
- V.** A. 1. d      2. c      3. a      4. e      5. b  
 B. 1. e      2. c      3. b      4. a      5. d



# Practical No. 18

## Special Senses



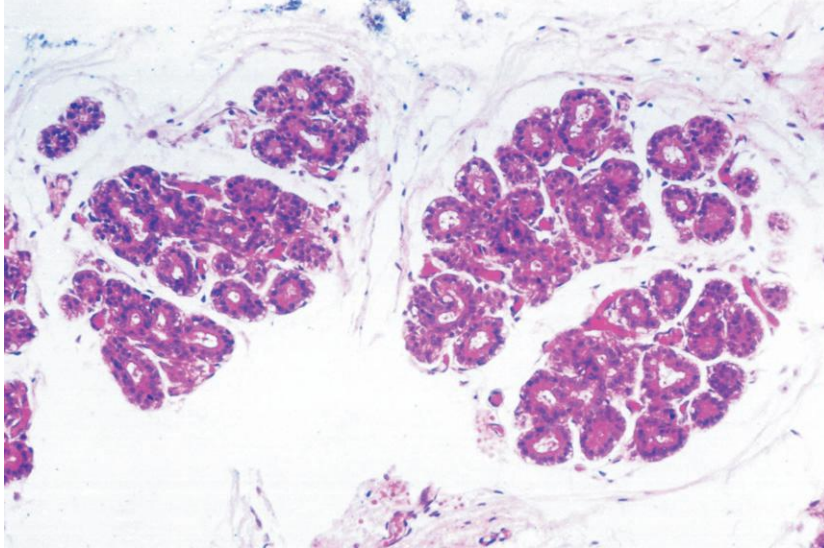
### Plate 18:1 Eyelid (panoramic view).

Examine a section of eyelid under scanner (Plate 18:1) and identify the various layers from superficial to deep:

- Thin skin (**Sk**)—covers the external surface lined by stratified squamous keratinized epithelium.
- Subcutaneous layer (**Sc**)—is formed by loose connective tissue devoid of fat.
- Muscle layer—formed by skeletal muscle, orbicularis oculi (**Oo**) cut cross-wise.
- Tarsal plate (**Tp**) and tarsal glands (**Tg**)—tarsal plate is a dense plate of fibrous tissue in which tarsal glands or Meibomian glands are embedded.
- Palpebral conjunctiva (**Pc**)—covers the internal surface of the eyelid and is lined by stratified columnar.

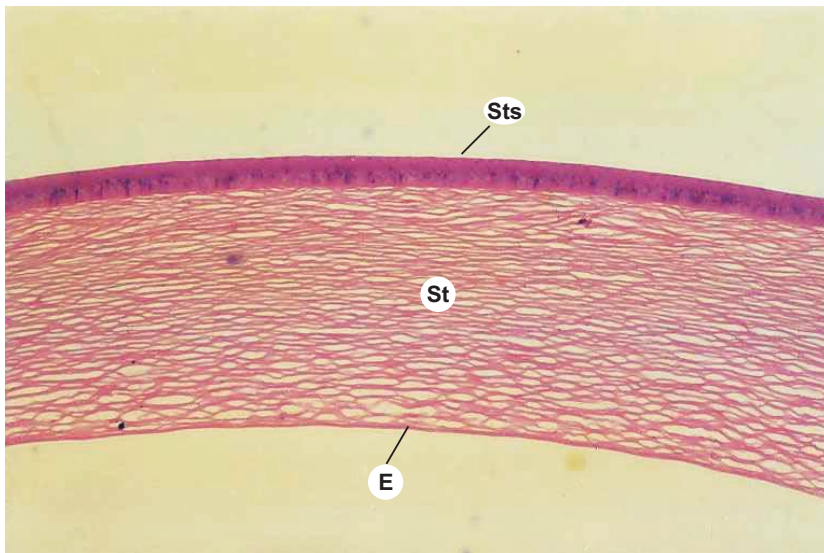
**Lg** = lacrimal gland (palpebral part);  
**arrow** = mucocutaneous junction (grey line).

X100

**Plate 18.2** Lacrimal gland.

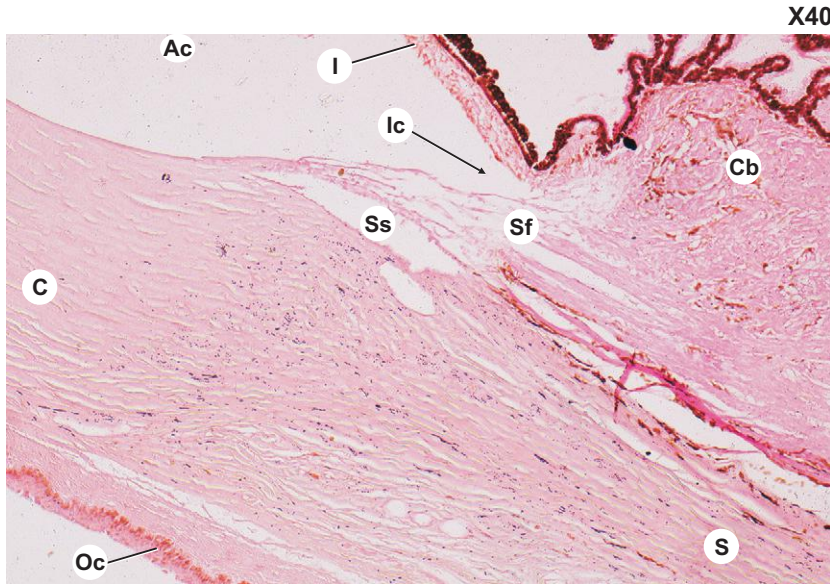
The general architecture of the lacrimal gland is similar to that of serous salivary glands. The secretory acini are lined by low columnar cells of serous type. They have distended lumen. Myoepithelial cells are seen surrounding the acini between basement membrane and secretory cells.

X40

**Plate 18.3** Cornea.

Examine the cornea under low power (Plate 18.3) and identify the five layers from superficial to deep:

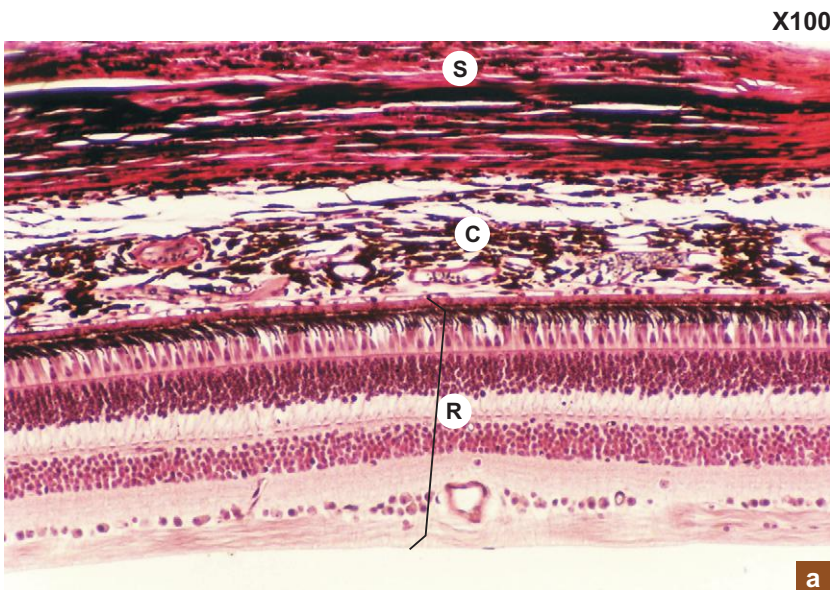
- Corneal epithelium (**Sts**)—stratified squamous epithelium.
- Bowman's membrane—homogeneous acellular layer.
- Substantia propria (**St**)—several layers of collagen fibrils with fibroblasts in between them.
- Descemet's membrane—homogeneous acellular layer.
- Endothelium (**E**)—simple squamous or simple cuboidal epithelium.



**Plate 18.4 Sclerocorneal junction.**

Sclerocorneal junction is the region where the transparent cornea (C) becomes continuous with the opaque sclera (S). An important circular canal, the scleral venous sinus (Ss) which appears as an oval cleft in section is present at the junction.

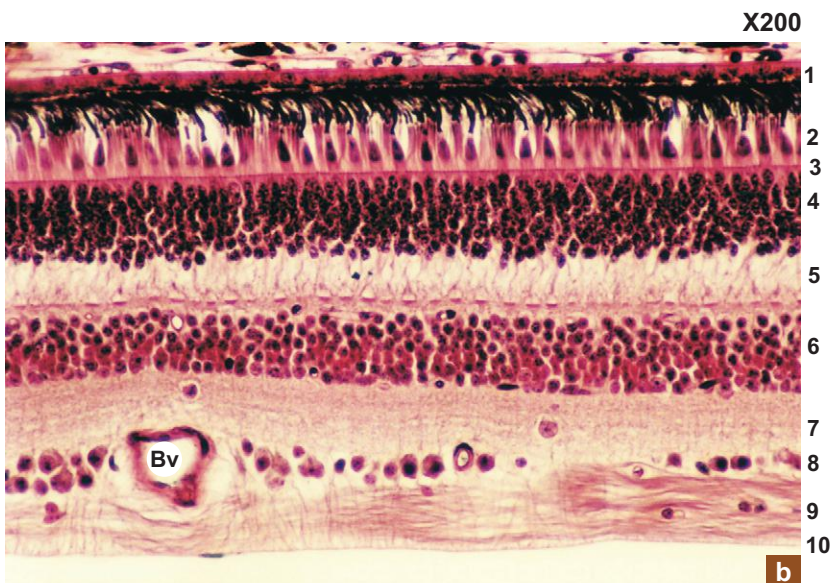
Sf = spaces of Fontana; Ic = iridocorneal angle; I = iris; Cb = ciliary body; Ac = anterior chamber; Oc = ocular conjunctiva.



**Plate 18.5 Retina.**  
**a. Coats of the eyeball.**  
**b. Retina.**

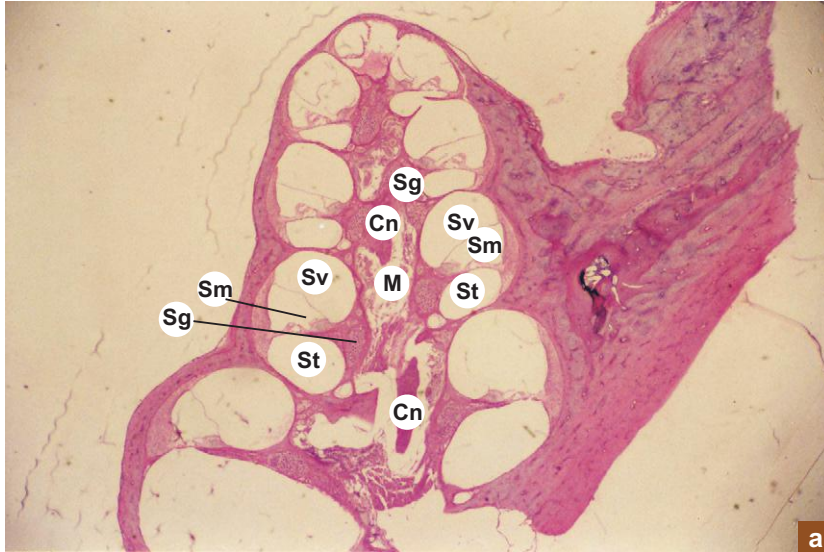
Plate 18:5a illustrates the three coats of the eyeball at low magnification. Sclera (S), part of it is seen – composed of collagen fibres. Choroid (C) – pigmented vascular coat. Retina (R) – made of many layers.

Identify the various layers of retina at high magnification (Plate 18.5b):



- 1 – Pigment epithelium
  - 2 – Layer of rods and cones
  - 3 – External limiting membrane
  - 4 – Outer nuclear layer
  - 5 – Outer plexiform layer
  - 6 – Inner nuclear layer
  - 7 – Inner plexiform layer
  - 8 – Ganglionic cell layer
  - 9 – Stratum opticum
  - 10 – Internal limiting membrane
- Bv = blood vessel.

X10



a

**Plate 18:6**  
**a and b**
**a. Cochlea (panoramic view).**  
**b. Cochlea.**

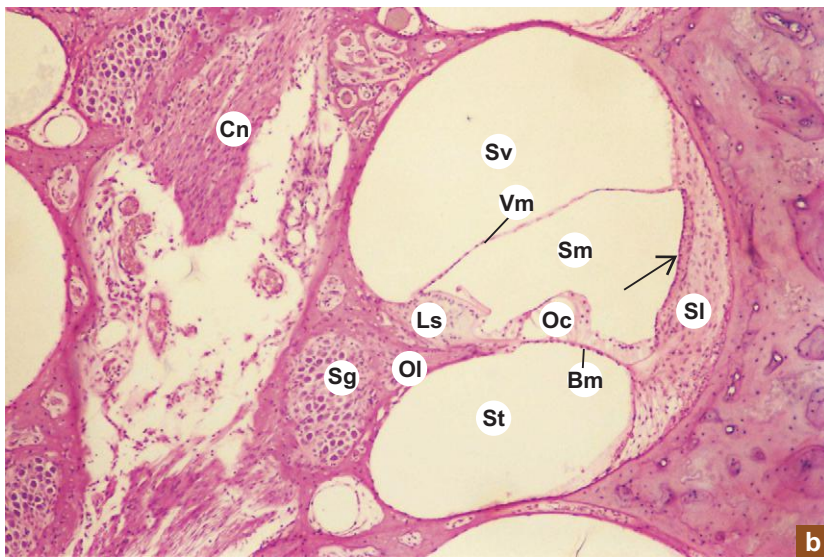
Examine the cochlea under scanner (Plate 18:6a) and appreciate its conical shape.

Identify the central pillar of bone, the modiolus (M) which is traversed by cochlear nerve (Cn) that arises from the spiral ganglion (Sg) situated at the base of the osseous spiral lamina.

Sections of the bony cochlear canal that winds round the modiolus can be seen divided into three compartments, scala vestibuli (Sv), scala media (Sm) and scala tympani (St).

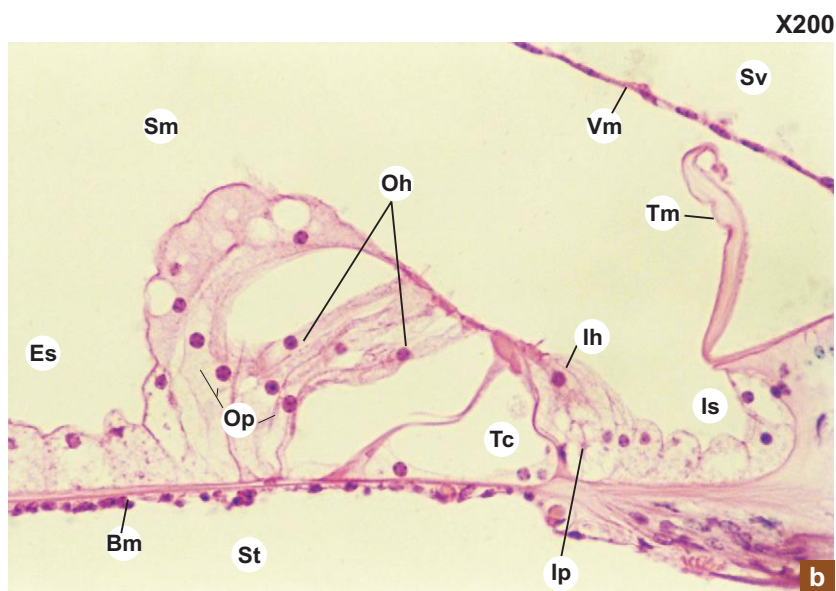
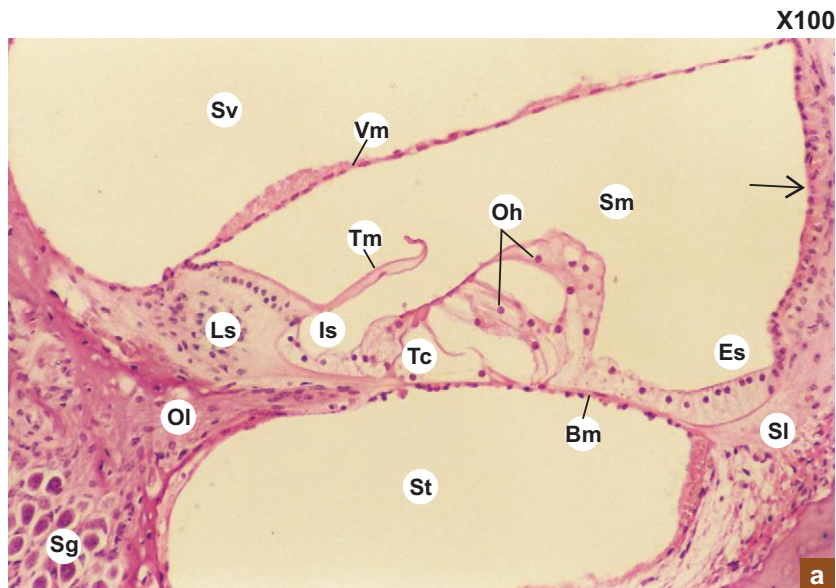
At low magnification (Plate 18:6b) examine the walls that form the triangular cochlear duct (scala media). In its wall identify the following structures:

X40



b

- Organ of Corti (Oc)—is the sense organ of hearing, made of specialized epithelial cells in the floor of cochlear duct. It lies on the basilar membrane (Bm) that separates the scala tympani (St) from scala media (Sm).
  - Stria vascularis (arrow)—is a stratified vascular epithelium forming the outer wall (base) of the cochlear duct. It covers an endosteal thickening called spiral ligament (Sl).
  - Vestibular membrane (Vm)—is a thin membrane lined by squamous epithelium forming the roof of the cochlear duct. It separates the scala media (Sm) from scala vestibuli (Sv).
  - Limbus spiralis (Ls)—is the thickened endosteum over the osseous spiral lamina (Ol) at the apex of the cochlear duct.
- Note the spiral ganglion (Sg) and the cochlear nerve (Cn).



### Plate 18.7 Organ of Corti. a and b

Examine the organ of Corti at low and high magnifications (Plate 18.7a and b). Identify the cells that form the organ of Corti and other related structures.

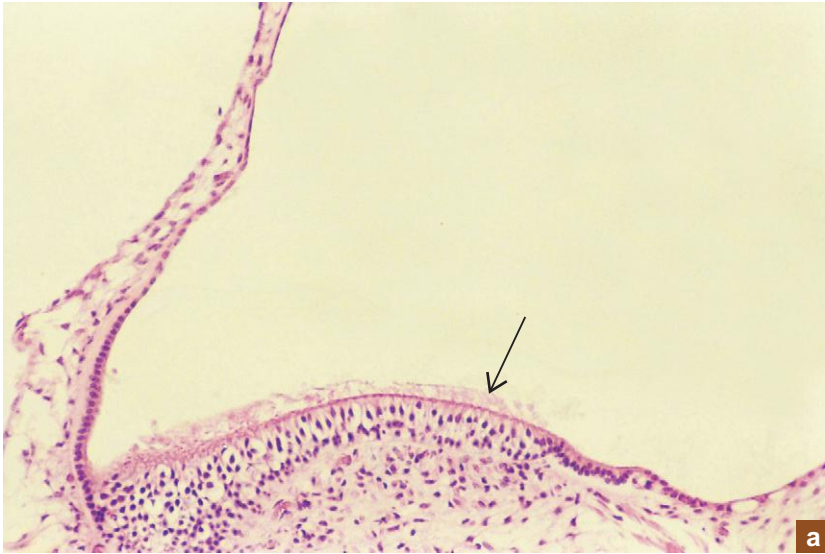#### Organ of Corti

- Tunnel of Corti (Tc)—is a triangular space bounded by inner and outer pillar cells.
- Outer hair cells (Oh)—are arranged in three to five rows supported by the same number of rows of outer phalangeal cells (Op).
- Inner hair cell (Ih)—is arranged in a single row, supported by a single row of inner phalangeal cells (Ip).
- Tectorial membrane (Tm)—overhang the organ of Corti.
- Basilar membrane (Bm)—is the one on which the organ of Corti lies.

#### Neighbouring structures:

- Internal spiral sulcus (Is)
- External spiral sulcus (Es)
- Spiral ligament (SI)
- Stria vascularis (arrow)
- Osseous spiral lamina (Ol)
- Limbus spiralis (Ls)
- Spiral ganglion (Sg)
- Scala vestibuli (Sv)
- Scala tympani (St)
- Scala media (Sm)
- Basilar membrane (Bm)
- Vestibular membrane (Vm)

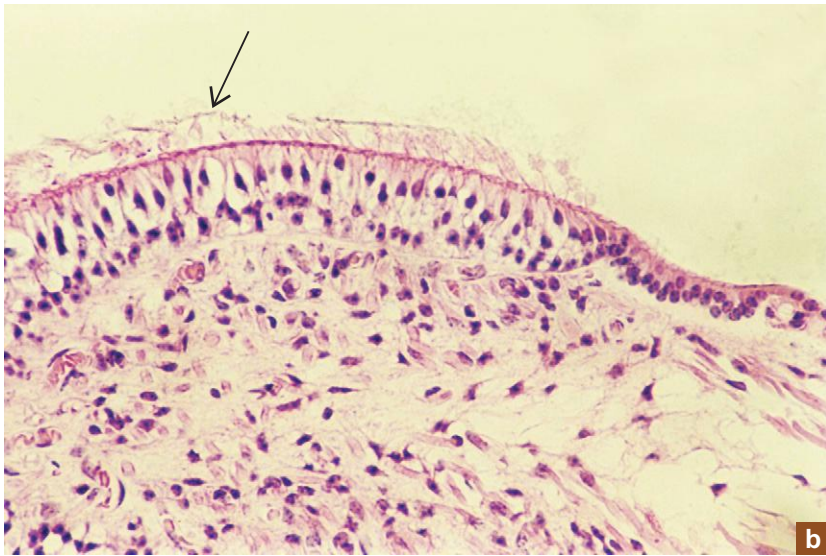
X100



**Plate 18:8** Macula.  
**a and b**

Macula is sense organ for balance found as a thickening of the wall of utricle and saccule. This specialized epithelial thickening is made of hair cells and supporting cells. The hair (**arrow**) project into a gelatinous layer, the otolithic membrane (not seen).

X200



"This page intentionally left blank"

# Appendix

## SOME IMPORTANT CELLS: THEIR LOCATION, FEATURES AND FUNCTIONS

Cell Type	Location	Features and Functions
• Alpha cells (of Pancreas)	– Islet of Langerhans	<ul style="list-style-type: none"> <li>– Usually found at the periphery of the Islet. Larger and less numerous (20%) than <math>\beta</math> cell.</li> <li>– Secrete <b>glucagon</b> that increases blood sugar level through hepatic glycogenolysis.</li> </ul>
• Acidophils	– Adenohypophysis	<ul style="list-style-type: none"> <li>– One type of chromophil cells. Can be stained with acid dyes.</li> <li>– Secrete <b>growth hormone</b> and <b>prolactin</b>.</li> </ul>
• Adipocytes – multilocular	– Brown fat in foetus and in hibernating animals	<ul style="list-style-type: none"> <li>– Contain multiple fat droplets and abundant mitochondria.</li> <li>– Centrally placed spherical nucleus.</li> <li>– <b>Produce heat</b> and protect the newborn against cold.</li> </ul>
• Adipocytes – unilocular	– Yellow fat in adults	<ul style="list-style-type: none"> <li>– Contain single fat droplet.</li> <li>– Eccentric flat nucleus.</li> <li>– <b>Store energy</b> (in the form of triglycerides).</li> </ul>
• Absorptive cells	<ul style="list-style-type: none"> <li>– Mucosal lining of intestine</li> <li>– Gallbladder</li> <li>– Proximal convoluted tubule of kidney</li> </ul>	<ul style="list-style-type: none"> <li>– Brush border or striated border under L/M due to presence of microvilli on the luminal surface.</li> <li>– Increase the surface area for <b>absorption</b>.</li> </ul>
• Adventitial cells/pericytes (Mesenchymal cells)	<ul style="list-style-type: none"> <li>– Blood capillaries</li> <li>– Loose connective tissue</li> </ul>	<ul style="list-style-type: none"> <li>– Undifferentiated <b>pluripotential cells</b> derived from mesoderm found along the blood capillaries. So they are also called pericytes or adventitial cells. Can transform into other cells. Represent tunica media of capillaries. Involved in <b>regeneration</b> of blood vessels after injury.</li> </ul>
• Agranulocytes	– Peripheral blood	<ul style="list-style-type: none"> <li>– Mononuclear leucocytes: lymphocytes and monocytes; do not have specific granules; but do have azurophilic granules.</li> <li>– Involved in <b>defense</b> of the body.</li> </ul>
• Alveolar cells: Type I (Pneumocytes I)	– Lining of pulmonary alveolus	<ul style="list-style-type: none"> <li>– Thin squamous epithelial cells.</li> <li>– Form <b>blood air barrier</b> with endothelium of capillaries.</li> <li>– Involved in gas exchange.</li> </ul>

(Contd.)



(Contd.)

Cell Type	Location	Features and Functions
• Alveolar cells (Great): Type II (Pneumocytes II or septal cells)	– Lining of pulmonary alveolus	– Cuboidal cells found in groups at angles of alveoli. – Foamy cytoplasm containing lamellar bodies. – Produce pulmonary <b>surfactant</b> (lipoprotein), which reduces surface tension.
• Alveolar macrophages (Dust cells)	– Pulmonary interalveolar septum	– Derived from blood monocyte. Part of Mono- nuclear phagocytic system. – <b>Phagocytose</b> inhaled carbon and dust par- ticles. When loaded with RBCs they are called <b>heart failure cells</b> (in heart failure).
• Amacrine cells	– Inner nuclear layer of retina	– Internuncial neurons, which lack axon. Make contact between ganglionic cells. – Help to <b>integrate stimuli</b> .
• Ameloblasts	– Developing tooth	– Columnar cells forming inner enamel epithe- lium of enamel organ (ectodermal derivative) produce <b>enamel</b> of the tooth.
• Antigen-presenting cells (APC):	– Various sites	– Irregular cells. Cytoplasm contains many lyso- somes and phagosomes. – Process the antigen and present to the underly- ing lymphocytes.
(a) Dendritic cells	– In the germinal centre of lymphoid follicles	– Stellate cells with many processes. Bind with antigen and present to B lymphocytes.
(b) Langerhans' cells	– Epidermis of skin, oral mucosa and vagina	– Stellate cells mainly found in the stratum spinosum of epidermis. Contain racquet shaped granules. Capture, process and present surface antigens to underlying lymphoid cells.
(c) M (microfold) cells	– In the surface epithelium over Peyer's patches in ileum	– Specialized epithelial cells overlying lymphoid follicles of Peyer's patches. Transport antigen from the intestinal lumen to the underlying lymphoid tissue.
(d) Macrophages		
• APUD cells (Enteroendocrine cells or neuroendocrine cells)	– Mucosa of GIT, respiratory tract	– Diffuse system of endocrine cells present in the mucosa of GIT. These cells take up amine precursor from blood and decarboxylase them to form amines or peptides which serve as hormones. So they are called <b>Amine Precursor Uptake and Decarboxylation</b> cells. – Basal part of cells shows cytoplasmic granules containing enzymes (amino acid decarboxylase) necessary for synthesis of peptides or amines. Older term <b>argentaffin</b> or <b>enterochromaffin</b> cells. Tumours arising from these cells are called apudomas.
(a) D cells	– Stomach (mainly pylorus), duodenum and Pancreas	– Small, lightly stained cells. – Secrete <b>somatostatin</b> that causes local inhibition of other endocrine cells.

(Contd.)

(Contd.)

Cell Type	Location	Features and Functions
(b) D1 cells	<ul style="list-style-type: none"> <li>– Pancreas and</li> <li>– Digestive tract</li> </ul>	<ul style="list-style-type: none"> <li>– Secrete <b>vasoactive intestinal polypeptide</b> (VIP).</li> <li>– Involved in water and electrolyte balance; increase gut motility.</li> </ul>
(c) EC cells	<ul style="list-style-type: none"> <li>– Pancreas and</li> <li>– Digestive tract</li> </ul>	<ul style="list-style-type: none"> <li>– Secrete 5HT, <b>motilin</b> and <b>substance P</b>.</li> <li>– Increase gut motility.</li> </ul>
(d) G cells	<ul style="list-style-type: none"> <li>– Stomach (pylorus),</li> <li>– Pancreas</li> <li>– Small intestine</li> </ul>	<ul style="list-style-type: none"> <li>– Release <b>gastrin</b> that causes stimulation of gastric acid secretion.</li> </ul>
(e) I cells	<ul style="list-style-type: none"> <li>– Small intestine (mainly duodenum)</li> </ul>	<ul style="list-style-type: none"> <li>– Release <b>cholecystokinin</b> (CCK) that causes stimulation of pancreatic enzyme secretion and gall bladder contraction.</li> </ul>
(f) L cells	<ul style="list-style-type: none"> <li>– Small and large intestine</li> </ul>	<ul style="list-style-type: none"> <li>– Release <b>enteroglucagon</b> that increases blood sugar level through hepatic glycogenolysis.</li> </ul>
(g) N cells	<ul style="list-style-type: none"> <li>– Small intestine</li> </ul>	<ul style="list-style-type: none"> <li>– Release <b>neurotensin</b>.</li> </ul>
(h) S cells	<ul style="list-style-type: none"> <li>– Small intestine (mainly duodenum)</li> </ul>	<ul style="list-style-type: none"> <li>– Release <b>secretin</b>—that causes stimulation of pancreatic enzyme secretion and bicarbonate and water release (water and ion transport).</li> </ul>
● Astrocytes: Fibrous	<ul style="list-style-type: none"> <li>– Mainly in white matter of nervous tissue</li> </ul>	<ul style="list-style-type: none"> <li>– Neuroglial cells.</li> <li>– Have many long slender fibrillar cytoplasmic processes. Give <b>support, nutrition</b> and involved in repair. Serve as barrier to diffusion of toxic substances.</li> </ul>
● Astrocytes: Protoplasmic	<ul style="list-style-type: none"> <li>– Mainly in grey matter of nervous tissue</li> </ul>	<ul style="list-style-type: none"> <li>– Neuroglial cells.</li> <li>– Have many short thick granular cytoplasmic processes. Functions same as fibrous astrocytes.</li> </ul>
● Astroglial cells (Interstitial cells)	<ul style="list-style-type: none"> <li>– Pineal body</li> </ul>	<ul style="list-style-type: none"> <li>– Neuroglial cells.</li> <li>– Characterized by dark elongated nuclei.</li> <li>– Have long cytoplasmic processes containing microfilaments.</li> </ul>
● Beta cells (of Pancreas)	<ul style="list-style-type: none"> <li>– Islet of Langerhans</li> </ul>	<ul style="list-style-type: none"> <li>– Usually concentrated in the centre of islet.</li> <li>– Smaller and more numerous (60–80%) than alpha cells.</li> <li>– Cytoplasmic granules are irregular with angular crystals of insulin.</li> <li>– Secrete <b>insulin</b> that decreases blood sugar level.</li> </ul>
● Basket cells	<ul style="list-style-type: none"> <li>– Deeper part of molecular layer of cerebellum</li> </ul>	<ul style="list-style-type: none"> <li>– Arborize around the Purkinje cells to form a basket-like structure.</li> </ul>
● Basophils (of blood)	<ul style="list-style-type: none"> <li>– Peripheral blood</li> </ul>	<ul style="list-style-type: none"> <li>– A subtype of granular leucocytes.</li> <li>– Constitute about 0.5 – 1% of total leucocytes.</li> <li>– Cytoplasmic granules contain <b>histamine</b> and <b>heparin</b>.</li> </ul>
● Basophils (of pituitary)	<ul style="list-style-type: none"> <li>– Adenohypophysis</li> </ul>	<ul style="list-style-type: none"> <li>– One type of chromophil cells.</li> <li>– Can be stained with basic dyes and are PAS +ve.</li> <li>– Contain basophilic granules.</li> <li>– Secrete <b>TSH, FSH, LH</b> and <b>ACTH</b>.</li> </ul>

(Contd.)

(Contd.)

Cell Type	Location	Features and Functions
• Bone cells:		
(a) Osteoprogenitor cells	– Periosteum and endosteum	– Flat, spindle shaped cells derived from embryonic mesenchyme. – Give rise to osteoblasts and osteoclasts.
(b) Osteoblasts	– Lie on the bone surface	– Active osteoblasts are large cuboidal cells with basophilic cytoplasm. Inactive ones are flat spindle shaped cells with acidophilic cytoplasm. – Secrete organic components of bone matrix ( <b>osteoid</b> ).
(c) Osteocytes	– Lie in lacunae surrounded by bone matrix	– Send cytoplasmic processes into canaliculi to touch other processes of neighbouring cells and to form nexuses. Maintain bone matrix.
(d) Osteoclasts	– Lie on the surface of bone in specialized pits called. Howship's lacunae.	– Large multinucleated cells with acidophilic cytoplasm. Exhibit a ruffled border of deep infoldings of plasma membrane. – Involved in <b>phagocytosis—bone resorption</b> .
• Brush cells	– Respiratory epithelium of respiratory tract	– Columnar cells with microvilli on their free surfaces. May have <b>sensory</b> function.
• Centroacinar cells	– Centre of pancreatic serous acinus	– Cuboidal cells representing the intra-acinar part of the intercalated duct. – Secrete <b>bicarbonate rich fluid</b> that helps to neutralize acid chyme.
• Chief cells (of fundic gland)—Zymogenic cells/Peptic cells	– Basal part of fundic glands of stomach	– Cuboidal cells with basophilic cytoplasm. – Secrete mainly <b>pepsinogen</b> and also <b>lipase</b> and <b>amylase</b> .
• Chief cells (of parathyroid)—Principal cells	– Parathyroid gland	– Small polygonal cells with round vesicular nuclei and pale staining cytoplasm. – Involved in synthesis of <b>parathormone (PTH)</b> .
• Chondrogenic cells	– Inner layer of perichondrium	– Fusiform cells derived from mesenchymal cells. – Give rise to chondroblasts.
• Chondroblasts	– Peripheral zone of cartilage	– Young, oval immature cartilage cells. – Responsible for <b>appositional growth</b> of cartilage.
• Chondrocytes	– Deeper zone of cartilage	– Round, mature cartilage cells found in lacunae. – Responsible for the production of extra-cellular matrix (fibres and ground substance) and <b>interstitial growth</b> of cartilage.
• Chromaffin cells	– Adrenal medulla	– Polyhedral cells derived from neural crest cells. – Synthesize and secrete <b>catecholamines</b> (adrenaline and noradrenaline).
• Chromophils	– Adenohypophysis	– Darkly stained cells; have affinity to acid dyes (acidophils) or basic dyes (basophils). – Responsible for synthesis and secretion of many <b>trophic hormones</b> of pituitary.

(Contd.)

(Contd.)

Cell Type	Location	Features and Functions
• Chromophobes	– Adenohypophysis	– Lightly stained cells; have no affinity to any dye; considered as degranulated chromophils; some may be resting or <b>reserve cells</b> .
• Ciliated cells	– Respiratory epithelium of respiratory mucosa and lining epithelium of uterine tube	– Columnar cells with cilia on their free surfaces; beating of cilia help to <b>transport</b> the entangled structure on the surface towards one direction.
• Clara cells	– Bronchioles	– Nonciliated secretory cells. Replace goblet cells in the bronchiolar epithelium. – Secrete a <b>glycoprotein</b> that protects the lining against oxydative pollutants and inflammation.
• Cones (Photoreceptors)	– Retina	– Elongated cells composed of two portions, an external photosensitive, cone shaped outer segment containing photo-pigment iodopsin and an inner segment containing metabolic machinery necessary for biosynthesis and energy production. These two segments are united by a modified cilium. – Sensitive to light of high intensity; so for day light vision ( <b>colour vision</b> ).
• Corticotrophs	– Adenohypophysis	– One type of basophils of pituitary. Secrete <b>ACTH</b> .
• Cytotrophoblasts	– Chorionic villi	– Cuboidal cells forming an inner layer of trophoblast epithelium of villi during the first half of pregnancy.
• Cytotoxic T cells (Natural killer cells/Graft rejection cells)	– Blood, thymus-dependent zones of lymphoid organs and loose connective tissue	– A subtype of T lymphocyte; <b>kill virus infected cells</b> and some cancer cells directly. Can be identified by means of their surface receptors.
• D cells (see APUD cells) (Delta cells)		
• Decidual cells	– Stroma of endometrium of pregnant uterus – Maternal portion of placenta (decidua basalis)	– Large polyhedral cells rich in glycogen. – Develop from the uterine stromal fibroblast like cells after implantation.
• Dendritic cells (see Antigen presenting cells)		
• Dust cells (see Alveolar macrophages)		
• EC cells (see APUD cells)		
• Endothelial cells	– Line blood and lymph vessels	– Flat, plate like cells. Form a simple squamous epithelium ( <b>endothelium</b> ) lining blood and lymph vessels.
• Enteroendocrine cells (see APUD cells)		

(Contd.)

(Contd.)

Cell Type	Location	Features and Functions
• Eosinophils	– Peripheral blood, loose connective tissue	– A subtype of granular leucocytes. Contain large eosinophilic granules. Nucleus is bilobed. Constitute 1–3% of total leucocytes. – Increase markedly in certain allergic condition and in parasitic infection. – Selectively <b>phagocytose antigen antibody complexes</b> .
• Ependymal cells	– Line ventricles of brain and central canal of spinal cord	– Form a simple columnar epithelium lining ventricles and central canal. It lacks a basement membrane. In the ventricles these cells become modified to form secretory cells of the <b>choroid plexus</b> .
• Epithelial reticular cells	– Thymus	– Stellate cells form a cellular cytoplasmic network giving support to lymphocytes. – Involved in secretion of <b>thymosin</b> and <b>thymopoietin</b> and formation of <b>Hassall's corpuscles</b> .
• Erythrocytes	– Peripheral blood	– Also called red blood corpuscles. Nonnucleated biconvex disc-shaped cells. Contain large amount of oxygen carrying haemoglobin. Involved in <b>transport of oxygen and carbon dioxide</b> .
• Fat cells (see Adipocytes)		
• Fibroblasts	– Connective tissue	– Flat, fusiform cells with euchromatic nuclei. – Responsible for the <b>formation of fibres</b> and ground substance of the connective tissue.
• Fibrocytes	– Connective tissue	– Flat cells with dark elongated nuclei. Considered as inactive fibroblasts.
• Fibrous astrocytes (see Astrocytes)		
• Follicular cells (of ovary)	– Developing ovarian follicle	– Surround the oocyte of developing follicle. Form the membrana granulosa and the cumulus oophorus of the mature Graffian follicle. – Give rise to <b>granulosa lutein</b> cells of corpus luteum.
• Follicular cells (of thyroid)	– Thyroid	– Form cuboidal epithelium lining thyroid follicles. – Involved in synthesis and secretion of <b>triiodothyronine (<math>T_3</math>)</b> and <b>thyroxine (<math>T_4</math>)</b> .
• Foreign body giant cells (multinucleated giant cells)	– In connective tissue under certain pathological conditions (e.g. chronic inflammatory reaction)	– Many macrophages group around a large foreign body and fuse together to form large multinucleated giant cells. They attempt to engulf and destroy foreign particulate matter in tissues.
• G cells (see APUD cells)		

(Contd.)

(Contd.)

Cell Type	Location	Features and Functions
• Ganglion cells (of retina)	– Retina	– Multipolar II order neurons in the visual pathway. Receive inputs from bipolar cells. Axons of these cells form the <b>optic nerve</b> .
• Goblet cells	– Mainly in the epithelium of intestine and respiratory tract	– Flask-shaped secretory cells. – Secrete <b>mucus</b> . Function as <b>unicellular gland</b> .
• Golgi cells (Type II)	– In granular layer of cerebellar cortex	– Small neurons with vesicular nucleus and short neuronal processes. Involved in formation of <b>glomeruli</b> with Mossy fibres and dendrites of granular cells.
• Gonadotrophs	– Adenohypophysis	– One type of basophils of pituitary. Secrete <b>FSH</b> and <b>LH</b> .
• Granule cell	– Respiratory epithelium of respiratory tract	– Small round cells with many cytoplasmic granules (part of APUD cells).
• Granulocytes	– Peripheral blood	– One of the subgroups of leucocytes. They are so named because of their prominent cytoplasmic granules. Based on staining characteristics of these granules they are classified as neutrophil, eosinophil and basophil.
• Granulosa cells	– Ovarian follicles	– Surround the developing oocytes in the follicles. – Help to nourish and protect them. – Secrete liquor folliculi.
• Granulosa lutein cells	– Corpus luteum	– Large pale staining cells. Contain lipochrome pigments, lipid droplets, sER and abundant mitochondria. – Derived from granulosa cells of ovarian follicle. Secrete <b>progesterone</b> .
• Great alveolar cells (see Alveolar cells)		
• Gustatory cells	– Taste bud	– Lightly stained elongated cells with microvilli on their apical ends. Perception of <b>taste sensation</b> .
• Hair cells of organ of Corti	– Organ of Corti	– Flask-shaped cells arranged in two rows, a single inner row and 3–5 outer rows. Supported by phalangeal cells. Bear stereocilia (hairs). Concerned with <b>hearing</b> .
• Haemopoietic stem cells	– Bone marrow	– Pluripotent undifferentiated cells. Can produce all formed elements of blood.
• Heart failure cells	– Lung, sputum	– Alveolar macrophages with ingested erythrocytes. Appear when lung becomes congested with blood in congestive heart failure.
• Helper T cells	– Lymphoid organs, blood	– Subtype of T lymphocytes. Help other immune cells to perform their function very effectively by producing a variety of mediators known as <b>interleukins (cytokines)</b> .

(Contd.)

(Contd.)

Cell Type	Location	Features and Functions
• Hepatocytes	– Liver	– Large, polyhedral cells arranged in plates of one cell thick. Contain polyploid nuclei. Organelles are well developed reflecting the multiple function of the cells. Secrete <b>bile</b> and plasma proteins. Involved in <b>detoxification</b> of harmful drugs.
• Histiocytes (Macrophages)	– Loose connective tissue	– Irregular phagocytic cells with acidophilic cytoplasm and dark eccentrically placed indented nuclei. – Derived from monocytes. – Part of the <b>mononuclear phagocytic system</b> of cells.
• Horizontal cells of Cajal	– Molecular layer of cerebral cortex	– Small stellate or spindle shaped neurons found in the deeper part of the molecular layer.
• Horizontal cells of retina	– Retina	– Association neurons. Establish contact between different photoreceptors.
• Interstitial cells of Leydig	– Testis	– Polyhedral, endocrine cells with acidophilic cytoplasm. Occur in the angular interval between seminiferous tubules. Secrete male sex hormone, <b>testosterone</b> .
• Ion transporting cells	– Proximal convoluted tubules (PCT), striated ducts	– Epithelial cells lining the PCT and striated ducts. Show basal striations due to infoldings of plasma membrane and longitudinal orientation of mitochondria between the infoldings. Involved in transcellular transport of ions.
• Juxtaglomerular cells (JG cells)	– Afferent arteriole of the glomerulus	– Highly modified smooth muscle cells of tunica media of afferent arteriole at the point of contact with the DCT. – Secrete <b>renin</b> . Sensitive to blood pressure changes.
• Keratinocytes	– Epidermis of skin	– Most abundant cell type (90%) of epidermis. – Undergo keratinization by producing a tough scleroprotein, <b>keratin</b> , that protects the skin.
• Keratocytes	– Cornea	– Long slender fibroblasts present in the substantia propria of cornea. Responsible for production of <b>collagen</b> fibrils.
• Killer T cells (see Cytotoxic T cell)		
• Kupffer's cells	– Sinusoids of liver	– Modified endothelial cells of sinusoids, which are phagocytic in function. Phagocytose worn out RBCs, pigment deposits and iron. Part of <b>mononuclear phagocytic system</b> .
• Lacis cells (Extra glomerular mesangial cells/Polkissen cells)	– At the vascular pole of the renal corpuscle	– Resemble intraglomerular mesangial cells. Function is not exactly known. May be involved in production of <b>erythropoietin</b> .

(Contd.)

(Contd.)

Cell Type	Location	Features and Functions
<ul style="list-style-type: none"> <li>• Langerhans' cells (see Antigen-presenting cells)</li> </ul>		
<ul style="list-style-type: none"> <li>• Leucocytes</li> </ul>	<ul style="list-style-type: none"> <li>– Peripheral blood</li> </ul>	<ul style="list-style-type: none"> <li>– Also called white blood corpuscles. Subdivided into granulocytes and agranulocytes. Found in large number at the site of inflammation. Involved in <b>defense</b> of the body.</li> </ul>
<ul style="list-style-type: none"> <li>• Leydig cells (see Interstitial cells of Leydig)</li> </ul>		
<ul style="list-style-type: none"> <li>• Liver cells (see Hepatocytes)</li> </ul>		
<ul style="list-style-type: none"> <li>• Lymphocytes B</li> </ul>	<ul style="list-style-type: none"> <li>– Peripheral blood</li> <li>– Lymph</li> <li>– Lymphatic tissue</li> <li>– Loose connective tissue</li> </ul>	<ul style="list-style-type: none"> <li>– One of the functional (immunological) types of lymphocytes. Acquire their immunocompetency in bone marrow (bursa of Fabricius in birds).</li> <li>– When stimulated by an antigen, they divide and transform into plasma cells that in turn secrete antibodies.</li> <li>– Live for 2–3 days.</li> <li>– Concerned with <b>humoral immunity</b>.</li> </ul>
<ul style="list-style-type: none"> <li>• Lymphocytes T</li> </ul>	<ul style="list-style-type: none"> <li>– Peripheral blood</li> <li>– Lymph</li> <li>– Thymic-dependent zones of lymphoid organ</li> <li>– Loose connective tissue</li> </ul>	<ul style="list-style-type: none"> <li>– One of the functional types of lymphocytes. Form 80% of the circulating lymphocytes in peripheral blood. Acquire their immunocompetency in thymus. Involved in <b>cell mediated immune response</b>, in which T lymphocytes proliferate, attack and directly kill invading foreign micro-organisms or antigens.</li> </ul>
<ul style="list-style-type: none"> <li>• M (microfold) cells (see Antigen presenting cells)</li> </ul>		
<ul style="list-style-type: none"> <li>• Macrocytes and microcytes</li> </ul>	<ul style="list-style-type: none"> <li>– Peripheral blood</li> </ul>	<ul style="list-style-type: none"> <li>– Erythrocytes larger (9–12 <math>\mu\text{m}</math>) than normal size are called macrocytes.</li> <li>– Erythrocytes smaller (6 <math>\mu\text{m}</math>) than normal size are called microcytes.</li> </ul>
<ul style="list-style-type: none"> <li>• Macrophages (see Histocytes)</li> </ul>		
<ul style="list-style-type: none"> <li>• Mammothrophs (Lactotrophs)</li> </ul>	<ul style="list-style-type: none"> <li>– Adenohypophysis</li> </ul>	<ul style="list-style-type: none"> <li>– Subtype of acidophil. Can be stained with carmine or erythrosin. Secrete <b>prolactin</b> which stimulates milk production.</li> </ul>
<ul style="list-style-type: none"> <li>• Mast cells</li> </ul>	<ul style="list-style-type: none"> <li>– Loose connective tissue</li> </ul>	<ul style="list-style-type: none"> <li>– Large, round or fusiform cells containing metachromatic granules. Granules contain <b>histamine</b> and <b>heparin</b>.</li> <li>– Involved in inflammatory reaction, allergy and hypersensitive states.</li> </ul>
<ul style="list-style-type: none"> <li>• Megakaryocytes</li> </ul>	<ul style="list-style-type: none"> <li>– Bone marrow</li> </ul>	<ul style="list-style-type: none"> <li>– Large giant cells with multilobular polyploid nuclei. Fragments of their cytoplasm form blood <b>platelets (thrombopoiesis)</b>.</li> </ul>

(Contd.)



(Contd.)

Cell Type	Location	Features and Functions
• Melanocytes	– Epidermis, hair follicle and iris	– Round cells with many long cytoplasmic processes. Produce <b>melanin</b> pigments from tyrosinase filled vesicles (melanosomes). Neural crest in origin. Responsible for the colour of skin, hair and eye.
• Memory B lymphocytes and memory T lymphocytes	– Lymphoid organs, loose connective tissue	– Activated lymphocytes that are already exposed to specific antigen. Produce more effective <b>secondary immune response</b> .
• Merkel cells	– Epidermis of skin	– Sensory cells present in stratum basale of epidermis concerned with <b>touch sensation</b> .
• Mesangial cells	– Glomerulus of kidney	– Specialized connective tissue cells which are stellate in shape. Support the capillary network of glomerulus.
• Mesenchymal cells (see Adventitial cells)		
• Mesothelial cells	– Line the serous body cavities like peritoneal, pleural and pericardial cavities	– Flat, plate-like cells. Form a simple squamous epithelium ( <b>mesothelium</b> ) lining serous cavities.
• Microglia	– Brain and spinal cord	– Small neuroglial cells of mesodermal origin. Have short thin processes with spines. Involved in phagocytosis. Part of the <b>mononuclear phagocytic</b> system.
• Monocytes	– Peripheral blood	– Agranular leucocytes. Nucleus is kidney shaped and lightly stained. Migrate into connective tissue to become macrophages. <b>Precursor of mononuclear phagocytic system cells</b> .
• Mononuclear phagocytic cells (Old term – Reticulo-endothelial cells)	– Various sites	– Diffuse system of phagocytic cells. Irregular in outline. Contain many lysosomes. Derived from blood monocytes. Involved in <b>phagocytosis</b> .
(a) Alveolar macrophages (Dust cells)	} → (Antigen-presenting cells)	→ (See respective cells)
(b) Tissue macrophages (Histiocytes)		
(c) Kupffer's cells		
(d) Microglia		
(e) Osteoclasts		
(f) Dendritic cells		
(g) Langerhans' cells		
• Motor neurons (see Neurons)		
• Mucous cells	– Mucous glands	– Cuboidal or pyramidal cells with flat peripheral nuclei. Form secretory acini of glands. Contain mucigen droplets. Secrete thick, viscous, protective lubricating gel, the <b>mucus</b> .
• Mucous neck cells	– Fundic gland of stomach	– Low columnar cells in the neck of the fundic glands. Secrete <b>acid mucus</b> .

(Contd.)

(Contd.)

Cell Type	Location	Features and Functions
• Muller cells	– Retina	– Tall cells extending from inner to outer limiting membranes. <b>Support</b> other cells of retina.
• Multinucleated giant cells (see Foreign body giant cells)		
• Multipolar neurons (see Neurons)		
• Myoepithelial cells	– Salivary, sweat, mammary and lacrimal glands	– Contractile cells stellate in shape. Found between basement membrane and secretory cells, clasping the acini. Help to <b>squeeze out secretion</b> .
• Myofibroblasts	– At the site of wound	– Specialized contractile fibroblasts. Help in <b>wound contraction</b> .
• Myoid cells	– Testis	– Specialized contractile smooth muscle like cells. Present beneath the basement membrane of seminiferous tubule.
• Myointimal cells	– Large/Elastic artery	– Contractile smooth muscle-like cells present in the subendothelial connective tissue of tunica intima.
• Natural killer cells (see Cytotoxic T cells)		
• Neural crest cells	– Embryo	– Cord of cells present dorsolateral to the developing neural tube. Give rise to cerebrospinal ganglia, Schwann cells, medulla of suprarenal (chromaffin cells), carotid bodies, melanocytes, leptomeninges (pia and arachnoid) and pigment cells of CNS.
• Neuroepithelial cells	– Taste bud – Organ of Corti	– Specialized epithelial cells, e.g. gustatory cells of taste buds and hair cells of organ of Corti which serve as sensory cells for the <b>reception of external stimuli</b> .
• Neuroglia	– Brain – Spinal cord	– Supporting cells of CNS. Give <b>structural and metabolic support</b> .
(a) Astrocytes (b) Oligodendrocytes (c) Microglia (d) Ependyma	→ (See respective cells)	
• Neurons (Nerve cells)	– Nervous tissue	– Structural and functional units of nervous system. Consist of cell body, dendrites and axon. <b>Conduct</b> nerve impulses. Cannot multiply.
(a) Bipolar neurons	– Retina – Spiral and vestibular ganglia – Olfactory epithelium	– Have two processes—a central axon and a peripheral dendrite. <b>Sensory in function</b> .
(b) Inter-neurons	– Brain – Spinal cord	– Connect sensory and motor neurons and complete the functional circuit.

(Contd.)

(Contd.)

Cell Type	Location	Features and Functions
(c) Motor (efferent) neurons	– Brain – Spinal cord	– Conduct impulses from CNS to effector organs.
(d) Multipolar neurons	– CNS and Autonomic ganglia	– Have many processes.
(e) Pseudounipolar neurons	– Cerebrospinal ganglia	– Have single process that divides into an axon (central process) and a dendrite (peripheral process).
(f) Sensory (afferent) neurons	– Sensory ganglia	– Receive stimuli from receptors and conduct to CNS.
(g) Unipolar neurons	– Mesencephalic nucleus of Vth cranial nerve	– Have single process.
• Neutrophils	– Peripheral blood – Loose connective tissue at the site of injury	– A subtype of leucocytes that constitutes 55–60% of total population. Contain lobulated nuclei. Represent the <b>first line of cellular defense</b> against bacterial invasion by engulfing and destroying them.
• Odontoblasts	– Line the pulp cavity of the tooth	– Columnar cells with cytoplasmic processes, which extend into dentinal tubules. Form <b>dentin</b> of the tooth.
• Olfactory cells	– Olfactory epithelium	– Modified bipolar neurons. The dendritic processes extend to the surface and end in olfactory vesicles. The vesicles are provided with nonmotile olfactory hairs. The axonal processes are collected into bundles of olfactory nerves. Sensory in function for odour producing substances ( <b>smell</b> ).
• Oligodendrocytes	– White matter of CNS	– One of the neuroglial cells. Small angular cells with spherical nuclei. Form the <b>myelin</b> sheath in CNS.
• Oocytes		
(a) Primary	– Developing ovarian follicle	– Large female germ cell (50–80 $\mu\text{m}$ ) derived from oogonium. It is surrounded by follicular cells.
(b) Secondary	– Mature Graafian follicle	– Formed as a result of completion of I meiotic division. Released during ovulation as a large ovum (125 $\mu\text{m}$ ) along with zona pellucida and corona radiata.
• Osteoblasts	} → (see Bone cells)	
• Osteoclasts		
• Osteocytes		
• Osteoprogenitor cells		
• Oxyntic cells (Parietal cells)	– Fundic glands of stomach	– Large pyramidal cells with acidophilic cytoplasm. Concentrated more in the body of the gland. Secrete <b>HCl</b> and gastric <b>intrinsic factor</b> .

(Contd.)

(Contd.)

Cell Type	Location	Features and Functions
• Oxyphil cells	– Parathyroid	– Polyhedral cells with acidophilic cytoplasm. Increase in number with age. Function not known.
• Paneth cells	– At the base of crypt of Lieberkuhn of small intestine	– Pyramidal cells with large acidophilic granules. Secrete <b>lysozyme</b> , an antibacterial enzyme that controls intestinal flora.
• Parafollicular cells (C cells/Clear cells)	– Thyroid	– Found as a part of follicular epithelium or as isolated clusters of cells between thyroid follicles. – Larger but takes less stain than follicular cells. Never reach the lumen of the follicle. – Secrete <b>calcitonin</b> , a hormone that lowers blood calcium level.
• Paralutein cells (Theca lutein cells)	– Corpus luteum	– Derived from cells of theca interna of ovarian follicle after ovulation. Paralutein cells are much smaller and less numerous than granulosa lutein cells. Have lipochrome pigments, lipid droplets and abundant sER. Secrete <b>oestrogen</b> .
• Parietal cells (see Oxyntic cells)		
• Peg cells	– Lining epithelium of uterine tube	– Nonciliated secretory cells seen among the ciliated columnar cells. Increase in number during secretory phase and pregnancy.
• Peptic cells (see Chief cells of stomach)		
• Pericytes (see Adventitial cells)		
• Phalangeal cells	– Organ of Corti	– Columnar cells, support bases of outer and inner hair cells.
• Pillar cells	– Organ of Corti	– Rod-like cells arranged in inner and outer rows bordering the <b>tunnel of Corti</b> .
• Pinealocytes	– Pineal gland	– Modified neurons, stellate in shape having irregular nuclei. Secrete <b>melatonin</b> .
• Pituicytes	– Neurohypophysis	– Highly branched glial cells. Give support to axons.
• Plasma cells	– Connective tissue, sites of chronic inflammation	– Oval cells with eccentrically placed 'cart wheel' nuclei. Derived from B lymphocytes. Produce <b>antibodies</b> .
• Platelets (Thrombocytes)	– Peripheral blood	– They are not cells, but are fragments of cytoplasm derived from megakaryocytes. Carry clotting factors. Involved in <b>clot formation</b> and <b>clot retraction</b> .
• Pneumocytes (see Alveolar epithelial cells)		

(Contd.)

(Contd.)

Cell Type	Location	Features and Functions
• Podocytes	– Renal corpuscle	– Epithelial cells lining the visceral layer of Bowman's capsule. Applied to glomerular capillaries. Show primary and secondary cytoplasmic processes. The filtration slits found between interdigitating secondary processes, contribute to <b>glomerular filtration barrier</b> .
• Principal cells (of parathyroid)	– (See Chief cells of parathyroid)	
• Protein-synthesizing cells	– E.g. Fibroblasts, plasma cells, pancreatic acinar cells, etc.	– Characterised by the presence of basophilic cytoplasm and vesicular nuclei. Basophilia is due to the presence of well developed rER and abundant ribosomes. Contain secretory granules.
• Protoplasmic astrocytes (see Astrocytes)		
• Pseudounipolar neurons (see Neurons)		
• Purkinje cells (Golgi type I)	– Cerebellar cortex	– Large flask-shaped neurons whose dendrites arborize profusely in the molecular layer and their axons end in deeper nuclei of cerebellum.
• Pus cells	– At the site of pus forming infection	– Are dead neutrophils. They degenerate after a single burst of phagocytic activity and are the main cellular elements of pus.
• Pyramidal cells	– Cerebral cortex	– Pyramidal neurons of varying sizes. Giant pyramidal cells in motor cortex are called <b>Betz cells</b> .
• Red blood cells (see Erythrocytes)		
• Reticular cells	– Lymphoid tissue – Myeloid tissue	– Fibroblast-like cells found along reticular fibres. Reticular fibres form stroma of lymphoid organs and bone marrow.
• Reticulocytes	– Peripheral blood	– Young erythrocytes soon after loss of nuclei during erythropoiesis.
• Rods	– Retina	– One of the photoreceptors concentrated at the periphery of retina. Outer segment is cylindrical in shape. – Contain photopigment, <b>rhodopsin</b> . – Sensitive to light of low intensity ( <b>night vision</b> ).
• Satellite cells	– Cerebrospinal and autonomic ganglia	– Cuboidal cells. Surround the cell bodies of ganglionic neurons forming a capsule. – Provide structural and metabolic <b>support</b> .
• Schwann cells	– Peripheral nerve	– Lie along the length of axons and envelop them. – Provide structural and metabolic <b>support</b> . – Form <b>myelin sheath</b> of peripheral nerve.
• Septal cells (see Alveolar epithelial cells II)		

(Contd.)

(Contd.)

Cell Type	Location	Features and Functions
<ul style="list-style-type: none"> <li>Sensory neurons (see Neurons)</li> </ul>		
<ul style="list-style-type: none"> <li>Serous cells</li> </ul>	– Serous gland	<ul style="list-style-type: none"> <li>Pyramidal cells with round centrally placed nuclei. Darkly stained cells forming serous acini. Cytoplasm is filled with zymogen granules.</li> <li>Secrete a thin watery <b>enzymatic secretion</b>.</li> </ul>
<ul style="list-style-type: none"> <li>Sertoli cells</li> </ul>	– Testis	<ul style="list-style-type: none"> <li>Tall columnar cells present among spermatogenic cells in the seminiferous epithelium.</li> <li>Form <b>blood testis barrier</b>.</li> <li>Provide support, protection and nutrition to maturing spermatogenic cells. Secrete <b>androgen binding protein</b>.</li> </ul>
<ul style="list-style-type: none"> <li>Somatotrophs</li> </ul>	– Adenohypophysis	<ul style="list-style-type: none"> <li>One of the acidophils of pituitary. Large round or oval cells with many cytoplasmic granules.</li> <li>Can be stained with orange G.</li> </ul>
<ul style="list-style-type: none"> <li>Spermatids</li> </ul>	– Testis	<ul style="list-style-type: none"> <li>Secrete <b>growth hormone (GH)</b>.</li> <li>Small round nonmotile germ cells. Have haploid number of chromosomes. Found close to the lumen of seminiferous tubules. Undergo morphological changes to become motile spermatozoa by a process called <b>spermiogenesis</b>.</li> </ul>
<ul style="list-style-type: none"> <li>Spermatocytes</li> <li>(a) Primary</li> <li>(b) Secondary</li> </ul>	– Testis	<ul style="list-style-type: none"> <li>Primary spermatocytes are the largest germ cells found in the middle of seminiferous epithelium. Undergo 1st meiotic division to form secondary spermatocytes which in turn become spermatids after 2nd meiotic division.</li> </ul>
<ul style="list-style-type: none"> <li>Spermatogonia</li> </ul>	– Testis	<ul style="list-style-type: none"> <li>Immature spermatogenic cells lying on the basement membrane of seminiferous tubules. Have diploid number of chromosomes. Give rise to primary spermatocytes.</li> </ul>
<ul style="list-style-type: none"> <li>Spermatozoa</li> </ul>	– Testis and epididymis	<ul style="list-style-type: none"> <li>Long motile male gametes derived from spermatids as a result of spermiogenesis in testis. Have haploid number of chromosomes. Consist of head, neck and tail. Stored in epididymis.</li> </ul>
<ul style="list-style-type: none"> <li>Spongiocytes</li> </ul>	– Zona fasciculata of adrenal cortex	<ul style="list-style-type: none"> <li>Polyhedral cells arranged in parallel cords in adrenal cortex. Presence of many lipid droplets gives a vacuolated appearance to the cytoplasm. So they are called spongiocytes. Secrete <b>glucocorticoids</b> mainly cortisol. Concerned with regulation of carbohydrate and protein metabolism.</li> </ul>
<ul style="list-style-type: none"> <li>Stave cells</li> </ul>	– Spleen	<ul style="list-style-type: none"> <li>Elongated spindle shaped <b>endothelial cells</b> lining venous sinuses of red pulp of spleen. Lie parallel to the long axis of sinuses like wooden staves of a barrel.</li> </ul>

(Contd.)

(Contd.)

Cell Type	Location	Features and Functions
<ul style="list-style-type: none"> <li>• Stellate cells (of cerebellar cortex)</li> <li>• Stellate cells (of cerebral cortex)</li> </ul>	<ul style="list-style-type: none"> <li>– Molecular layer of cerebellar cortex</li> <li>– All layers of cerebral cortex</li> </ul>	<ul style="list-style-type: none"> <li>– Small star-shaped neurons of uniform size whose axons terminate in nearby neurons.</li> </ul>
<ul style="list-style-type: none"> <li>• Steroid-secreting cells</li> </ul>	<ul style="list-style-type: none"> <li>– E.g. Leydig cells in testis, lutein cells in corpus luteum, cells of adrenal cortex</li> </ul>	<ul style="list-style-type: none"> <li>– Rounded or polyhedral cells with acidophilic cytoplasm. Rich in sER, mitochondria and lipid droplets.</li> <li>– Synthesise and secrete steroids.</li> </ul>
<ul style="list-style-type: none"> <li>• Suppressor T cells</li> </ul>	<ul style="list-style-type: none"> <li>– Lymphoid organs and peripheral blood</li> </ul>	<ul style="list-style-type: none"> <li>– Functional subtype of T lymphocytes. Existence is still controversial. May suppress autoimmune response.</li> </ul>
<ul style="list-style-type: none"> <li>• Sustentacular cells</li> </ul>	<ul style="list-style-type: none"> <li>– Taste bud, olfactory epithelium and organ of Corti</li> </ul>	<ul style="list-style-type: none"> <li>– Elongated spindle or columnar cells resting on basement membrane.</li> <li>– Provide structural and metabolic support to the sensory cells.</li> </ul>
<ul style="list-style-type: none"> <li>• Syncytial trophoblasts</li> </ul>	<ul style="list-style-type: none"> <li>– Placenta</li> </ul>	<ul style="list-style-type: none"> <li>– Form the outer layer of trophoblast covering the villi. Derived from fusion of cytotrophoblast cells to form a continuous multinuclear syncytium. Secrete <b>human chorionic gonadotrophin (HCG)</b>, <b>placental lactogen (HPL)</b>, <b>oestrogen</b> and <b>progesterone</b>.</li> </ul>
<ul style="list-style-type: none"> <li>• T lymphocytes (see Lymphocytes)</li> <li>• Taste cells (see Gustatory cells)</li> <li>• Theca lutein cells (see Paralutein cells)</li> <li>• Thrombocytes (see Platelets)</li> </ul>		
<ul style="list-style-type: none"> <li>• Thymocytes</li> </ul>	<ul style="list-style-type: none"> <li>– Thymus</li> </ul>	<ul style="list-style-type: none"> <li>– Immature and maturing T lymphocytes present in the thymic cortex. Involved in <b>cell mediated immunity</b>.</li> </ul>
<ul style="list-style-type: none"> <li>• Thyrotrophs</li> <li>• Trophoblasts (see Cyto- and syncytiotrophoblasts)</li> </ul>	<ul style="list-style-type: none"> <li>– Adenohypophysis</li> </ul>	<ul style="list-style-type: none"> <li>– A subtype of basophil. Contain small secretory granules located at the periphery of the cell. Secrete <b>TSH</b>.</li> </ul>
<ul style="list-style-type: none"> <li>• Umbrella cells (Dome cells)</li> <li>• White blood cells (see Leucocytes)</li> </ul>	<ul style="list-style-type: none"> <li>– Transitional epithelium</li> </ul>	<ul style="list-style-type: none"> <li>– Large round cells on the luminal surface of transitional epithelium seen when urinary bladder is not distended. May contain two nuclei. Show thickening of the luminal surface of plasma membrane called cuticle—provide <b>protection</b>.</li> </ul>
<ul style="list-style-type: none"> <li>• Zygote</li> <li>• Zymogenic cells (see Chief cells of fundic glands of stomach)</li> </ul>	<ul style="list-style-type: none"> <li>– Ampulla of fallopian tube</li> </ul>	<ul style="list-style-type: none"> <li>– Fertilized ovum (Fusion of male and female gametes at ampulla of fallopian tube results in restoration of diploid number of chromosomes, initiation of cleavage, formation of embryo).</li> </ul>

# INDEX

## A

Acetylcholine 136  
Acid mucus 226  
Acidophils 363, 364, 365  
Acne 196  
Acromegaly 93  
Actin 131, 134  
Adenohypophysis 362, 364, 368  
Adipose tissue 51, 55, 63, 64  
Afferent arterioles 272, 273, 277, 278  
Albinism 194  
Aldosterone 373  
Alveolar duct 350, 353  
Alveolar pores 353, 354  
Alveolar sacs 353  
Alveoli 350, 353  
Amacrine cells 391, 392  
Ameloblasts 215  
Amylase 211, 226  
Anal canal 233  
Anchoring fibrils 195  
Anterior subcapsular epithelium 394  
Antidiuretic hormone (ADH) 366  
Antigen-presenting cells (APC) 105  
Apical foramen 216  
Appendices epiploicae 232  
Appositional growth 73  
Aqueous humour 394  
Arcuate arteries 272  
Areola 325  
Arrector pili 198  
Arteries 174  
Astrocytes 155  
Astroglial cells 375  
Atretic follicle 318  
Axolemma 150  
Axon hillock 150  
Axon terminals 150  
Axoplasm 150

## B

B Lymphocytes 103  
Basal cells 345  
Basal lamina 13  
Basilar membrane 398  
Basket cells 158  
Basophils 60, 365  
Betz cells 156  
Bile  
    canaliculus 240  
    duct 240  
Bipolar  
    cells 392  
    neuron 147  
Blind spot of retina 390  
Blood testis barrier 295  
Blood–thymus barrier 108  
Bone 83  
Bone marrow 88  
Bony  
    cochlea 398  
    labyrinth 397  
    trabeculae 88  
Border cells 401  
Bowman's  
    capsule 273  
    glands 345  
    membrane 387  
    space 273  
Bronchiole 351  
Bruch's membrane 389  
Brunner's glands 229  
Brush cells 346  
Buccopharyngeal fascia 347  
Bulbourethral gland 300

## C

Caecum 232  
Calcination 85



Calcitonin 369  
 Canal of Schlemm 388  
 Cardia 226  
 Cardiac glands 226  
 Cartilage  
   elastic 74  
   hyaline 74  
 Cell cycle 25  
 Cell death 25  
 Cells of Martinotti 156  
 Cellular immune response 103  
 Cementoblasts 215  
 Cementum 215  
 Central artery 114  
 Centre of ossification 90  
 Cerebellar cortex 158  
 Cerebral cortex 155  
 Ceruminous gland 396  
 Cervical canal 323  
 Cervix of uterus 323  
 Chief cells 370  
 Chief or zymogenic cells, 226  
 Chondrocytes 74  
 Choriocapillary layer 389  
 Choroid 388  
 Chromaffin cells 374  
 Chromatophores 195  
 Chromophils 364  
 Chromophobes 364  
 Chylomicrons 227  
 Chyme 223  
 Ciliary body 389  
 Ciliary  
   epithelium 389  
   glands 394  
   muscle 389  
 Ciliated cells 346  
 Circumferential system 85  
 Circumvallate papillae 218  
 Clara cells 351  
 Classification of epithelial tissue 13  
 Climbing fibres 158  
 Collagen fibres 61  
 Collecting  
   duct 277  
   tubule 277  
 Colon 232  
 Colostrum 325  
 Compact bone 83  
 Cones 393  
 Conjunctiva 394  
 Continuous or somatic capillary 178  
 Cornea 386  
 Corneal epithelium 387  
 Corona radiata 317  
 Corpora

  amylacea 299  
   arenacea 375  
   cavernosa 300  
 Corpus albicans 319  
 Corpus luteum 318  
   of menstruation 319  
   of pregnancy 319  
 Cortical nephrons 273  
 Corticotrophs 365  
 Crista ampullaris 400  
 Crypts of Lieberkuhn 228  
 Cumulus oophorus 317

## D

Decalcification 84  
 Dendrites 150  
 Dense collagenous connective tissue 51  
 Dentinal tubules 215  
 Dermal papillae 195  
 Dermatoglyphics 189  
 Dermis 195  
 Descemet's membrane 388  
 Diaphysis 90  
 Dilator pupillae 390  
 Distal convoluted tubule 277  
 Ducts of Rivinus 235  
 Ductus epididymis 296  
 Dust cells 353  
 Dwarfism 93

## E

Efferent  
   arterioles 272  
   ductules 291  
 Ejaculatory duct 297  
 Endochondral ossification 90  
 Endocrine pancreas 243  
 Endocytosis 23  
 Endolymph 397  
 Endometrium 321  
 Endomysium 131  
 Endoneurium 152, 154  
 Endosteum 84  
 Enteroendocrine cells 227  
 Enteroglucagon 227  
 Eosinophils 60  
 Ependymal cells 155  
 Epidermis 190  
 Epididymis 296  
 Epiglottis 347  
 Epimysium 131  
 Epinephrine 374  
 Epineurium 152, 154

Epiphyseal plate 92  
 Epiphysis 91  
 Episcleral layer 385  
 Epithelial reticular cells 108  
 Eponychium 200  
 Exocrine pancreas 241  
 Exocytosis 23  
 External ear 396  
 Eye 385  
 Eyelashes 394

## F

Fat cells (adipocytes) 57  
 Fenestra cochleae 397  
 Fenestra vestibuli 397  
 Fenestrated or visceral capillary 179  
 Fibres  
   elastic 61  
 Fibroblasts 56  
 Fibrocartilage 74  
 Fibromuscular stroma 299  
 Fila olfactoria 345  
 Filiform papillae 218  
 Filtration slits 274  
 Fixed macrophages or histiocytes 57  
 Foliate papillae 218  
 Follicle  
   primary 316  
   secondary 317  
 Follicular cells 368  
 Fontanelles 90  
 Fovea centralis 390  
 Free macrophages 58  
 Free nerve endings 200  
 Fundic glands 226  
 Fungiform papillae 218  
 Fusiform cells 156

## G

Gall bladder 244  
 Ganglionic neurons 392  
 Gastric intrinsic factor 226  
 Gastric pits 223  
 Germinal epithelium 293, 313  
 GH 365  
 Gigantism 93  
 Glands of Zeis 394  
 Glans penis 300  
 Glisson's capsule 237  
 Glomerular filter 274  
 Glomerulus 274  
 Glomus 189  
 Glucocorticoids 373  
 Goblet cells 346

Golgi cells 158  
 Gonadotrophs 365  
 Graafian follicle 317  
 Granule cells 156, 346  
 Granulosa lutein cells 318  
 Ground substance 74  
 Gustatory cells 218

## H

Haemopoietic tissue 52  
 Hair  
   bulb 198  
   follicle 198  
   papilla 198  
 Hassall's corpuscles 108  
 Haversian  
   canal 86  
   system or osteon 86  
 Helicotrema 398  
 Hensen's cells 403  
 Hepatic acinus 240  
 Hepatocytes 240  
 Herring bodies 366  
 Horizontal cells of Cajal 156  
 Horizontal cells 391  
 Humoral immune response 103  
 Hydrochloric acid 226  
 Hyponychium 200

## I

Immunoglobulins 103  
 Inferior vena cava (IVC) 182  
 Inflammation 103  
 Infundibulum 362  
 Inter-alveolar septum 353  
 Intercellular junctions 14  
 Internal ear 397  
 Interneuron 148  
 Interstitial  
   growth 74  
   system 88  
 Intestinal villi 227  
 Intrafusal muscle fibres 136  
 Intrapulmonary bronchus 350  
 Iris 390

## J

Juxtaglomerular (JG)  
   cells 278  
   apparatus 278  
 Juxtamedullary nephrons 273

**K**

Keratin 193  
 Keratinocytes 193  
 Keratohyaline granules 193  
 Kidney 271  
 Kinocilium 399  
 Kupffer's cells 237

**L**

Labial glands 212  
 Lacis (network)/Polkissen cells 278  
 Lacrimal gland 395  
 Lactiferous duct 325  
 Lactiferous sinus 325  
 Lactotrophs 365  
 Lamina fusca 385  
 Langerhans cells 194  
 Lanugo 198  
 Large vein 173  
 Large/elastic artery 174  
 Laryngopharynx 346  
 Larynx 347  
 Lens substance 394  
 Lens 394  
 Leucocytes 59  
 Leydig cells 295  
 LH and FSH 365  
 Limbus spiralis 398  
 Lingual papillae 217  
 Lipase 226  
 Liquor folliculi 317  
 Liver 237  
 Liver lobule 237  
 Loop of Henle, 275  
 Loose areolar connective tissue 51  
 Lutein cells 318  
 Lymph node 109  
 Lymphatic nodules 110  
 Lymphocytes 59

**M**

M Cells 230  
 Macula  
   densa 278  
   lutea 390  
 MALT 106  
 Mammary gland 325  
 Mast cells 58  
 Mediastinum testis 291  
 Medium sized vein 180  
 Medium sized/Muscular/Distributing artery 176

Medullary  
   cords 111  
   rays 271  
   sinuses 111  
 Meissner's corpuscle 200  
 Melanocytes 194  
 Melanosomes 194  
 Melatonin 375  
 Membrana granulosa 317  
 Membranous labyrinth 398  
 Merkel's cells 194  
 Merkel's corpuscle 200  
 Mesangial cells 274  
 Mesaxon 151  
 Mesenchymal cells 56  
 Mesovarium 313  
 Meta-arterioles 178  
 Microglia 155  
 Microscopy 5  
 Microvilli 227  
 Middle ear 396  
 Milk teeth 213  
 Mineralocorticoids 373  
 Mongolian spot 195  
 Mossy fibres 160  
 Motor end-plates 136  
 Motor ganglia 154  
 Motor neuron 148  
 MSH 364  
 Mucocutaneous junctions 211  
 Mucoïd tissue 51  
 Mucous neck cells 226  
 Muller's cells 391  
 Multipolar neuron 147  
 Muscle of accommodation 389  
 Muscle spindles 136  
 Myelin sheath 150  
 Myelinated nerve fibres 150  
 Myoepithelial cells 37  
 Myofibril 133  
 Myofibroblasts 56  
 Myofilaments 133  
 Myoglobin 135  
 Myoid cells 293  
 Myometrium 321  
 Myosin 134

**N**

Nail 199  
 Nasal cavity 344  
 Nasopharynx 346  
 Natural killer (NK) cells 105  
 Navicular fossa 302  
 Nephron 273

Nervous layer 391  
 Neural crest cells 160  
 Neurofilaments 150  
 Neuroglia 155  
 Neurohypophysis 366  
 Neurons 147  
 Neutrophils 59  
 Nipple 325  
 Nissl bodies 148  
 Nodes of Ranvier 150  
 Norepinephrine 374

## O

Odontoblasts 215  
 Oesophageal glands 222  
 Oestrogen 317  
 Olfactory mucosa 345  
 Oligodendrocytes 155  
 Oocyte (ovum) 313  
 Optic disc 390  
 Optic papilla 390  
 Ora serrata 390  
 Oral cavity 211  
 Orbicularis oculi 395  
 Ordinary connective tissue 56  
 Organ of Corti 401  
 Oropharynx 346  
 Osseous spiral lamina 398  
 Ossification 88  
   primary centre 90  
   secondary centre 91  
 Osteogenic or periosteal bud 91  
 Osteoid 90  
 Osteomalacia 92  
 Osteoprogenitor cells 84  
 Otolithic membrane 399  
 Otoliths or otoconia 399  
 Outer fibrous coat/Sclerocorneal layer 385  
 Ovulation 317  
 Oxyphil cells 370  
 Oxytocin 366

## P

Pacinian corpuscle 200  
 Palatine tonsil 116  
 Paneth cells 228  
 Papillary ducts 277  
 Parafollicular cells 368, 369  
 Parathormone (PTH) 370  
 Parathyroid 370  
 Paraurethral glands of Littre 302  
 Paraventricular nuclei 366  
 Parietal or oxyntic cells 226  
 Parotid 235

Pars distalis 362  
 Pars intermedia 362  
 Pars nervosa 362  
 Pars tuberalis 362  
 Peg (secretory) cells 320  
 Penicillar arterioles 114  
 Penile urethra 300  
 Penis 300  
 Pepsinogen 226  
 Periarterial lymphatic sheath 114  
 Perichondrium 73  
 Pericytes or adventitial cells 178  
 Perilymph 397  
 Perimetrium 321  
 Perimysium 131  
 Perineurium 152  
 Periodontal ligament 216  
 Periosteum 84  
 Permanent teeth 213  
 Peyer's patches 230  
 Phagocytosis 24  
 Phalangeal cells 401  
 Pharynx 346  
 Pharyngobasilar fascia 346  
 Photoreceptors 391  
 Pigment epithelium 390  
 Pillar cells 401  
 Pineal body 375  
 Pinealocytes 375  
 Pinocytosis 24  
 Pituicytes 366  
 Pituitary (hypophysis cerebri) 361  
 Placenta 328  
 Plasma cells 58  
 Plicae circulares 227  
 Podocytes 274  
 Portal lobule 240  
 Postcapillary venules 180  
 Primary spermatocytes 294  
 Primordial follicle 314  
 Principal bronchus 350  
 Progesterone 318  
 Prolactin (PRL) 365  
 Prostate 299  
 Prostatic  
   urethra 299  
   utricle 299  
 Pseudo-unipolar neuron 147, 154  
 Pulmonary surfactant 355  
 Pulp cavity 213  
 Pupil 390  
 Purkinje cells 158  
 Pyloric  
   glands 227  
   sphincter 227  
 Pyramidal cells 156

**R**

Rectum 232  
 Red and white muscle fibres 136  
 Renal column of Bertin 271  
 Renal  
   lobe 272  
   lobule 272  
   papillae 271  
   pyramids 271  
 Renin 278  
 Respiratory bronchiole 351  
 Respiratory mucosa 345  
 Rete testis 291  
 Reticular  
   fibres 62  
   lamina 13  
   tissue 51  
 Retina 390  
 Rickets 92  
 Rods 391  
 Root canal 213  
 Ruffini's corpuscle 200  
 Rugae 223

**S**

Scanning electron microscopy 7  
 Saccule 399  
 Saccus endolymphaticus 399  
 Salivary glands 234  
 Sarcomere 133  
 Satellite cells 154  
 Scala  
   media 398, 401  
   tympani 398, 401  
 Schmidt-Lantermann clefts 151  
 Schwann cells 150  
 Sclera 385  
 Scleral connective tissue 52  
 Scleral venous sinus 388  
 Scurvy 92  
 Sebum 196  
 Secondary spermatocytes 294  
 Semicircular  
   canals 397  
   ducts 400  
 Seminal vesicle 298  
 Seminiferous  
   epithelium 293  
   tubules 293  
 Sensory neuron 148  
 Sensory ganglia 154  
 Septal cells 355  
 Sertoli cells 295  
 Sharpey's fibres 84

Single corpus spongiosum 300  
 Sinus  
   laticiferous 325  
 Sinuses of Morgagni 302  
 Sinusoidal capillary 179  
 Sinusoids 237  
 Skeletal muscle 131  
 Small Intestine 227  
 Smooth muscle 351  
 Somatotrophs 365  
 Space of Disse 239  
 Spaces of Fontana 388  
 Spermatids 294  
 Spermatocytogenesis 294  
 Spermatogenesis 293  
 Spermatogenic cells 293  
 Spermatogonia 293  
 Sphincter pupillae 390  
 Spinal ganglion 154  
 Spiral ligament 398  
 Splenic cords of Billroth 114  
 Splenic venous sinuses 114  
 Spongy or cancellous bone 88  
 Stave cells 114  
 Stellate cells 158  
 Straight tubules 291  
 Stratum opticum 392  
 Stria vascularis 401  
 Subcapsular sinus 110  
 Sublingual gland 235  
 Submandibular gland 235  
 Substantia propria 388  
 Superior conjunctival fornix 395  
 Superior vena cava (SVC) 182  
 Suprachoroidal layer 389  
 Supraoptic nuclei 366  
 Suprarenal 372  
 Surface modifications of epithelial cells 15  
 Sustentacular cells 218  
 Sympathetic ganglion 154  
 Synostosis 92

**T**

Transmission electron microscopy 6  
 T Lymphocytes 105  
*Taenia coli* 232  
 Tarsal (Meibomian) glands 395  
 Tarsal plate 395  
 Taste buds  
   hairs 218  
   pore 218  
 Tectorial membrane 403  
 Teeth 213  
 Tenon's  
   capsule 385  
   space 385

Terminal boutons 150  
 Testis 291  
 Testosterone 295  
 Tetra-iodothyronine 368  
 Theca  
     externa 317  
     folliculi 316  
     interna 317  
     lutein cells 318  
 Thymus 106  
 Thyroid 367  
 Thyroid follicles 368  
 Thyrotrophs 365  
 Thyroxine 368  
 Tongue 216  
 Tonofibrils 193  
 Tonofilaments 193  
 Trachea 348  
 Trachealis 348  
 Transitional epithelium 280  
 Transverse (T) tubule 135  
 Triad 135  
 Tri-iodothyronine 368  
 TSH 365  
 Tubal tonsils 346  
 Tubercles of Montgomery 325  
 Tunica  
     albuginea 291, 300, 313  
     vaginalis 291  
     vasculosa 291  
 Tunnel of Corti 401  
 Type I pneumocytes 355

## U

Umbilical cord 330  
 Unipolar neuron 147

Unmyelinated nerve fibres 150  
 Uriniferous (renal) tubules 272  
 Urogastrone 229  
 Urothelium 280  
 Uterine glands 321  
 Uterine tube (Fallopian tube) 320  
 Utricle 399  
 Uveal tract 388

## V

Vagina 324  
 Vas deferens 297  
 Vasa recta 272  
 Vasa vasorum 174  
 Vascular layer 389  
 Vasopressin 366  
 Vellus 198  
 Vermiform appendix 232  
 Vermilion border 212  
 Vestibular (Reissner's) membrane 401  
 Vestibule 345  
 Vitreous body 394  
 Volkmann's canals 86

## W

Wharton's duct 235

## Z

Zona fasciculata 373  
 Zona glomerulosa 373  
 Zona pellucida 316  
 Zona reticularis 373